Thieme

Endoscopy E-Videos

Jejunal endoscopic submucosal dissection is feasible using the pocket-creation method and balloon-assisted endoscopy

Endoscopic submucosal dissection (ESD) is widely used for the resection of superficial gastrointestinal neoplasms. Previously, we reported that the pocket-creation method (PCM) overcomes difficulties in ESD, such as in duodenal lesions [1] and subpedunculated neoplastic lesions [2]. Here, we describe the use of the PCM to facilitate ESD of a jejunal lesion.

A 54-year-old woman with familial adenomatous polyposis was referred for resection of a large adenoma in the proximal jejunum. Laparotomy would have been difficult owing to adhesions from previous surgery. Good maneuverability was confirmed in the vicinity of the lesion by double-balloon endoscopy (▶ **Fig. 1**), and we performed ESD using the PCM and balloon-assisted endoscopy (BAE).

An endoscope with a 3.2-mm working channel (EI-580BT; Fujifilm, Tokyo, Japan) and a small-caliber-tip transparent hood (ST hood; DH-15GR; Fujifilm) were used. The endoscope tip balloon was not attached because the lesion was located in the upper jejunum. The Hook knife (Olympus, Tokyo, Japan) was used for most of the dissection. The key feature of the PCM is entering and dissecting the submucosal layer to make a pocket using an ST hood after a minimal mucosal incision (▶ **Fig. 2**). After creation of the submucosal pocket under the entire tumor, an additional mucosal incision was made and submucosal dissection performed. Use of the PCM for ESD with BAE safely

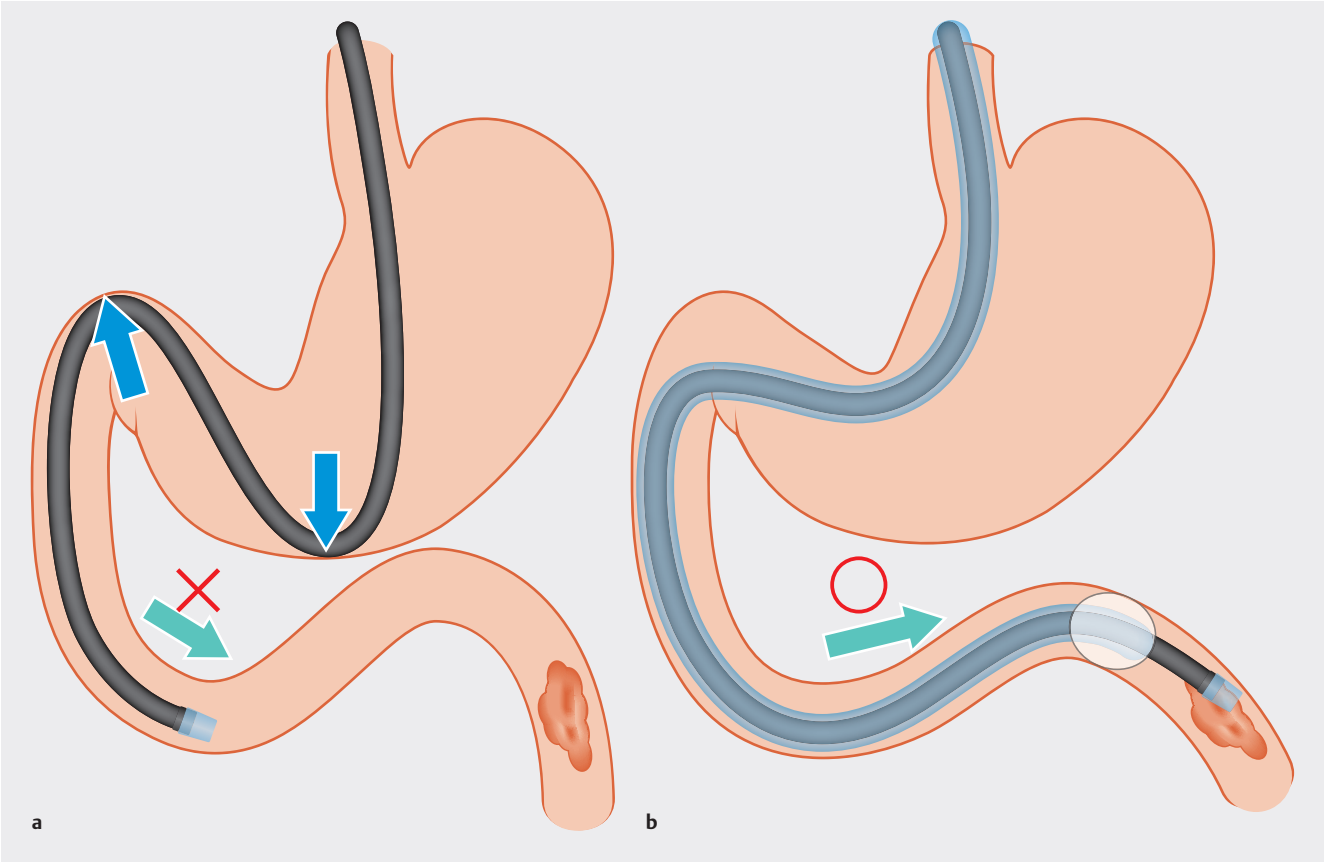

▶ **Fig. 1** Advantages of balloon-assisted endoscopy (BAE) compared with push enteroscopy. **a** Push enteroscopy becomes unstable owing to stretching of the gastric and duodenal walls. **b** By using BAE, the overtube with a balloon prevents a redundant loop, enabling accurate and stable operation without paradoxical movements.

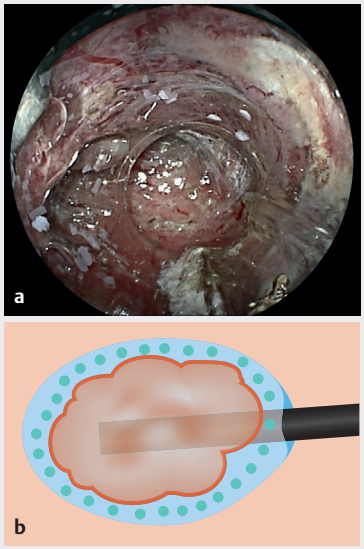

▶ **Fig. 2** An endoscopic image and schema of the pocket-creation method of endoscopic submucosal dissection for jejunal neoplastic lesions. **a** Endoscopic image in a submucosal pocket after creation of the submucosal pocket under the entire tumor. **b** Schema at the time the pocket was completed.

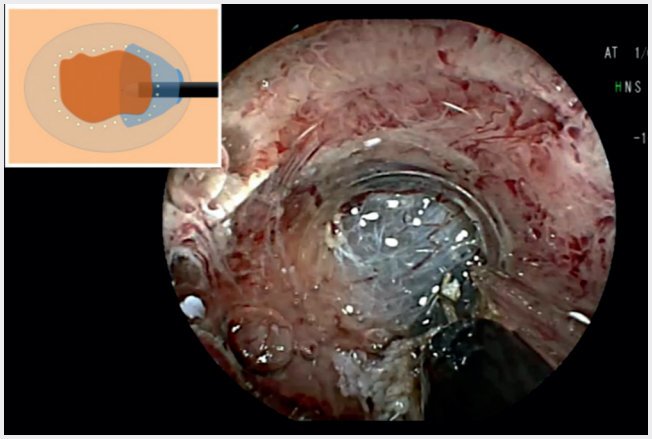

▶ **Video 1** The pocket-creation method for endoscopic submucosal dissection of a jejunal adenoma.

achieved an en bloc resection of the tumor (▶ **Video 1**).

The PCM has four main advantages including: (i) maintaining a thick submucosal layer with a minimal incision; (ii) obtaining good traction by using an ST hood; (iii) conquering the vertical approach by adjusting the direction of the endoscope tip; and (iv) stabilizing the endoscope tip by synchronizing the endoscope and the pocket [1]. By using BAE, the overtube with a balloon prevents formation of a redundant loop, enabling accurate and stable operation without paradoxical movements (▶ **Fig. 1**) [3].

Endoscopy_UCTN_Code_TTT_1AP_2AD

Competing interests

Hironori Yamamoto has patents for ESD devices and double-balloon endoscopy produced by Fujifilm Corporation. He also has a consultant relationship with the Fujifilm Corporation and has received honoraria, grants, and royalties from the company. Yoshimasa Miura, Tomonori Yano, and Yoshikazu Hayashi have received honoraria from Fujifilm Corporation.

The authors

Mizuho Iida[1], Hirotsugu Sakamoto[1], Yoshimasa Miura[1], Tomonori Yano[1], Yoshikazu Hayashi[1], Alan Kawarai Lefor[2], Hironori Yamamoto[1]

1 Department of Medicine, Division of Gastroenterology, Jichi Medical University, Shimotsuke, Japan

2 Department of Surgery, Jichi Medical University, Shimotsuke, Japan

Corresponding author

Hironori Yamamoto, MD, PhD
3311-1 Yakushiji, Shimotsuke, Tochigi 329-0498, Japan
Fax: +81-285-406598
ireef@jichi.ac.jp

References

[1] Miura Y, Shinozaki S, Hayashi Y et al. Duodenal endoscopic submucosal dissection is feasible using the pocket-creation method. Endoscopy 2017; 49: 8 – 14

[2] Hayashi Y, Sunada K, Takahashi H et al. Pocket-creation method of endoscopic submucosal dissection to achieve en bloc resection of giant colorectal subpedunculated neoplastic lesions. Endoscopy 2014; 46 (Suppl. 01): E421 – E422

[3] Yamashina T, Hayashi Y, Sakamoto H et al. Balloon-assisted endoscopy facilitates endoscopic submucosal dissection of difficult superficial proximal colon tumors. Endoscopy 2018. DOI: 10.1055/s-0044-100720

Bibliography
DOI https://doi.org/110.1055/a-0626-6893
Endoscopy 2018; 50: 931–932

ISSN 0013-726X