

Management of Urethral Lesions and Urethrovaginal Fistula Formation Following Placement of a Tension-Free Suburethral Sling: Evaluation From a University Continence and Pelvic Floor Centre

Management von Urethraläsionen und urethrovaginaler Fistelbildung nach Anlage einer spannungsfreien suburethralen Schlinge: Evaluation aus einem universitären Kontinenz- und Beckenbodenzentrum



Authors

Dorit Schöller, Sara Brucker, Christl Reisenauer

Affiliation

Obstetrics and Gynecology, University of Tübingen, Tübingen, Germany

Key words

urethrovaginal fistula, TVT erosion, urethral lesion, Martius flap

Schlüsselwörter

urethrovaginale Fistel, TVT-Erosion, Urethraläsion, Martius-Flap

received 17.7.2018

revised 18.8.2018

accepted 19.8.2018

Bibliography

DOI <https://doi.org/10.1055/a-0704-3461>

Geburtsh Frauenheilk 2018; 78: 991–998 © Georg Thieme Verlag KG Stuttgart · New York | ISSN 0016-5751


Correspondence

Prof. Dr. Christl Reisenauer

Universitätsklinikum Tübingen, Frauenklinik

Calwerstraße 7, 72076 Tübingen, Germany

Christl.Reisenauer@med.uni-tuebingen.de

 Deutsche Version unter:
<https://doi.org/10.1055/a-0704-3461>

ABSTRACT

Introduction The complication of tape erosion in the urethra following placement of a retropubic (TVT) or transobturator (TOT) tension-free suburethral vaginal sling or an accidental iatrogenic transurethral tape position can result in the formation of a urethrovaginal or vesicovaginal fistula. The objective of the investigation is the evaluation of the management of such rare complications.

Patients and Methods Retrospective analysis of 14 patients who were treated for a urethral lesion or urethrovaginal fistula formation status post TVT/TOT placement between June 2011 and February 2018 in the Tübingen University Department of Gynaecology.

Results As surgical therapy, 57.1% (n = 8) cases underwent vaginal fistula closure using a Martius flap of the labium majus and in 21.4% (n = 3) using a vaginal rotation skin flap. In 21.4% (n = 3), exclusively vaginal suture reconstruction of the urethra following excision of the tape running transurethrally or tape erosion was performed. 50% (n = 7) of the patients had lasting continence postoperatively without any further need for therapy. In 28.6% (n = 4), there was ongoing stress urinary incontinence, in 21.4% (n = 3) mixed urinary incontinence. Six of the 7 patients with persistent incontinence underwent new placement of a tension-free suburethral retropubic sling (TVT) an average of 8.8 months (5–13 months) postoperatively which was uncomplicated in all patients and achieved satisfactory continence. The 3 patients with mixed urinary incontinence and persistent urgency components additionally received anticholinergic medication. During the time period investigated, there were no long-term complications, in particular no recurrent fistulas.

Conclusion The rare but relevant complications of a urethral erosion, transurethral tape position or urethrovaginal fistula formation status post TVT/TOT placement can be successfully managed via vaginal surgery. Persistent postoperative urinary incontinence with the need for a two-phase repeat TVT

placement following sufficient wound healing must be preoperatively clarified.

ZUSAMMENFASSUNG

Einleitung Die Komplikation einer Banderosion in die Urethra nach Anlage einer retropubischen (TVT) oder transobturatorischen (TOT) spannungsfreien suburethralen Vaginalschlinge oder die iatrogen akzidentell verursachte transurethrale Bandlage können eine urethrovaginale bzw. vesikovaginale Fistelbildung zur Folge haben. Zielsetzung der Untersuchung ist die Auswertung des Managements solcher seltenen Komplikationen.

Patienten und Methode Retrospektive Analyse von 14 Patientinnen, die aufgrund einer urethralen Läsion bzw. urethrovaginaler Fistelbildung im Zustand nach TVT-/TOT-Anlage zwischen Juni 2011 und Februar 2018 in der Universitäts-Frauenklinik Tübingen behandelt wurden.

Ergebnisse Als operative Therapie erfolgte in 57,1% (n = 8) der vaginale Fistelverschluss mittels Martius-Flap des Labium majus und in 21,4% (n = 3) mittels eines vaginalen Schwenkhautlappens. In 21,4% (n = 3) erfolgte ausschließlich die vaginale Nahtrekonstruktion der Urethra nach Exzision des trans-

urethral verlaufenden Bandes bzw. der Banderosion. 50% (n = 7) der Patientinnen waren postoperativ anhaltend kontinent ohne weiteren Therapiebedarf. Bei 28,6% (n = 4) bestand eine anhaltende Belastungsharninkontinenz, bei 21,4% (n = 3) eine Mischharninkontinenz. Bei 6 der 7 persistierend inkontinenten Patientinnen erfolgte die Neuanlage einer spannungsfreien suburethralen retropubischen Schlinge (TVT) im Mittel 8,8 Monate (5–13 Monate) postoperativ, die bei allen Patientinnen komplikationslos verlief und eine zufriedenstellende Kontinenz erreichte. Die 3 Patientinnen mit Mischharninkontinenz und persistierender Drangkomponente erhielten ergänzend eine anticholinerge Medikation. Es traten keine Langzeitkomplikationen, insbesondere keine Fistelrezidive, im untersuchten Zeitraum auf.

Schlussfolgerung Die seltene, aber relevante Komplikationen einer urethralen Erosion, transurethralen Bandlage oder urethrovaginaler Fistelbildung im Zustand nach TVT-/TOT-Anlage kann erfolgreich vaginal operativ gemanagt werden. Eine postoperativ persistierende Harninkontinenz mit der Notwendigkeit einer zweizeitigen erneuten TVT-Anlage nach ausreichender Wundheilung muss präoperativ aufgeklärt werden.

Introduction

The placement of a retropubic (TVT) or transobturator (TOT) tension-free suburethral vaginal sling is considered the gold standard for the treatment of stress urinary incontinence and is widely used [1]. Complications are rare in this case. While iatrogenic accidental bladder perforations are described in 4% of cases, intraoperative injuries of the urethra, at 0.5%, appear to be far more rare [2]. Postoperative tape erosions in the bladder are described in 0.5–0.6% of cases and in the urethra in 0.007–1.5% of cases [3, 4]. However the erosion of the tape in the urethra or the accidental iatrogenic transurethral tape position as well as necessary revision surgeries, such as in terms of a secondary tape transection in the case of bladder voiding dysfunction, can result in a urethrovaginal or vesicovaginal fistula formation [5, 6]. This very rare complication signifies a massive limitation in quality of life for the patient, generally with incontinence and pain as well as often multiple operations, which also present a major surgical challenge for the surgeon.

We are reporting on our experience with 14 patients who were referred to the Tübingen University Department of Gynaecology with urethral erosion or a urethral lesion or urethrovaginal fistula following a TVT/TOT placement. The objective of this investigation is the description of the diagnostics and management of such rare complications.

Patients and Methods

The case files of 14 female patients who were treated in the certified continence and pelvic floor centre of the Tübingen University Department of Gynaecology between June 2011 and February 2018 due to a urethral lesion or urethrovaginal or urethrovesico-

vaginal fistula formation following placement of a TVT (n = 10) or TOT (n = 4) at an outside hospital were retrospectively analysed using in-house digital patient files. The cases were identified based on in-house statistics. Approximately 3000 patients with urinary incontinence are treated annually at the Tübingen University Department of Gynaecology.

The detailed characteristics of the patients can be seen in ► **Table 1**. Monofilament tapes were used in all patients. Thirteen of the 14 patients were already referred with the diagnosis confirmed at an outside facility. One patient presented due to pronounced recurrent urinary incontinence following TOT placement in which the intraurethral tape position was diagnosed on ultrasound and cystoscopically during the initial presentation. Recurrent urinary incontinence, pain or vaginal urine loss were indicated as symptoms. Microhaematuria was detected in some patients. The primary surgeries for the TVT/TOT placement occurred between 3 months and 15 years previously. In 10 of the 14 cases (71.4%), up to 3 revision surgeries (tape transection, [partial] removal of the tape, fistula closure/excision) had already been performed at outside facilities.

Results

We are presenting a collective of 14 unique cases with urethral tape erosion/tape penetration following placement of a suburethral retropubic or transobturator sling for the treatment of stress urinary incontinence and describe the diagnostic and therapeutic management.

The mean age of the patients was 54.8 years (41–67 years).

In addition to a detailed medical history, the preoperative diagnostic measures included a gynaecological examination, an introitus ultrasound and renal ultrasound and a urethroscopy

► **Table 1** Case overview. Patient characteristics.

Case no.	Age at time of initial presentation to the Tübingen Dept. of Gynaecology	Diagnosis	Previous surgeries at an external facility	Surgical management
1	52	TOT running transurethrally	TOT placement 02/2014	TOT excision, urethral reconstruction. interposition of a Martius flap from the right labium majus 11/2016. TVT placement 12/2017.
2	50	Arm of TVT in the urethra	TVT placement 06/2016. Transection of the TVT tape running through the urethra following an unsuccessful attempt at tape removal 11/2016.	TVT excision, urethral reconstruction using 2 tension-free rows of simple, interrupted sutures 12/2017. TVT placement 7/2018.
3	58	TVT running transurethrally	TOT placement 05/2011	TOT excision, urethral reconstruction using 2 tension-free rows of simple, interrupted sutures 09/2016. TVT placement 03/2017.
4	50	0.5 cm urethrovaginal fistula	TVT placement 03/2012. TVT transection due to persistent urinary retention 04/2012. Partial TVT removal due to pain and 2 surgical revisions due to secondary haemorrhage 10/2012.	Urethrovaginal fistula closure with Martius flap interposition of the right labium majus 03/2013. Laparoscopic adhesiolysis and ovarian cyst removal, left, mini laparotomy with removal of both TVT arms in toto from the retropubic space due to persistent abdominal pain 05/2014. Burch colposuspension in 03/2016 at another facility after refusing the recommended repeat TVT placement.
5	53	4 cm urethrovesicovaginal fistula with destruction of the complete urethra and bladder neck	TVT placement 12/2016. Removal of the tape running transurethrally 03/2017.	Reconstruction of the urethra and bladder neck and Martius flap interposition of the left labium majus 10/2017.
6	64	Vaginal, vesical and urethral erosion of the TVT and the anterior mesh	Anterior mesh implantation 2005. TVT placement 2006.	Excision of the implant erosions and reconstruction of the bladder and urethra 01/2014.
7	65	Double 1 mm urethrovaginal fistula	TVT placement 03/2007. Tape loosening 04/2007. Tape transection in the setting of residual urine formation and bladder voiding dysfunction 05/2016. Partial TVT transection in the setting of bladder voiding dysfunction with intraoperative urethral lesion 05/2016.	Urethrovaginal fistula closure and Martius flap interposition of the large right labium majus 07/2016.
8	59	1.5 cm recurrent urethrovaginal fistula	Vaginal hysterectomy and TVT placement 2000. Attempt to close a urethrovaginal fistula after excision of a periurethral granuloma based on an eroded TVT tape 05/2014.	Urethral reconstruction with vaginal tissue rotation flap 02/2015. TVT placement 03/2016.
9	58	2 mm urethrovaginal fistula in the setting of a TOT running transurethrally	TOT placement 02/2014	TOT partial removal, urethrovaginal fistula closure and Martius flap interposition from the right labium majus 07/2014.
10	41	Double 8 mm recurrent urethrovaginal fistula	TOT placement with suture dehiscence and secondary suture 09/2016. TOT tape removal 12/2016. Urethrovaginal fistula closure 01/2017. Urethrovaginal fistula excision and over-sewing 03/2017.	Urethrovaginal fistula closure and Martius flap interposition from the right labium majus 09/2017.

Continued next page

► **Table 1** Case overview. Patient characteristics. (Continued)

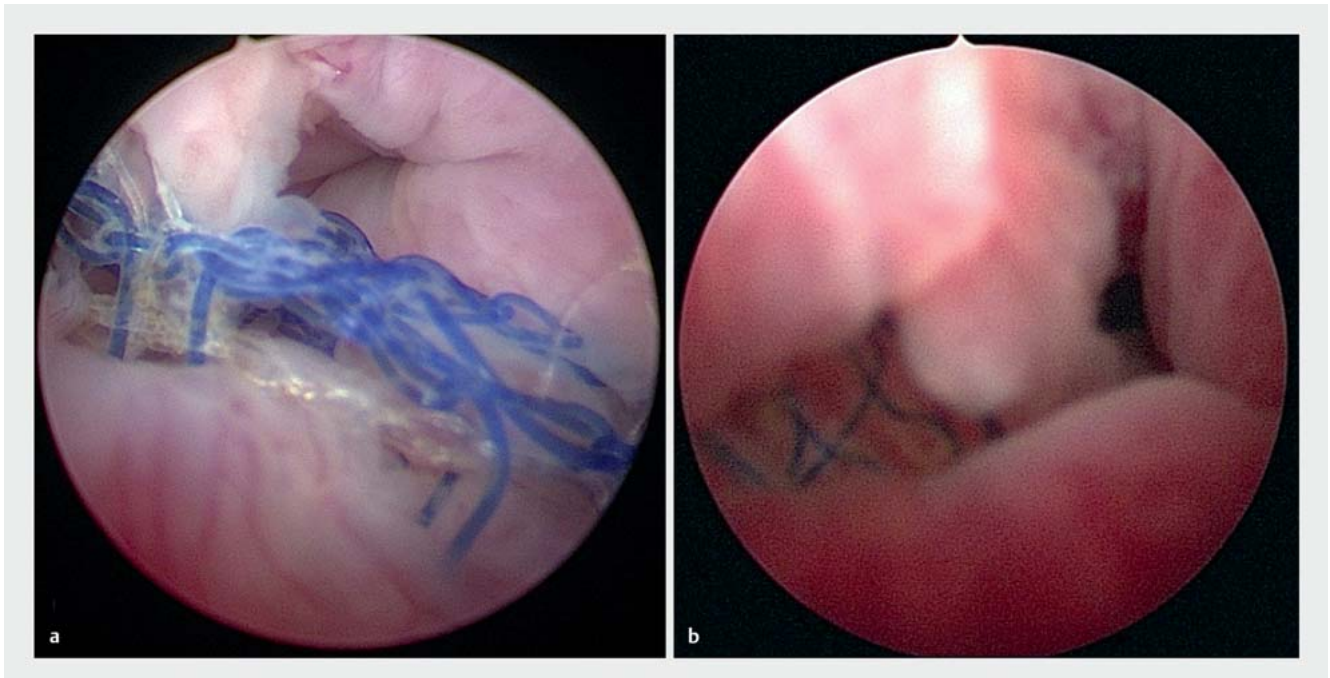
Case no.	Age at time of initial presentation to the Tübingen Dept. of Gynaecology	Diagnosis	Previous surgeries at an external facility	Surgical management
11	60	2 mm urethrovaginal fistula with TVT erosion in the urethra	TVT placement 2007	TVT partial removal, urethral suture using the simple, interrupted suture technique 03/2013. T-inverted vaginal tissue flap due to persistent fistula 09/2013. TVT placement 03/2014.
12	72	2 mm vesicourethrovaginal fistula in the region of the bladder neck	Vaginal hysterectomy, vaginal sacrospinous fixation according to Amreich-Richter, TVT placement 02/2012. TVT transection in the setting of bladder voiding dysfunction 05/2012. Partial resection of the TVT in the setting of urge incontinence; suturing of a bladder lesion 05/2012.	Urethrovesicovaginal fistula closure and Martius flap interposition from the right labium majus 11/2012. TVT placement 04/2013.
13	60	2 cm urethrovaginal fistula	TVT placement 2004. External urethrotomy with resection of the intraluminal tape 10/2009. Suprapubic TVT explantation, left 10/2010.	Urethral reconstruction with vaginal tissue rotation flap 09/2011.
14	62	2 cm urethrovaginal fistula	TVT placement 04/2017. TVT explantation and closure of a vesicovaginal fistula, oblique oversewing of the urethra and flaps of the anterior vaginal wall 09/2017.	Urethrovaginal fistula closure und Martius flap interposition from the right labium majus 02/2018.

(► **Fig. 1 a and b**). While the urethrovaginal fistula could be clearly seen during the gynaecological examination in some patients (► **Fig. 2**), the urethrovaginal fistula formation could be identified in other patients only upon exploration (► **Fig. 3 a**). Following intraurethral introduction of blue solution, two patients were even able to be diagnosed with a double urethrovaginal fistula (► **Fig. 3 b**). ► **Fig. 3 c** shows urine leakage into the vagina through the urethrovaginal fistula. As symptoms, all patients indicated recurrent stress urinary incontinence or continual involuntary urine loss. In 28.6% (n = 4), there were also symptoms of urgency and in 21.4% (n = 3) there was also local pain.

In the case of unremarkable urinary findings, surgical therapy, in 57.1% (n = 8), involved vaginal fistula closure using Martius flap interposition of the labium majus (► **Fig. 4 a to c**) and in 21.4% (n = 3), it involved the use of vaginal rotation tissue flaps (► **Fig. 5 a to c**). The surgical techniques were performed as already described in the literature [6, 7]. In 21.4% (n = 3), surgery consisted exclusively of vaginal suture reconstruction of the urethra in 2 tension-free rows of simple interrupted sutures after excision of the tape running transurethrally or tape erosion. All surgeries were performed by the same urogynaecological surgeon (CR), in one case in cooperation with colleagues from urology. The surgical method was chosen based on the size and location of the urethral defect as well as the local tissue conditions as an individual case-specific decision. If the fistula was near the external urethral ostium, we performed the urethral reconstruction us-

ing vaginal tissue rotation flaps. Due to an infected TVT tape, a planned two-stage procedure was performed in one case with initial partial removal of the TVT and fistula closure in the interval. All patients underwent an intraoperative urethrocystoscopy as well as the placement of a suprapubic bladder catheter (SPC) and an indwelling transurethral catheter (IC). The IC was able to be removed after 2–12 days. The inpatient discharge took place with prophylactic oral antibiotic administration of nitrofurantoin extended release with the SPC in place which was able to be removed as usual in all cases after 3–4 weeks after prior bladder training which had been performed for 1–3 days. There were no serious postoperative complications. In one case, on the 6th postoperative day, the outpatient urethrocystoscopy and bladder irrigation were performed due to impaired outflow of the SPC and another patient underwent outpatient urethrocystoscopy and examination under anaesthesia 4 weeks postoperatively to rule out a recurrent fistula in the setting of involuntary loss of urine. There was no abnormal wound healing or recurrent fistulas.

50% (n = 7) of the patients were symptom-free postoperatively and persistently continent without any further need for therapy. In 28.6% (n = 4) there was ongoing stress urinary incontinence, in 21.4% (n = 3) there was mixed urinary incontinence. After exhausting options for conservative treatment, 6 out of the 7 patients with persistent incontinence underwent the new placement of a tension-free suburethral retropubic sling (TVT) an average of 8.8 months (5–13 months) postoperatively which was

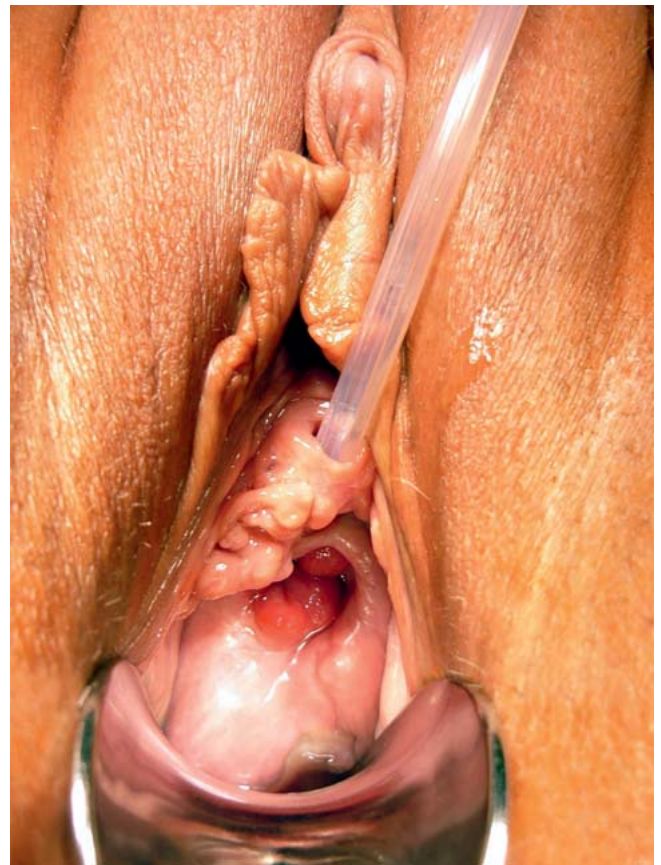

► **Fig. 1** Urethroscopy: a Tape running through the urethra, b right-sided urethral tape penetration.

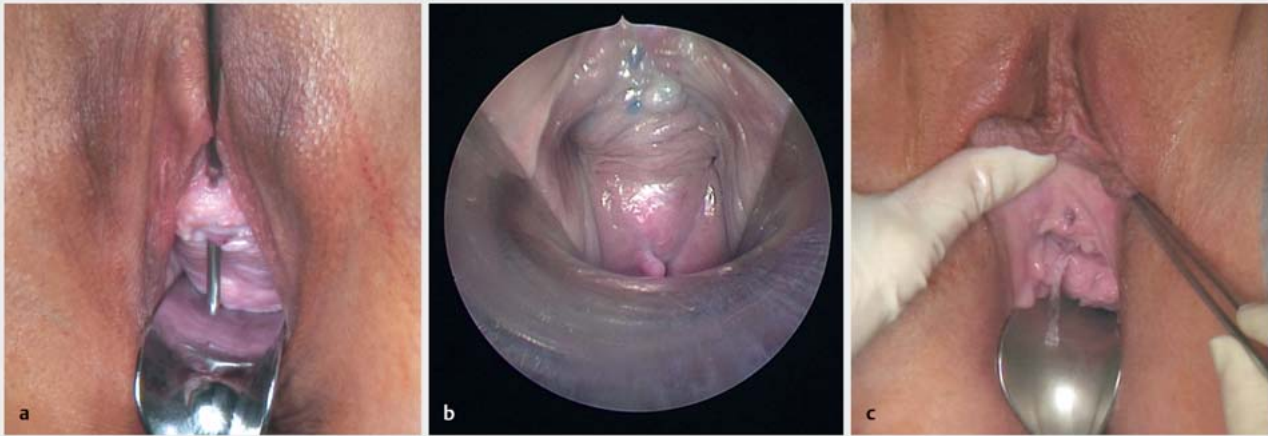
performed without complications in all patients and achieved satisfactory continence. In one patient, the use of incontinence tampons is still sufficient to treat the stress urinary incontinence. One patient refused the recommended repeat placement of a TVT. A Burch colposuspension performed elsewhere did not result in any satisfactory continence in this case. The 3 patients with mixed urinary incontinence and persistent urgency component additionally received anticholinergic medication. Due to persistent abdominal pain following vaginal closure of the urethrovaginal fistula via Martius flap, one patient secondarily underwent laparoscopic adhesiolysis and removal of both TVT arms in toto from the retropubic space via mini laparotomy 14 months postoperatively. The mean follow-up observation period was 7.5 months. There were no long-term complications, in particular no recurrent fistulas, during the time period investigated.

Discussion

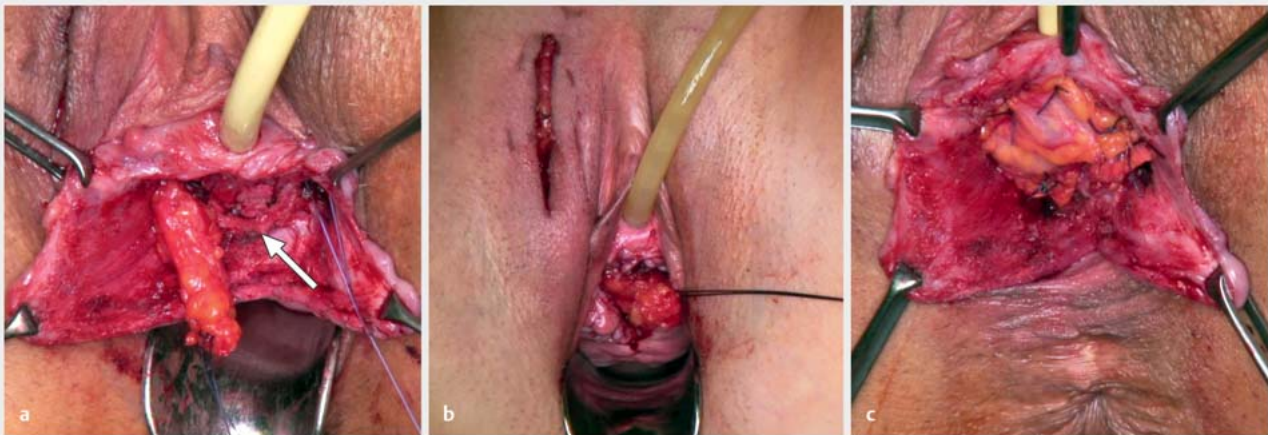
The placement of a retropubic (TVT) or transobturator (TOT) tension-free suburethral vaginal sling for the treatment of stress urinary incontinence is widely performed [1]. The erosion of a TVT or TOT tape in the urethra, iatrogenic accidental transurethral tape position and a urethrovaginal or urethrovesicovaginal fistula formation following placement of a TVT or TOT or revision surgeries are rare in this case but extremely relevant and complex complications [2]. Persistent or new urinary incontinence but also genital pain are clinically indicative. A careful medical history and a clinical examination as well as a diagnostic urethrocytostcopy, if applicable, under anaesthesia, appear to be sufficient for diagnosis (literature: Reisenauer). In our collective, 13 of the 14 (92.9%) patients were already referred with the diagnosis which was con-



► **Fig. 2** Gynaecological examination: urethrovaginal fistula.



► **Fig. 3** Gynaecological examination: a urethrovaginal fistula with probe in place, b double urethrovaginal fistula following urethral filling with blue solution, c urethrovaginal fistula with urine leakage.

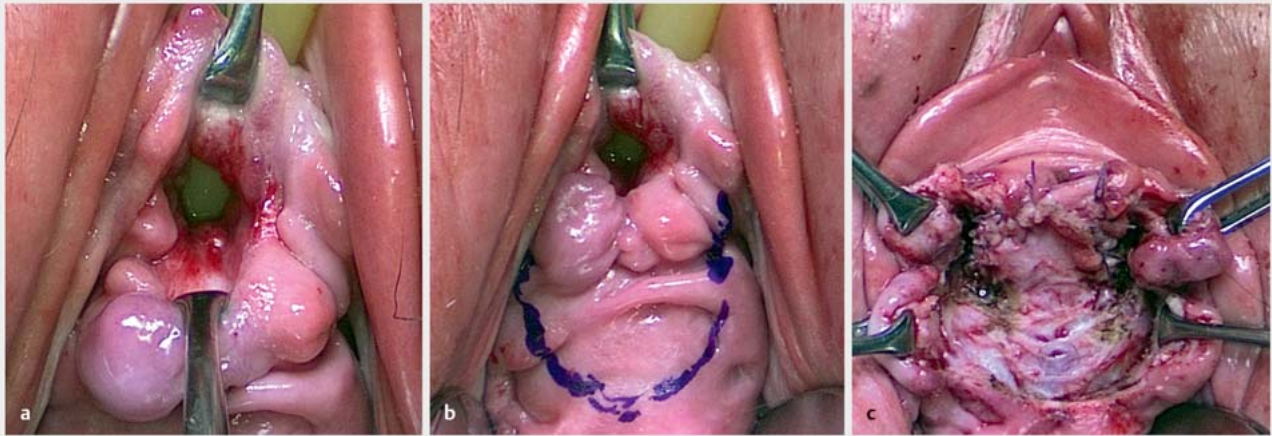


► **Fig. 4** Closure of the urethrovaginal fistula with Martius flap interposition of the labium majus: a Fat flap rotated from the vulvar to the vaginal wound area; the arrow points to the urethral suture, b the fat flap covers the urethral suture tension-free, c photo after suturing of the fat flap (of the Martius flap).

firmed at an outside facility. In our investigation, the primary surgeries for TVT/TOT placement occurred between 3 months and 15 years previously.

Risk factors for these generally multifactorially substantiated findings include, among others, scarring due to previous surgeries, genital infections, status post radiation, but also an inexperienced surgeon or unsuitable surgical technique [2]. A diagnostic urethroscopy therefore appears to be necessary not only in the case of persistent postoperative or repeat urinary incontinence, but rather it should be performed as an obligatory measure within the scope of the primary TVT/TOT placement to intraoperatively rule out an injury to the urethra or bladder [2]. In 10 of our 14 cases (71.4%), up to 3 revision surgeries were already performed at an outside facility due to bladder voiding dysfunc-

tion, tape erosions, pain, secondary haemorrhage, fistula or accidental transurethral band placement. A review of 38 case series and case reports did not demonstrate any significant difference between retropubic and transobturator sling placement with regard to the frequency of a urethral perforation or erosion [2]. Because of the individually highly variable findings with regard to manifestation and localisation and the patients who often underwent multiple previous surgeries, our data confirm the need for an individual approach. Various vaginal and abdominal surgical procedures are discussed in the literature, whereby vaginal procedures are prioritised. The vaginal interposition of a Martius flap as a defect coverage has proven itself here to be an efficient method with low morbidity [3, 8–13]. In our investigation, only urethral reconstruction using a double-row, tension-free rows of sim-



► **Fig. 5** Urethral reconstruction and fistula closure of the urethrovaginal fistula which is very near the ostium (a) with a vaginal tissue rotation flap (b). Urethral reconstruction with sutured vaginal tissue flap, the Allis clamps grasp the edges of the vaginal tissue which, in the end, are adapted over the vaginal tissue flaps sutured in the urethra (c).

ple interrupted sutures was performed in the case of smaller defects. All larger or multiple urethral defects or recurrent fistulas were successfully closed vaginally using interposition of a tissue flap in the sense of a pedicled fat flap of the labium majus as a Martius flap or as a vaginal tissue rotation flap.

Detailed information for patients about the surgical options as well as careful therapeutic planning and treatment in centres is necessary to prevent recurrences or long-term complications. In our collective, there was ongoing stress urinary incontinence postoperatively in 28.6% (n = 4) and mixed urinary incontinence in 21.4% (n = 3). After exhausting options for conservative treatment, 6 of these 7 patients with persistent incontinence underwent the new placement of a tension-free suburethral retropubic sling (TVT) an average of 8.8 months (5–13 months) postoperatively which was performed without complications in all patients and achieved satisfactory continence. Due to multiple previous surgeries and traumatic experiences in connection with the TVT placement, another patient refused repeat TVT placement despite significant stress urinary incontinence following successful closure of the urethrovesical fistula. Our data highlight the need for providing careful information and for interdisciplinary care of complex cases. The patients should be informed in particular about postoperative measures and postoperative behaviour, such as, for example, wearing a suprapubic bladder catheter for 3 weeks for better healing of the urethral suture and to safeguard the surgical result, but also about possible persistent or recurrent postoperative urinary incontinence and its therapy options, in order to achieve good satisfaction with compliance. Following urethral reconstruction or fistula closure, 50% of the patients of our collective were already continent without a need for further therapy and this therefore confirms a two-stage approach.

Conclusion

Our investigation shows that the rare but relevant complications of a urethral tape erosion, accidental transurethral tape placement or urethrovaginal fistula formation in status post TVT/TOT placement can be successfully managed via an individual vaginal surgical approach. A high degree of surgical expertise as well as the possibility for potentially interdisciplinary collaboration with urology is the precondition for a successful individual therapeutic concept. Persistent postoperative urinary incontinence must be preoperatively clarified. A two-phase repeat TVT placement is possible after sufficient wound healing and should be recommended.

Conflict of Interest

The authors declare that they have no conflict of interest.

References

- [1] Reisenauer C, Muche-Borowski C, Anthuber C et al. Interdisciplinary S2e Guideline for the Diagnosis and Treatment of Stress Urinary Incontinence in Women: Short version – AWMF Registry No. 015-005, July 2013. *Geburtsh Frauenheilk* 2013; 73: 899–903
- [2] Morton HC, Hilton P. Urethral injury associated with minimally invasive mid-urethral sling procedures for the treatment of stress urinary incontinence: a case series and systematic literature search. *BJOG* 2009; 116: 1120–1126
- [3] Goujon E, Jarniat A, Bardet F et al. Retrospective study on the management and follow-up of 18 patients with a mid-urethral sling penetrating the urethra or bladder. *J Gynecol Obstet Hum Reprod* 2018; 47: 289–297
- [4] Costantini E, Lazzeri M, Porena M. Managing complications after midurethral sling for stress urinary incontinence. *EAU-EBU Update Ser* 2007; 5: 232–240

- [5] Bader G, Koskas M. Complications of midurethral sling procedures for surgical treatment of female stress urinary incontinence. *J Gynecol Obstet Biol Reprod* 2009; 38 (Suppl.): S201–S211
- [6] Reisenauer C, Wallwiener D, Stenzl A et al. Urethrovaginal fistula—a rare complication after the placement of a suburethral sling (IVS). *Int Urogynecol J* 2007; 18: 343–346
- [7] Wallwiener D, Jonat W, Kreienberg R, Friese K, Diedrich K, Beckmann MW, Hrsg. *Atlas der gynäkologischen Operationen*. 7. Aufl. Stuttgart: Thieme; 2009
- [8] Amundsen CL, Flynn BJ, Webster GD. Urethral erosion after synthetic and nonsynthetic pubovaginal slings: differences in management and continence outcome. *J Urol* 2003; 170: 134–137; discussion 137
- [9] Zilberlicht A, Lavy Y, Auslender R et al. Transvaginal repair of a urethrovaginal fistula using the Latzko technique with a bulbocavernosus (Martius) flap. *Int Urogynecol J* 2016; 27: 1925–1927
- [10] Reisenauer C, Janowitz J, Wallwiener D et al. Urethrovaginal fistulae associated with tension-free vaginal tape procedures: a clinical challenge. *Int Urogynecol J* 2014; 25: 319–322
- [11] Reisenauer C. Vesicovaginal fistulas: a gynecological experience in 41 cases at a German pelvic floor center. *Arch Gynecol Obstet* 2015; 292: 245–253
- [12] Sokol ER, Urban R. Novel repair of tension-free midurethral sling erosion into the urethra. *J Minim Invasive Gynecol* 2008; 15: 755–757
- [13] Blaivas JG, Mekel G. Management of urinary fistulas due to midurethral sling surgery. *J Urol* 2014; 192: 1137–1142