

Quality of endoscopy reporting at index colonoscopy significantly impacts outcome of subsequent EMR in patients with > 20 mm colon polyps



Authors

Gottumukkala Raju¹, Phillip Lum¹, William Ross¹, Selvi Thirumurthi¹, Ethan Miller¹, Patrick Lynch¹, Jeffrey Lee¹, Manoop S. Bhutani¹, Mehnaz A. Shafi¹, Brian Weston¹, Boris Blechacz¹, George J Chang², Katherine Hagan³, Asif Rashid⁴, Marta Davila¹, John Strohlein¹

Institutions

- 1 Department of Gastroenterology, Hepatology and Nutrition, The University of Texas MD Anderson Cancer Center, Houston, Texas, United States
- 2 Department of Surgical Oncology, The University of Texas MD Anderson Cancer Center, Houston, Texas, United States
- 3 Department of Anesthesiology, The University of Texas MD Anderson Cancer Center, Houston, Texas, United States
- 4 Department of Pathology, The University of Texas MD Anderson Cancer Center, Houston, Texas, United States

submitted 30.4.2018

accepted after revision 9.8.2018

Bibliography

DOI <https://doi.org/10.1055/a-0746-3520> |
Endoscopy International Open 2019; 07: E361–E366
© Georg Thieme Verlag KG Stuttgart · New York
ISSN 2364-3722

Corresponding author

Gottumukkala Raju, The University of Texas MD Anderson Cancer Center, Gastroenterology, Hepatology and Nutrition, 1515 Holcombe Boulevard, GI Division – Unit 1466, Houston, TX 77030-4009, United States
Fax: +1-713-563-4408
gsraju@mdanderson.org

ABSTRACT

Background and study aims Endoscopic mucosal resection (EMR) is safe and cost-effective in management of patients with colon polyps. However, very little is known about the actions of the referring endoscopist following identification of these lesions at index colonoscopy, and the impact of those actions on the outcome of subsequent referral for EMR. The aim of this study was to identify practices at index colonoscopy that lead to failure of subsequent EMR.

Patients and methods Two hundred and eighty-nine consecutive patients with biopsy-proven non-malignant colon polyps (>20 mm) referred for EMR were analyzed to identify practices that could be improved from the time of identifying the lesion at index colonoscopy until completion of therapy.

Results EMR was abandoned at colonoscopy at the EMR center in 71 of 289 patients (24.6%). Reasons for abandoning EMR included diagnosis of invasive carcinoma (n=9; 12.7%), tethered lesions (n=21; 29.6%) from prior endoscopic interventions, and overly large (n=22; 31%) and inaccessible lesions (n=17; 24%) for complete and safe resection whose details were not recorded in the referring endoscopy report, or polyposis syndromes (n=2; 2.8%) that were not recognized.

Conclusions In our practice, one in four EMR attempts were abandoned as a result of inadequate diagnosis or management by the referring endoscopist, which could be improved by education on optical diagnosis of polyps, comprehensive documentation of the procedure and avoidance of interventions that preclude resection.

Introduction

Despite the benefits of colon polyp endoscopic mucosal resection (EMR), patients with large polyps continue to be referred for surgery instead of EMR [1–3]. In a recent meta-analysis, 8% of patients referred for EMR required surgery [4]. In contrast, in our center, 25% of patients with complex colon polyps

referred for EMR required surgery [5]. Possible explanations could be due to variation in practice at index colonoscopy in different settings. However, very little is known about the practice patterns of colonoscopists after detection of a large colon polyp. We decided to identify practices at index colonoscopy that lead to failure of subsequent EMR of patients with large (>2 cm) colon polyps in our center.

Patients and methods

Patients

Data on consecutive patients with biopsy-proven large benign polyps (≥ 20 mm) by the endoscopist referred for EMR at The University of Texas MD Anderson Cancer Center from 2009 to 2017 were analyzed retrospectively. All the patients were seen in the clinic for evaluation and counseling prior to EMR. The MD Anderson Institutional Review Board approved the study.

Procedures

Clinic visits

Prior to the clinic visits, an endoscopist reviewed the patients' endoscopy reports along with color photographs of the colon polyps and pathology reports and made decisions about whether the polyps could potentially be resected. In some cases, when the endoscopist was unclear about the anticipated success of resection, endoscopy was performed to directly assess the potential for EMR based on the patient's expressed desire to proceed. All patients underwent evaluation and counseling regarding EMR for approximately 1 hour in the clinic using figures and YouTube videos (<https://www.youtube.com/user/GottumukkalaSRaju>).

Endoscopic resection

All patients underwent EMR under a standardized protocol performed by a single endoscopist [5]. EMR was undertaken if the procedure could achieve complete and clean resection of the lesion and manage complications without the need for emergency surgery. Ease of moving around and accessing the lesion from different angles as well as endoscope stability were taken into consideration in making a decision before undertaking EMR.

EMR was not undertaken if: 1) optical diagnosis suggested obvious deep submucosal cancer; 2) a lesion could not be resected completely due to anatomic location (lesions extending into the appendix or engulfing the entire ileocecal valve and extending into terminal ileum); 3) a lesion could not be cut completely and safely due to inability to access the entire lesion easily (especially when the lesion is extensive); or 4) extensive tethering of the lesion was present, which failed to lift after submucosal injection for complete resection.

Outcome measures

Abandoned EMR

EMRs were abandoned if the lesion could not be resected completely and safely. Reasons for abandoning EMR fell into two groups: 1) Information from prior endoscopy was not complete (obvious cancer in the polyp overlooked, access to the lesion and extent of lesion were not documented completely) – “incomplete assessment of the polyp group”; and 2) extensive biopsies, snare resection, argon plasma coagulation of the lesion and tattoo of the lesion caused tethering and precluded resection – “inadvertent intervention of the polyp group”.

Successful EMR

Success of EMR was defined as complete resection of a colon polyp with no evident residual polyp at the end of session in all patients referred for EMR.

Follow-up

Except for a few patients, all were discharged from the endoscopy center after their recovery from the procedure. Patients were instructed to send an email message to the endoscopist daily for the first 5 days to report any complications. The endoscopist contacted the patient between Day 5 and Day 7 to report the pathology results. Serious adverse events (AEs) were defined as those that required hospitalization, transfusion, repeat endoscopic intervention, or surgery.

Data collection and analysis

All patient data were collected from electronic medical records and endoscopy reports using a natural language processing tool developed in our institution [6]. Variables collected included patient age, sex, race, and body mass index; EMR details; AEs; colon polyp morphology, pathology, and recurrence; and referral for surgery. Data were collected using a detailed, structured field format in an endoscopic reporting system (EndoWorks; Olympus, Center Valley, Pennsylvania, United States; ProVation Medical, Minneapolis, Minnesota, United States). Detailed photographic documentation of each EMR was performed, consisting of 20 to 30 photographs per resection. In addition, videos of all large EMRs ($n = 120$) were uploaded to the EMR Channel at YouTube (<https://www.youtube.com/playlist?list=PL43D6FC92ECCD341E>) to help with education. Surveillance endoscopy was performed at 6 and 18 months to check for local recurrence of polyp.

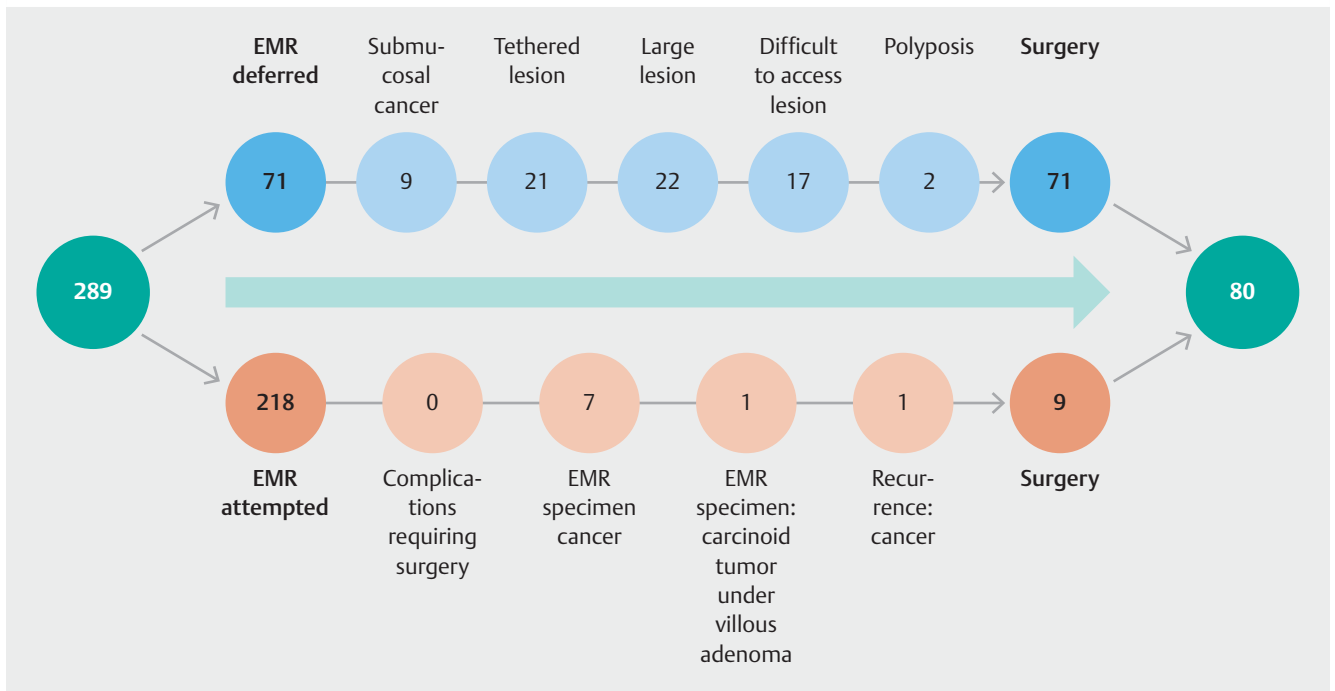
Results

Patient demographics

Two hundred eighty-nine consecutive patients with colon polyps ≥ 20 mm who underwent colonoscopy at our center constituted the study group. Among these patients, 23 (8%) self-referred for EMR after their endoscopists and surgeons only offered surgical resection and did not present EMR as a management option. Mean age of the patients was 63.8 years (range, 30.0–90.1 years), with an equal distribution of men ($n = 143$) and women ($n = 146$). The majority of patients were white ($n = 227$; 78.6%) and either overweight or obese ($n = 206$; 71.3%). The polyps were mostly located proximal to the splenic flexure (244; 84.4%); right colon ($n = 209$; 72.3%) or transverse colon ($n = 35$; 12.1%). Most of the polyps were nonpolypoid in morphology ($n = 225$; 78%). One hundred one patients were taking aspirin, 18 were taking clopidogrel, and 51 were taking other blood thinners (warfarin 8; heparin 16; newer oral anti coagulants 27).

Outcome of patients referred for EMR

EMR was abandoned in 71 patients (24.6%). In the remaining 218 patients (75%), EMR was successful (► **Fig. 1**). We observed two reasons for the 71 EMR deferrals. Incomplete initial assess-



► **Fig. 1** Outcomes of the 289 study patients with large colon polyps referred to our institution for EMR.

ment of the polyp accounted for abandoned resection in 50 patients (17%). In some cases, a large lesion extended over three colon folds or occupied greater than three quarters of the circumference of the colon ($n=22$; 7.6%). Except for describing that the polyp was large in the endoscopy report at index colonoscopy, there was no detailed description of the extent of involvement in terms of the longitudinal (number of folds involved) or circumferential (1/3, 1/2, or 3/4 circumference involvement) in the reports. In addition, one or two pictures were taken to document the lesion and those pictures did not provide any detailed depiction of the extent of polyp. In other cases, a lesion was difficult to access for safe and complete resection ($n=17$; 5.9%). None of the referring colonoscopy reports described that the lesion was difficult to access the lesion for complete and safe resection. Except for noting the size and morphology of the lesion (large and sessile or flat), there was no mention on the technical challenges (such as the type of endoscope used, application of external pressure, stability of the endoscope in front of the lesion, and ability to bring the lesion to lower half of the visual field) involved in accessing the lesion.

A small number of cases involved obvious cancer (prior random biopsies by the referring endoscopist were negative for cancer, but targeted biopsies done at the EMR center were positive; $n=9$; 3.1%). All these patients were referred as “benign lesions” and the patients were told that the lesions were benign prior to referral to the EMR center.

Initial assessment of the polyp was incomplete in two cases because of polyposis syndrome (0.7%). In one patient, underlying polyposis syndrome was not recognized by the referring endoscopist. In the second patient, the serrated polyposis syn-

drome was recognized, but the polyps were too many and too large for successful endoscopic clearance.

In 7% of patients (21) with EMR that was deferred, it was secondary to initial inadvertent endoscopic management which resulted in extensive polyp tethering from multiple biopsies with or without tattoo into the lesion ($n=3$; 1%) and to snare resection with or without tattoo into the lesion in 18 patients (6.2%).

EMR was successful in 218 of 289 patients (75%). Sixty-six patients underwent en bloc resection, whereas 152 underwent piecemeal resection. EMR was also successful in 14 of the 23 self-referred patients. Average resection time was 65.6 minutes (range, 17–178 minutes).

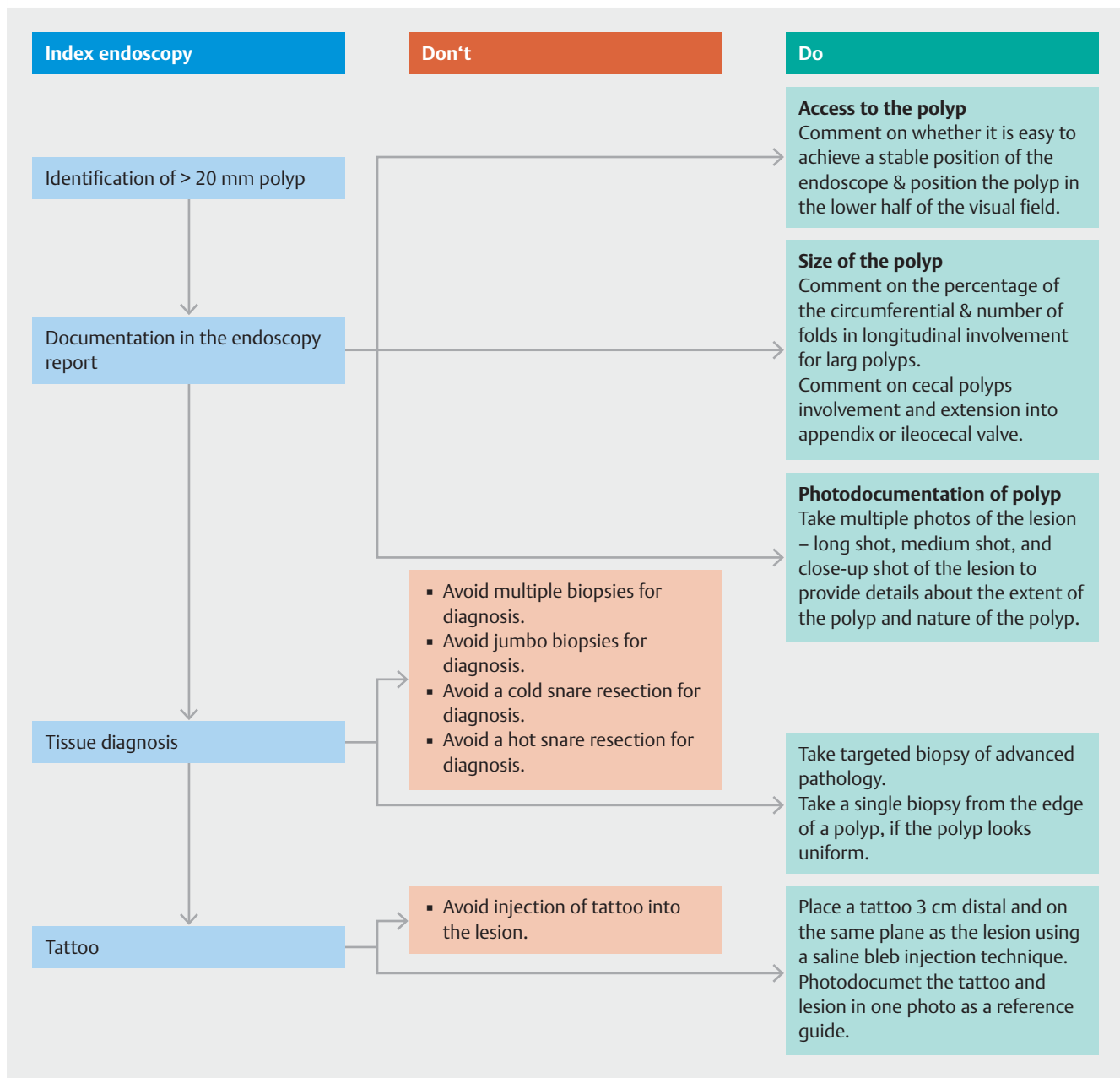
Pathology of resected polyp specimens

Pathological analysis of the 218 successfully resected polyps revealed benign polyps in 208 patients and cancer in 10 patients.

Serious adverse colonoscopy-related events requiring hospitalization after discharge occurred in 11 patients (4%; rectal bleeding in 10 patients and fever in 1 patient). None of the patients required surgery or died of these complications.

Discussion

EMR is effective in management of patients with large and complex benign polyps [7–13]. However, in our practice, one in four patients referred for EMR had EMR abandoned as a result of inadequate diagnosis or management by the referring endoscopist. Opportunities to improve the quality of care for these patients include improved optical diagnosis education for referring endoscopists on differentiation between adeno-



► **Fig. 2** Suggested do's and don'ts at index colonoscopy prior to referral to an EMR center.

mas and adenocarcinoma, creating a template for clear written and photographic documentation of the colonoscopy procedure and polyp for the referral EMR center, and instruction on how to avoid interventions that preclude endoscopic resection such as extensive biopsy of the lesion, snare resection of part of the lesion or injection of carbon particle tattoo too close to the lesion.

Surgery instead of EMR is indicated in patients with deep submucosal colon cancer. Therefore, avoiding referral of patients with deep submucosal cancer for EMR is important to save cost and avoid inconvenience to the patient. In our study, nine patients diagnosed with benign-appearing polyps by the referring endoscopist had obvious features of cancer, and tar-

geted biopsies confirmed them as such; these patients were referred for surgery without EMR. Friedland et al. reported a similar experience [14]. Learning to recognize endoscopic predictors of deep (> 1 mm) submucosal invasion of flat and sessile lesions as described according to type 3 of the Narrow-Band Imaging International Colorectal Endoscopic classification will help diagnose invasive cancer in patients with colon polyps [15, 16]. Such patients must be referred directly for surgery instead of EMR. When in doubt, the physician can record a video of the polyp for cross-consultation before referring a patient to an EMR center [17].

Clear documentation of polyp location and extent (for example, the polyp involves half the circumference of the cecum and

extends from the ileocecal valve to the appendicular orifice, with involvement of both structures) instead of describing it as a “large cecal polyp” would be helpful. In addition, multiple photographs that could be combined to provide a panoramic view of the polyp (instead of just one or two photographs) may have been useful to convince the patient about the need for surgery for an extensive polyp instead of repeat colonoscopies in 22 patients. Whether the practice of inadequate documentation of colonoscopy findings results from production pressures or a true lack of knowledge about the importance of clear documentation for consultation with an EMR center is unclear [18]. It leads to waste of resources that could have been avoided by performing extensive photographic as well written documentation of polyps [19, 20].

EMR was abandoned in 21 patients with benign polyps owing to extensive polyp tethering [21]. Although novel techniques such as two-stage resection, endoscopic submucosal dissection (ESD), underwater EMR, and full-thickness colon resection may serve as options for managing patients with polyps tethered to the colon wall, submucosal fibrosis increases complications and failure rate [22–30]. In our own practice, we are able to remove polyps that have limited tethering to the underlying wall using a combination of underwater EMR and hot biopsy avulsion, but could not remove polyps with extensive and deep tethering. Although the adverse impact on EMR success of extensive, deep biopsies, partial snare resections, and tattooing into or at the margin of the polyp is established, endoscopists continue to perform these interventions to the detriment of their patients [29–31]. We have observed that informal feedback to the referring endoscopists about the impact of such interventions on EMR has lessened this problem and noted a decrease in use of such interventions; some of the endoscopists are referring patients without taking biopsies from the lesion, after detailed photographic documentation of the lesion, which has made resection of such polyps much easier than those that were tethered to the wall from prior interventions. Despite some improvements, the problem of inadvertent interventions continues in the general endoscopy community. To mitigate this problem, we developed a care pathway for endoscopists to consider when managing patients with large polyps (► Fig. 2) Video conferencing consultation between the referring center and EMR center to decide the best management for large polyps offers an opportunity to improve care of these patients [31].

In addition to inadequate documentation and inadvertent interventions by the referring endoscopist, our study identified that patients with large polyps are not given the option of colon EMR as an option [14]. Eight percent of patients in our study self-referred for EMR after seeing surgeons and then performing web searches for alternatives to surgery (“Removing a Large Flat Colon Polyp by EMR without Surgery” by Jim Sease – <http://www.sease.com/polyp/emr.html>); the majority of these patients avoided surgery. Education of physicians, the public, and payers about colon EMR as an alternative to surgery may avoid unnecessary surgeries and save money.

Although our study was limited in that it was single-center and retrospective, it offers an opportunity to initiate proce-

dures and practices that could be incorporated into every community practice when large colon polyps are found to improve quality of care for such patients (► Fig. 2). Our study also raises several important questions that require further study. Why do the referring endoscopists fail to provide optimal management of large polyps? Is it because they are unaware of the limits of EMR? Or because they do not know which information is needed by the EMR center? Or do they assume that the EMR center will perform an independent colonoscopy? Furthermore, it would be interesting to investigate if poor documentation correlates with the experience of the referring endoscopist.

Conclusion

In summary, the majority of patients with colon polyps larger than 20 mm can be managed using EMR instead of surgery. Education on recognition of cancerous polyps, detailed documentation of and access to lesions, and avoidance of interventions that preclude resection will improve quality of care for patients with large polyps.

Acknowledgements

We are grateful to our colleagues in anesthesia, pathology, and colorectal surgery departments, our endoscopy colleagues in the community, and our endoscopy center and clinic staff for their support. We thank Donald Norwood, Department of Scientific Publications for reviewing and editing the manuscript.

Competing interests

None

References

- [1] Lee TJW, Rees CJ, Nickerson C et al. Management of complex colonic polyps in the English Bowel Cancer Screening Programme. *Br J Surg* 2013; 100: 1633–1639
- [2] Le Roy F, Manfredi S, Hamonic S et al. Frequency of and risk factors for the surgical resection of nonmalignant colorectal polyps: a population-based study. *Endoscopy* 2016; 48: 263–270
- [3] van Nimwegen LJ, Moons LMG, Geesing JMJ et al. Extent of unnecessary surgery for benign rectal polyps in the Netherlands. *Gastrointest Endosc* 2018; 87: 562–570.e1
- [4] Hassan C, Repici A, Sharma P et al. Efficacy and safety of endoscopic resection of large colorectal polyps: a systematic review and meta-analysis. *Gut* 2016; 65: 806–820
- [5] Raju GS, Lum PJ, Ross WA et al. Outcome of EMR as an alternative to surgery in patients with complex colon polyps. *Gastrointest Endosc* 2016; 84: 315–325
- [6] Raju GS, Lum PJ, Slack RS et al. Natural language processing as an alternative to manual reporting of colonoscopy quality metrics. *Gastrointest Endosc* 2015; 82: 512–519
- [7] Arebi N, Swain D, Suzuki N et al. Endoscopic mucosal resection of 161 cases of large sessile or flat colorectal polyps. *Scand J Gastroenterol* 2007; 42: 859–866

- [8] Moss A, Bourke MJ, Metz AJ. A randomized, double-blind trial of succinylated gelatin submucosal injection for endoscopic resection of large sessile polyps of the colon. *Am J Gastroenterol* 2010; 105: 2375–2382
- [9] Ah Soune P, Ménard C, Salah E et al. Large endoscopic mucosal resection for colorectal tumors exceeding 4 cm. *World J Gastroenterol* 2010; 16: 588–595
- [10] Buchner AM, Guarner-Argente C, Ginsberg GG. Outcomes of EMR of defiant colorectal lesions directed to an endoscopy referral center. *Gastrointest Endosc* 2012; 76: 255–263
- [11] Dior M, Coriat R, Tarabichi S et al. Does endoscopic mucosal resection for large colorectal polyps allow ambulatory management? *Surg Endosc* 2013; 27: 2775–2781
- [12] Gómez V, Racho RG, Woodward TA et al. Colonic endoscopic mucosal resection of large polyps: Is it safe in the very elderly? *Dig Liver Dis* 2014; 46: 701–705
- [13] Longcroft-Wheaton G, Mead R et al. Endoscopic mucosal resection of colonic polyps: a large prospective single centre series. *Gut* 2011; 60: A14–A15
- [14] Friedland S, Banerjee S, Kochar R et al. Outcomes of repeat colonoscopy in patients with polyps referred for surgery without biopsy-proven cancer. *Gastrointest Endosc* 2014; 79: 101–107
- [15] Hayashi N, Tanaka S, Hewett DG et al. Endoscopic prediction of deep submucosal invasive carcinoma: validation of the narrow-band imaging international colorectal endoscopic (NICE) classification. *Gastrointest Endosc* 2013; 78: 625–632
- [16] Zhang Q-W, Teng L-M, Zhang X-T et al. Narrow-band imaging in the diagnosis of deep submucosal colorectal cancers: a systematic review and meta-analysis. *Endoscopy* 2017; 49: 564–580
- [17] Daram SR, Tang S-J, Raju GS. A primer on endoscopic movie production (with videos). *Gastrointest Endosc* 2012; 75: 161–164
- [18] Whitson MJ, Bodian CA, Aisenberg J et al. Is production pressure jeopardizing the quality of colonoscopy? A survey of U.S. endoscopists' practices and perceptions *Gastrointest Endosc* 2012; 75: 641–648
- [19] Tang S-J, Raju G. Endoscopic photography and image documentation. *Gastrointest Endosc* 2015; 82: 925–931
- [20] Roorda AK, Triadafilopoulos G. A fellow's guide to generating the endoscopy procedure report. *Gastrointest Endosc* 2010; 72: 803–805
- [21] Moss A, Bourke MJ, Pathmanathan N. Safety of colonic tattoo with sterile carbon particle suspension: a proposed guideline with illustrative cases. *Gastrointest Endosc* 2011; 74: 214–218
- [22] Lin AY, O'Mahoney PRA, Milsom JW et al. Dynamic article: full-thickness excision for benign colon polyps using combined endoscopic laparoscopic surgery. *Dis Colon Rectum* 2016; 59: 16–21
- [23] Veerappan SG, Ormonde D, Yusoff IF et al. Hot avulsion: a modification of an existing technique for management of nonlifting areas of a polyp (with video). *Gastrointest Endosc* 2014; 80: 884–888
- [24] Backes Y, Kappelle WFW, Berk L et al. T1 CRC Working Group. Colorectal endoscopic full-thickness resection using a novel, flat-base over-the-scope clip: a prospective study. *Endoscopy* 2017; 49: 1092–1097
- [25] Kuwai T, Yamaguchi T, Imagawa H et al. Endoscopic submucosal dissection of early colorectal neoplasms with a monopolar scissor-type knife: short- to long-term outcomes. *Endoscopy* 2017; 49: 913–918
- [26] Tate DJ, Desomer L, Hourigan LF et al. Two-stage endoscopic mucosal resection is a safe and effective salvage therapy after a failed single-session approach. *Endoscopy* 2017; 49: 888–898
- [27] Hosotani K, Imai K, Hotta K et al. Underwater endoscopic mucosal resection for complete R0 removal of a residual adenoma at a perforated scar in a patient with colostomy. *Endoscopy* 2017; 49: E121–E122
- [28] Javia S, Dedania B, Wang X et al. Endoscopic full-thickness resection of a non-lifting large laterally spreading flat colonic polyp. *Endoscopy* 2017; 49: E171–E172
- [29] Agrawal D, Chak A, Champagne BJ et al. Endoscopic mucosal resection with full-thickness closure for difficult polyps: a prospective clinical trial. *Gastrointest Endosc* 2010; 71: 1082–1088
- [30] Meier B, Caca K, Schmidt A. Hybrid endoscopic mucosal resection and full-thickness resection: a new approach for resection of large non-lifting colorectal adenomas (with video). *Surg Endosc* 2017; 31: 4268–4274
- [31] Kandiah K, Subramaniam S, Bhandari P. Polypectomy and advanced endoscopic resection. *Frontline Gastroenterol* 2017; 8: 110–114