

Carney Complex

Authors

Crystal D. C. Kamilaris¹, Fabio Rueda Faucz¹, Antonis Voutetakis², Constantine A. Stratakis¹

Affiliations

- 1 Section on Endocrinology and Genetics & Endocrinology Inter-institute Training Program, Eunice Kennedy Shriver National Institute of Child Health & Human Development (NICHD), National Institutes of Health (NIH), Bethesda, MD, USA
- 2 Division of Endocrinology, Metabolism and Diabetes, 1st Department of Pediatrics, Medical School, National and Kapodistrian University of Athens, Athens, Greece

Key words

Carney complex, *PRKAR1A*, primary pigmented nodular adrenocortical disease, myxomas, acromegaly, lentiginosis

received 17.05.2018

revised 06.09.2018

accepted 02.10.2018

Bibliography

DOI <https://doi.org/10.1055/a-0753-4943>

Published online: 14.11.2018

Exp Clin Endocrinol Diabetes 2019; 127: 156–164

© J. A. Barth Verlag in Georg Thieme Verlag KG Stuttgart ·

New York

ISSN 0947-7349

Correspondence

Dr. Constantine A. Stratakis,

10 Center Drive

Building 10

NIH-Clinical Research Center

Room 1-3330

MSC1103

20892-1862 Bethesda MD

USA

Tel.: + 1/301/496 4686, Fax: + 1/301/4020 574

stratak@mail.nih.gov

ABSTRACT

Carney complex is a rare, autosomal dominant, multiple endocrine neoplasia and lentiginosis syndrome, caused in most patients by defects in the *PRKAR1A* gene, which encodes the regulatory subunit type 1 α of protein kinase A. Inactivating defects of *PRKAR1A* lead to aberrant cyclic-AMP-protein kinase A signaling. Patients may develop multiple skin abnormalities and a variety of endocrine and non-endocrine tumors. Endocrine manifestations include primary pigmented nodular adrenocortical disease, that may cause Cushing syndrome, growth-hormone secreting pituitary adenoma or pituitary somatotrophic hyperplasia which can result in acromegaly, as well as gonadal and thyroid tumors. Non-endocrine tumors associated with Carney complex include myxomas of the heart, breast, and other sites, psammomatous melanotic schwannomas, breast ductal adenomas, osteochondromyxomas, and a predisposition to a number of malignancies from adrenal to pancreatic and liver cancer.

Introduction

Carney complex (CNC) is a rare, multiple endocrine neoplasia and lentiginosis syndrome, characterized by abnormal cutaneous and mucosal pigmentation, myxomas predominantly of the heart, skin, and breast, endocrine neoplasms, psammomatous melanotic schwannomas (PMS), breast ductal adenomas, osteochondromyxomas, and other non-endocrine tumors. Endocrine tumors include

primary pigmented nodular adrenocortical disease (PPNAD), pituitary adenomas, thyroid tumors, testicular tumors, and ovarian lesions [1]. CNC is familial in 70% of cases, with autosomal dominant inheritance. With respect to the underlying molecular defect, germline inactivating mutations in the *PRKAR1A* gene, situated at the 17q24.2–24.3 locus (CNC1 locus) of the long arm of chromosome 17, are found in 37% of patients with sporadic CNC and more

than 70 % of patients with familial CNC, with almost 100 % penetrance [2–4]. This gene encodes the regulatory subunit type 1 α (R1 α) of protein kinase A (PKA). In most of the remaining cases of CNC, genetic linkage analysis of tumors has revealed a second affected locus on chromosome 2p16 (CNC2 locus) [5, 6]. Nevertheless, the responsible gene at this locus has not yet been identified. Lastly, *PRKACB* gene locus copy number gains on chromosome 1 were found in a single patient with CNC that presented with abnormal skin pigmentation, myxomas, and acromegaly [7].

The “complex of myxomas, spotty pigmentation, and endocrine overactivity” was first described by Dr. J. Aidan Carney in 1985, and designated as CNC in 1986 [8, 9]. Most patients who had been diagnosed with LAMB (lentiginos, atrial myxoma, mucocutaneous myxoma, blue nevi) or NAME (nevi, atrial myxoma, myxoid neurofibroma, ephelide) are now more appropriately classified as CNC [10, 11]. More than 750 cases of CNC have been reported by the National Institutes of Health (NIH) – Mayo Clinic (United States), Cornell (United States), and the Cochin Hospital (France), including patients of different races and from all continents [12]. In the largest cohort of patients that has been genotyped (353 patients), 63 % of patients were females and 37 % were males [3].

Genetics and Molecular Pathogenesis

CNC is a clinically and molecularly heterogeneous disorder. As mentioned previously, genetic linkage analysis has revealed 2 distinct loci for CNC, the CNC1 locus on chromosome 17q22–24 which harbors the *PRKAR1A* gene that encodes the R1 α subunit of PKA, and the CNC2 locus on chromosome 2p16 [2, 3, 6]. PKA is a ubiquitous cyclic AMP (cAMP)-dependent serine-threonine kinase, that is involved in the regulation of a wide range of cellular processes including transcription, metabolism, cell cycle progression, and apoptosis. PKA is a heterotetramer comprised of 2 regulatory and 2 catalytic subunits. Four isoforms exist for both the regulatory subunits (R1 α , R1 β , R2 α , and R2 β) and catalytic subunits (C α , C β , C γ , and PRKX) of PKA, with each isoform having individual localization and specificity [13]. The PKA signaling system includes targeting proteins that localize PKA to specific sites in the cell, in close proximity to specific substrates. The ultimate result of PKA signaling is determined by the cell type specific expression of the different PKA regulatory and catalytic isoforms and/or splice variants, the different PKA substrates, and the subcellular localization of PKA. The cAMP-PKA pathway is activated by the binding of a ligand to a G-protein coupled receptor (GPCR). This leads to activation of adenylyl cyclase and synthesis of cAMP which activates PKA. Once cAMP binds to the regulatory subunits of PKA, the catalytic subunits dissociate from the regulatory subunits and are then able to phosphorylate downstream cytoplasmic and nuclear targets (► **Fig. 1**). CNC was the first disorder associated with mutations in the PKA enzyme. Inactivating mutations of *PRKAR1A* lead to constitutive activation of the cAMP-PKA pathway through loss of regulation of the catalytic subunits of PKA. The effect of increased PKA activity on mitosis and cell proliferation varies according to cell type. The binding of ligands such as FSH, ACTH, TSH, GHRH, and MSH to their respective GPCRs, on the cell membranes of Sertoli cells, adrenocortical cells, thyrocytes, somatotrophs, and melanocytes, respectively, leads to a mi-

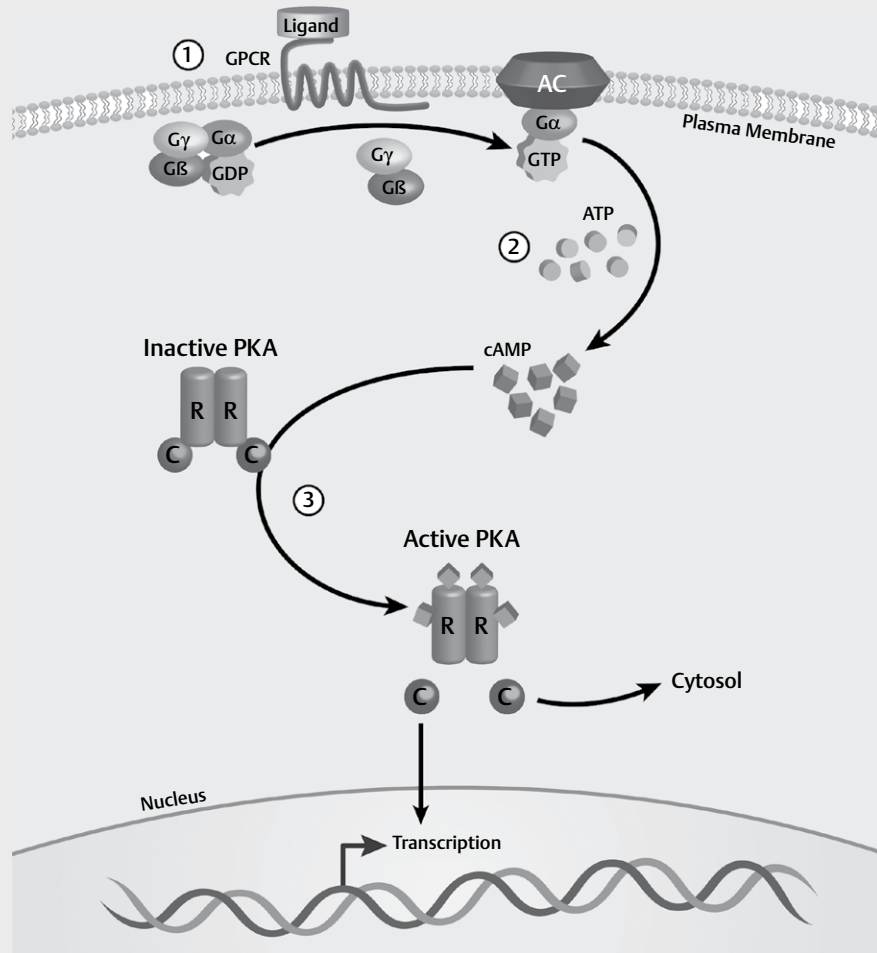
togenic response, which correlates with the increased cell proliferation observed in these specific cell types in CNC [14].

More than 140 *PRKAR1A* molecular defects have been reported in patients with CNC (<http://prkar1a.nichd.nih.gov/hmdb/intro.html>). These defects include single base substitutions and small (≤ 15 bp) deletions, insertions, or combined rearrangements as well as several relatively large deletions [3, 15, 16]. Only 3 pathogenic *PRKAR1A* variants have been identified in more than three unrelated pedigrees pointing to “hot spots” for *PRKAR1A* sequence changes: c.82 C > T, c.491_492delTG, and c.709–2_709–7 delATTTT [1, 17]. Approximately 80 % of pathogenic *PRKAR1A* variants are subject to mRNA nonsense-mediated decay (NMD) of the mutant sequence, leading to predicted absence of mutant protein products in affected cells. This results in *PRKAR1A* haploinsufficiency. The remaining 20 % of mutations escape NMD, and can potentially lead to the expression of an alternative protein [3, 18]. Patients with this type of mutation have been noted to have a more aggressive form of the disease with a higher total number of CNC manifestations. Some *PRKAR1A* mutations do not lead to NMD but lead to an elongated protein that is subject to proteosomal degradation resulting again in *PRKAR1A* haploinsufficiency [19]. Initial data supported that *PRKAR1A* functions as a “classic” tumor-suppressor gene, with tumors from CNC patients exhibiting germline mutations and subsequent loss of heterozygosity (LOH) at the *PRKAR1A* locus. However, more recent data has demonstrated that haploinsufficiency of *PRKAR1A* may be sufficient for increased PKA activity and development of certain tumors, such as eyelid myxomas [20, 21].

Certain genotype-phenotype correlations have been noted in patients with CNC. Patients with a *PRKAR1A* mutation are more likely to have pigmented skin lesions, myxomas, PMS, and thyroid and gonadal tumors, with cardiac myxomas, thyroid tumors, and large cell calcifying Sertoli cell tumors (LCCSCT) presenting at a younger age than non-*PRKAR1A* mutation carriers [3]. Patients harboring mutations located in exons develop acromegaly, myxomas, lentiginos, and PMS more frequently. The c.491–492delTG mutation is more often associated with lentiginos, cardiac myxomas, and thyroid tumors when compared to all other *PRKAR1A* defects.

Diagnosis and Clinical Characteristics

Manifestations of CNC develop over years, with peak penetrance in young adulthood. In a cohort of 235 patients the median age at diagnosis was 20 years. The diagnosis of CNC was made at birth in 5 patients showing that presentation as early as in neonates is possible [1]. Abnormal skin pigmentation may be present at birth, though lentiginos do not reach their characteristic distribution, number, or intensity until the peripubertal period. Lentiginos tend to fade after the fourth decade, though some may persist even in the eighth decade. Depigmented lesions and other pigmented lesions such as blue nevi or café-au-lait spots, may also be present at birth but most typically develop in early childhood. The most common tumors in infancy are cardiac and cutaneous myxomas; PPNAD tends to appear after the age of 5 years, whereas LCCSCT and thyroid nodules form around the time of puberty. Cardiac myxomas are distributed evenly among the different ages. PPNAD can manifest as early as the first 5 years of life, but more frequently presents in



► **Fig. 1** The protein kinase A pathway: 1) Ligand binds to G-protein coupled receptor (GPCR) on the plasma membrane. This catalyzes exchange of GTP for GDP on the α subunit of the associated heterotrimeric G protein, with dissociation of the α subunit from the $\beta\gamma$ dimer; 2) The α subunit binds to adenylyl cyclase (AC) and activates its enzymatic activity. Activated AC produces cyclic AMP (cAMP) from ATP; 3) cAMP binds to the regulatory subunits (R) of protein kinase A (PKA) which allows for release of the catalytic subunits (C) of PKA, that then mediate serine-threonine phosphorylation of target molecules, including the transcription factor CREB (cAMP response element-binding protein).

the second and third decades of life. Acromegaly is seen in the third and fourth decades of life, and gigantism is rare. The average life expectancy for individuals with CNC is 50 years [22]. However, this calculation is skewed due to early death in some patients, while most patients with CNC have a normal lifespan, especially if they are involved in active surveillance. The most common causes of death in patients with CNC include complications of cardiac myxomas (myxoma emboli, cardiomyopathy, cardiac arrhythmia, and surgical intervention), metastatic or intracranial PMS, thyroid carcinoma, and metastatic pancreatic and testicular tumors [1].

The diagnosis of CNC requires the presence of 2 major manifestations or criteria, verified by histological evaluation, biochemical testing, or imaging (► **Table 1**). A patient may also meet the diagnostic criteria for CNC when one major manifestation or criterion is present and they have either an inactivating mutation of the *PRKAR1A* gene or an affected first degree relative [1]. Molecular testing for *PRKAR1A* mutations is not currently recommended for all patients with CNC but may be used to detect affected family

members in families with known mutations to avoid unnecessary medical surveillance of non-carriers.

Endocrine Manifestations

Adrenocortical tumors

PPNAD is the most common endocrine manifestation in CNC, and is detected in 25–60% of patients [1, 12]. In about half of the patients with CNC, PPNAD causes ACTH-independent Cushing syndrome (CS). CS in these patients can be overt, cyclical, atypical, or subclinical. PPNAD is characterized by normal-sized or enlarged adrenal glands with bilateral adrenocortical nodules that are pigmented, less than 1 centimeter in diameter, and surrounded by atrophic adrenocortical tissue [23]. Evidence of PPNAD has been found on histologic examination in almost all patients with CNC that underwent autopsy. PPNAD is the only manifestation of CNC with a gender predilection, occurring more commonly and earlier

► **Table 1** Diagnostic criteria for Carney complex*

Main Criteria
Spotty skin pigmentation with a typical distribution (lips, conjunctiva and inner or outer canthi, vaginal and penile mucosa)
Myxoma (cutaneous and mucosal)**
Cardiac myxoma**
Breast myxomatosis** or fat-suppressed magnetic resonance imaging findings suggestive of this diagnosis
PPNAD** or paradoxical positive response of urinary glucocorticosteroids to dexamethasone administration during 6-day modified Liddle test
Acromegaly due to GH-producing adenoma**
LCCSCT** or characteristic calcification on testicular ultrasonography
Thyroid carcinoma** or multiple, hypoechoic nodules on thyroid ultrasonography
Psammomatous melanotic schwannoma**
Blue nevus, epithelioid blue nevus (multiple)**
Breast ductal adenoma (multiple)
Osteochondromyxoma of bone**
Supplemental criteria
Affected 1 st -degree relative
Inactivating mutation of the <i>PRKAR1A</i> gene
*To make a diagnosis of Carney complex, a patient must either: 1) exhibit 2 of the manifestations of the disease listed above, or 2) exhibit one of these manifestations and meet one of the supplemental criteria (an affected first-degree relative or an inactivating mutation of the <i>PRKAR1A</i> gene); **with histologic confirmation

in women, with 71 % of patients being female, with a median age at diagnosis of 30 years, compared to 46 years in men [3]. This gender difference is evident after puberty. More than 80 % of patients with CNC and PPNAD have germline inactivating mutations in *PRKAR1A* [2–4]. Other genetic modifying factors may play a role in the development of PPNAD in patients with CNC, most notably defects in the gene that encodes phosphodiesterase 11 A (*PDE11A*) which also plays a role in the PKA pathway. In a series of 150 patients with CNC and *PRKAR1A* mutations, those with PPNAD and/or LCCSCT were more frequently carriers of *PDE11A* variants [24]. PPNAD has also been described as an isolated manifestation. However, patients with isolated PPNAD diagnosed younger than 8 years of age are rarely *PRKAR1A* mutation carriers.

Urinary free cortisol, diurnal cortisol, or the overnight 1 milligram dexamethasone test can be used to detect hypercortisolemia in patients with CNC. Cortisol hypersecretion in patients with PPNAD, even those with cyclical, atypical, or subclinical disease, may be detected by a dexamethasone-stimulation test or 6-day modified Liddle test. During this test patients with PPNAD will show a paradoxical increase of more than 50 % in 24-hour urinary free cortisol on the second day of high-dose dexamethasone administration [25]. This response to dexamethasone is attributed to the paradoxical stimulation of cortisol release in PPNAD tissue by dexamethasone, that is induced by increased glucocorticoid receptor expression and glucocorticoid receptor-mediated effects on the PKA catalytic subunits [26, 27]. In patients with PPNAD, imaging with computed tomography (CT) of the adrenal glands may reveal subtle adrenal contour abnormality and bilateral micronodules, which

are small, round, well delineated, and hypodense, and are best seen when the CT slices are 3 millimeters or less in thickness (can be missed if the CT slice thickness is 5 millimeters or more) [28].

Bilateral adrenalectomy is the most common treatment for patients with PPNAD and CS. Rarely medical treatment with ketoconazole or mitotane has been used [29]. In a recent retrospective study of 15 patients with CNC and classic CS who underwent surgical treatment, cure was achieved with bilateral adrenalectomy (12 patients), subtotal adrenalectomy (2 patients), and partial unilateral adrenalectomy (1 patient), whereas CS regressed spontaneously in 1 patient and persisted untreated for almost 3 decades in another [30]. These data highlight the possible need for reconsideration of less than total bilateral adrenalectomy in patients with CNC and CS.

Only 2 cases of adrenocortical carcinoma in CNC patients with PPNAD and *PRKAR1A* mutations have been described in the literature [31]. These cases were characterized by co-secretion of androgens and cortisol and aggressive disease which metastasized rapidly or recurred locally. Somatic mutations in *PRKAR1A* have also been described in cortisol-producing adrenal tumors including adrenocortical adenomas and carcinomas [32].

Pituitary manifestations

Up to 12 % of patients with CNC develop acromegaly, whereas approximately 75 % may have asymptomatic elevation of GH and IGF-I, abnormal oral glucose tolerance test, and/or paradoxical response to TRH stimulation, without evidence of a pituitary adenoma on imaging [1, 33–35]. When present, pituitary adenomas may be single or multifocal. Histology may demonstrate somatotroph hyperplasia that often surrounds adenomas, and may potentially precede the development of GH and/or prolactin-producing adenomas. Patients can have concurrent GH and prolactin secretion with up to 64 % of patients with CNC demonstrating hyperprolactinemia [36]. Prolactinomas, however, are rare [37]. In addition to growth hormone, tissue from GH-producing pituitary adenomas commonly stains for prolactin, as well as for other hormones such as the glycoprotein subunit- α , TSH- β , LH- β , and occasionally for FSH- β . Recently, 2 cases of corticotropinomas have been described in patients with CNC and *PRKAR1A* mutations, with *PRKAR1A* LOH demonstrated in molecular analysis of the tumor tissue [38, 39]. Furthermore, a case of a pituitary adenoma with hypersecretion of both GH and TSH and positive staining for TSH on pathology, was described in a patient with presumed CNC in Japan [40].

In patients with acromegaly due to a GH-secreting pituitary adenoma, selective adenomectomy is the preferred treatment [41]. Patients with multiple GH-secreting adenomas with associated hyperplasia may require partial or complete hypophysectomy to achieve biochemical remission. Medical treatment with a somatostatin analogue or GH antagonist may be considered in patients with GH excess without a discrete pituitary adenoma.

Thyroid tumors

Thyroid lesions occur more commonly in CNC than in the general population and can range from follicular hyperplasia and/or cystic changes to carcinoma [41]. Greater than 60 % of children and adults with CNC have cystic or multinodular disease on thyroid ultrasound,

with follicular adenoma being the most common finding on biopsy. In a cohort of 353 patients, thyroid tumors were detected in 25% of patients, with thyroid cancer (follicular and/or papillary carcinoma) detected in 2.5% of patients [42]. In a recent review of 26 patients with CNC and thyroid disorders, 15% of patients had hyperthyroidism (caused by presumed diffuse follicular hyperplasia in 2 patients with Graves disease, and toxic adenoma in the other 2), 61% had benign lesions (follicular hyperplasia, nodular hyperplasia, or follicular adenoma), and 38% had carcinomas (7 patients with follicular carcinoma and 3 patients with papillary carcinoma) [43]. One patient with multinodular goiter was found to have a follicular adenoma and a possibly unique type of microscopic multifocal follicular hyperplasia. Most patients were middle-aged women presenting with an asymptomatic thyroid mass. In this series, follicular carcinoma was more frequent than papillary carcinoma, and exhibited atypical features, with multifocal and bilateral disease, as well as lymph node metastases. The carcinoma was fatal in 75% of cases (3 of 4 patients) where the tumor was ≥ 3 centimeters in diameter. Abnormalities in *PRKAR1A* were detected in 7 out of 10 patients tested from this cohort.

PRKAR1A LOH at the *CNC1* locus has also been described in sporadic thyroid cancer, supporting the hypothesis that *PRKAR1A* loss of function can lead to tumorigenesis in thyroid tissue [44]. Patients with CNC should receive long-term clinical and/or sonographic surveillance with biopsy of suspicious nodules, with the goal of early detection and surgical treatment of thyroid carcinomas.

Testicular lesions

LCCSCTs are sex-cord stromal tumors that may be present in at least 41% of males with CNC [3]. In contrast to sporadic LCCSCT, LCCSCTs in CNC tend to be multicentric and bilateral. These tumors contain microcalcifications and can be detected on ultrasound where they have the unique appearance of multiple homogeneous echogenic masses with a smooth contour and acoustic shadowing, that lack an associated soft tissue component [1]. LCCSCTs are commonly asymptomatic but occasionally may be functional and can lead to gynecomastia in prepubertal and peripubertal boys through increased P-450 aromatase expression. This may result in premature epiphyseal fusion and induction of central precocious puberty. In addition, these tumors progress gradually with age and replace normal testicular tissue, which may cause replacement and obstruction of the seminiferous tubules and reduced fertility.

Men with CNC may have morphologically abnormal sperm and reduced sperm counts [45]. LCCSCT is almost always benign, though metastasis of the tumor has been reported in a 62-year-old patient [1].

Other testicular tumors that may occur in CNC patients, include Leydig cell and adrenocortical rest tumors, which occur concurrently with LCCSCT. Adrenocortical rest tumors can lead to recurrent CS after adrenalectomy in patients with PPNAD.

Ovarian lesions

Ovarian lesions are frequent in women with CNC. Though the exact prevalence is unclear, in several series these lesions have been reported in 14–66% of affected women [3, 46]. The *CNC2* locus

was found to be involved in ovarian pathology with apparent copy number gain.

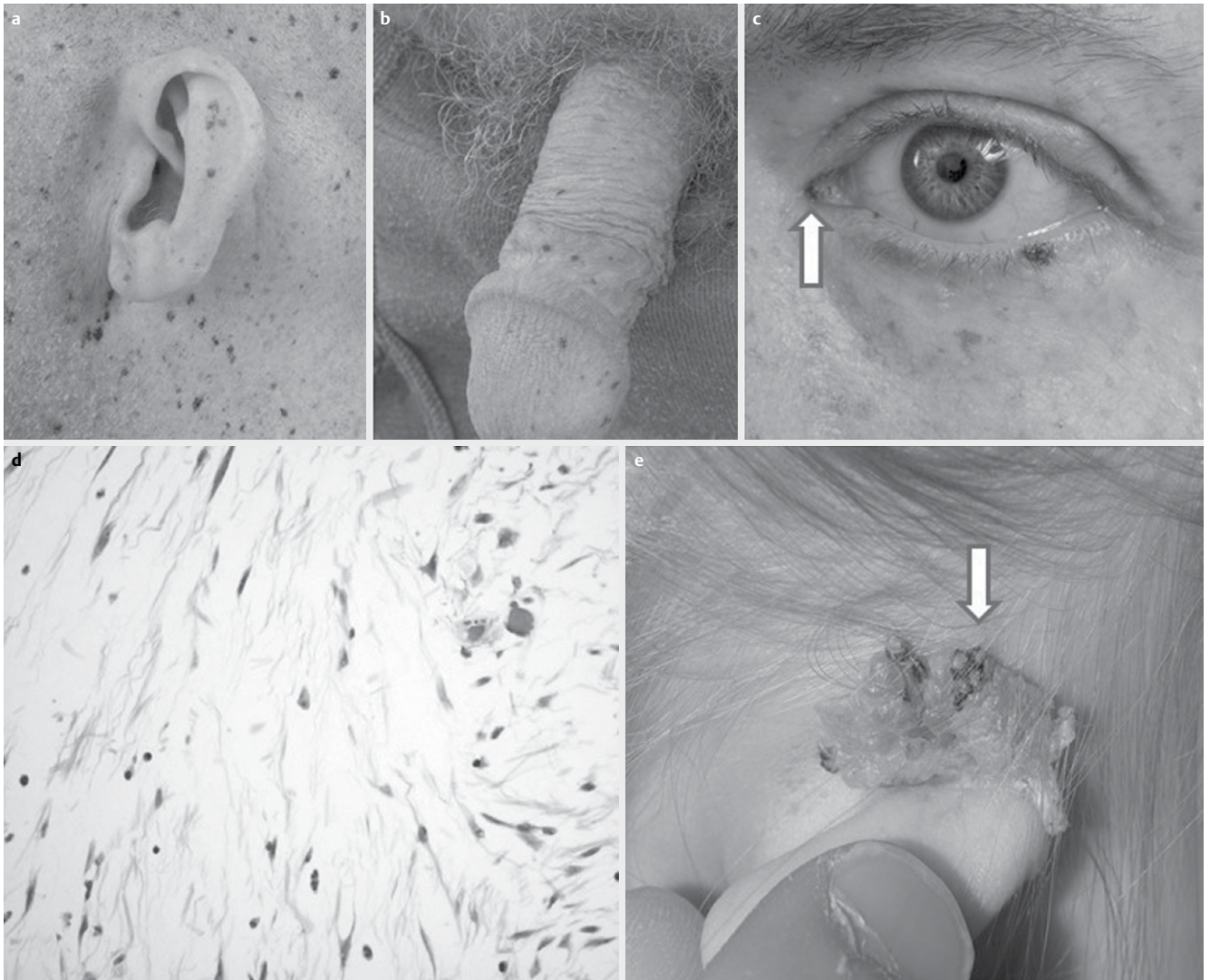
Ovarian cysts and tumors of the ovarian surface epithelium (serous cystadenomas and cystic teratomas) are most common, whereas ovarian carcinoma, such as mucinous adenocarcinoma or endometrioid carcinoma, is rare. Initial evaluation of women with CNC may include ultrasound of the ovaries, and any identified lesion requires follow-up.

Cutaneous Manifestations

Cutaneous lesions are the earliest and most common manifestation of CNC and include 3 of the major diagnostic criteria – lentiginos, cutaneous and mucosal myxomas, and blue nevi and epithelioid blue nevi (EBN) [1]. Café-au-lait spots, irregular depigmented areas, multiple compound nevi, and Spitz nevi have also been reported in patients with CNC but are rarely isolated manifestations [1, 3, 47–50]. Lentiginos occur in 70 to 80% of patients with CNC, and are hamartomatous melanocytic lesions that are small, flat, poorly circumscribed, and brown or black in color. They can occur in areas not exposed to sunlight, and are typically distributed on the face, vermilion border, genital area, and mucosa (► Fig. 2a–c). They can affect the eyes with palpebral lesions as well as lesions of the caruncle or conjunctival semilunar fold (► Fig. 2c). Blue nevi can be observed in approximately 40% of patients and are characterized as small, circular or star-shaped, and blue to black in color, with variable distribution. EBNs comprise a subtype of blue nevi that can be commonly seen in CNC but is rare in the general population [51, 52]. These lesions are characterized by intense pigmentation and poorly circumscribed proliferative regions with associated dermal fibrosis. Cutaneous myxomas, are reported in 30–55% of patients and typically appear before adulthood but can recur in older patients. They most commonly affect the eyelids, ears, nipples, external auditory canals, trunk, and perineum (► Fig. 2d, e) [20, 53, 54]. Approximately 80% of patients with cardiac myxomas exhibit cutaneous myxomas earlier in life. Other areas that may develop myxomas include the breasts (often bilateral), the oropharynx (tongue, hard palate, pharynx), the female genital tract (uterus, cervix, vagina), and the female pelvis [1]. Angiomyxoid nodules are rare [55].

Cardiac Myxomas

Cardiac myxomas are the most common non-cutaneous manifestation in CNC, developing in 20–40% of patients, with median age at diagnosis of 20 years [12, 28]. In CNC, these tumors occur in both sexes without predilection, can affect any chamber of the heart, and have a more aggressive course with multifocality, rapid growth, and multiple recurrences [1]. In contrast, sporadic cardiac myxomas develop almost exclusively in the left atrium, are more common in older women, and do not tend to recur. Up to 10% of cardiac myxomas occur in the setting of CNC [56]. Somatic *PRKAR1A* mutations have also been detected during molecular analysis of cardiac tissue from sporadic cardiac myxomas [57]. Patients may present with symptoms due embolic phenomena or intracardiac obstruction of blood flow which may lead to sudden death. Cardi-



► **Fig. 2** Clinical manifestations of Carney complex: **a** and **b** Lentiginos on the face, earlobe, neck, and genitals of a patient with Carney complex; **c** Typical inner canthal pigmentation (arrow); pigmented macules in the inner or outer canthus are present in 1/3 of patients with the complex and the only other disease that one sees that at is Peutz-Jeghers syndrome; **d** Typical histology of a myxoma from a patient with Carney complex; the lesion is not hypercellular; rather, few fibroblast-like cells are surrounded by copious myxoid, glycoprotein-based material that is gelatin-like macroscopically (hematoxylin and eosin staining, x20 magnification); **e** Earlobe myxoma complicated by a superficial, bacterial skin infection in a toddler with Carney complex.

ac myxomas are responsible for more than 50% of mortality in CNC [1]. Early detection with regular screening echocardiography, or cardiac CT or MRI in puzzling cases, is essential. Cardiac myxomas should be removed surgically [58]. The development of cardiac myxomas in CNC may be associated with increased GH secretion, and treatment of GH excess in patients with CNC may reduce the likelihood of cardiac myxoma recurrence [59].

Breast Lesions

Manifestations of CNC in the breast include breast myxomas, which occur in 20% of women after puberty and are often bilateral, myxomas of the nipple, that occur in both sexes at any age, ductal adenomas, and myxoid fibroadenomas [1, 3, 12].

Osteochondromyxoma

Osteochondromyxoma is a rare myxomatous tumor of the bone that affects 1% of patients with CNC [60]. These tumors often appear before the age of 2 years and have been noted to occur in long bones (diaphyseal) and small flat bones (nasal). Osteochondromyxomas are considered benign tumors, but can be both locally invasive and recur. Complete excision of these tumors may be curative.

Schwannomas

Psamomatous melanotic schwannoma (PMS) is a rare tumor of the nerve sheath that has been reported in 8–10% of patients with CNC, with median age at presentation of 32 years [3, 33]. Other than the neurofibromatosis syndromes and isolated familial schwannomatosis, CNC is the only hereditary condition that

manifests with schwannomas. Schwannomas that occur in CNC are distinguished by their heavy pigmentation (melanin), frequent calcification, and multicentricity [61]. These tumors may be located anywhere in the central or peripheral nervous system, with the most frequent sites affected being the gastrointestinal tract (esophagus, stomach, liver, and rectum), the paraspinal sympathetic chain, as well as the chest wall [28, 61, 62]. Patients may present with symptoms of pain and radiculopathy. Ten percent of these tumors are malignant, with frequent metastasis to the lung, liver, and/or brain [33, 63]. Symptomatic patients should undergo MRI of the brain, spine, chest, abdomen, pelvis, and/or retroperitoneum. PMS are the most difficult tumors to treat as their location in or around nerve roots along the spine can make them frequently inoperable and there is practically no effective medical or surgical treatment for metastatic PMS.

Other Lesions and Predisposition to Malignancies

Up to 2.5% of patients with CNC develop pancreatic neoplasms, which can be a significant cause of mortality and include acinar cell carcinoma, adenocarcinoma, and intraductal pancreatic mucinous neoplasm [1]. Other lesions that have been described in CNC include parotid mixed tumor, bronchogenic cyst, hepatocellular adenoma and carcinoma, colonic, gastric carcinomas, and retroperitoneal fibrous histiocytomas, as well as most recently fibrolamellar carcinomas of the liver and hepatic and renal cysts [1, 3, 64–66].

Surveillance

Clinical surveillance, in patients with CNC, for the early detection of manifestations of the syndrome differs according to age group, since most endocrine tumors do not become clinically significant until the second decade of life. Pre-pubertal pediatric patients should undergo evaluation with echocardiogram annually (biannually for patients with prior history of excised cardiac myxoma) beginning at 6 months of age [67]. Boys should undergo testicular ultrasonography. Close monitoring of the growth rate and annual pubertal staging is recommended as abnormalities may be indicative of hormone excess. Post-pubertal pediatric and adult patients should have annual echocardiogram (biannual for adolescent patients with a history of excised cardiac myxoma), testicular and thyroid ultrasound, and measurement of urinary free cortisol, and serum IGF-1 [67]. Women with CNC should undergo transabdominal pelvic ultrasound during initial evaluation which does not need to be repeated unless an abnormality is detected.

Acknowledgement

We thank Jeremy A. Swan, and Nichole C. Swan (NICHD, Computer Support Services Core) for the development of the figures.

Funding statement

This work was supported by the research project Z01-HD008920 (Principal Investigator: Dr. Constantine A. Stratakis) of the Intra-

mural Research Program of the Eunice Kennedy Shriver National Institute of Child Health & Human Development (NICHD), National Institutes of Health (NIH), Bethesda, MD, USA.

Conflict of Interest

Dr. Stratakis holds patents on the *PRKAR1A* and other genes of the cyclic AMP pathway and their genetics and applications. Dr. Stratakis' lab has received research funding from Pfizer Inc. for the study of gigantism and/or acromegaly.

References

- [1] Stratakis CA, Kirschner LS, Carney JA. Clinical and molecular features of the carney complex: Diagnostic criteria and recommendations for patient evaluation. *J Clin Endocrinol Metab* 2001; 86: 4041–4046. doi:10.1210/jcem.86.9.7903
- [2] Kirschner LS, Carney JA, Pack SD et al. Mutations of the gene encoding the protein kinase A type I-alpha regulatory subunit in patients with the carney complex. *Nat Genet* 2000; 26: 89–92. doi:10.1038/79238
- [3] Bertherat J, Horvath A, Groussin L et al. Mutations in regulatory subunit type 1A of cyclic adenosine 5'-monophosphate-dependent protein kinase (*PRKAR1A*): Phenotype analysis in 353 patients and 80 different genotypes. *J Clin Endocrinol Metab* 2009; 94: 2085–2091. doi:10.1210/jc.2008-2333
- [4] Cazabat L, Ragazzon B, Groussin L et al. *PRKAR1A* mutations in primary pigmented nodular adrenocortical disease. *Pituitary* 2006; 9: 211–219. doi:10.1007/s11102-006-0266-1
- [5] Stratakis CA, Carney JA, Lin JP et al. Carney complex, a familial multiple neoplasia and lentiginosis syndrome. Analysis of 11 kindreds and linkage to the short arm of chromosome 2. *J Clin Invest* 1996; 97: 699–705. doi:10.1172/JCI118467
- [6] Matyakhina L, Pack S, Kirschner LS et al. Chromosome 2 (2p16) abnormalities in carney complex tumours. *J Med Genet* 2003; 40: 268–277
- [7] Forlino A, Vetro A, Garavelli L et al. *PRKACB* and Carney complex. *N Engl J Med* 2014; 370: 1065–1067. doi:10.1056/NEJMc1309730
- [8] Carney JA, Gordon H, Carpenter PC et al. The complex of myxomas, spotty pigmentation, and endocrine overactivity. *Medicine (Baltimore)* 1985; 64: 270–283
- [9] Bain J. Carney's complex. *Mayo Clin Proc* 1986; 61: 508
- [10] Atherton DJ, Pitcher DW, Wells RS et al. A syndrome of various cutaneous pigmented lesions, myxoid neurofibromata and atrial myxoma: The NAME syndrome. *Br J Dermatol* 1980; 103: 421–429
- [11] Rhodes AR, Silverman RA, Harrist TJ et al. Mucocutaneous lentiginosis, cardiomyocutaneous myxomas, and multiple blue nevi: The "LAMB" syndrome. *J Am Acad Dermatol* 1984; 10: 72–82
- [12] Espiard S, Bertherat J. Carney complex. *Front Horm Res* 2013; 41: 50–62. doi:10.1159/000345669
- [13] Taylor SS, Ilouz R, Zhang P et al. Assembly of allosteric macromolecular switches: Lessons from PKA. *Nat Rev Mol Cell Biol* 2012; 13: 646–658. doi:10.1038/nrm3432
- [14] Amieux PS, McKnight GS. The essential role of RI alpha in the maintenance of regulated PKA activity. *Ann NY Acad Sci* 2002; 968: 75–95
- [15] Horvath A, Bossis I, Giatzakis C et al. Large deletions of the *PRKAR1A* gene in carney complex. *Clin Cancer Res* 2008; 14: 388–395. doi:10.1158/1078-0432.CCR-07-1155

- [16] Salpea P, Horvath A, London E et al. Deletions of the PRKAR1A locus at 17q24.2-q24.3 in carney complex: Genotype-phenotype correlations and implications for genetic testing. *J Clin Endocrinol Metab* 2014; 99: E183–E188. doi:10.1210/jc.2013-3159
- [17] Groussin L, Horvath A, Jullian E et al. A PRKAR1A mutation associated with primary pigmented nodular adrenocortical disease in 12 kindreds. *J Clin Endocrinol Metab* 2006; 91: 1943–1949. doi:10.1210/jc.2005-2708
- [18] Bonnet-Serrano F, Bertherat J. Genetics of tumors of the adrenal cortex. *Endocr Relat Cancer* 2018; 25: R131–R152. doi:10.1530/ERC-17-0361
- [19] Patronas Y, Horvath A, Greene E et al. In vitro studies of novel PRKAR1A mutants that extend the predicted R1alpha protein sequence into the 3'-untranslated open reading frame: Proteasomal degradation leads to r1alpha haploinsufficiency and carney complex. *J Clin Endocrinol Metab* 2012; 97: E496–E502. doi:10.1210/jc.2011-2220
- [20] Tsilou ET, Chan CC, Sandrini F et al. Eyelid myxoma in carney complex without PRKAR1A allelic loss. *Am J Med Genet A* 2004; 130A: 395–397. doi:10.1002/ajmg.a.30279
- [21] Robinson-White A, Hundley TR, Shiferaw M et al. Protein kinase-A activity in PRKAR1A-mutant cells, and regulation of mitogen-activated protein kinases ERK1/2. *Hum Mol Genet* 2003; 12: 1475–1484
- [22] Stratakis CA, Salpea P, Raygada M. Carney Complex. In: Adam MP, Ardinger HH, Pagon RA et al. (eds.). *GeneReviews*(R). 1993 Seattle (WA)
- [23] Shenoy BV, Carpenter PC, Carney JA. Bilateral primary pigmented nodular adrenocortical disease. Rare cause of the Cushing syndrome. *Am J Surg Pathol* 1984; 8: 335–344
- [24] Libe R, Horvath A, Vezzosi D et al. Frequent phosphodiesterase 11A gene (PDE11A) defects in patients with carney complex (CNC) caused by PRKAR1A mutations: PDE11A may contribute to adrenal and testicular tumors in CNC as a modifier of the phenotype. *J Clin Endocrinol Metab* 2011; 96: E208–E214. doi:10.1210/jc.2010-1704
- [25] Stratakis CA, Sarlis N, Kirschner LS et al. Paradoxical response to dexamethasone in the diagnosis of primary pigmented nodular adrenocortical disease. *Ann Intern Med* 1999; 131: 585–591
- [26] Bourdeau I, Lacroix A, Schurch W et al. Primary pigmented nodular adrenocortical disease: Paradoxical responses of cortisol secretion to dexamethasone occur in vitro and are associated with increased expression of the glucocorticoid receptor. *J Clin Endocrinol Metab* 2003; 88: 3931–3937. doi:10.1210/jc.2002-022001
- [27] Louiset E, Stratakis CA, Perraudin V et al. The paradoxical increase in cortisol secretion induced by dexamethasone in primary pigmented nodular adrenocortical disease involves a glucocorticoid receptor-mediated effect of dexamethasone on protein kinase A catalytic subunits. *J Clin Endocrinol Metab* 2009; 94: 2406–2413. doi:10.1210/jc.2009-0031
- [28] Courcoutsakis NA, Tatsi C, Patronas NJ et al. The complex of myxomas, spotty skin pigmentation and endocrine overactivity (carney complex): Imaging findings with clinical and pathological correlation. *Insights Imaging* 2013; 4: 119–133. doi:10.1007/s13244-012-0208-6
- [29] Cignarelli M, Picca G, Campo M et al. A six month mitotane course induced sustained correction of hypercortisolism in a young woman with PPNAD and carney complex. *J Endocrinol Invest* 2005; 28: 54–60
- [30] Lowe KM, Young WF Jr., Lyssikatos C et al. Cushing syndrome in carney complex: clinical, pathologic, and molecular genetic findings in the 17 affected mayo clinic patients. *Am J Surg Pathol* 2017; 41: 171–181. doi:10.1097/PAS.0000000000000748
- [31] Bertherat J. Adrenocortical cancer in carney complex: A paradigm of endocrine tumor progression or an association of genetic predisposing factors? *J Clin Endocrinol Metab* 2012; 97: 387–390. doi:10.1210/jc.2011-3327
- [32] Bertherat J, Groussin L, Sandrini F et al. Molecular and functional analysis of PRKAR1A and its locus (17q22-24) in sporadic adrenocortical tumors: 17q losses, somatic mutations, and protein kinase A expression and activity. *Cancer Res* 2003; 63: 5308–5319
- [33] Watson JC, Stratakis CA, Bryant-Greenwood PK et al. Neurosurgical implications of carney complex. *J Neurosurg* 2000; 92: 413–418. doi:10.3171/jns.2000.92.3.0413
- [34] Raff SB, Carney JA, Krugman D et al. Prolactin secretion abnormalities in patients with the “syndrome of spotty skin pigmentation, myxomas, endocrine overactivity and schwannomas” (carney complex). *J Pediatr Endocrinol Metab* 2000; 13: 373–379
- [35] Pack SD, Kirschner LS, Pak E et al. Genetic and histologic studies of somatomammotropic pituitary tumors in patients with the “complex of spotty skin pigmentation, myxomas, endocrine overactivity and schwannomas” (carney complex). *J Clin Endocrinol Metab* 2000; 85: 3860–3865. doi:10.1210/jcem.85.10.6875
- [36] Kirschner LS. PRKAR1A and the evolution of pituitary tumors. *Mol Cell Endocrinol* 2010; 326: 3–7. doi:10.1016/j.mce.2010.04.027
- [37] Armstrong DK, Irvine AD, Handley JM et al. Carney complex: Report of a kindred with predominantly cutaneous manifestations. *Br J Dermatol* 1997; 136: 578–582
- [38] Hernandez-Ramirez LC, Tatsi C, Lodish MB et al. Corticotropinoma as a component of carney complex. *J Endocr Soc* 2017; 1: 918–925. doi:10.1210/js.2017-00231
- [39] Kiefer FW, Winhofer Y, Iacovazzo D et al. PRKAR1A mutation causing pituitary-dependent cushing disease in a patient with carney complex. *Eur J Endocrinol* 2017; 177: K7–K12. doi:10.1530/EJE-17-0227
- [40] Okamoto A, Wajima D, Tei R et al. A case of a pituitary adenoma diagnosed as carney complex syndrome in an older female patient. *No Shinkei Geka* 2017; 45: 225–231. doi:10.11477/mf.1436203483
- [41] Lonser RR, Mehta GU, Kindzelski BA et al. Surgical management of carney complex-associated pituitary pathology. *Neurosurgery* 2017; 80: 780–786. doi:10.1227/NEU.0000000000001384
- [42] Stratakis CA, Courcoutsakis NA, Abati A et al. Thyroid gland abnormalities in patients with the syndrome of spotty skin pigmentation, myxomas, endocrine overactivity, and schwannomas (carney complex). *J Clin Endocrinol Metab* 1997; 82: 2037–2043. doi:10.1210/jcem.82.7.4079
- [43] Carney JA, Lyssikatos C, Seethala RR et al. The spectrum of thyroid gland pathology in carney complex: The importance of follicular carcinoma. *Am J Surg Pathol* 2018; 42: 587–594. doi:10.1097/PAS.0000000000000975
- [44] Sandrini F, Matyakhina L, Sarlis NJ et al. Regulatory subunit type I-alpha of protein kinase A (PRKAR1A): A tumor-suppressor gene for sporadic thyroid cancer. *Genes Chromosomes Cancer* 2002; 35: 182–192. doi:10.1002/gcc.10112
- [45] Burton KA, McDermott DA, Wilkes D et al. Haploinsufficiency at the protein kinase A RI alpha gene locus leads to fertility defects in male mice and men. *Mol Endocrinol* 2006; 20: 2504–2513. doi:10.1210/me.2006-0060
- [46] Stratakis CA, Papageorgiou T, Premkumar A et al. Ovarian lesions in carney complex: Clinical genetics and possible predisposition to malignancy. *J Clin Endocrinol Metab* 2000; 85: 4359–4366. doi:10.1210/jcem.85.11.6921
- [47] Mateus C, Palangie A, Franck N et al. Heterogeneity of skin manifestations in patients with carney complex. *J Am Acad Dermatol* 2008; 59: 801–810. doi:10.1016/j.jaad.2008.07.032
- [48] Horvath A, Stratakis CA. Carney complex and lentiginosis. *Pigment Cell Melanoma Res* 2009; 22: 580–587. doi:10.1111/j.1755-148x.2009.00613.x
- [49] Stratakis CA. Genetics of Peutz-Jeghers syndrome, Carney complex and other familial lentiginoses. *Horm Res* 2000; 54: 334–343. doi:10.1159/000053283

- [50] Vandersteen A, Turnbull J, Jan W et al. Cutaneous signs are important in the diagnosis of the rare neoplasia syndrome Carney complex. *Eur J Pediatr* 2009; 168: 1401–1404. doi:10.1007/s00431-009-0935-y
- [51] Carney JA, Stratakis CA. Epithelioid blue nevus and psammomatous melanotic schwannoma: The unusual pigmented skin tumors of the Carney complex. *Semin Diagn Pathol* 1998; 15: 216–224
- [52] Carney JA, Ferreiro JA. The epithelioid blue nevus. A multicentric familial tumor with important associations, including cardiac myxoma and psammomatous melanotic schwannoma. *Am J Surg Pathol* 1996; 20: 259–272
- [53] Carney JA, Headington JT, Su WP. Cutaneous myxomas. A major component of the complex of myxomas, spotty pigmentation, and endocrine overactivity. *Arch Dermatol* 1986; 122: 790–798
- [54] Kennedy RH, Waller RR, Carney JA. Ocular pigmented spots and eyelid myxomas. *Am J Ophthalmol* 1987; 104: 533–538
- [55] Hachisuka J, Ichikawa M, Moroi Y et al. A case of carney complex. *Int J Dermatol* 2006; 45: 1406–1407 doi:10.1111/j.1365-4632.2006.02889.x
- [56] Serio A, Favalli V, Giuliani L et al. Cardio-Oncology: The carney complex Type I. *J Am Coll Cardiol* 2016; 68: 1921–1923. doi:10.1016/j.jacc.2016.07.764
- [57] He J, Sun M, Li E et al. Recurrent somatic mutations of PRKAR1A in isolated cardiac myxoma. *Oncotarget* 2017; 8: 103968–103974. doi:10.18632/oncotarget.21916
- [58] Boikos SA, Stratakis CA. Carney complex: The first 20 years. *Curr Opin Oncol* 2007; 19: 24–29. doi:10.1097/CCO.0b013e32801195eb
- [59] Bandettini WP, Karageorgiadis AS, Sinaii N et al. Growth hormone and risk for cardiac tumors in carney complex. *Endocr Relat Cancer* 2016; 23: 739–746. doi:10.1530/ERC-16-0246
- [60] Carney JA, Boccon-Gibod L, Jarka DE et al. Osteochondromyxoma of bone: A congenital tumor associated with lentiginos and other unusual disorders. *Am J Surg Pathol* 2001; 25: 164–176
- [61] Carney JA. Psammomatous melanotic schwannoma. A distinctive, heritable tumor with special associations, including cardiac myxoma and the Cushing syndrome. *Am J Surg Pathol* 1990; 14: 206–222
- [62] Rodriguez FJ, Stratakis CA, Evans DG. Genetic predisposition to peripheral nerve neoplasia: diagnostic criteria and pathogenesis of neurofibromatosis, Carney complex, and related syndromes. *Acta Neuropathol* 2012; 123: 349–367. doi:10.1007/s00401-011-0935-7
- [63] Shields LB, Glassman SD, Raque GH et al. Malignant psammomatous melanotic schwannoma of the spine: A component of carney complex. *Surg Neurol Int* 2011; 2: 136. doi:10.4103/2152-7806.85609
- [64] Gonzalez-Cantu YM, Rodriguez-Padilla C, Tena-Suck ML et al. Synchronous fibrolamellar hepatocellular carcinoma and auricular myxoma. *Case Rep Pathol* 2015; 2015: 241708 doi:10.1155/2015/241708
- [65] Graham RP, Lackner C, Terracciano L et al. Fibrolamellar carcinoma in the Carney complex: PRKAR1A loss instead of the classic DNAJB1-PRKACA fusion. *Hepatology* 2017, doi:10.1002/hep.29719
- [66] Ye H, Wang X, Constans MM et al. The regulatory 1alpha subunit of protein kinase A modulates renal cystogenesis. *Am J Physiol Renal Physiol* 2017; 313: F677–F686. doi:10.1152/ajprenal.00119.2017
- [67] Stratakis CA. Carney complex: A familial lentiginosis predisposing to a variety of tumors. *Rev Endocr Metab Disord* 2016; 17: 367–371. doi:10.1007/s11154-016-9400-1