Published online: 2018-12-11

Endoscopic ultrasound-guided coil embolization and thrombin injection of a bleeding gastroduodenal artery pseudoaneurysm

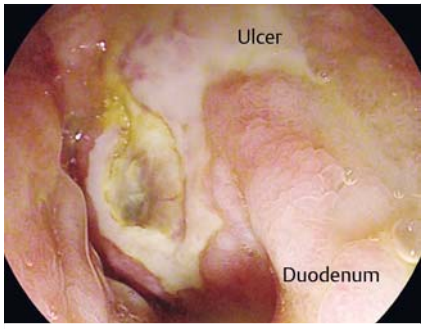

▶ **Fig. 1** Side-viewing endoscopy showed a pulsatile bulge with a large overlying ulcer.

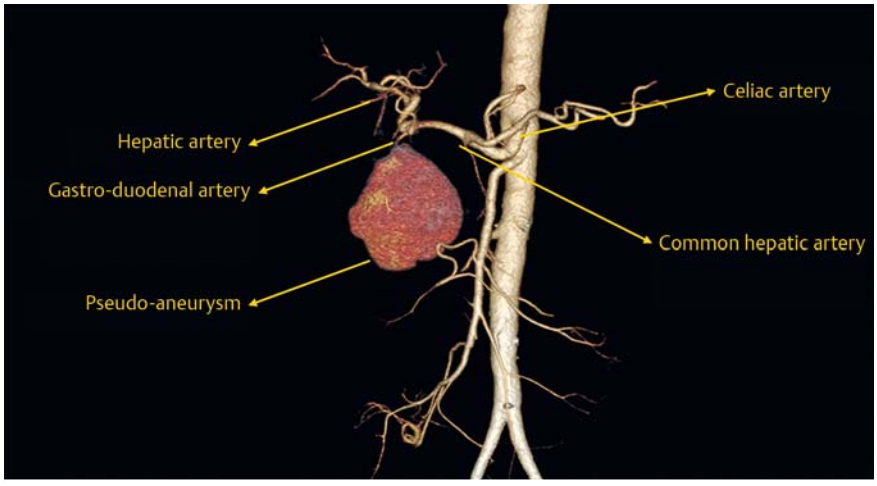

▶ **Fig. 2** Abdominal computed tomography with angiography showed a saccular pseudoaneurysm of size 4 × 6 cm in relation to the gastroduodenal artery.

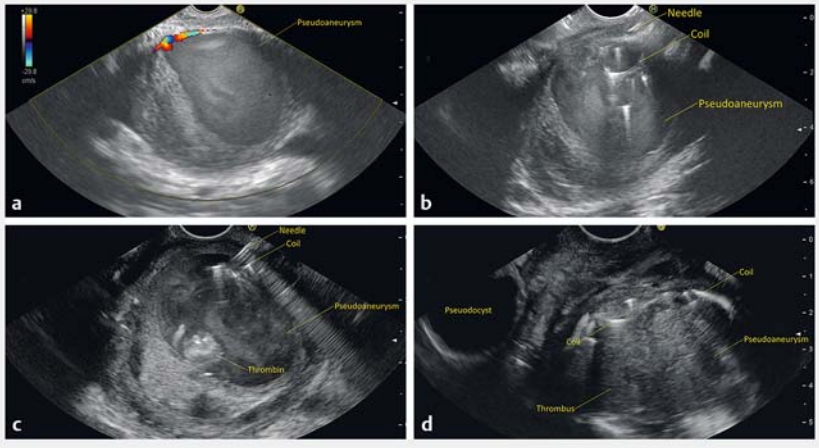

▶ **Fig. 3** Endoscopic ultrasound (EUS) images. **a** EUS from the duodenal bulb showed a pseudoaneurysm of size 4.1 × 5.8 cm arising from the gastroduodenal artery. **b** Under EUS and fluoroscopy guidance, five 10-mm coils were placed within the pseudoaneurysm through a 19-gauge EUS needle. **c** 1 mL of human thrombin (500 IU) was injected into the pseudoaneurysm through a 22-gauge needle. **d** Complete obliteration of the pseudoaneurysm with hyperechoic thrombus with no blood flow.

A 50-year-old man had an episode of alcohol-induced acute pancreatitis 1 month before presenting with melena, which required six units of transfused blood for hemodynamic stabilization. After hemodynamic resuscitation, the patient underwent upper gastrointestinal endoscopy. Upper endoscopy showed a bulge with overlying ulceration in the second part of the duodenum. Side-viewing endoscopy showed a pulsatile bulge with a large overlying ulcer (▶ **Fig. 1**). Abdominal ultrasound showed a pseudoaneurysm of size 3.8 × 5.6 cm arising from the gastroduodenal artery (GDA). Abdominal computed tomography with angiography showed a saccular pseudoaneurysm of size 4 × 6 cm in relation to the GDA (▶ **Fig. 2**). Endoscopic ultrasound (EUS) from the duodenal bulb showed a pseudoaneurysm of size 4.1 × 5.8 cm arising from the GDA (▶ **Fig. 3 a**). Radiological or EUS-guided interventions were considered. The patient selected the option of EUS-guided coil embolization (▶ **Video 1**).

Under EUS and fluoroscopy guidance, five 10-mm coils were placed within the pseudoaneurysm through a 19-gauge EUS needle (▶ **Fig. 3 b**). After coil embolization, contrast injection into the pseudoaneurysm showed partial filling of the pseudoaneurysm. Follow-up EUS 1 day after coil embolization showed high flow in the pseudoaneurysm. Around 30 % of the pseudoaneurysm was obliterated. On the third day, 6 mL of human thrombin (3000 IU) was injected in six boluses of 500 IU each (▶ **Fig. 3 c**). After thrombin injection, high velocity flow was confined to the neck and periphery of the pseudoaneurysm. A further 2 mL of

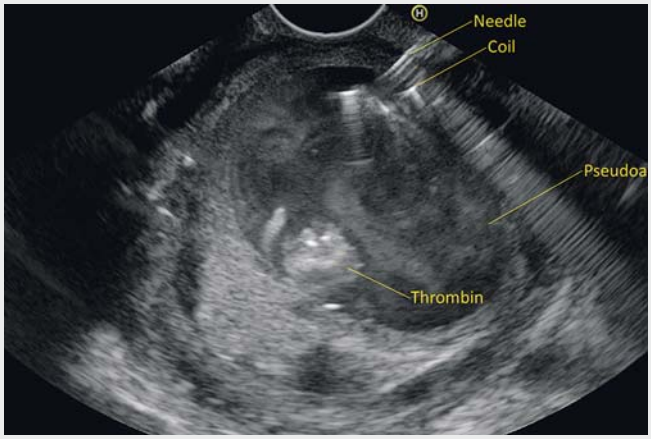

Video 1 Endoscopic ultrasound-guided coil embolization and thrombin injection of a bleeding gastroduodenal artery pseudoaneurysm.

thrombin was injected. Immediately after thrombin injection, color Doppler EUS showed complete obliteration of the pseudoaneurysm (▶ **Fig. 3 d**). Repeat EUS 2 weeks later showed a completely obliterated pseudoaneurysm with no flow.

This case shows the practical problems of EUS-guided coil embolization of pseudoaneurysms. Further studies are required regarding the best modality or combination of modalities of EUS-guided treatment of pseudoaneurysms with coils, glue or thrombin.

Endoscopy_UCTN_Code_TTT_1AO_2AD

Acknowledgment

The authors thank Pran Prakash for assistance with the graphics.

Competing interests

None

The authors

Malay Sharma[1], Piyush Somani[1], Tagore Sunkara[2], Ritesh Prajapati[1], Rahul Talele[1]

1 Department of Gastroenterology, Jaswant Rai Speciality Hospital, Meerut, India
2 Department of Gastroenterology and Hepatology, The Brooklyn Hospital Center, Clinical Affliate of the Mount Sinai Hospital, Brooklyn, New York, United States

Corresponding author

Malay Sharma, MD, DM
Department of Gastroenterology, Jaswant Rai Speciality Hospital, Saket, Meerut, PIN-250 001, Uttar Pradesh, India
Fax: +91-121-2657154
sharmamalay@hotmail.com

Bibliography
DOI https://doi.org/10.1055/a-0790-8134
Published online: 11.12.2018
Endoscopy 2019; 51: E36–E37

ISSN 0013-726X