

Endoscopic grading of gastric intestinal metaplasia (EGGIM): a multicenter validation study

Authors

Gianluca Esposito¹, Pedro Pimentel-Nunes^{2,3,4}, Stefano Angeletti¹, Rui Castro², Diogo Libânio^{2,3}, Gloria Galli¹, Edith Lahner¹, Emilio Di Giulio¹, Bruno Annibale¹, Mario Dinis-Ribeiro^{2,3}

Institutions

- 1 Department of Medical-Surgical Sciences and Translational Medicine, Sant'Andrea Hospital, Sapienza University of Rome, Rome, Italy
- 2 Gastroenterology Department, Portuguese Oncology Institute of Porto, Porto, Portugal
- 3 Center for Research in Health Technologies and Information Systems (CINTESIS), Faculty of Medicine, University of Porto, Porto, Portugal
- 4 Department of Surgery and Physiology, Faculty of Medicine, University of Porto, Porto, Portugal

submitted 1.7.2018

accepted after revision 1.11.2018

Bibliography

DOI <https://doi.org/10.1055/a-0808-3186>

Published online: 21.12.2018 | *Endoscopy* 2019; 51: 515–521

© Georg Thieme Verlag KG Stuttgart · New York

ISSN 0013-726X

Corresponding author

Gianluca Esposito, MD, Department of Medical-Surgical Sciences and Translational Medicine, Sant'Andrea Hospital, Sapienza University of Rome, Via di Grottarossa 1035, 00189 Roma, Italy
gle.esposito@gmail.com

ABSTRACT

Background Random biopsies are recommended to identify individuals at risk of gastric adenocarcinoma. Cumulative evidence suggests that narrow-band imaging (NBI)

can be used to grade gastric intestinal metaplasia (GIM). We aimed to externally validate a classification of endoscopic grading of gastric intestinal metaplasia (EGGIM).

Methods Consecutive patients in two centers were submitted to high resolution white-light gastroscopy followed by NBI to estimate EGGIM – a score (0–10) resulting from the sum of endoscopic assessments of GIM, scored as 0, 1, or 2 for no GIM, ≤30%, or >30% of the mucosa, respectively, in five areas (lesser and greater curvature of both antrum and corpus, and incisura). If GIM was endoscopically suspected, targeted biopsies were performed; if GIM was not noticeable, random biopsies were performed according to the Sydney system to estimate the operative link on gastric intestinal metaplasia (OLGIM; the gold standard).

Results 250 patients (62% female; median age 55 years) were included. GIM was staged as OLGIM 0, I, II, III, IV in 136 (54%), 15 (6%), 52 (21%), 34 (14%), and 13 (5%) patients, respectively. All patients with GIM except three were identifiable with targeted biopsies. For the diagnosis of OLGIM III/IV, the area under the ROC curve was 0.96 (95% confidence interval [CI] 0.93–0.98) and by using the cutoff >4, sensitivity, specificity, and positive likelihood ratio were 89%, 95%, and 16.5, respectively; results were similar (91%, 95%, and 18.1) when excluding patients with foveolar hyperplasia.

Conclusions For the first time, an endoscopic approach was externally validated to determine the risk of gastric cancer without the need for biopsies. This can be used to simplify and individualize the management of patients with gastric precancerous conditions.

Introduction

Gastric intestinal metaplasia (GIM) is considered a precancerous condition as it constitutes the background in which dysplasia and intestinal-type gastric adenocarcinoma often develop [1, 2]. The intragastric distribution of precancerous conditions of the gastric mucosa is a determinant of gastric cancer risk as multifocal intestinal metaplasia (IM) affecting the mucosa of the antrum and corpus has been associated with a higher risk of gastric cancer. In patients harboring this condition surveil-

lance at 3-yearly intervals has been recommended by European guidelines [3] and is cost-effective [4].

Several histologic classifications have been developed to stratify risk for pre-neoplastic changes. The operative link on gastric intestinal metaplasia (OLGIM) classification was proposed for the staging of gastritis and to stratify the risk of gastric cancer based on the presence and severity of IM in five biopsy samples: two from the antrum, one from the incisura, and two from the corpus [5]. In a retrospective case-control study including 474 patients with gastric cancer, OLGIM III

(odds ratio [OR] 5.5, 95% confidence interval [CI] 3.38–5.95) and IV (OR 8.91, 95%CI 5.16–15.37) were significantly more common in the gastric cancer group than in the control group [6]; moreover, in a post-hoc analysis, based on 4552 consecutive biopsy sample sets, intraepithelial or invasive neoplastic lesions were significantly more frequent in the high risk stages (OLGIM III and IV) than in the low risk stages (OLGIM 0-II) [7].

Cumulative evidence suggests that electronic chromoendoscopy with narrow-band imaging (NBI) is highly accurate for the diagnosis of precancerous conditions [8,9]. A study conducted in 2012 showed that NBI had accuracy rates higher than 85%–90% for the diagnosis of IM and dysplasia [8] and a recent trial demonstrated that NBI is superior to white-light endoscopy (WLE) in identifying patients with IM [10], showing that NBI is useful for the diagnosis of IM.

More recently, a new type of endoscopic classification has been proposed. The endoscopic grading of gastric intestinal metaplasia (EGGIM) may be used to assess a patient's risk by the endoscopic assessment of IM in the antrum, incisura, and corpus with the use of high resolution (HR) NBI scopes [11,12]. In a post-hoc analysis based on endoscopic images taken from 201 patients in a multicenter study, the diagnostic accuracy of EGGIM compared with OLGIM for the identification of patients with extensive IM was 98%, but this was assessed solely by a single endoscopist [11].

The aim of this study was to formally validate the diagnostic accuracy of EGGIM, using OLGIM as the reference test, for the presence and extension of GIM in a prospective multicenter study and to discuss the need for random biopsies in future guidelines.

Methods

Study design and participants

A prospective study involving two endoscopic academic centers (Italy and Portugal) was conducted. From January 2016 to September 2017, consecutive outpatients undergoing gastroscopy with HR-NBI gastroscopes (GIF-H185 or GIF-HQ190; Olympus) because of upper gastrointestinal (GI) symptoms were included. Exclusion criteria were: known OLGIM; contraindication for biopsies; significant comorbidities (severe heart, pulmonary, or renal failure), given that prolonged procedures

associated with the study protocol would potentially be associated with increased risk without increased benefit in this group; previous gastric neoplasia or surgery; or intolerance of the endoscopic procedure. In the 250 included patients, 1.6% had ulcerative lesions (0.8% early gastric cancer, 0.8% peptic ulcers) and 2.8% had elevated lesions (2% hyperplastic polyps, 0.8% adenomas). These patients were not excluded as both the endoscopic and histologic assessment of GIM was not impaired.

Data collection was planned before the index test and reference standard were performed according to the Standards for Reporting of Diagnostic Accuracy Studies (STARD) statement [13]. Informed consent was obtained from all patients and the study was approved by local ethics committees.

Endoscopic procedures and biopsies

In each center, fully trained endoscopists (Italy: G.E. and S.A.; Portugal: D.L. and P.P.N.) with NBI experience (>100 HR-NBI per year) performed the endoscopies with the patient under pharyngeal anesthesia (xylocaine spray puffs) and/or conscious sedation (midazolam). The interobserver agreement between endoscopists was assessed using the proportion of agreement for the first 20 procedures (0.93).

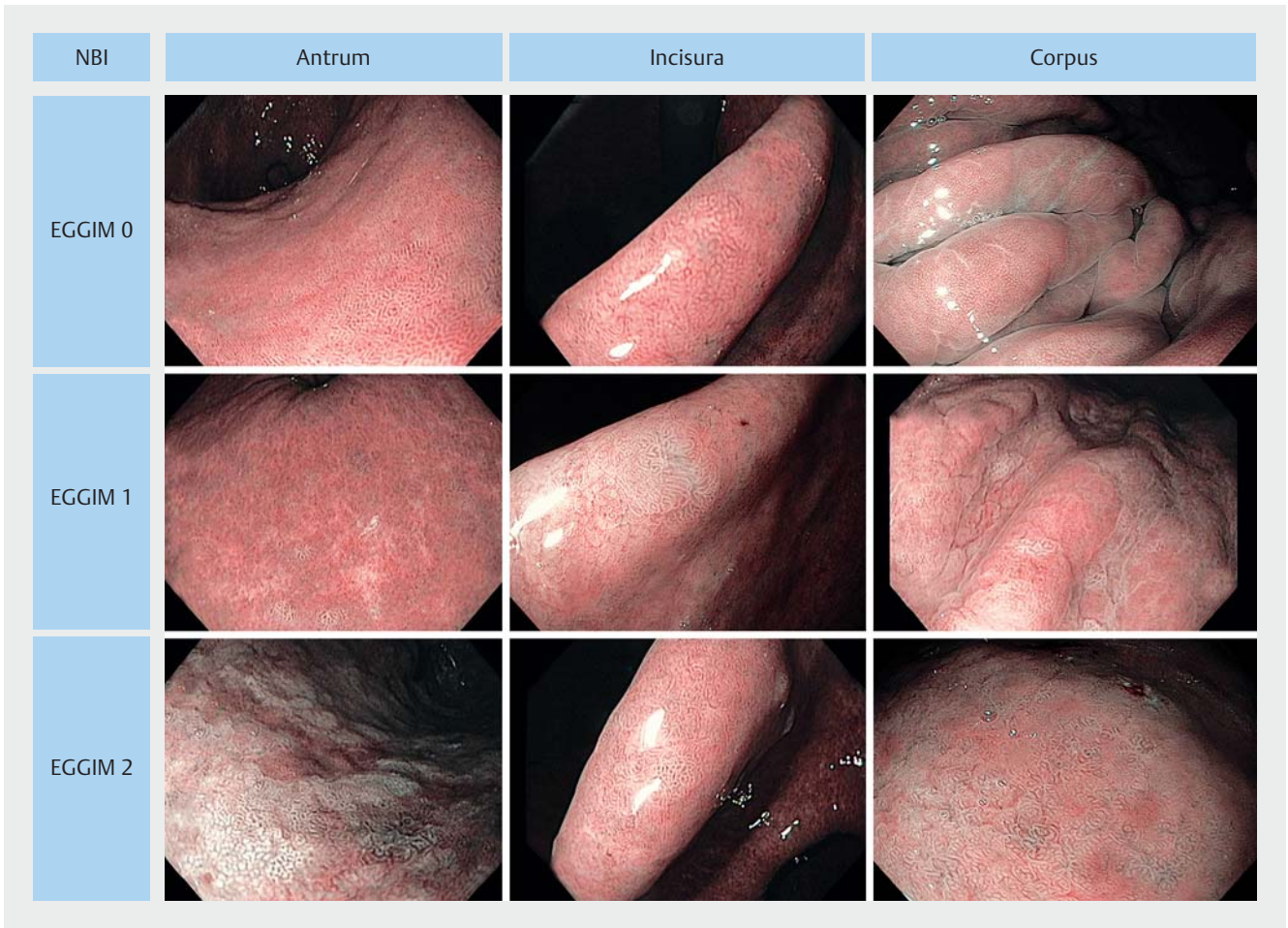
Firstly, detailed observation of the gastric mucosa was undertaken with HR-WLE. Next, HR-NBI observation of the entire gastric mucosa was performed with an accurate evaluation of the mucosa of the antrum, incisura, and corpus. Five different areas were considered: lesser and greater curvature of the antrum, lesser and greater curvature of the corpus, and incisura. In each area scores of 0 (no GIM), 1 (focal GIM, $\leq 30\%$ of the area), or 2 points (extensive GIM $> 30\%$ of the area) were attributed for a total of 10 points (► **Table 1**) [11]. During the evaluation with NBI, the EGGIM score was orally expressed by the operating endoscopist and registered in real-time by a co-worker present during the endoscopic examination. No further changes to these notes were allowed. ► **Fig. 1** shows endoscopic pictures of the EGGIM classification for mucosa in the antrum, incisura, and corpus.

Biopsies were targeted to areas suspicious of IM that were endoscopically recognizable [8]; if GIM was not suspected, random biopsies were taken using the updated Sydney system pro-

► **Table 1** Endoscopic grading of gastric intestinal metaplasia (EGGIM) score: total score varies from 0 (normal endoscopy with no areas suggestive of intestinal metaplasia) to 10 (extensive metaplasia in all gastric areas).

	Antrum		Incisura	Corpus	
	Lesser curvature	Greater curvature		Lesser curvature	Greater curvature
No GIM	0	0	0	0	0
$\leq 30\%$ GIM	1	1	1	1	1
$> 30\%$ GIM	2	2	2	2	2
GIM score	0–4		0–2	0–4	

GIM, gastric intestinal metaplasia.



► **Fig. 1** Example narrow-band imaging (NBI) views of the endoscopic grading of gastric intestinal metaplasia (EGGIM) scores at the greater curvature of the antrum, the incisura, and the greater curvature of the corpus showing: **top row** EGGIM 0, which is normal mucosa (no GIM); **middle row** EGGIM 1, shown by the presence of regular ridge/tubulo-villous mucosa with regular vessels in a small area of the mucosa (focal GIM; $\leq 30\%$ of the area); **bottom row** EGGIM 2, shown by the presence of regular ridge/tubulo-villous mucosa with regular vessels and the presence of light-blue crests in several areas of the mucosa (extensive IM; $>30\%$ of the area).

tolocol [14] and were sent for histopathologic evaluation, with separate vials used for mucosa from the antrum and the corpus.

Histopathologic evaluation

In each center, specimens were evaluated with standard techniques and *Helicobacter pylori* (HP) infection was also evaluated using modified Giemsa staining. Two expert GI pathologists in each center, blinded to the endoscopic diagnosis, reported the final histologic diagnosis according to the updated Sydney system [14] and OLGIM classification [5]. Furthermore, the presence of foveolar hyperplasia was assessed as being potentially associated with false-positive results for IM [15]. OLGIM III/IV was considered the phenotype of interest (i.e. identifying those individuals with extensive IM who were therefore at risk of gastric cancer and merited surveillance).

Statistical analysis

For the sample size calculation, we considered the NBI accuracy shown in previous studies [8, 11]: based on these accuracy values of 90% (95%CI 86%–97%) or 95% (95%CI 90%–99%), 220 or 280 patients would have been required, respectively, with a power of 90% and significance level of 5%.

A descriptive statistical analysis was performed on patients' clinical features and data were expressed as number of total and/or percentage of total, median (interquartile range [IQR]), or mean and standard deviation (SD).

Receiver operating characteristic (ROC) curve analysis was performed [16] to determine the optimal cutoff for EGGIM (index test) when compared to the OLGIM scores (reference standard and dichotomized into OLGIM 0–II and III/IV) obtained by histopathologic evaluation of gastric biopsies. The diagnostic accuracy of EGGIM scores compared to the presence of OLGIM III/IV was expressed as sensitivity, specificity, positive and negative predictive values (PPV and NPV, respectively), and positive likelihood ratio (LR+). False positives were consid-

ered when suspected extensive GIM (OLGIM III/IV) was diagnosed with endoscopy but only OLGIM 0–II was present at histopathologic evaluation. Subgroup analyses of diagnostic performance with respect to the presence of HP infection and/or foveolar hyperplasia were performed.

P values <0.05 were considered statistically significant. Analyses were performed using a software package (version 17.4; MedCalc Software, Mariakerke, Belgium).

Results

Endoscopic and histologic data were available from all included patients, with no indeterminate or missing index test or reference standard data. The 250 included patients had a median age of 55 (IQR 45–68) and 62% of them were women. Detailed clinical characteristics are shown in ► **Table 2**.

► **Table 2** Baseline sociodemographic and clinical characteristics of the 250 patients included.

Sex, female, n (%)	156 (62.4)
Age, median (interquartile range), years	55 (45–68)
BMI, median (interquartile range), kg/m ²	25.1 (22.5–27.1)
Current smokers, n (%)	54 (21.6)
Alcohol, n (%)	18 (7.2)
First degree family member with gastric cancer, n (%)	42 (16.8)
Chronic use of NSAIDs, n (%)	38 (15.2)
Chronic use of proton pump inhibitors, n (%)	90 (36.0)
Previous treatment after non-invasive tests for HP, n (%)	54 (21.6)
Indication for endoscopy, n (%)	
▪ Dyspepsia	69 (27.6)
▪ Reflux disease	34 (13.6)
▪ Anemia	132 (52.8)
▪ Other	15 (6.0)
Histopathology, n (%)	
▪ OLGIM 0	136 (54.4)
▪ OLGIM I	15 (6.0)
▪ OLGIM II	52 (20.8)
▪ OLGIM III	34 (13.6)
▪ OLGIM IV	13 (5.2)
Endoscopic lesions (other than EGGIM)	11 (4.4)

BMI, body mass index; NSAID, nonsteroidal anti-inflammatory drug; HP, *Helicobacter pylori*; OLGIM, operative link on gastric intestinal metaplasia.

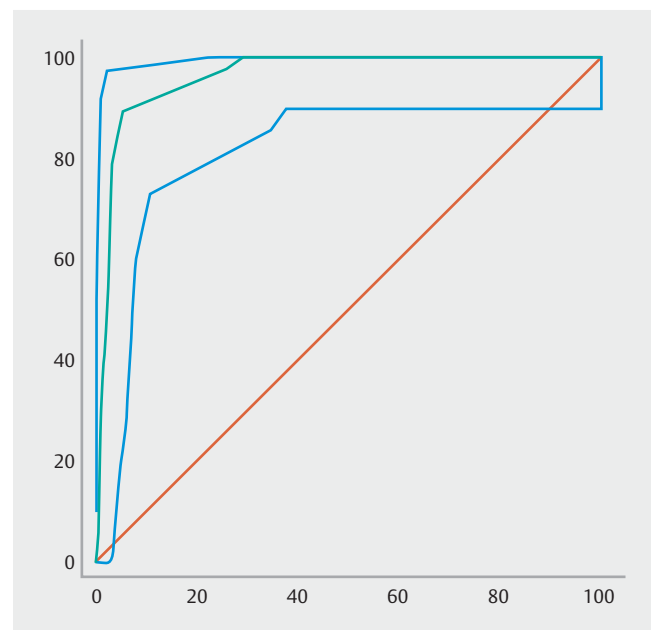
Prevalence of GIM and OLGIM III/IV

GIM was present in 114 patients (45.6%) and it was identified by targeted biopsies in 97.4%. Three patients had GIM diagnosed only by random biopsies. As shown in ► **Table 2**, at pathologic evaluation, 136 patients (54.4%) were staged OLGIM 0; 15 (6.0%) OLGIM I; 52 (20.8%) OLGIM II; 34 (13.6%) OLGIM III; and 13 (5.2%) OLGIM IV. The prevalence of GIM was similar in both centers (43.4% in Italian patients vs. 47.6% in Portuguese patients) but OLGIM III/IV was more prevalent in the Portuguese population (27.6% vs. 9.2%; *P*<0.001).

EGGIM vs. OLGIM

Among the 250 included patients, the EGGIM scores were as follows: 128 patients (51.2%) had EGGIM 0; 16 (6.4%) had EGGIM 2; 7 (2.8%) had EGGIM 3; 46 (18.4%) had EGGIM 4; 9 (3.6%) had EGGIM 5; 18 (7.2%) had EGGIM 6; 11 (4.4%) had EGGIM 7; 9 (3.6%) had EGGIM 8; 2 (0.8%) had EGGIM 9; and 4 (1.6%) had EGGIM 10.

For the presence of OLGIM III/IV, the area under the ROC curve of EGGIM classification was 0.96 (95%CI 0.93–0.98) (► **Fig. 2**). As shown in ► **Table 3**, different cutoffs could be used with high sensitivity and specificity. If a cutoff >4 (i.e. 5–10) is used, the best balance is found – sensitivity, specificity, PPV, NPV, and LR+ would be 89.4% (95%CI 76.9%–96.5%), 94.6% (95%CI 90.5%–97.3%), 79.2% (95%CI 73.6%–84.0%), 97.5% (95%CI 94.4%–98.9%), and 16.5 (95%CI 14.9–18.3), respectively.



► **Fig. 2** The green line represents the receiver operating characteristic (ROC) curve (with 95% confidence intervals; blue lines) for endoscopic grading of gastric intestinal metaplasia (EGGIM) scores compared to operative link on gastric intestinal metaplasia (OLGIM) stages III and IV for the presence of extensive intestinal metaplasia, giving an area under the curve (AUC) of 0.96.

► **Table 3** Accuracy estimates for the diagnosis of OLGIM III/IV according to different cutoffs for the EGGIM score.

Cutoff	Sensitivity (95%CI), %	Specificity (95%CI), %	Positive likelihood ratio (95%CI)	Negative likelihood ratio (95%CI)
>2	100.0 (92.5–100.0)	70.9 (64.2–77.1)	3.4 (3.1–3.7)	0.0 (0.0–0.0)
>3	97.9 (88.7–99.9)	73.9 (67.3–79.8)	3.7 (3.4–4.1)	0.0 (0.0–0.0)
>4	89.4 (76.9–96.5)	94.6 (90.5–97.3)	16.5 (14.9–18.3)	0.1 (0.1–0.1)
>5	78.7 (64.3–89.3)	96.5 (93.0–98.6)	22.8 (19.6–26.5)	0.2 (0.2–0.3)
>6	46.8 (32.1–61.9)	98.0 (95.0–99.5)	23.8 (17.5–32.2)	0.5 (0.4–0.7)
>7	27.7 (15.6–42.6)	99.0 (96.5–99.9)	28.1 (17.7–44.6)	0.7 (0.5–1.2)
>8	10.6 (3.5–23.1)	99.5 (97.3–100.0)	21.6 (9.4–49.5)	0.9 (0.4–2.1)
>9	6.4 (1.3–17.5)	99.5 (97.3–100.0)	13.0 (4.3–38.7)	0.9 (0.3–2.8)

OLGIM, operative link on gastric intestinal metaplasia; EGGIM, endoscopic grading of gastric intestinal metaplasia; CI, confidence interval.

► **Table 4** Endoscopic grading of gastric intestinal metaplasia (EGGIM) score compared to the operative link on gastric intestinal metaplasia (OLGIM) score.

		EGGIM score		
		0	1–4	5–10
OLGIM grade	0	125 (91.9%)	11 (8.1)	0
	I/II	3 (4.5)	53 (79.1)	11 (16.4)
	III/IV	0	5 (10.6)	42 (89.4)
Extent of GIM		Absent	Focal/moderate	Extensive

As shown in ► **Table 4**, 125 out of 128 patients scored as having EGGIM 0 were confirmed as having no GIM (OLGIM 0), whereas in three patients EGGIM misrecognized the presence of GIM (one patient was OLGIM I; two patients were OLGIM II). Out of the 69 patients categorized as having focal/moderate GIM (EGGIM scores 1–4), 53 were confirmed as having focal/moderate GIM by OLGIM (stages I and II in 14 and 39 patients, respectively), while in five patients GIM was classified as extensive by OLGIM (stage III) and in 11 patients the presence of GIM was not confirmed at all by histopathology (OLGIM 0).

Helicobacter pylori infection and foveolar hyperplasia

HP infection was present in 52 patients (20.8%) and 44 of these (84.6%) were correctly staged by the EGGIM score compared to the OLGIM. In the remaining eight patients (15.4%) in which the EGGIM score was discordant from the OLGIM score, there was an overestimation of the EGGIM score in seven (five patients with OLGIM 0 were wrongly staged as focal/moderate and two with OLGIM I/II were staged as endoscopically extensive). If patients with HP infection were excluded, the sensitivity, specificity, and LR+ for extensive IM were not significantly decreased, being 87.2% (95%CI 81.2%–91.7%), 94.3% (95%CI 89.8%–97.1%), and 15.4 (95%CI 13.6–17.5), respectively.

Foveolar hyperplasia was present in 26 patients (10.4%) and 17 of these patients (65.4%) were correctly staged with the EG-

GIM classification. In the remaining nine patients (34.6%), there was an overestimation of the EGGIM score in six (four patients with OLGIM 0 were wrongly staged as focal/moderate and two with OLGIM I/II were staged as extensive). If patients with foveolar hyperplasia were excluded, the sensitivity, specificity, and LR+ for extensive IM were increased (not significantly) to 91.3% (95%CI 86.5%–94.7%), 94.9% (95%CI 90.9%–97.4%), and 18.1 (95%CI 16.4–19.9), respectively.

Discussion

This is the first prospective multicenter study of the real-time use of EGGIM classification to assess both the presence and the extent of GIM, showing a high diagnostic performance compared to OLGIM. The application of the EGGIM classification was conducted in a low risk country (Italy) and in an intermediate-to-high risk country (Portugal) in Western Europe, showing consistency in European countries with different risks for gastric cancer.

In our study, first, all patients with GIM were identified with targeted biopsies, with the exception of three (1%) who were diagnosed by random biopsies. This further supports the ESGE guidelines on advanced imaging [17] and was demonstrated also in a study by Buxbaum et al. where random biopsies were compared with NBI targeted biopsies with no advantage for random biopsies [10]. Second, an endoscopic score for IM

(EGGIM) was externally validated and may be used as the method of choice for diagnosing the extent of GIM, thereby representing a promising decision tool for the identification of patients at risk of gastric cancer who, according to the ESGE's management of precancerous conditions and lesions in the stomach (MAPS) guidelines [3], would need biopsies for staging and follow-up (i. e. those with extensive IM [OLGIM III/IV]). For this reason, a patient during his first gastroscopy may well need staging through targeted biopsies; however, once staged, more biopsies may not be needed during follow-up, unless changes and/or lesions with suspected dysplasia are seen.

With the application of this strategy, a best cutoff for extensive IM of 4 was established, as a score of ≥ 5 would identify 89% of the patients with OLGIM III/IV, in whom surveillance is advised, without the need of biopsies. On the other hand, 11% of the patients with OLGIM III/IV would be allocated to no surveillance with only endoscopic assessment and 5% of the patients with OLGIM 0–II would be allocated to follow-up (► **Table 4**). However, the EGGIM classification permits an endoscopic assessment of the entire gastric mucosa and targeted biopsies yield a higher diagnostic accuracy than the random biopsies on which the OLGIM classification is based.

This diagnostic value was not confounded by HP infection, but special attention should be given to foveolar hyperplasia (see below).

Different cutoffs could be discussed however in different scenarios from those in our study. In ► **Table 5**, we used a range of prevalences [18] (a priori chances for harboring extensive IM) to better explore the clinical outcome of the use of EGGIM. For instance, in low prevalence countries (prevalence of extensive IM of 5%), it is more relevant to consider the NPV. That is, whenever no IM is suspected, no biopsies would be required, except for HP diagnosis. In this scenario, the endoscopic assumption of extensive IM would still require biopsies as the predictive values (a posteriori chance of harboring this pheno-

type) would vary between 15% and 56%. In contrast, for high prevalence settings (patients under surveillance), interestingly the cutoff of 4 may work for both decisions – if a patient shows a score over 4 (i. e. ≥ 5), the need for biopsies would be negligible as the chance of having OLGIM III/IV and therefore the need for surveillance is 94%; and if a patient has a score of 0–4, possibly we would not need biopsies as the probability of needing surveillance is 9%. In an intermediate scenario, again the most useful cutoff is 4 as no biopsies would be required, except for HP diagnosis.

The ESGE guideline on upper GI endoscopy [19] suggests taking at least five pictures of the stomach during gastroscopy. It may be the case that, in the near future, we should also include suspicious areas for GIM (without collection of biopsies) in the final report for future assessment.

In summary, with proper training, simply scoring the mucosa of the antrum, incisura, and corpus during an endoscopy using NBI to give an overall score (and using a cutoff of 4) may be enough to decide whether biopsies are needed to identify patients at risk of gastric cancer. Moreover, this system could also allow gastric biopsies to be sent in a single vial, because the gastric area where mild atrophy or mild GIM could have been missed could be easily recognized by an expert pathologist. In this way, money may be saved in terms of the procedure itself, as well as the costs related to specimen processing and histopathologic interpretation [20], because endoscopic biopsies increase the cost of the procedure itself.

Our study showed that HP infection did not influence the diagnostic performance of EGGIM, while an important confounding factor in the diagnosis of GIM was the presence of foveolar hyperplasia, which caused an overestimation of the presence of GIM. In particular, excluding patients with foveolar hyperplasia, a slight improvement in the sensitivity and specificity of EGGIM compared to OLGIM was noticed. As already reported in a letter to the editor by Pimentel-Nunes et al. [17],

► **Table 5** Predictive values for intestinal metaplasia (95%CI) and need for biopsies, estimated according to different scenarios and different example cutoffs.

Prevalence of intestinal metaplasia [18]	Cutoff for EGGIM	Estimated chance of extensive IM if EGGIM is positive, %	Need for biopsies?	Estimated chance of extensive IM if EGGIM is negative, %	Need for biopsies?
5%	>2	15.3 (11.2–20.5)	Yes	0.0 (0.0–1.9)	No
	>4*	46.5 (40.2–52.9)	Yes	0.5 (0.1–2.6)	No
	>6	55.6 (49.2–61.8)	Yes	2.5 (0.8–5.6)	No
25%	>2	53.4 (47.0–59.7)	Yes	0.0 (0.0–1.9)	No
	>4*	84.6 (79.4–88.7)	No	3.0 (1.2–6.4)	No
	>6	88.8 (84.0–92.3)	No	14.0 (9.8–19.4)	Yes
50%	>2	77.5 (71.7–82.4)	Yes	0.0 (0.0–1.9)	No
	>4*	94.3 (90.4–96.7)	No	9.0 (5.7–13.8)	No
	>6	96.0 (92.5–98.0)	No	33.0 (27.2–39.6)	Yes

CI, confidence interval; EGGIM (Endoscopic grading for gastric intestinal metaplasia); IM, intestinal metaplasia.

* In general, the cutoff of 4 (i. e. separate patients with EGGIM of ≥ 5 vs. 0–4) seems to be most useful, making the performance of biopsies negligible in most scenarios, with the exception of a score of 5–10 in low prevalence countries/settings, where the post-test probability is still very low (46.5%).

endoscopic misdiagnosis could result from the ridge/tubule-villous pattern that foveolar hyperplasia can present. Of course, this pattern is not the only one that leads to a diagnosis of GIM, but even the presence of a light-blue crest is not an assurance of the presence of GIM.

One limitation of our multicenter study could be that all of the endoscopists had significant NBI experience (>100 NBI upper GI endoscopies per year), which may be essential for the correct application of the EGGIM classification, meaning that the feasibility cannot be generalized to all endoscopy units, but only to those units with experience in the use NBI scopes for gastroscopies. Nevertheless, we also showed previously that these features can easily be learned [10, 21]. Another limitation could be that the examinations were performed with different gastroscopes. In Italy, gastroscopies were performed with the GIF-H185, while the GIF-HQ190 was used in Portugal. The difference between the two instruments is that the GIF-HQ190 has dual focus, which permits a closer view of the gastric mucosa. Nevertheless, the use of different gastroscopes did not affect the results, which were similar in the two countries.

In conclusion, this is the first prospective assessment of the EGGIM classification and it showed a high diagnostic performance compared with OLGIM. This approach could be used to simplify the surveillance of these patients by avoiding biopsies. A possible confounding factor leading to overestimation of the presence of IM might be the presence of foveolar hyperplasia, which should be taken into account before final staging is communicated to the patient. This endoscopic diagnostic tool could become a promising instrument for surveillance for gastric cancer. It is not expected that this outcome would be restricted to Olympus scopes and the scopes of other providers may well follow the same trend, as well as developing automated systems that may help in training and/or standardization for follow-up studies.

Competing interests

None

References

- [1] Correa P. Human gastric carcinogenesis: a multistep and multifactorial process – First American Cancer Society Award Lecture on Cancer Epidemiology and Prevention. *Cancer Res* 1992; 52: 6735–6740
- [2] Giroux V, Rustgi AK. Metaplasia: tissue injury adaptation and a precursor to the dysplasia-cancer sequence. *Nat Rev Cancer* 2017; 17: 594–604
- [3] Dinis-Ribeiro M, Areia M, de Vries AC et al. Management of precancerous conditions and lesions in the stomach (MAPS): guideline from the European Society of Gastrointestinal Endoscopy (ESGE), European Helicobacter Study Group (EHSG), European Society of Pathology (ESP), and the Sociedade Portuguesa de Endoscopia Digestiva (SPED). *Endoscopy* 2012; 44: 74–94
- [4] Areia M, Dinis-Ribeiro M, Rocha Gonçalves F. Cost-utility analysis of endoscopic surveillance of patients with gastric premalignant conditions. *Helicobacter* 2014; 19: 425–436
- [5] Capelle LG, de Vries AC, Haringsma J et al. The staging of gastritis with the OLGA system by using intestinal metaplasia as an accurate alternative for atrophic gastritis. *Gastrointest Endosc* 2010; 71: 1150–1158
- [6] Cho SJ, Choi IJ, Kook MC et al. Staging of intestinal- and diffuse-type gastric cancers with the OLGA and OLGIM staging systems. *Aliment Pharmacol Ther* 2013; 38: 1292–1302
- [7] Ruge M, Fassan M, Pizzi M et al. Operative link for gastritis assessment vs operative link on intestinal metaplasia assessment. *World J Gastroenterol* 2011; 17: 4596–4601
- [8] Pimentel-Nunes P, Dinis-Ribeiro M, Soares JB et al. A multicenter validation of an endoscopic classification with narrow band imaging for gastric precancerous and cancerous lesions. *Endoscopy* 2012; 44: 236–246
- [9] Kikuste I, Marques-Pereira R, Monteiro-Soares M et al. Systematic review of the diagnosis of gastric premalignant conditions and neoplasia with high-resolution endoscopic technologies. *Scand J Gastroenterol* 2013; 48: 1108–1117
- [10] Buxbaum JL, Hormozdi D, Dinis-Ribeiro M et al. Narrow-band imaging versus white light versus mapping biopsy for gastric intestinal metaplasia: a prospective blinded trial. *Gastrointest Endosc* 2017; 86: 857–865
- [11] Pimentel-Nunes P, Libanio D, Lage J et al. A multicenter prospective study of the real-time use of narrow-band imaging in the diagnosis of premalignant gastric conditions and lesions. *Endoscopy* 2016; 48: 723–730
- [12] Lage J, Pimentel-Nunes P, Figueiredo PC et al. Light-NBI to identify high-risk phenotypes for gastric adenocarcinoma: do we still need biopsies? *Scand J Gastroenterol* 2016; 51: 501–506
- [13] Cohen JF, Korevaar DA, Altman DG et al. STARD 2015 guidelines for reporting diagnostic accuracy studies: explanation and elaboration. *BMJ Open* 2016; 6: e012799
- [14] Dixon MF, Genta RM, Yardley JH et al. Classification and grading of gastritis. The updated Sydney System. International Workshop on the Histopathology of Gastritis, Houston 1994. *Am J Surg Pathol* 1996; 20: 1161–1181
- [15] Pimentel-Nunes P, Dobru D, Libânio D et al. White flat lesions in the gastric corpus may be intestinal metaplasia. *Endoscopy* 2017; 49: 617–618
- [16] Zweig MH, Campbell G. Receiver-operating characteristic (ROC) plots: a fundamental evaluation tool in clinical medicine. *Clin Chem* 1993; 39: 561–577
- [17] East JE, Vleugels JL, Roelandt P et al. Advanced endoscopic imaging: European Society of Gastrointestinal Endoscopy (ESGE) Technology Review. *Endoscopy* 2016; 48: 1029–1045
- [18] Marques-Silva L, Areia M, Elvas L et al. Prevalence of gastric precancerous conditions: a systematic review and meta-analysis. *Eur J Gastroenterol Hepatol* 2014; 26: 378–387
- [19] Bisschops R, Areia M, Coron E et al. Performance measures for upper gastrointestinal endoscopy: A European Society of Gastrointestinal Endoscopy quality improvement initiative. *United European Gastroenterol J* 2016; 4: 629–656
- [20] Weinstein WM. Mucosal biopsy techniques and interaction with the pathologist. *Gastrointest Endosc Clin N Am* 2000; 10: 555–572
- [21] Dias-Silva D, Pimentel-Nunes P, Magalhães J et al. The learning curve for narrow-band imaging in the diagnosis of precancerous gastric lesions by using Web-based video. *Gastrointest Endosc* 2014; 79: 910–920