

Noninvasive Collateral Flow Velocity Imaging in Acute Ischemic Stroke: Intraindividual Comparison of 4D-CT Angiography with Digital Subtraction Angiography

Nichtinvasive Bildgebung der Füllungsgeschwindigkeit der bestehenden Kollateralen bei akutem Schlaganfall: Intraindividuelle Vergleich der 4D-CTA mit der digitalen Subtraktionsangiografie

Authors

Iris Muehlen¹, Stephan P. Kloska², Philipp Gölitz¹, Philip Hölter¹, Lorenz Breuer³, Hendrik Ditt⁴, Arnd Doerfler¹

Affiliations

- 1 Neuroradiology, Friedrich-Alexander-University of Erlangen-Nuremberg, Erlangen, Germany
- 2 Radiology, Klinikum Furth, Germany
- 3 Neurology, University of Erlangen-Nuremberg, Erlangen, Germany
- 4 Diagnostic Imaging, Computed Tomography, Siemens Healthcare GmbH Forchheim, Bayern, DE, Forchheim, Germany

Key words

cerebral angiography, stroke, 4D-CTA, collateral supply, relative filling time delay, CT angiography

received 13.08.2018

accepted 14.12.2018

Bibliography

DOI <https://doi.org/10.1055/a-0825-6660>

Published online: 21.1.2019

Fortschr Röntgenstr 2019; 191: 827–835

© Georg Thieme Verlag KG, Stuttgart · New York

ISSN 1438-9029

Correspondence

Dr. Iris Muehlen

Neuroradiology, Friedrich-Alexander-University of Erlangen-Nuremberg, Schwabachanlage 6, 91054 Erlangen, Germany

Tel.: ++/49/91 31/44847

iris.muehlen@uk-erlangen.de

ZUSAMMENFASSUNG

Hintergrund Der Kollateralisierungs-Status kann nicht nur qualitativ anhand der morphologischen Ausdehnung der Kollateralen, sondern auch quantitativ anhand der relativen Füllungsverzögerung (rFTD) bestimmt werden. Ziel unserer Studie war es, verschiedene Methoden der nichtinvasiven Darstellung der rFTD, abgeleitet aus der 4D-CT-Angiografie (4D-CTA), mit der digitalen Subtraktionsangiografie (DSA) zu vergleichen und den Zusammenhang zwischen dem funktionellen

und morphologischen Kollateralisierungs-Status zu untersuchen.

Methode Retrospektiv wurden 50 Patienten mit akutem M1-Verschluss, bei denen nach Anfertigung eines multimodalen CTs eine DSA zur mechanischen Re-Kanalisation erfolgte, untersucht. Zur Bestimmung der relativen Füllungsverzögerung im A1-Segment der betroffenen Hemisphäre gegenüber den Mediaästen in der Sylvischen Fissur distal des M1-Verschlusses wurden die 4D-CTA-Datensätze herangezogen. Es wurden zum einen die Rohdaten (4D-CTA-SI), zum anderen eine Prototyp-Software mit farbkodierter Darstellung der Füllungsgeschwindigkeiten (fv-CTA) mit der DSA verglichen. Der morphologische Kollateralisierungs-Status wurde anhand der aus den CT-Perfusionsdaten berechneten zeitinvarianten CTA mithilfe des Collateral Score (CS) ermittelt.

Ergebnisse Die Korrelation der rFTD zwischen der fv-CTA und DSA war sehr gut ($n = 50$, $r = 0,9$, $p < 0,05$). Die Unterschiede zwischen den absoluten rFTD-Werten waren nicht signifikant. 4D-CTA-SI und DSA zeigten ebenfalls eine gute Korrelation ($n = 50$, $r = 0,6$, $p < 0,05$), allerdings unterschieden sich hier die Mittelwerte der rFTD signifikant ($p < 0,05$). Die aus der fvCTA abgeleitete rFTD und der anhand der zeitinvarianten CTA berechnete CS zeigten einen negativen Zusammenhang ($R = -0,5$, $P = 0,000$). Bei den Patienten mit erfolgreicher Re-Kanalisation (TICI 2b/3) bestand eine signifikante negative Korrelation zwischen dem CS und dem mRS nach 3 Monaten ($R = -0,4$, $P = 0,006$).

Schlussfolgerung Der Kollateralisierungs-Status spielt eine bedeutende Rolle für das Outcome bei Schlaganfall-Patienten. Die aus der 4D-CTA abgeleitete rFTD stellt einen adäquaten Parameter zur nichtinvasiven funktionellen Bildgebung des Kollateralisierungs-Status dar und korreliert mit dem morphologischen Kollateralisierungs-Status. Zur Definition valider Schwellenwerte und zur Evaluation der diagnostischen und prognostischen Relevanz sind weitere Studien nötig.

Kernaussagen:

- Anhand der Füllungsgeschwindigkeit der Kollateralen kann der Kollateralisierungs-Status bei akutem Schlaganfall bestimmt werden.
- Die relative Anflutungsverzögerung (rFTD) kann zur quantitativen Bestimmung der Kollateralisierung dienen und korreliert mit dem morphologischen Kollateralisierungs-Status.
- Die 4D-CTA ist hierbei eine adäquate nichtinvasive Bildgebungstechnik.

ABSTRACT

Purpose The collateral status can be defined not only by its morphological extent but also by the velocity of collateral filling characterized by the relative filling time delay (rFTD). The aim of our study was to compare different methods of noninvasive visualization of rFTD derived from 4D-CT angiography (4D-CTA) with digital subtraction angiography (DSA) and to investigate the correlation between functional and morphological collateral status on timing-invariant CTA.

Materials and Methods 50 consecutive patients with acute occlusion in the M1 segment who underwent DSA for subsequent mechanical recanalization after multimodal CT were retrospectively analyzed. 4D-CTA data were used to assess the relative filling time delay between the A1 segment of the affected hemisphere and the sylvian branches distal to the occluded M1 segment using source images (4D-CTA-SI) and color-coded flow velocity visualization with prototype software (fv-CTA) in comparison to DSA. The morphological extent of collaterals was assessed on the basis of the Collateral Score (CS) on temporal maximum intensity projections (tMIP) derived from CT perfusion data.

Results There was very good correlation of rFTD between fv-CTA and DSA ($n = 50$, $r = 0.9$, $p < 0.05$). Differences of absolute rFTD values were not significant. 4D-CTA-SI and DSA also showed good correlation ($n = 50$, $r = 0.6$, $p < 0.05$), but mean values of rFTD were significantly different ($p < 0.05$). rFTD derived from fvCTA and CS derived from timing-invariant CTA showed a negative association ($R = -0.5$; $P = 0.000$). In patients with a favorable radiological outcome defined by a TICI score of 2b or 3, there was a significant negative correlation of CS and mRS at 3 months ($R = -0.4$, $P = 0.006$).

Conclusion Collateral status plays an important role in the outcome in stroke patients. rFTD derived from 4D-CTA is a suitable parameter for noninvasive imaging of collateral velocity, which correlates with the morphological extent of collaterals. Further studies are needed to define valid thresholds for rFTD and to evaluate the diagnostic and prognostic value.

Key points:

- Collateral supply in anterior circulation stroke can be defined by the velocity of collateral filling
- Relative filling time delay (rFTD) can serve for quantitative measurement of collateral flow and correlates with the morphological extent of collaterals
- 4D-CTA is a suitable noninvasive imaging technique

Citation Format

- Muehlen I, Kloska SP, Göllitz P et al. Noninvasive Collateral Flow Velocity Imaging in Acute Ischemic Stroke: Intraindividual Comparison of 4D-CT Angiography with Digital Subtraction Angiography. *Fortschr Röntgenstr* 2019; 191: 827–835

Introduction

Since several endovascular trials (MR Clean, ESCAPE, EXTEND-IA, SWIFT-PRIME) have proven the efficacy of additional endovascular therapy versus standard care alone in acute anterior circulation ischemic stroke, patient selection on the basis of brain imaging has become a major focus of interest [1–4]. The most important challenge is to identify salvageable brain tissue [5–7]. For this reason irreversibly injured brain tissue (“ischemic core”) was distinguished from tissue at risk for infarction (“ischemic penumbra”) through perfusion imaging analysis in the EXTEND-IA and SWIFT PRIME trial. Beyond Penumbra analysis detailed knowledge about tissue perfusion distal to an occlusion through the backfilling of pial arteries receiving blood flow through small inter-arteriolar connections is crucial. ESCAPE is the only one among the above-mentioned trials to take collateral supply under consideration for patient selection even though a number of previous studies have proven the quality of collateral flow to be an independent predictor of clinical and radiologic outcome and treatment success [8–15]. Good collateral flow can maintain the penumbra until reperfusion is reestablished. However, the imaging modalities

and assessment approaches that authors refer to vary significantly [16]. Conventional digital subtraction angiography (DSA), which can reveal retrograde collateral perfusion in a dynamic fashion and which offers excellent temporal and spatial resolution, is the “gold standard” for the assessment of collateral flow, but it is an invasive technique that is usually only performed in case of an endovascular treatment intention [17]. Different scores to assess leptomeningeal collaterals have been described on the basis of DSA [8, 9, 11–15, 18–22]. Also, static CT angiography (CTA) has been widely used for collateral assessment [23–27], but as visualization of the collateral vessel structure is time-dependent and strongly depends on individual anatomic and hemodynamic preconditions, dynamic evaluation approaches have been shown to be beneficial for the identification of the origin of the dominant collaterals and for their precise quantification [10, 28–30]. Moreover, several recently published studies suggest that besides a mere morphological assessment of collaterals, the evaluation of the velocity of collateral filling can serve as an indicator of collateral function [10, 31].

Following the idea of Cao et al., our aim was to evaluate the velocity of collateral flow by measuring the relative filling time

delay (rFTD) distal to an M1 occlusion using time-resolved 4D-CTA. [31] For the assessment of rFTD from 4D-CTA data-source images (4D-CTA-SI) as well as a semi-automated prototype, color-coded flow velocity images (fv-CTA) were used [32]. DSA served as the gold standard [33–35]. The aim of our study was to compare the results of rFTD derived from 4D-CTA-SI and from fv-CTA with DSA and to see whether functional collateral status on the basis of rFTD correlates with the morphological collateral status on the basis of timing-invariant CTA derived from CT perfusion data.

Materials and Methods

Study population

The study was performed in accordance with the ethical standards and institutional review board. Informed consent of the patient or legal representative was obtained in advance according to legal regulations. Our initial cohort consisted of 69 consecutive patients who underwent multimodal CT for acute ischemic stroke and following transfemoral conventional digital subtraction angiography (DSA) for mechanical thrombectomy at our institution between January 2012 and June 2018. We included patients with complete occlusion of the middle cerebral artery (MCA) in the M1 segment on CTA and DSA only. As injection of both carotid arteries and the dominant vertebral artery was not routinely performed because of time-saving issues, we only included patients with an existing A1 segment in the affected hemisphere to use it as a reference vessel for the evaluation of rFTD instead of the contralateral MCA branches [31]. All patients presented to our institution within 4.5 hours of stroke symptom onset. The exclusion criteria included:

1. An aplastic A1 segment of the affected hemisphere
2. Missing whole-brain perfusion source imaging
3. Non-diagnostic image quality, i. e., due to strong motion artifacts
4. Insufficient depiction of the parenchymal and late venous phase on conventional angiography

Three patients had to be excluded because the M1 segment was partially recanalized between initial multimodal CT and following DSA after bridging therapy with intravenous thrombolysis. Another three patients had to be excluded because of strong motion artifacts. Incomplete depiction of the venous phase on DSA obviated reliable assessment of rFTD in ten patients. Aplasia of the A1 segment in the affected hemisphere was found in three patients.

Image Acquisition and Postprocessing

Multimodal Computed Tomography

CT examinations were performed on a 128-section CT scanner (Somatom Definition AS+; Siemens, Forchheim, Germany). All patients underwent a standardized multiparametric CT protocol consisting of non-enhanced CT (NECT) (section thickness: 0.6 mm), whole-brain color-coded perfusion mapping from 4D-CTA (section thickness: 0.6 mm, increment: 0.4 mm) and

arterial phase CTA from the aortic arch to the vertex. Two contrast material injections were performed in each patient (for 4D-CTA and for arterial phase CTA). 4D-CTA (80 kV, 180 mAs, collimation: 128 × 0.6 mm, rotation time: 0.3 s) was acquired with 9.6 cm coverage in the z-axis from the supraorbital skull to the vertex. A total of 30 ml of iodinated contrast agent (Imeron 400; Bracco Imaging, Konstanz, Germany) followed by 50 ml of saline flush was injected via an 18-gauge cannula into a cubital vein at a rate of 5 ml/s using a double-piston power injector (Medtron, Saarbruecken, Germany). Pulsed full-rotation scan beginning 2 s after contrast injection with 35 scans over 60 s was used.

Flow Visualization 4D-CT Angiography (fv-CTA)

Fv-CTA is a pre-released post-processing prototype (flow visualization, syngo.via Frontier, Siemens, Forchheim, Germany) which displays dynamic cerebral CT angiography data sets that combine color-coded information of cerebral vasculature with an indication of absolute delay values of maximum vessel opacification (Tdelay) in a single composite 3-dimensional data set. Fv-CTA is reconstructed from 4D-CTA data. After segmentation, spline interpolation of the calculated arterial input function to the time attenuation curves and bolus parameterization Tdelay is calculated. Tdelay values are then color-coded using the hue saturation value color space. By superimposing the color-coded Tdelay maps over temporal maximum intensity projections (tMIP), composite 3-dimensional color-coded images are generated. Absolute Tdelay values can be easily read from the current mouse position [32].

DSA

DSA was performed on a commercial biplane flat panel detector angiographic system (Axiom Artis dBA, Siemens, Erlangen, Germany) under local or general anesthesia. The 2 D DSA series that were acquired by contrast injection into the proximal internal carotid artery (ICA) of the affected hemisphere with a rate of four frames per second had to be evaluable for collateral flow grading which means that the late venous phase had to be depicted. 10 patients had to be excluded because of missing assessment through the late venous phase. The angiographic series were transferred to a workstation (Leonardo, Siemens, Forchheim, Germany) and automated reconstructions of composite color intensity projections of the injection run were calculated using an FDA-approved application (iFlow, syngo classic, Siemens, Forchheim, Germany) [33–35]. The application combines the information contained in a number of sequential images and depicts the time that contrast media needs to arrive at any location in the brain vasculature in a single image. This postprocessing algorithm is called parametric color coding. Tdelay is also calculated and can be directly read from any point of interest.

Image Assessment

The relative filling time delay (rFTD) was quantified on 4D-CTA-SI, fv-CTA, and DSA. First, three points of interest (ICA (C7 segment), ACA (A1 segment), MCA (M2/M3 branches in the Sylvian fissure distal to the M1 clot) were determined respectively. The differing time of the beginning of the arterial cerebral inflow was equalized by referring to the reference point in the distal ICA. By defining the

difference between maximum opacification in the MCA branches in the Sylvian fissure distal to the occlusion and maximum opacification in the distal ICA as ΔA and the difference between maximum opacification in the A1 segment of the affected hemisphere and maximum opacification in the distal ICA as ΔB , rFTD could be determined as $\Delta A - \Delta B$. As injection of both carotid arteries was not routinely performed because of time-saving issues, we invariably used the A1 segment as the reference vessel instead of the contralateral MCA branches.

The morphological extent of collaterals was evaluated on the basis of a semiquantitative scoring scheme indicating the collateral supply of the occluded territory on a scale from 0–3 (Collateral Score (CS) = 0: complete absence of collateral vessels, CS = 1: collateral supply $\leq 50\%$ and $> 0\%$, CS = 2: collateral supply $> 50\%$ and $< 100\%$, CS = 3: collateral supply 100%). Assessment was performed in accordance with previous studies having shown timing-invariant CTA derived from CT perfusion data to be more sensitive than traditional CTA for evaluating the morphological extent of collaterals [29, 30]. Image data analysis was performed with commercial software (syngo.via CT Dynamic Angio, Siemens, Forchheim, Germany) providing temporal maximum intensity projections (tMIP), which combine all 35 spiral scans and display maximal enhancement over the 60-second scan time for each voxel.

Statistical Analysis

Statistical analysis was performed using commercial software (SPSS 20.0; IBM, Chicago, IL). Results are described as mean \pm standard deviation or as median with interquartile range. The differences of the rFTD values between the different imaging modalities were tested for significance using the two-sided paired t-test. A p-value of ≤ 0.05 was considered statistically significant. Results were graphically depicted using box-and-whisker plots. The Spearman nonparametric rank correlation was used to investigate the relationship between rFTD derived from fv-CTA and collateral status on timing-invariant CTA and to analyze the correlation of CS and mRS at 3 months in patients with successful vessel recanalization.

Results

The mean patient age was 74 ± 11 years with 62% being female. The baseline median pretreatment NIHSS score could be determined in 48 patients with a median of 15 (IQR 12–18). Intravenous rtPA was given to 39 patients (78%). Aside from 18 patients with unclear onset, the mean time between symptom onset and vessel recanalization was 254 ± 94 min. Under consideration of the 'last seen normal' (lsn) time point as onset, the mean time in the whole patient collective was 356 ± 227 min. Successful vessel recanalization was defined by a grade of reperfusion of 2b or 3 on the TICI scale and could be achieved in 46 patients (92%). A favorable clinical outcome was determined by a difference of 3-month mRS and prae-mRS (Δ mRS) of ≤ 2 . The median prae-mRS was 0 (interquartile range: 0–2), and the median 3-month mRS was 3 (interquartile range: 2–5). In two patients the 3-month mRS was

not available because of loss to follow-up. A favorable clinical outcome could be reported in 19 patients (39.6%).

Source data are provided in ► **Table 1**. rFTD could be determined on fv-CTA, 4D-CTA-SI and DSA in 50 cases. The mean rFTD (fv-CTA) was 5.0 ± 3.4 s, the mean rFTD (4D-CTA-SI) was 6.4 ± 3.7 s and the mean rFTD (DSA) was 4.6 ± 3.3 s. The mean difference was 1.5 ± 2.9 s between fv-CTA and 4D-CTA-SI, 0.4 ± 1.6 s between fv-CTA and DSA, and 1.8 ± 3.0 s between 4D-CTA-SI and DSA. With $p < 0.05$ there was good correlation of rFTD between fv-CTA and DSA ($n = 50$, $r = 0.9$, $p < 0.05$) without a significant difference of mean values. 4D-CTA-SI and DSA also showed good correlation ($n = 50$, $r = 0.6$, $p < 0.05$), but the mean values of rFTD were significantly different ($p < 0.05$) (► **Fig. 1**).

► **Fig. 2** shows the 4D-CTA-SI results of a patient with a proximal M1 occlusion of the right hemisphere and a maximum opacification in the distal ICA and in the A1 segment at 22.45 seconds and in the Sylvian fissure at 25.60 seconds with a resulting rFTD of 3.15 seconds.

► **Fig. 3** shows the fv-CTA of the same patient with an rFTD of 3 seconds and ► **Fig. 4** depicts the DSA result of this patient with a resulting rFTD of 2.4 seconds.

The median CS was 3 (range: 1–3; interquartile range: 2–3). There was a significant negative association between rFTD on fvCTA and CS on timing-invariant CTA ($R = -0.5$; $P = 0.000$).

In the dominant fraction of our patient collective with successful vessel recanalization (92%), CS and mRS at 3 months showed a significant negative correlation ($R = -0.4$; $P = 0.006$).

Discussion

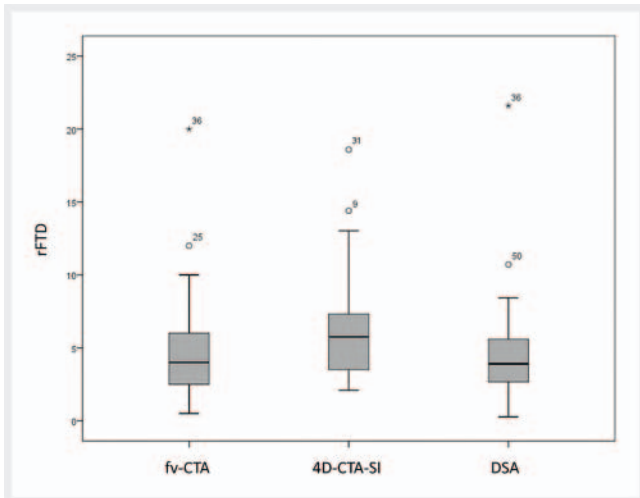
Collateral blood flow plays a key role in the pathophysiology of cerebral ischemia and is an important parameter for outcome prognosis and therapeutic decisions in acute ischemic stroke [8–15], but, due to its complexity, quantification poses a diagnostic challenge. Several previous studies have shown that only a time-resolved analysis can meet the requirements for an integrated survey and that not only the anatomic extent but also the velocity of collateral flow may be relevant for a comprehensive understanding of cerebral hemodynamics [10, 28–31]. The temporal variability of backfilling of pial arteries is an indicator of the functional status of leptomeningeal collaterals and their autoregulatory capacity. Experimental studies have shown that the leptomeningeal collateral network decreases with age. The impaired collateral reserve might be the reason for the increased risk of conversion of penumbra tissue into infarction in elderly patients [36, 37]. Analysis of the relative filling time delay distal to a proximal artery occlusion allows a simple and dynamic evaluation of collateral status in patients with acute anterior circulation stroke. As rFTD derived from 4D-CTA-SI and fv-CTA showed good correlation with DSA, rFTD appears to be a reliable and reproducible parameter to evaluate the velocity of collateral flow. There were no significant differences of quantitative rFTD between fv-CTA and DSA, while quantitative rFTD showed significant differences between 4D-CTA-SI and DSA. As quantitative values depend not only on the imaging method but also on the reconstruction mode, the challenge of proper manual ROI determination in the

► **Table 1** Clinical and radiological source data.

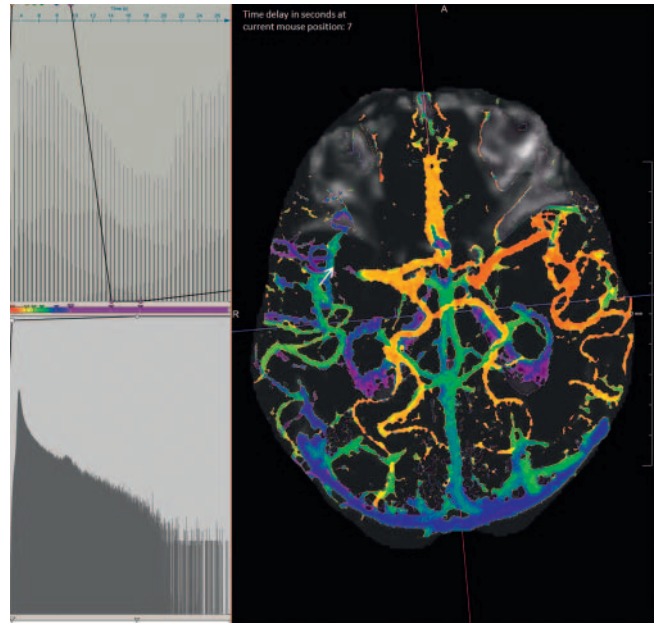
patient	age	sex	occlusion site	NIHSS	rFTD fv-CTA	rFTD CTP-SI	rFTD iFlow	collateral score	IV-lysis	TICI	Prae-mRS	mRS (3 months)	symptom onset to recanalization time (min)	onset unclear
1	80	f	R	15	4.50	13.00	5.33	2	1	3	3	3	218	0
2	70	f	R	14	3.00	2.89	2.94	3	1	2a	0	2	327	0
3	88	f	R	8	3.00	3.15	2.40	3	1	3	3	4	253	0
4	94	m	L	20	5.50	11.77	4.52	3	1	2b	2	3	152	0
5	75	m	R	11	2.50	4.98	0.80	3	1	3	0	2	441	0
6	77	f	R	17	5.00	3.01	4.53	3	1	3	0	4	327	0
7	64	f	R	24	10.00	5.70	5.06	2	1	3	2	5	313	1
8	70	f	L	12	4.00	5.72	4.40	3	1	3	0	2	139	0
9	83	f	L	17	6.00	14.40	6.66	3	0	3	1	3	225	0
10	73	f	R	18	2.50	6.86	4.27	3	0	3	3	3	377	0
11	75	m	R	12	2.50	4.56	2.13	3	1	3	0	2	160	1
12	88	m	L	17	2.00	3.42	2.14	2	1	3	1	6	806	1
13	78	f	L	9	3.50	7.01	1.33	3	1	3	0	2	211	0
14	71	f	R	11	2.00	2.42	1.87	3	1	3	0	1	231	0
15	84	f	L	20	10.00	12.81	5.59	2	1	3	3	6	236	1
16	75	f	L		2.00	6.47	5.85	3	1	3	2	5	466	0
17	55	m	R		2.00	6.50	3.20	3	1	2b	0	4	450	0
18	72	f	R	13	3.00	2.30	3.20	2	1	3	0	2	506	1
19	79	f	L	17	2.00	2.94	3.46	3	1	3	0	3	155	0
20	79	m	L	22	1.50	2.09	2.40	3	1	3	0	5	432	0
21	83	f	L	14	2.50	2.37	0.27	3	1	3	0	3	553	1
22	81	f	L	17	3.50	6.89	2.70	2	0	1	0	5	167	0
23	83	f	R	20	5.50	3.50	3.20	2	1	3	0	5	255	0
24	81	f	R	10	8.00	8.95	8.30	1	1	3	0	4	210	0
25	77	m	L	18	12.00	11.93	7.97	1	1	3	0	3	290	0
26	83	f	R	15	8.00	7.32	6.97	3	1	2a	0	5	707	1
27	81	f	R	15	3.00	3.01	3.56	1	1	2b	3	6	234	0
28	69	f	L	13	2.50	2.86	2.60	3	1	3	0	3	1114	1
29	67	f	L	16	9.00	9.10	8.37	2	1	3	0	3	213	0

▶ Table 1 (Continuation)

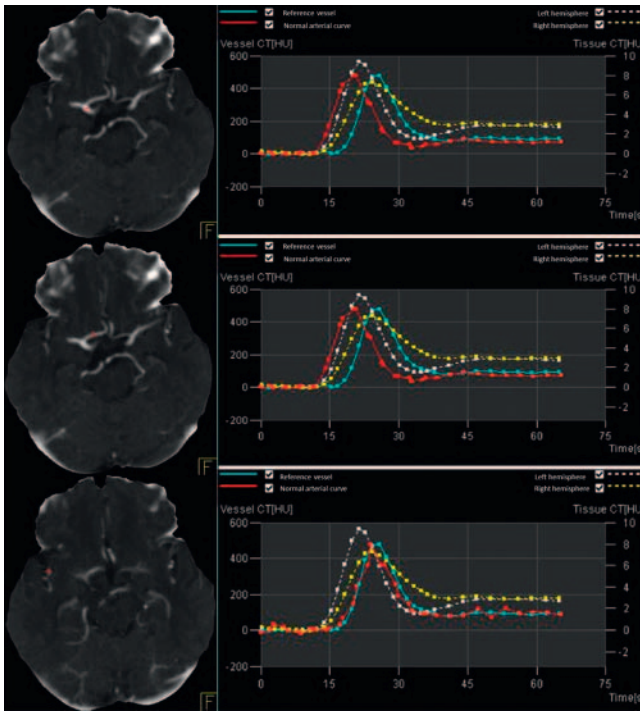
patient	age	sex	occlusion site	NIHSS	rFTD fv-CTA	rFTD CTP-SI	rFTD iFlow	collateral score	IV-lysis	TICI	Prae- mRS	mRS (3 months)	symptom onset to recanalization time (min)	onset unclear
30	75	f	L	12	4.50	6.89	5.53	3	0	3	0	3	345	1
31	42	m	R	16	8.50	18.59	7.72	2	0	3	0	3	1022	1
32	81	f	L	10	4.00	6.04	4.26	3	1	3	0	0	218	1
33	80	m	R	16	5.00	5.76	4.69	3	1	3	0	3	632	1
34	81	m	R	17	3.00	6.19	2.73	2	1	3	2	5	261	0
35	63	m	R	15	4.50	4.31	5.13	2	1	2b	3	4	399	1
36	67	m	R	18	20.00	13.03	21.60	1	1	3	0	2	149	0
37	54	m	R	13	2.50	3.65	2.67	3	1	3	0	1	175	0
38	79	m	L	4	5.00	5.21	4.69	3	0	3	0	1	198	0
39	41	f	R	14	2.00	3.77	2.40	3	1	3	0	1	155	0
40	81	f	R	21	6.50	6.00	7.73	1	1	0	3	6	215	0
41	67	m	R	38	3.50	6.33	3.47	3	0	3	3	5	310	1
42	58	f	L	8	2.00	3.77	3.47	3	1	3	0		306	0
43	74	m	R	12	9.00	8.87	8.43	3	0	3	0	3	461	1
44	89	f	L	19	7.00	9.62	5.67	2	0	3	3	6	650	1
45	74	f	L	15	6.00	5.87	5.06	2	1	3	0	3	380	1
46	76	m	L	5	0.50	2.66	0.80	2	0	2b	0	4	250	0
47	83	f	L	18	3.50	3.65	1.87	3	1	3	0	3	242	0
48	79	m	L	24	5.00	5.53	2.66	1	0	3	0	5	874	1
49	59	m	L	19	6.00	5.75	2.94	2	1	3	0	3	147	0
50	83	f	R	14	9.50	12.64	10.71	2	1	3	2		264	0



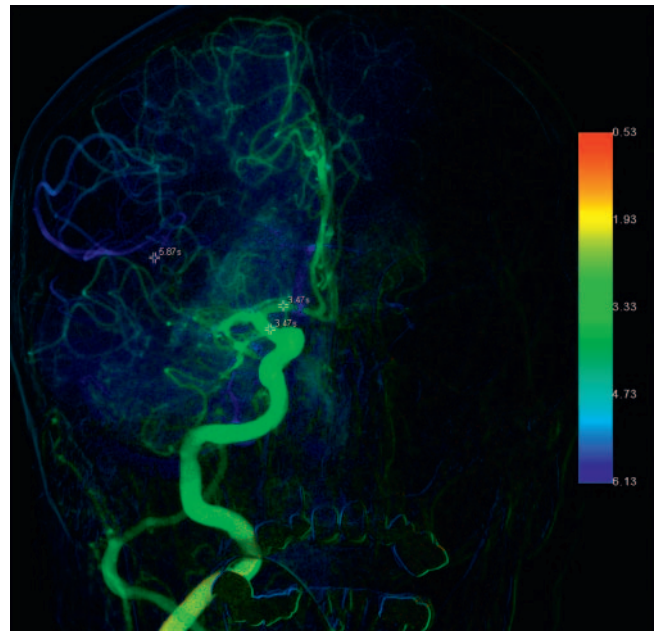
► **Fig. 1** Box plot diagram for the visualization of rFTD results for fv-CTA, 4D-CTA-SI and DSA.



► **Fig. 3** fv-CTA of the same patient as in Fig. 2 with a time delay in the distal ICA and A1 segment of 4 seconds and in the Sylvian fissure of 7 seconds with a consecutive rFTD of 3 seconds.



► **Fig. 2** 4D-CTA-SI results of a patient with a proximal M1 occlusion of the right hemisphere and a maximum opacification in the distal ICA and in the A1 segment at 22.45 seconds and in the Sylvian fissure at 25.60 seconds.



► **Fig. 4** DSA result of the same patient with an rFTD of 2.4 seconds.

Sylvian fissure distal to the occlusion on 4D-CTA-SI might have confounded our results. Diagnostic workup in stroke patients is extremely time-critical. Therefore, an easily evaluable and reliable diagnostic tool for standardized noninvasive assessment of cerebral hemodynamics is all the more important [38, 39]. While manual ROI determination on 4D-CTA is time-consuming depending on the clinician's experience, fv-CTA provides concentrated information on cerebral hemodynamics in a single composite

3-dimensional data set which is calculated automatically and mostly independently from the software's operator and can be easily interpreted [35]. However, with a postprocessing time of 5 to 6 minutes, time reduction would be particularly desirable in the workflow of stroke diagnostics. Furthermore, the color coding might allow clearer visualization of the speed and extent of parenchymal opacification in tissue downstream from the occlusion [33]. Therefore, it might also simplify the quantification of

the morphological extent of collaterals, which we found to be correlated with the functional collateral status. A wider extent of collaterals is associated with a higher flow velocity, reflecting the integrity of the collateral network. Under consideration of the effect of recanalization – a major outcome parameter, we could validate the importance of the collateral network with regard to patient outcome. Higher collateral scores were associated with a lower mRS at 3 months in our patient collective with successful vessel recanalization (TICI 2b or 3).

A scoring scheme combining quantitative and qualitative analysis could be a promising approach for standardized assessment of collateral flow. However, future studies are needed to define thresholds for rFTD in fv-CTA.

With reference to 4D-CTA-SI, Cao et al. already proposed a threshold of rFTD >4 seconds as an indicator of poor prognosis after acute stroke with large vessel occlusion. However, due to the heterogeneity of patient treatment, these results are preliminary and require further evaluation.

Our study has some limitations. Besides the retrospective design with a selected population of patients with acute M1 occlusion, the study carries the risk of having missed potential inflow sources from the posterior circulation on DSA.

Conclusion

The velocity of collateral filling can provide information on collateral function and autoregulatory capacity beyond the morphological extent of collaterals. rFTD derived from 4D-CTA correlates with DSA and allows quantification of collateral velocity. Quantitative rFTD from fv-CTA correlates better with DSA than rFTD from 4D-CTA-SI. Therefore, fv-CTA is a promising noninvasive and widely user-independent post-processing workflow making cerebral hemodynamics easy to analyze. Further studies are needed to define thresholds for rFTD in fv-CTA.

CLINICAL RELEVANCE OF THE STUDY

- Collateral blood flow plays a key role in the pathophysiology of cerebral ischemia and is an important parameter for outcome prognosis and therapeutic decisions in acute ischemic stroke
- Beyond a mere morphological description of collaterals, analysis of the velocity of collateral flow allows dynamic evaluation of collateral function
- Fv-CTA derived from 4D-CTA offers the possibility of non-invasive, semi-automated intuitive analysis of collateral status

Conflict of Interest

The authors declare that they have no conflict of interest.

Acknowledgments

The author Hendrik Ditt is a full-time Siemens employee. The authors of this manuscript declare no other relationships with any companies whose products or services may be related to the subject matter of the article. The authors state that this study has not received any funding.

References

- [1] Berkhemer OA, Fransen PS, Beumer D, MR CLEAN Investigators et al. A randomized trial of intraarterial treatment for acute ischemic stroke. *N Engl J Med* 2015; 372: 11–20. doi:10.1056/NEJMoal1411587
- [2] Goyal M, Demchuk AM, Menon BK, ESCAPE Trial Investigators et al. Randomized assessment of rapid endovascular treatment of ischemic stroke. *N Engl J Med* 2015; 372: 1019–1030. doi:10.1056/NEJMoal1414905
- [3] Campbell BC, Mitchell PJ, Kleinig TJ, EXTEND-IA Investigators et al. Endovascular therapy for ischemic stroke with perfusion-imaging selection. *N Engl J Med* 2015; 372: 1009–1018. doi:10.1056/NEJMoal1414792
- [4] Saver JL, Jahan R, Levy EI et al. SWIFT Trialists. Solitaire flow restoration device versus the Merci Retriever in patients with acute ischaemic stroke (SWIFT): a randomized, parallel-group, non-inferiority trial. *Lancet* 2012; 380: 1241–1249. doi:10.1016/S0140-6736(12)61384-1
- [5] Menon BK, Campbell BC, Levi C et al. Role of Imaging in Current Acute Ischemic Stroke Workflow for Endovascular Therapy. *Stroke* 2015; 46: 1453–1461. doi:10.1161/STROKEAHA.115.009160
- [6] Lee JS, Demchuk AM. Choosing a hyperacute stroke imaging protocol for proper patient selection and time efficient endovascular treatment: Lessons from recent trials. *JoS* 2015; 17: 221–228. doi:10.5853/jos.2015.17.3.221
- [7] Zheng F, Xie W. Imaging-based patient selection and endovascular therapy of ischemic stroke- a stratified meta-analysis. *Medicine (Baltimore)* 2015; 94 (38): e1539. doi:10.1097/MD.0000000000001539
- [8] Bang OY, Saver JL, Buck BH et al. Impact of collateral flow on tissue fate in acute ischaemic stroke. *J Neurol Neurosurg Psychiatry* 2008; 79: 625–629. doi:10.1136/jnnp.2007.132100
- [9] Hwang YH, Kang DH, Kim YW et al. Impact of Time-to-Reperfusion on Outcome in Patients with Poor Collaterals. *AJNR Am J Neuroradiol* 2015; 36: 495–500
- [10] Beyer SE, Baumgarten L, Thierfelder KM et al. Predictive value of the velocity of collateral filling in patients with acute ischemic stroke. *J Cereb Blood Flow Metab* 2015; 35: 206–212. doi:10.1038/jcbfm.2014.182
- [11] Bang OY, Saver JL, Kim SJ et al. Collateral Flow predicts Response to endovascular Therapy for acute ischemic stroke. *Stroke* 2011; 42: 693–699. doi:10.1161/STROKEAHA.110.595256
- [12] Liebeskind DS, Tomsick TA, Foster LD et al. Collaterals at Angiography and Outcomes in the Interventional Management of Stroke (IMS) III Trial. *Stroke* 2014; 45: 759–764. doi:10.1161/STROKEAHA.113.004072
- [13] Christoforidis GA, Mohammad Y, Kehagias D et al. Angiographic Assessment of pial collaterals as prognostic indicator following intra-arterial thrombolysis for acute ischemic stroke. *AJNR Am J Neuroradiol* 2005; 26: 1789–1797
- [14] Liebeskind DS, Jahan R, Nogueira RG et al. Impact of Collaterals on successful revascularization in Solitaire FR with the intenetion for Thrombectomy. *Stroke* 2014; 45: 2036–2040. doi:10.1161/STROKEAHA.114.004781
- [15] Roberts HC, Dillon WP, Furlan AJ et al. Computed tomographic findings in patients undergoing intra-arterial thrombolysis for acute ischemic stroke due to middle cerebral artery occlusion: Results from the PROACT II Trial. *Stroke* 2002; 33: 1557–1565. doi:10.1161/01.STR.0000018011.66817.41

- [16] McVerry F, Liebeskind DS, Muir KW. Systematic review of Methods for Assessing Leptomeningeal Collateral Flow. *AJNR* 2012. doi:doi.org/10.3174/ajnr.A2794
- [17] Higashida RT, Furlan AJ. Trial design and reporting standards for intra-arterial cerebral thrombolysis for acute ischemic stroke. *Stroke* 2003. doi:10.1161/01.STR.0000082721.62796.09
- [18] Galimanis A, Jung S, Mono ML et al. Endovascular therapy of 623 patients with anterior circulation stroke. *Stroke* 2012; 43: 1052 – 1057. doi:10.1161/STROKEAHA.111.639112
- [19] Saito I, Segawa H, Shiokawa Y et al. Middle cerebral artery occlusion: Correlation of computed tomography and angiography with clinical outcome. *Stroke* 1987; 18: 863 – 868
- [20] Al-Ali F, Jefferson A, Barrow T et al. The capillary index score: rethinking the acute ischemic stroke treatment algorithm. Results from the Borgess Medical Center Acute Ischemic Stroke Registry. *J NeuroIntervent Surg* 2013; 5: 139 – 143. doi:10.1136/neurintsurg-2011-010146
- [21] Kim JJ, Fischbein NJ, Lu Y et al. Regional angiographic grading system for collateral flow- Correlation with cerebral infarction in patients with middle cerebral artery occlusion. *Stroke* 2004; 35: 1340 – 1344. doi:10.1161/01.STR.0000126043.83777.3a
- [22] Consoli A, Andersson T, Holmberg A et al. CT perfusion and angiographic assessment of pial collateral reperfusion in acute ischemic stroke: the CAPRI study. *J NeuroIntervent Surg* 2016; 8: 1211 – 1216. doi:10.1136/neurintsurg-2015-012155
- [23] Souza LCS, Yoo AJ, Chaudhry ZA et al. Malignant CTA collateral profile is highly specific for large admission DWI infarct core and poor outcome in acute stroke. *AJNR Am J Neuroradiol* 2012; 33: 1331 – 1336. doi:10.3174/ajnr.A2985
- [24] Miteff F, Levi CR, Bateman GA et al. The independent predictive utility of computed tomography angiographic collateral status in acute ischaemic stroke. *Brain* 2009; 132: 2231 – 2238. doi:10.1093/brain/awp155
- [25] Cheng-Ching E, Frontera JA, Man S et al. Degree of collaterals and not time is the determining factor of core infarct volume within 6 hours of stroke onset. *AJNR Am J Neuroradiol* 2015; 36: 1272 – 1276. doi:10.3174/ajnr.A4274
- [26] Rosenthal ES, Schwamm LH, Roccatagliata L et al. Role of recanalization in acute stroke outcome: rationale for a CT angiogram-based “benefit of recanalization” model. *AJNR Am J Neuroradiol* 2008; 29: 1471 – 1475
- [27] Lima FO, Furie KL, Sliva GS et al. The pattern of leptomeningeal collaterals on CT angiography is a strong predictor of long-term functional outcome in stroke patients with large vessel intracranial occlusion. *Stroke* 2010; 41: 2316 – 2322
- [28] Menon BK, O'Brien B, Bivard A et al. Assessment of leptomeningeal collaterals using dynamic CT angiography in patients with acute ischemic stroke. *J Cereb Blood Flow Metab* 2013; 33: 365 – 371
- [29] Kaschka IN, Kloska SP, Struffert T et al. Clot Burden and Collaterals in anterior circulation stroke: Differences between single-phase CTA and multi-phase 4D-CTA. *Clin Neuroradiol* 2014. doi:10.1007/s00062-014-0359-6
- [30] Smit EJ, Voncken EJ, van Seeters T et al. Timing-invariant imaging of collateral vessels in acute ischemic stroke. *Stroke* 2013; 44: 2194 – 2199. doi:10.1161/STROKEAHA.111.000675
- [31] Cao W, Campbell BCV, Dong Q et al. Relative filling time delay based on CT perfusion source imaging: a simple method to predict outcome in acute ischemic stroke. *AJNR Am J Neuroradiol* 2014; 35: 1683 – 1687. doi:10.3174/ajnr.A3931
- [32] Thierfelder KM, Havla L, Beyer S et al. Color-coded cerebral computed tomographic angiography-Implementation of a convolution-based algorithm and first clinical evaluation in patients with acute ischemic stroke. *Invest Radiol* 2015; 50: 361 – 365
- [33] Cover KS, Lagerwaard FJ, van den Berg R et al. Color intensity projection of digitally subtracted angiography for the visualization of brain arteriovenous malformations. *Neurosurgery* 2007; 60: 511 – 515. doi:10.1227/01.NEU.0000255331.49791.B4
- [34] Strother CM, Bender F, Deuerling-Zheng Y et al. Parametric color coding of digital subtraction angiography. *AJNR Am J Neuroradiol* 2010; 31: 919 – 924. doi:10.3174/ajnr.A2020
- [35] Göllitz P, Kaschka I, Lang S et al. Real-time, in vivo monitoring, and quantitative assessment of intra-arterial vasospasm therapy. *Neurocrit Care* 2015. doi:10.1007/s12028-015-0231-9
- [36] Yamaguchi S, Kobayashi S, Murata A et al. Effect of aging on collateral circulation via pial anastomoses in cats. *Gerontology* 1988; 34: 157 – 164
- [37] Faber JE, Zhang H, Lassance-Soares RM et al. Aging causes collateral rarefaction and increased severity of ischemic injury in multiple tissues. *Arterioscler Thromb Vasc Biol* 2011; 31: 1748 – 1756. doi:10.1161/ATVBAHA.111.227314. Epub 2011 May
- [38] Meretoja A, Keshtkaran M, Saver JL et al. Stroke thrombolysis: save a minute, save a day. *Stroke* 2014; 45: 1053 – 1058
- [39] Kaschka IN, Kloska SP, Struffert T et al. Clinical and radiological outcome after mechanical thrombectomy in acute ischemic stroke: What matters? *Neuroradiol J* 2016; 29: 99 – 105. doi:10.1177/1971400916628170