Published online: 2019-02-21

Magnetic beads-assisted endoscopic submucosal dissection of duodenal heterotopic gastric mucosa with fibrosis

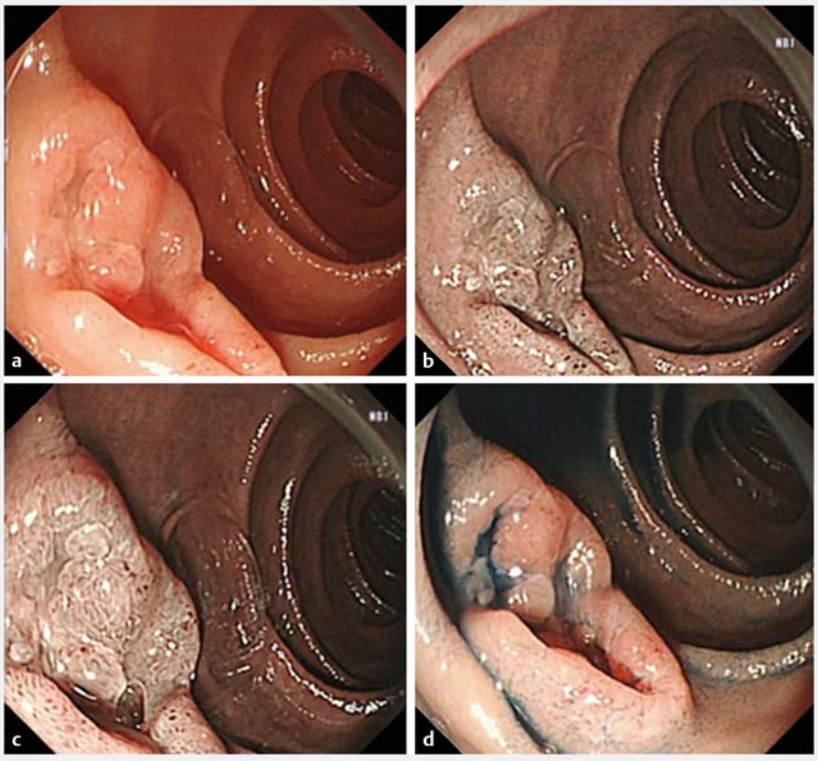

▶ **Fig. 1** Heterotopic gastric mucosa in the duodenum with the appearance of a laterally spreading tumor: **a** white light appearance; **b** narrow band imaging; **c** closer look using narrow band imaging; **d** indigo carmine staining.

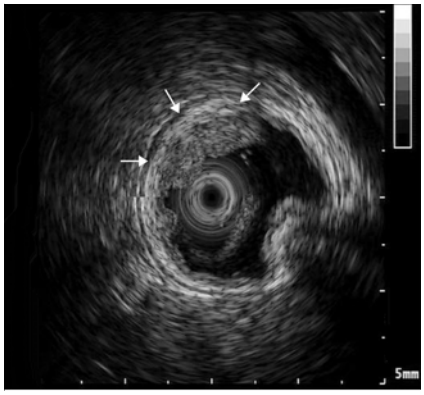

▶ **Fig. 2** Endoscopic ultrasound (EUS) revealed a medium-echo lesion (arrows) in the mucosal layer.

A 53-year-old man was referred to our hospital for full evaluation of the nature of a lesion in the descending duodenum. Upper endoscopy showed a wide-based laterally spreading tumor-like mass (about 15 × 20 mm) with a depression at the top of the lesion (▶ **Fig. 1**). Endoscopic ultrasound (EUS) revealed a medium-echo lesion in the mucosal layer (▶ **Fig. 2**). The biopsy result was inconclusive. Diagnostic endoscopic submucosal dissection (ESD) was attempted. However, despite repeated injections, lifting of the lesion was not satisfactory and the submucosal layer could not be exposed clearly, because of fibrosis (▶ **Fig. 3 a**). Magnetic beads were used to apply traction by gravity. An endoclip was used to attach the thread of a magnetic bead to the edge of the mucosa. When two magnetic beads had been attached, the cutting line was clearly exposed and the lesion was smoothly dissected en bloc (▶ **Fig. 3 b – d**, ▶ **Video 1**).

Histological examination demonstrated the presence of pyloric glands and these glands were positive for MUC5AC and MUC6 (▶ **Fig. 4**). The diagnosis of heterotopic gastric mucosa in the descending duodenum was made, and the patient was discharged uneventfully in 5 days. At 1-month follow-up, the ulcer bed after ESD was seen to be healed (▶ **Fig. 5**).

Heterotopic gastric mucosa in the duodenum can mimic the appearance of a polyps, laterally spreading tumor, submucosal tumor, and so on [1]. In certain cases, ESD is indicated in order to achieve a definitive diagnosis especially when the heterotopic gastric mucosa is large in size. Magnetic beads are a novel traction method that can assist ESD [2].

Endoscopy_UCTN_Code_TTT_1AO_2AG

Competing interests

All authors have no financial relationships relevant to this article or conflicts of interest to disclose.

The authors

Lin Jie Guo[1,*], Liansong Ye[1,*], Zhi Ying Huang[1], Xiaoxue Yin[2], Bing Hu[1]

1 Department of Gastroenterology, West China Hospital, Sichuan University, China
2 Department of Pathology, West China Hospital, Sichuan University, China

* These authors contributed equally.

This document was downloaded for personal use only. Unauthorized distribution is strictly prohibited.

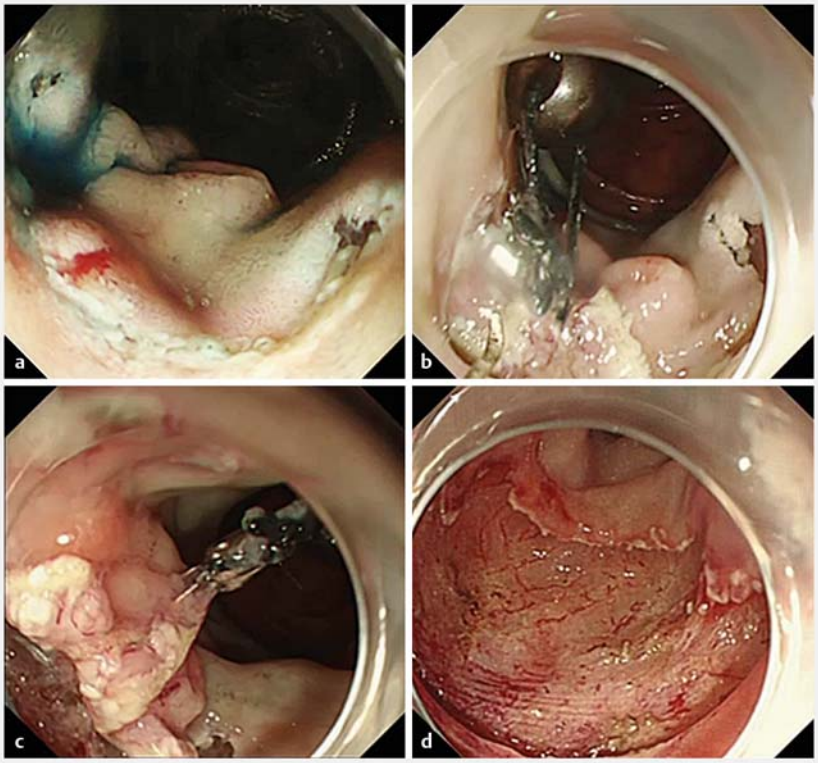

▶ **Fig. 3** Magnetic bead-assisted endoscopic submucosal dissection (ESD). **a** The submucosal layer could not be clearly exposed despite repeated injections. **b** Attachment of one magnetic bead to the edge of the mucosa assisted traction by gravity. **c** A second magnetic bead was then attached for further traction. **d** The ulcer bed after resection.

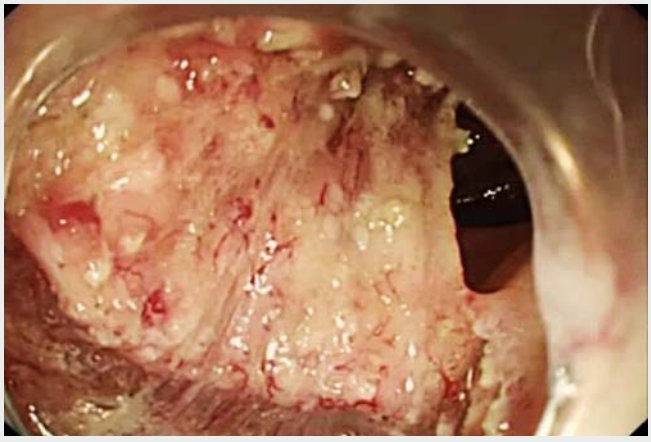

Video 1 Magnetic beads-assisted endoscopic submucosal dissection of duodenal heterotopic gastric mucosa with fibrosis.

Corresponding author

Bing Hu, MD
Department of Gastroenterology, West China Hospital, 37 Guo Xue Xiang, Chengdu 610041, Sichuan, China
Fax: +86-028-85423387
hubingnj@163.com

References

[1] Eguchi K, Aoyagi K, Nimura S et al. Diagnostic value of endoscopic and endoscopic ultrasound characteristics of duodenal submucosal tumour-like heterotopic gastric mucosa. Can J Gastroenterol 2011; 25: 365–367
[2] Bethge J, Ye L, Ellrichmann M et al. Advanced endoscopic submucosal dissection with magnetic bead-assisted traction based on gravity for a flat colorectal neoplasm with severe fibrosis. Endoscopy 2018; 50: 824–825

This document was downloaded for personal use only. Unauthorized distribution is strictly prohibited.

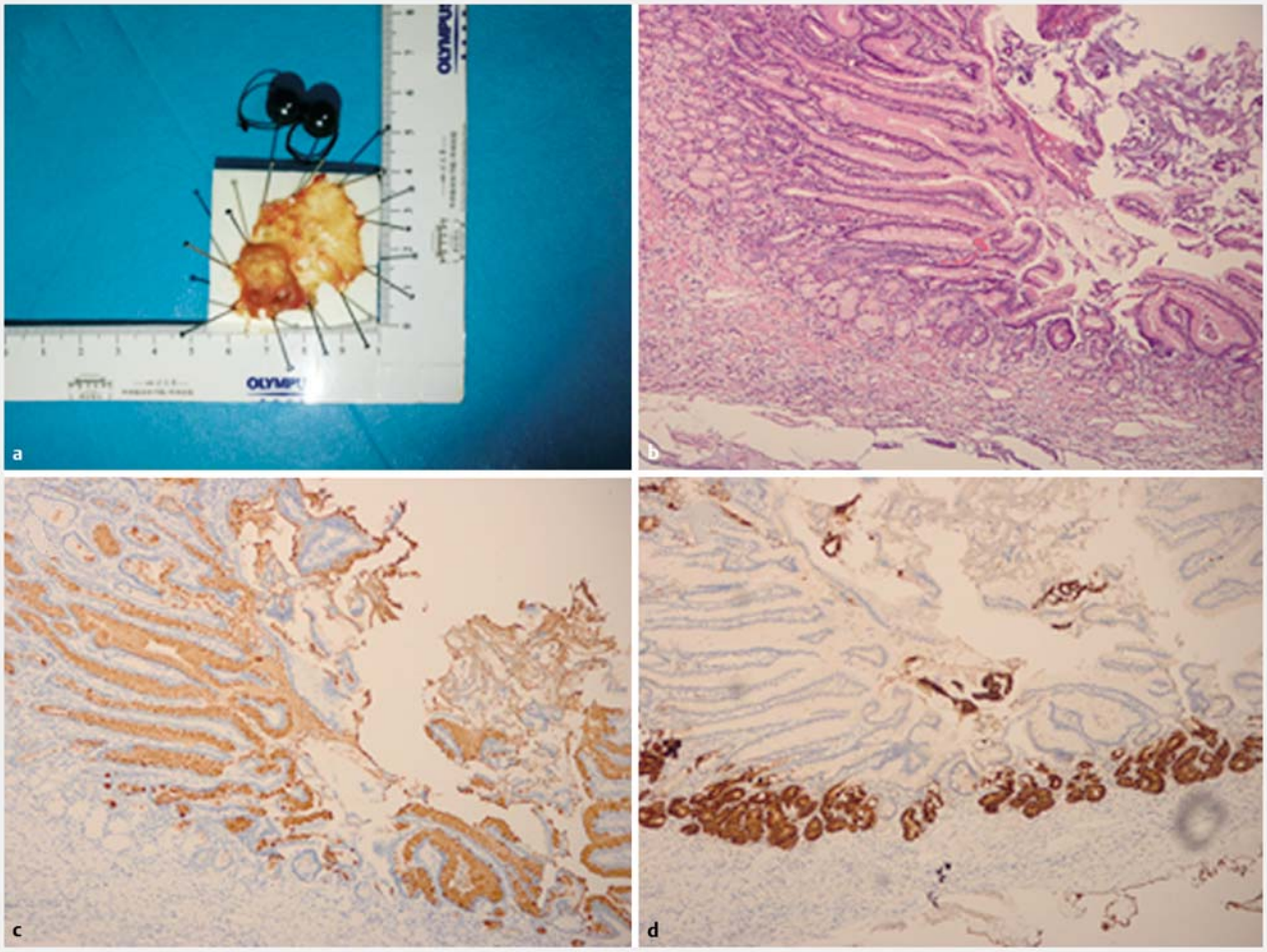

▶ **Fig. 4** Specimen and pathological result. **a** The lesion after complete en bloc resection, with two magnetic beads. **b** Hematoxylin and eosin (H&E) staining showed heterotopic gastric mucosa. **c** Immunohistochemical staining for MUC5AC was positive. **d** Immunohistochemical staining for MUC6 was positive.

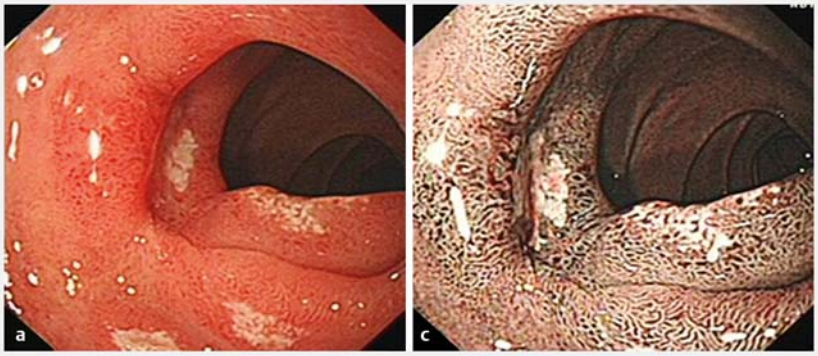

▶ **Fig. 5** The ulcer bed after endoscopic submucosal dissection (ESD) seen at follow-up after 1 month: **a** white light; **b** narrow band imaging.

Bibliography
DOI https://doi.org/10.1055/a-0836-2545
Published online: 21.2.2019
Endoscopy 2019; 51: E113–E115
© Georg Thieme Verlag KG
Stuttgart · New York
ISSN 0013-726X

This document was downloaded for personal use only. Unauthorized distribution is strictly prohibited.