Published online: 2019-05-02

Danger hidden underneath: a rare esophageal subepithelial lesion

A 54-year-old woman was admitted because regular gastroendoscopy incidentally revealed an 8-mm subepithelial lesion 30 cm from the incisors (▶ **Fig. 1**). Magnifying narrow-band imaging (NBI) showed regular intrapapillary capillary loops, several of which showed slight dilatation (type A) (▶ **Fig. 2**). Lugol's iodine staining and ultrasound gastroscopy yielded negative findings. Endoscopic biopsy revealed several scattered heterocyst clusters. Positron emission tomography-computed tomography did not indicate metastasis.

Endoscopic submucosal dissection (ESD) was performed for further diagnosis and treatment (▶ **Video 1**). Microscopically, the lesion was covered with normal epithelium (▶ **Fig. 3 a**). Several poorly differentiated squamous carcinoma cells with dense lymphoplasmacytic infiltration were distributed in the mucosal lamina propria and muscularis mucosa (M3) (▶ **Fig. 3 b**), consistent with lymphoepithelioma-like carcinoma (LELC). In situ hybridization for Epstein-Barr virus showed negative findings. In addition, a dermoid cyst was identified in the muscularis mucosa (▶ **Fig. 4**). At 3 months post-ESD, the ESD wound had healed well without distant metastasis.

Esophageal LELCs are rare and characterized by poorly differentiated carcinoma with prominent lymphocytic infiltration covered with normal epithelium [1]. Epstein-Barr virus positivity is common but not necessary for diagnosis. Esophagectomy and adjuvant chemoradiotherapy are traditional treatments [2]. Complete removal of early-stage LELC by ESD without distant metastases or recurrence has only been reported once [1]. Dermoid cysts, benign cutaneous tumors of ectoderm origin, have not been found in the esophagus [3]. Squamous cell carcinoma arising from a cranial dermoid cyst has only been reported by Tsugu et al. [4], indicating malignant potential of dermoid cysts, especially of those co-existing with squamous cell carcinoma. To our knowledge, this is the first report of co-existing primary LELC and dermoid cyst in the esophagus, indicating that LELC and dermoid cysts have appearances similar to benign subepithelial lesion on gastroscopy, even with the help of Lugol's iodine staining, magnifying NBI, and ultrasound gastroscopy. Endoscopists are encouraged to perform regular biopsies for differential diagnosis.

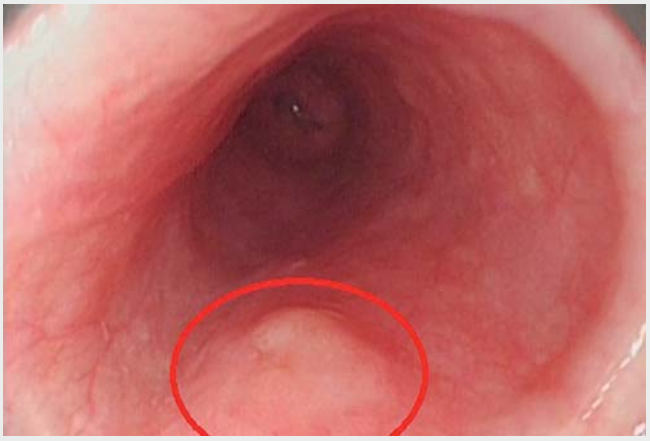

▶ **Video 1** Gastroscopy showing a subepithelial lesion. Submucosal dissection was performed. Histological results revealed a lymphoepithelioma-like carcinoma and a dermoid cyst.

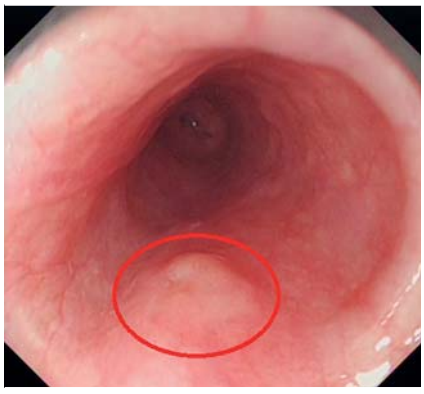

▶ **Fig. 1** Gastroscopy revealed an 8-mm subepithelial lesion (circled) 30 cm from the incisors.

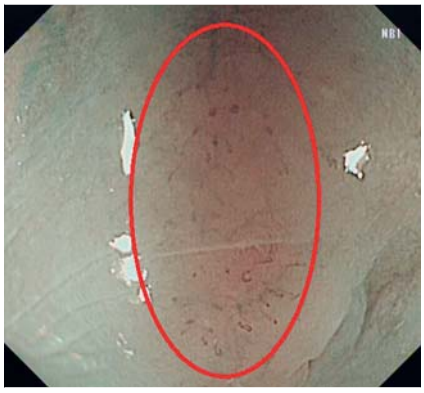

▶ **Fig. 2** Magnifying narrow-band imaging showed regular intrapapillary capillary loops (circled), several of which showed slight dilatation.

Endoscopy_UCTN_Code_CCL_1AB_2AC_3AB

Competing interests

None

This document was downloaded for personal use only. Unauthorized distribution is strictly prohibited.

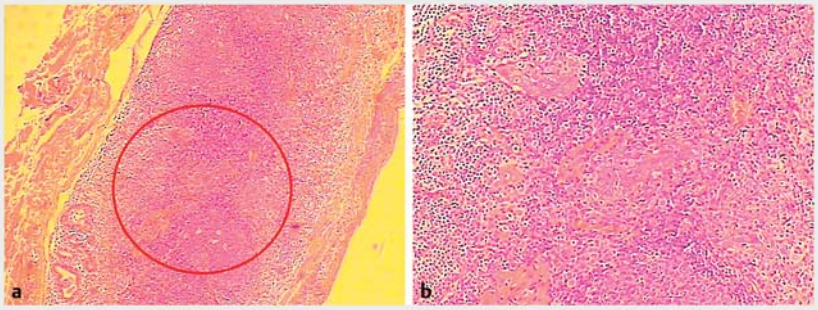

▶ **Fig. 3** Histopathological section from endoscopic submucosal dissection sample showed lymphoepithelioma-like carcinoma (LELC). **a** The LELC was covered with normal epithelium. **b** The LELC was composed of poorly differentiated squamous carcinoma cells with dense lymphoplasmacytic infiltration (hematoxylin and eosin stain).

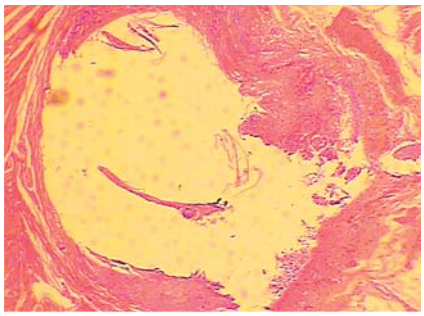

▶ **Fig. 4** Histopathological section revealed a dermoid cyst lined with squamous epithelium and containing hair follicles (hematoxylin and eosin stain).

The authors

Yan Jin[1], Liang Chengbo[1], Wen Qiuyuan[2], Tan Yuyong[1], Liu Deliang[1]

1 Department of Gastroenterology, The Second Xiangya Hospital, Central South University, Changsha, China

2 Department of Pathology, The Second Xiangya Hospital, Central South University, Changsha, China

Corresponding author

Liu Deliang, MD
Department of Gastroenterology, The Second Xiangya Hospital, Central South University, 139 People's Road, Changsha, Hunan, 410011, P. R. China
Fax: +86-50352057
deliangliu@csu.edu.cn

References

[1] Pinn DM, D'Souza LS, Mannan AA et al. A rare case of non-Epstein–Barr virus-associated lymphoepithelioma-like carcinoma of the esophagus treated with endoscopic submucosal dissection. Gastrointest Endosc 2016; 83: 471 – 472

[2] Khokhar N, Nasir H, Amir M et al. Lymphoepithelioma-like carcinoma of the esophagus: a rare tumor. J Coll Physicians Surg Pak 2017; 27: S114 – S116

[3] Paradis J, Koltai PJ. Pediatric teratoma and dermoid cysts. Otolaryngol Clin North Am 2015; 48: 121 – 136

[4] Tsugu H, Fukushima T, Hayashi S et al. Squamous cell carcinoma arising in an intracranial dermoid cyst – case report. Neurol Med Chir (Tokyo) 2001; 41: 213 – 216

Bibliography
DOI https://doi.org/10.1055/a-0885-9840
Published online: 2.5.2019
Endoscopy 2019; 51: E225–E226
© Georg Thieme Verlag KG
Stuttgart · New York
ISSN 0013-726X

ENDOSCOPY E-VIDEOS
https://eref.thieme.de/e-videos

Endoscopy E-Videos is a free access online section, reporting on interesting cases and new techniques in gastroenterological endoscopy. All papers include a high quality video and all contributions are freely accessible online.

This section has its own submission website at https://mc.manuscriptcentral.com/e-videos

This document was downloaded for personal use only. Unauthorized distribution is strictly prohibited.