

# Endoscopic ultrasound-guided placement of coils and cyanoacrylate embolization in refractory gastric variceal bleeding: a pediatric case report




## Authors

Juan I. Olmos, Roberto Oleas, Juan A. Alcívar, Jorge Baquerizo-Burgos, Carlos Robles-Medranda

## Institution

Gastroenterology and Endoscopy Division, Instituto Ecuatoriano de Enfermedades Digestivas (IECED), Guayaquil, Ecuador

submitted 22.1.2019

accepted after revision 20.3.2019

## Bibliography

DOI <https://doi.org/10.1055/a-0915-9532> |  
Endoscopy International Open 2019; 07: E1061–E1063  
© Georg Thieme Verlag KG Stuttgart · New York  
eISSN 2196-9736

## Corresponding author

Carlos Robles-Medranda, MD, Endoscopy Division, Instituto Ecuatoriano de Enfermedades Digestivas- IECED, Av. Abel Romero Castillo y Av. Juan Tanca Marengo, Torre Vitalis, Mezzanine 3, Guayaquil, Ecuador  
Fax: +59342109180  
[carlosoakm@yahoo.es](mailto:carlosoakm@yahoo.es)

## ABSTRACT

**Background and study aims** Gastric variceal bleeding management is challenging, especially in the pediatric population. Endoscopic cyanoacrylate glue injection is considered the standard for management of gastric varices but it is associated with a high rebleeding rate. Endoscopic ultrasound (EUS)-guided placement of coils with cyanoacrylate is a newly available technique with a lower rebleeding rate but there are no reported cases using this technique in pediatric patients. We report on a 12-year-old child with liver cirrhosis and gastric variceal hemorrhage who was refractory to the endoscopic cyanoacrylate injection and in whom hemostasis was achieved without rebleeding following EUS-guided coiling and cyanoacrylate injection. Neither rebleeding nor varix reappearance was noted on 12-month follow-up. EUS-guided coiling and cyanoacrylate injection is safe and feasible in pediatric patients and could be considered as rescue therapy for treatment of refractory gastric variceal bleeding.

## Introduction

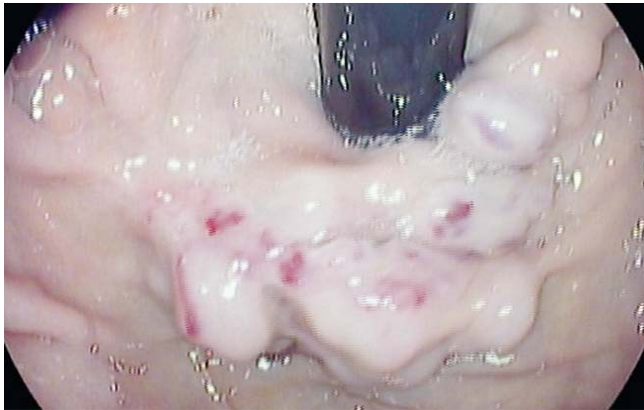Gastric varices (GVs) are a significant complication of portal hypertension in children. Endoscopic injection of glue is considered the standard for management of gastric variceal hemorrhage with a high hemostasis rate [1]. However, rebleeding due to necrosis and ulceration at the sclerosing site or late bleeding secondary to an incomplete obliteration or extrusion of glue is described in 10% to 14% of patients [2, 3].

Available endoscopic options for recurrent and rebleeding GV are scarce. Endoscopic ultrasound (EUS)-guided placement of coils represents a new technique for management of GV bleeding in these patients [4]. Nevertheless, there are no reports on use of this technique in pediatric patients. In this case report, we detail EUS-guided coil placement with cyanoacrylate injection for management of gastric variceal bleeding after two failed endoscopic cyanoacrylate injections in a 12-year-old patient.

## Case report

A 12-year-old child with the history of cryptogenic liver cirrhosis who was awaiting a liver transplantation was admitted to our unit due to recurrent upper gastrointestinal bleeding. The Model End-Stage Liver Disease (MELD) score of the patient was nine points. Despite two endoscopic sessions of glue injection with N-2 butyl-cyanoacrylate injection at another center, gastroesophageal varix (GOV) type I (Sarin and Kumar classification) remained (**▶ Fig. 1**). On admission, after adequate fluid resuscitation, an intravenous infusion of 0.02 mg/kg terlipressin was maintained. The patient's hemoglobin level was 8.4 mg/L. Her liver and renal function tests were within normal limits.

After obtaining informed consent from her parents within 24 hours of hemodynamic stability, and due to the patient's history of nonresponse to cyanoacrylate injection via upper endoscopy, she underwent EUS-guided placement of coils with cyanoacrylate injection using a linear array echoendoscope (Pentax EG-3870UTK) attached to a Hitachi Avius ultrasound

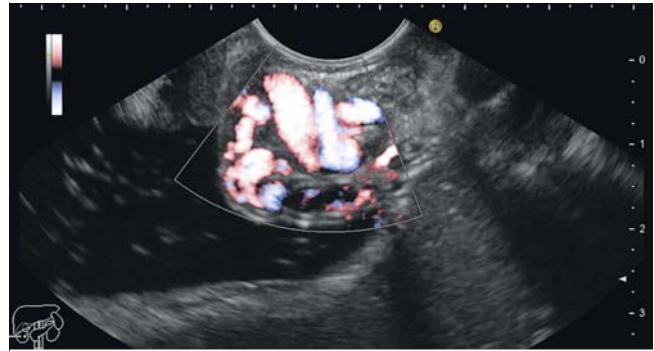


► **Fig. 1** Endoscopic view of type 1 gastroesophageal varices in accordance to the Sarin classification.

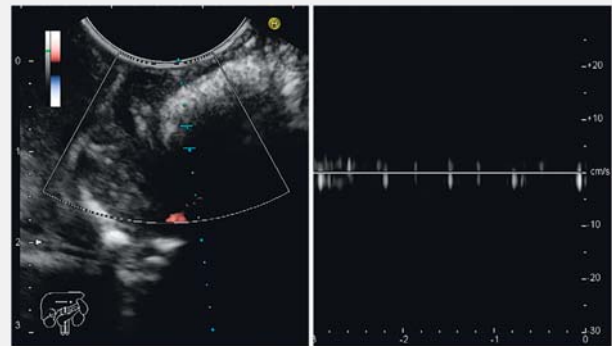
console (► **Video 1**). The endoscopic procedure was performed with the patient under general anesthesia with tracheal intubation and mechanical ventilation.

After identification of GV via EUS Doppler flow (► **Fig. 2**), 200 mg of intravenous ciprofloxacin was given as antibiotic prophylaxis. Transesophageal EUS-directed intravascular puncture of the GV was performed using a 19G-FNA needle (Expect; Boston Scientific, Marlborough, Massachusetts, United States) and two 10-mm Nester Embolization Coils (Cook Medical, Bloomington, Indiana, United States) were deployed, followed by injection of 1.2 mL of 2-Octyl-CYA (Dermabond; Ethicon, Piscataway, New Jersey, United States) (► **Video 1**). Absence of flow during EUS Doppler evaluation of the index gastric varices after the procedure was noted (► **Fig. 3**).

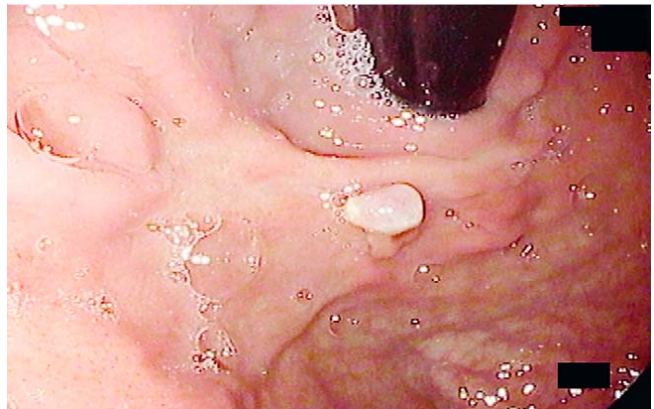
Primary endoscopic hemostasis was achieved with normalization of vital signs and no hemoglobin drop, need for blood transfusion, or incidence of hematemesis or melena, or rebleeding within 48 hours of gastric varix obliteration. On follow-up via upper endoscopy and EUS evaluation 1 month after the index procedure, complete eradication of the GV was observed. Neither rebleeding nor need for reintervention occurred during the 12-month follow-up period (► **Fig. 4**).



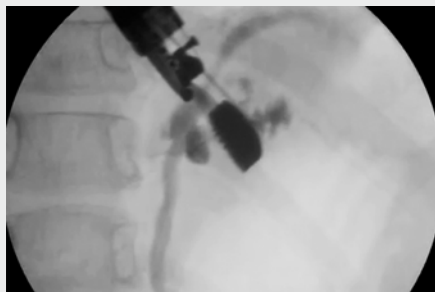► **Fig. 2** Endoscopic ultrasound evaluation of gastric variceal flow using color Doppler.



► **Fig. 3** Absence of flow during EUS Doppler evaluation of the index gastric varices after EUS-guided coiling and cyanoacrylate injection.



► **Fig. 4** Endoscopic view of the gastric varices 12 months after EUS-guided therapy.



► **Video 1** Endoscopic ultrasound-guided placement of coils and cyanoacrylate embolization in refractory gastric variceal bleeding.

## Discussion

Acute variceal hemorrhage secondary to rupture of gastric varices is a life-threatening event in children due to the volume and severity of bleeding, with high rebleeding, mortality, and morbidity rates. Management of GV hemorrhage is challenging, requiring a high level of expertise in endoscopy and interventional radiology techniques. Studies regarding management of GV bleeding in the pediatric population are limited.

Endoscopic gastric varix obliteration with direct injection of N-butyl-2-cyanoacrylate into the varix, transjugular intrahepatic portosystemic shunt (TIPS), and balloon-occluded retrograde transvenous obliteration (B-RTO) are alternatives for treatment of GV hemorrhage; however, these techniques require skillful endoscopic and radiological expertise. Moreover, cyanoacrylate injection through standard gastroscopes is associated with a 25% to 50% rebleeding rate [5], and even death secondary to glue embolism has been reported [6, 7].

The Baveno VI consensus suggests use of N-butyl-2-cyanoacrylate for treatment of IGTV and GOV-2, but no definitive recommendations exist, and data regarding the safety and efficacy of N-butyl-2-cyanoacrylate in management of bleeding gastric varices in children are scarce [8, 9]. After failed obliteration of GV with endoscopic injection of cyanoacrylate, alternatives are limited in the pediatric population. EUS-guided transesophageal-transcaval variceal targeting with combined coil and 2-octyl-cyanoacrylate embolization represents a novel approach in adults with excellent results [10]. This approach was safe and feasible in this pediatric case, without any reported adverse events, and complete obliteration and varix disappearance was achieved [5].

Emergent shunt surgery, TIPS, and B-RTO are not available options in our center, and hemostasis in our patient was imperative. We preferred 2-octyl-cyanoacrylate over N-butyl-cyanoacrylate because the former has a similar efficacy for hemostasis but also has longer polymerization time, allowing a longer injection time and reducing risk of endoscope damage. It also does not require dilution with Lipiodol (which makes injection more difficult due to viscosity) [8].

EUS-guided embolization with coils and cyanoacrylate might be more beneficial because less glue is required, reducing risk of embolization and increasing the procedure success and obliteration rate in adults. No AEs were reported after the procedure or during the 12-month follow-up period in this patient. EUS-guided coil and cyanoacrylate embolization was a safe and effective technique for treating GV hemorrhage in this pediatric patient and might be considered as rescue therapy for GV hemorrhage in pediatric cases.

## Competing interests

---

None

## References

---

- [1] Rivet C, Robles-Medrand C, Dumortier J et al. Endoscopic treatment of gastro esophageal varices in young infants with cyanoacrylate glue: a pilot study. *Gastrointest Endosc* 2009; 69: 1034–1038
- [2] Kamani L, Ahmad BS, Arshad M et al. Safety of endoscopic N-Butyl-2-Cyanoacrylate injection for the treatment of bleeding gastric varices in children. *Pak J Med Sci* 2018; 34: 1363–1368
- [3] Poddar U, Borkar V, Yachla S et al. Endoscopic management of bleeding gastric varices with N-butyl,2-cyanoacrylate glue injection in children with non-cirrhotic portal hypertension. *Endosc Int Open* 2016; 4: E1063–E1067
- [4] Jun CH, Kim KR, Yoon JH et al. Clinical outcomes of gastric variceal obliteration using N-butyl-2-cyanoacrylate in patients with acute gastric variceal hemorrhage. *Korean J Intern Med* 2014; 29: 437–444
- [5] Binmoeller K, Weilert F, Janak N et al. EUS-guided transesophageal treatment of gastric fundal varices with combined coiling and cyanoacrylate glue injection. *Gastrointest Endosc* 2011; 74: 1019–1025
- [6] Roy JM, Rajesh A, Mathew J et al. Endoscopic ultrasound-guided coil or glue injection in post-cyanoacrylate gastric variceal re-bleed. *Indian J Gastroenterol* 2018; 37: 153–159
- [7] Kok K, Bond RP, Duncan IC et al. Distal embolization and local vessel wall ulceration after gastric variceal obliteration with N-butyl-2-cyanoacrylate: a case report and review of the literature. *Endoscopy* 2004; 36: 442–446
- [8] Robles-Medrand C, Valero M, Autran J et al. Endoscopic-ultrasound guided coil and cyanoacrylate embolization for gastric varices and the roles of endoscopic Doppler and endosonographic varicealography in vascular targeting. *Digestive Endoscopy* 2019; doi:10.1111/den.13305
- [9] De Franchis R. Baveno VI faculty. Expanding consensus in portal hypertension: Report of the Baveno VI consensus workshop: stratifying risk and individualizing care for portal hypertension. *J Hepatol* 2015; 63: 743–752
- [10] Rickman OB, Utz JP, Aughenbaugh GL et al. Pulmonary embolization of 2-octyl cyanoacrylate after endoscopic injection therapy for gastric variceal bleeding. *Mayo Clin Proc* 2004; 79: 1455–1458