

## Cholangioscopic management of proximally migrated biliary stent using a novel through-the-cholangioscope snare

Endoscopic biliary stenting using plastic or metal stents is an established therapy for the management of biliary obstruction due to benign or malignant disease. Stent migration (proximal or distal) has been reported to occur in 5%–10% of cases [1–3]. Distally migrated stents mostly pass through the intestine without incident, although bowel perforation, fistulas, and gastrointestinal bleeding have been reported. Proximally migrated stents can cause jaundice and cholangitis, and can be tricky to retrieve. Proximal migration is rare with pigtail stents [4]. This video describes the re-

trieval of a proximally migrated pigtail stent using a novel through-the-cholangioscope snare (► **Video 1**).

A 37-year-old woman with choledocholithiasis underwent four conventional endoscopic retrograde cholangiopancreatographies (ERCPs), which were unsuccessful in clearing a large stone from the common bile duct (CBD). Two plastic pigtail stents were inserted and she was referred to our center for cholangioscopy using SpyGlass (Boston Scientific, Marlborough, Massachusetts, USA) and electrohydraulic lithotripsy (EHL).

The first ERCP at our center revealed that one of the pigtail stents had migrated proximally within the CBD (► **Fig. 1**). EHL successfully cleared the large stone. However, attempts to remove the migrated stent using techniques such as balloon placement parallel to the stent with traction retrieval (► **Fig. 2**) and SpyBite forceps (Boston Scientific) were unsuccessful.

At the second ERCP, the SpySnare (Boston Scientific) was introduced through the cholangioscope and manipulated to en-

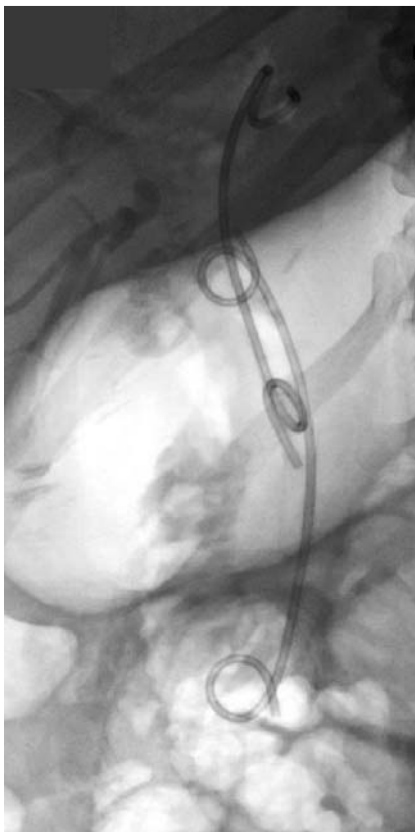
gage the lower end of the pigtail stent. As the stent was embedded within the left intrahepatic duct, significant traction was required to extract the stent; the stent was retrieved successfully.

This is the first case in the UK in which a SpySnare was used to retrieve a migrated stent. Various conventional techniques include balloon placement parallel to the stent with traction retrieval, fluoroscopy-guided use of biopsy forceps, use of a Soehendra stent retriever and wire-guided basket, etc. The newer techniques include using a cholangioscope with various through-the-cholangioscope devices such as SpyBite forceps and SpySnare.

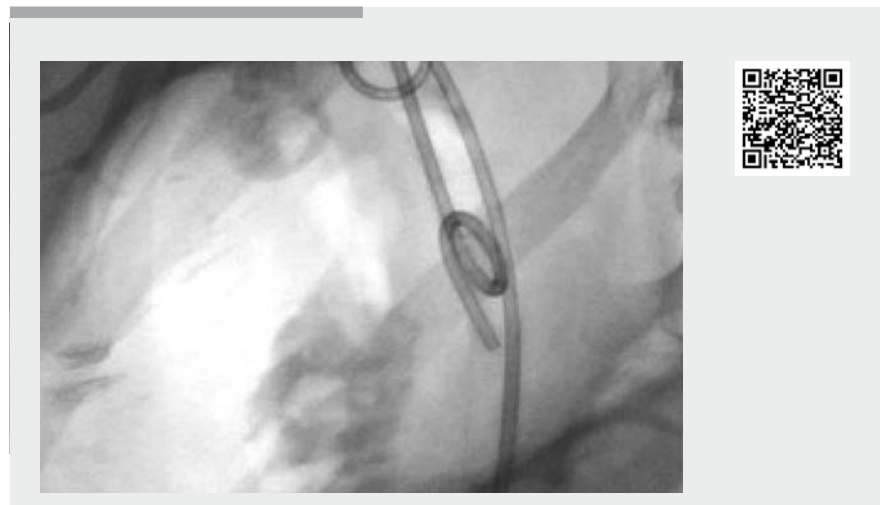
Endoscopy\_UCTN\_Code\_CPL\_1AK\_2AD

### Competing interests

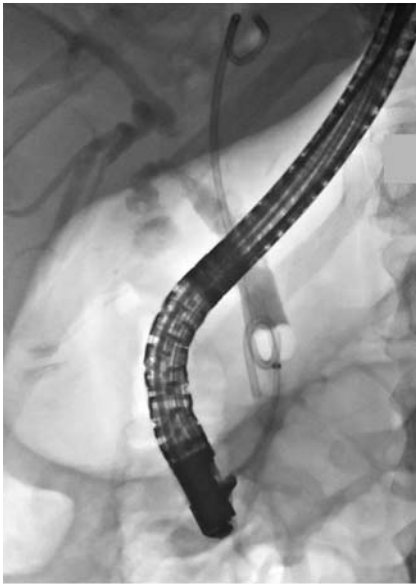Dr. Webster has received honoraria, support for educational meetings, and advisory board fees from Boston Scientific Inc.



► **Fig. 1** Migrated pigtail stent in the common bile duct, with the upper end within the left intrahepatic duct; the transpapillary stent is in the normal position.



► **Video 1** Cholangioscopy-assisted retrieval of a proximally migrated common bile duct stent using a SpySnare (Boston Scientific, Marlborough, Massachusetts, USA).



► **Fig. 2** Balloon placement parallel to the stent with traction retrieval.

## The authors

**Sreelakshmi Kotha<sup>1</sup>, Philip Berry<sup>1</sup>, George Webster<sup>2</sup>, Terry Wong<sup>1</sup>**

- 1 Department of Gastroenterology, Guy's and St Thomas' Hospital, London, United Kingdom
- 2 Department of Pancreaticobiliary Medicine, University College London, London, United Kingdom

## Corresponding author

**Sreelakshmi Kotha, MD**

Department of Gastroenterology, Guy's and St Thomas' Hospital, Westminster Bridge Rd, London SE1 7EH, United Kingdom  
 Fax: +44-20-71887188  
 sreelakshmi\_kotha@yahoo.com

## References

- [1] Namdar T, Raffel AM, Topp SA et al. Complications and treatment of migrated biliary endoprotheses: a review of the literature. *World J Gastroenterol* 2007; 13: 5397 – 5399
- [2] Akbulut S, Cakabay B, Ozmen CA et al. An unusual cause of ileal perforation: report of a case and literature review. *World J Gastroenterol* 2009; 15: 2672 – 2674
- [3] Johanson J, Schmalz M, Geenen J. Incidence and risk factors for biliary and pancreatic stent migration. *Gastrointest Endosc* 1992; 38: 341 – 346
- [4] Barton RJ. Migrated double pigtail biliary stent causes small bowel obstruction. *J Gastroenterol Hepatol* 2006; 21: 783 – 784

## Bibliography

DOI <https://doi.org/10.1055/a-0977-2488>

Published online: 9.8.2019

*Endoscopy* 2020; 52: E5–E6

© Georg Thieme Verlag KG

Stuttgart · New York

ISSN 0013-726X

## ENDOSCOPY E-VIDEOS

<https://eref.thieme.de/e-videos>



*Endoscopy E-Videos* is a free access online section, reporting on interesting cases and new techniques in gastroenterological endoscopy. All papers include a high quality video and all contributions are freely accessible online.

This section has its own submission website at <https://mc.manuscriptcentral.com/e-videos>