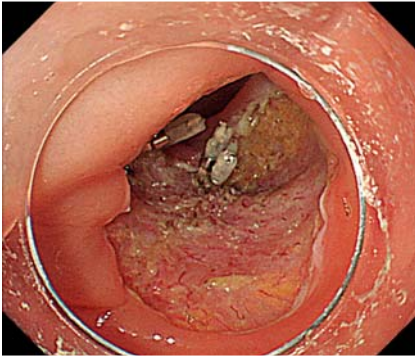
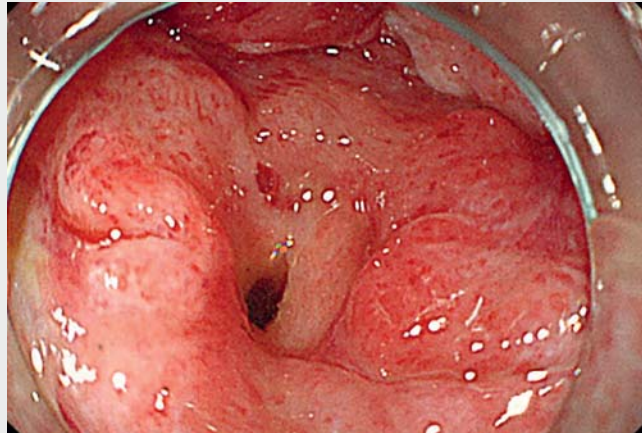


Endoscopic closure using polyglycolic acid sheets for delayed perforation after colonic endoscopic submucosal dissection



► **Fig. 1** Endoscopic view showing no perforation after colorectal endoscopic submucosal dissection.

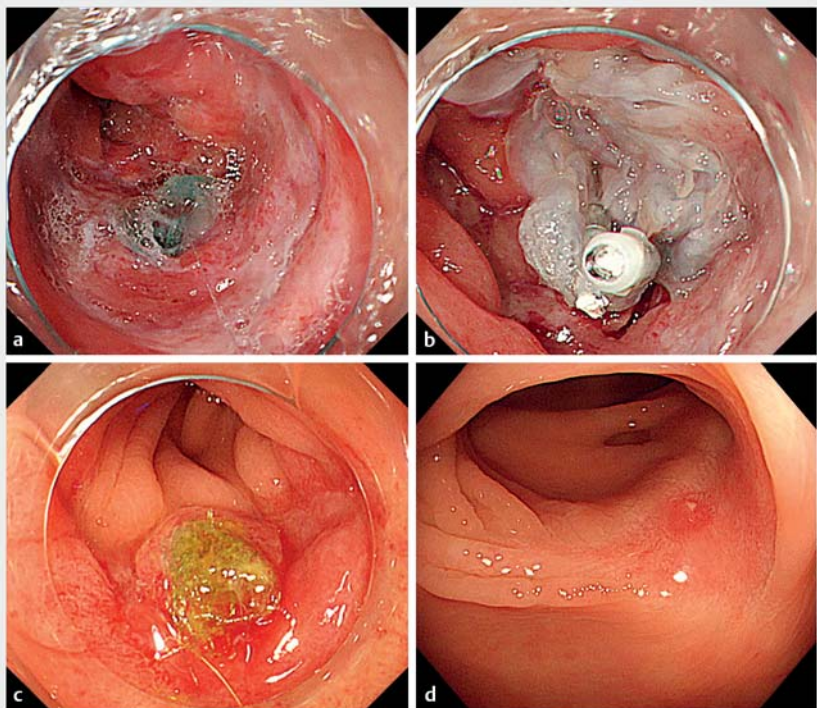


► **Video 1** Endoscopic closure using polyglycolic acid sheets for delayed perforation after colonic endoscopic submucosal dissection.

Recently, polyglycolic acid (PGA) sheets and fibrin glue have been reported to close perforations in several areas of the gastrointestinal tract [1–5]. However, delayed perforation after colonic endoscopic submucosal dissection (ESD) usually requires emergency surgery. We report on a case of delayed perforation after colonic ESD that was treated with PGA sheets and fibrin glue.

An 81-year-old man with a 40 mm laterally spreading tumor in the ascending colon underwent ESD without perforation (► **Fig. 1**). On postoperative Day 2, he had high fever and abdominal pain, and computed tomography showed free air. Conservative treatment with antibiotics improved his symptoms and blood test findings; however, the free air persisted. Colonoscopy revealed a small perforation on the ESD ulcer. Therefore, we attempted to close the perforation through endoscopic closure using PGA sheets and fibrin glue (► **Video 1**).

Initially, the PGA sheet (Neoveil; Gunze, Kyoto, Japan) was cut into 10×10 mm pieces, and then, the perforation site was filled and covered with these pieces using biopsy forceps through the scope channel of a colonoscope (PCF-Q260J; Olympus, Tokyo, Japan) (► **Fig. 2a**). Thereafter, fibrin glue (Beriplast P Combi-Set; CSL



► **Fig. 2** Closure of perforation using polyglycolic acid (PGA) sheets and fibrin glue. **a** The perforation site was covered with small PGA sheets using biopsy forceps through the scope channel of an upper gastrointestinal endoscope. **b** Fibrin glue and endoclips were applied. **c** The perforation site was covered with regenerating tissue 2 weeks later. **d** Endoscopic view showing the ulcer scar 3 months later.

Behring Pharma, Tokyo, Japan) and endoclips were applied (► **Fig. 2 b**).

Two weeks after the procedure, the perforation site was covered with regenerating tissue (► **Fig. 2 c**), and oral intake was initiated. Post-ESD ulcer scarring was observed after 3 months (► **Fig. 2 d**).

The findings of the present case suggest that PGA sheets and fibrin glue can be used to close delayed perforation after colonic ESD.

Endoscopy_UCTN_Code_CPL_1AJ_2AH

Competing interests

None

The authors

Yasuaki Nagami, Shusei Fukunaga, Atsushi Kanamori, Taishi Sakai, Masaki Ominami, Toshio Watanabe, Yasuhiro Fujiwara
Department of Gastroenterology, Osaka City University Graduate School of Medicine, Osaka, Japan

Corresponding author

Yasuaki Nagami, MD

Department of Gastroenterology, Osaka City University Graduate School of Medicine, 1-4-3 Asahimachi, Abeno-ku, Osaka, 545-8585, Japan
Fax: +81-6-66453813
yasuaki1975@hotmail.com

References

- [1] Nagami Y, Shiba M, Arakawa T. Use of PGA sheets in the endoscopic closure of a perforation after endoscopic submucosal dissection for gastric-tube cancer. *Am J Gastroenterol* 2016; 111: 768
- [2] Ono H, Takizawa K, Kakushima N et al. Application of polyglycolic acid sheets for delayed perforation after endoscopic submucosal dissection of early gastric cancer. *Endoscopy* 2015; 47 (Suppl. 01): E18–E19
- [3] Sakaguchi Y, Tsuji Y, Yamamichi N et al. Successful closure of a large perforation during colorectal endoscopic submucosal dissection by application of polyglycolic acid sheets and fibrin glue. *Gastrointest Endosc* 2016; 84: 374–375
- [4] Takimoto K, Hagiwara A. Filling and shielding for postoperative gastric perforations of endoscopic submucosal dissection using polyglycolic acid sheets and fibrin glue. *Endosc Int Open* 2016; 4: E661–E664

- [5] Tonai Y, Takeuchi Y, Akita H et al. Iatrogenic duodenal perforation during underwater ampullectomy: endoscopic repair using polyglycolic acid sheets. *Endoscopy* 2016; 48 (Suppl. 01): E97–98

Bibliography

DOI <https://doi.org/10.1055/a-0978-4501>
Published online: 9.8.2019
Endoscopy 2020; 52: E11–E12
© Georg Thieme Verlag KG
Stuttgart · New York
ISSN 0013-726X

ENDOSCOPY E-VIDEOS

<https://eref.thieme.de/e-videos>



Endoscopy E-Videos is a free access online section, reporting on interesting cases and new

techniques in gastroenterological endoscopy. All papers include a high quality video and all contributions are freely accessible online.

This section has its own submission website at <https://mc.manuscriptcentral.com/e-videos>