

A long (7 cm) prophylactic pancreatic stent decreases incidence of post-endoscopic papillectomy pancreatitis: a retrospective study



Authors

Kazuhiro Minami¹, Eisuke Iwasaki¹, Shintaro Kawasaki¹, Seiichiro Fukuhara², Takashi Seino¹, Tadashi Katayama¹, Yoichi Takimoto¹, Hiroki Tamagawa¹, Yujiro Machida¹, Masayasu Horibe¹, Minoru Kitago³, Haruhiko Ogata², Takanori Kanai¹

Institutions

- 1 Division of Gastroenterology and Hepatology, Department of Internal Medicine, Keio University School of Medicine, Tokyo, Japan
- 2 Center for Diagnostic and Therapeutic Endoscopy, Keio University School of Medicine, Tokyo, Japan
- 3 Division of Hepato-Pancreato-Biliary and Transplant Surgery, Department of Surgery, Keio University School of Medicine, Tokyo, Japan

submitted 21.5.2019

accepted after revision 6.8.2019

Bibliography

DOI <https://doi.org/10.1055/a-1010-5581> |
Endoscopy International Open 2019; 07: E1663–E1670
© Georg Thieme Verlag KG Stuttgart · New York
eISSN 2196-9736

Corresponding author

Takanori Kanai MD, PhD, Chief Professor, Division of Gastroenterology and Hepatology, Department of Internal Medicine, Keio University School of Medicine, 35 Shinanomachi, Shinjuku-ku, Tokyo 160-8582, Japan
Fax: +81-(0)3-3353-6247
takagast@z2.keio.jp

ABSTRACT

Background and study aims Endoscopic papillectomy (EP) is a minimally invasive treatment for ampullary neoplasms and is recognized as an alternative treatment to surgical resection; however, there are few reports on a suitable pancreatic stent (PS) after EP for preventing pancreatitis. The aim of this study was to evaluate the efficacy of a long PS after EP.

Patients and methods In this retrospective single-center study, 39 patients with pathologically proven ampullary neoplasms who underwent EP between March 2012 and August 2018 were enrolled. The study participants were divided into two subgroups according to the PS length: those with a PS shorter than 5 cm (short PS group, n=17) and those with a PS of 7 cm (long PS group, n=22). The incidence of adverse events and risk factors for pancreatitis were evaluated.

Results The diameter of all PSs was 5 Fr. Post-EP pancreatitis occurred in nine patients (23.1%), with two cases of severe pancreatitis (5.1%). Pancreatitis occurred more frequently in the short PS group (7/17, 41.2%) than in the long PS group (2/22, 9.1%) ($P=0.026$). There were no significant differences between the two groups in terms of other adverse events. Univariate and multivariate analyses showed that a long PS was the only factor associated with a decreased incidence of post-EP pancreatitis ($P=0.042$; odds ratio, 0.16; 95% confidence interval, 0.027–0.94).

Conclusion A long (7 cm) PS significantly decreased incidence of pancreatitis after EP. Prospective randomized studies with a larger number of patients and wider range of PS lengths are required.

Introduction

Endoscopic papillectomy (EP) was first reported in Japan in 1983 [1]. Since then, it has been reported that EP has a higher success rate and fewer adverse events compared to open surgery [2–4]. Although resection is typically recommended for ampullary neoplasms even if the tumor is benign, because of

the adenoma-carcinoma sequence [5, 6], EP is currently recognized as an alternative to surgical resection for ampullary neoplasms. However, EP has a potential risk of severe adverse events (AEs), with a procedure-related mortality rate of 0% to 7% [7]. Previous studies have reported that the rate of AEs varies from 8% to 35%, with a bleeding rate of 2% to 16% and a pancreatitis incidence rate of 5% to 15% [8]. Procedure-related

pancreatitis frequently occurs because of pancreatic duct stricture after resection or a direct burn effect in the pancreatic parenchyma.

To date, various methods for EP have been developed for better prevention of AEs, including placement of a pancreatic stent (PS) [9, 10], endoscopic closure using hemoclips for distal-side mucosal defects [11], wire-guided papillectomy [12], and submucosal injection [13]. Despite these efforts, EP remains challenging, and a standard method for EP has not yet been established.

It is well known that PS placement is effective for preventing post-endoscopic retrograde cholangiopancreatography (ERCP) pancreatitis [14, 15]. Furthermore, several studies have shown the efficacy of PS placement after EP [16, 17]. Although the number of patients was low, one randomized controlled trial showed that PS placement after EP significantly reduced frequency of pancreatitis (33% vs 0%, $P=0.02$) [17]. Thus, PS may play a role in improving intra-pancreatic duct pressure and preventing pancreatic duct stenosis due to papillary edema and scarring. However, it remains unclear which PS features (in terms of length, thickness, and form) are optimal in EP. For post-ERCP pancreatitis prevention, a longer and larger PS is recommended, based on previous studies [18, 19]; however, controversy exists, and selecting the type of PS currently depends on the endoscopist's preference. Moreover, the optimal PS length after EP has not yet been considered. Therefore, the aim of the current study was to evaluate outcomes of EP for different PS lengths, focusing on a suitable PS for prevention of pancreatitis.

Patients and methods

Study design and patients

A retrospective observational study was conducted. Patients who underwent EP in our institution between March 2012 and August 2018 were enrolled. The indication for EP was detection of a pathological neoplasm, without pancreatic or biliary invasion, with a tumor diameter <40 mm. Patients with an intraductal papillary mucinous neoplasm (IPMN) were excluded, as it is well-known that an IPMN without a dilated pancreatic head duct is a possible risk factor for pancreatitis after prophylactic pancreatic duct stenting [20]. We classified patients into two groups according to PS length; those with a PS ≤ 5 cm were classified into the short PS group and those with a PS = 7 cm were classified into the long PS group. This study was approved by our institutional review board (20150245).

EP procedure

EP was performed using a therapeutic duodenoscope with a large working channel (TJF260V; Olympus, Tokyo, Japan) (► Fig. 1). After detection of the target lesion, mucosal resection was performed using a standard loop snare (spiral snare forceps; Olympus). The tumor was strangulated, and mucosal resection was performed electrosurgically. Tumor resection was performed in Endocut or Autocut mode (120W, Effect3, ICC200; ERBE Elektromedizin GmbH, Tübingen, Germany). Next, the resected specimen was grasped using a net snare

and removed along with the endoscope. After reinserting the scope, a 0.025-inch guidewire (VisiGlide2; Olympus) was inserted into the biliary and pancreatic tracts via a catheter. Endoscopic biliary sphincterotomy (EST) was then performed and a PS was placed to prevent papillary stenosis. According to American Society of Gastrointestinal Endoscopy guidelines, difficult cannulation was defined as repetitive attempts or prolonged duration before cannulation (>5–10 minutes) [21]. In all cases, the PS was a 5-Fr diameter straight stent with double flanges (Advanix; Boston Scientific Japan, Tokyo, Japan). We used a double-flanged stent to prevent it from spontaneously falling off. Choice of PS length was dependent on operator preference because the most suitable stent length has not been established. If necessary, endoscopic closure was performed on the caudal side using an endoscopic hemoclip (Resolution; Boston Scientific Japan, Tokyo, Japan), as delayed bleeding frequently occurs from the vessels at the base or cut edge on the caudal side of the ulcer [22]. Immediate bleeding was controlled with local injection of hypertonic saline-epinephrine (HSE), hemoclips, argon plasma coagulation (APC), hemostats, and cold water or epinephrine spray.

In all cases, a suppository containing nonsteroidal anti-inflammatory drugs was used after EP to help prevent pancreatitis. Five to 7 days after EP, a second-look endoscopy was performed, and the PS was removed.

Study outcome and definition of adverse events

We defined post-EP pancreatitis in accordance with the consensus definition and classification for procedure-related pancreatitis as reported in the study by Cotton et al. [23]. Delayed bleeding was defined as clinical evidence of bleeding that required endoscopic haemostasis occurring from hours to weeks after the procedure. Perforation was defined based on symptoms and abdominal computed tomography findings. Cholangitis was defined based on findings of a high fever (>38°C) and elevated liver enzymes. Serum amylase level on the day after EP was also obtained.

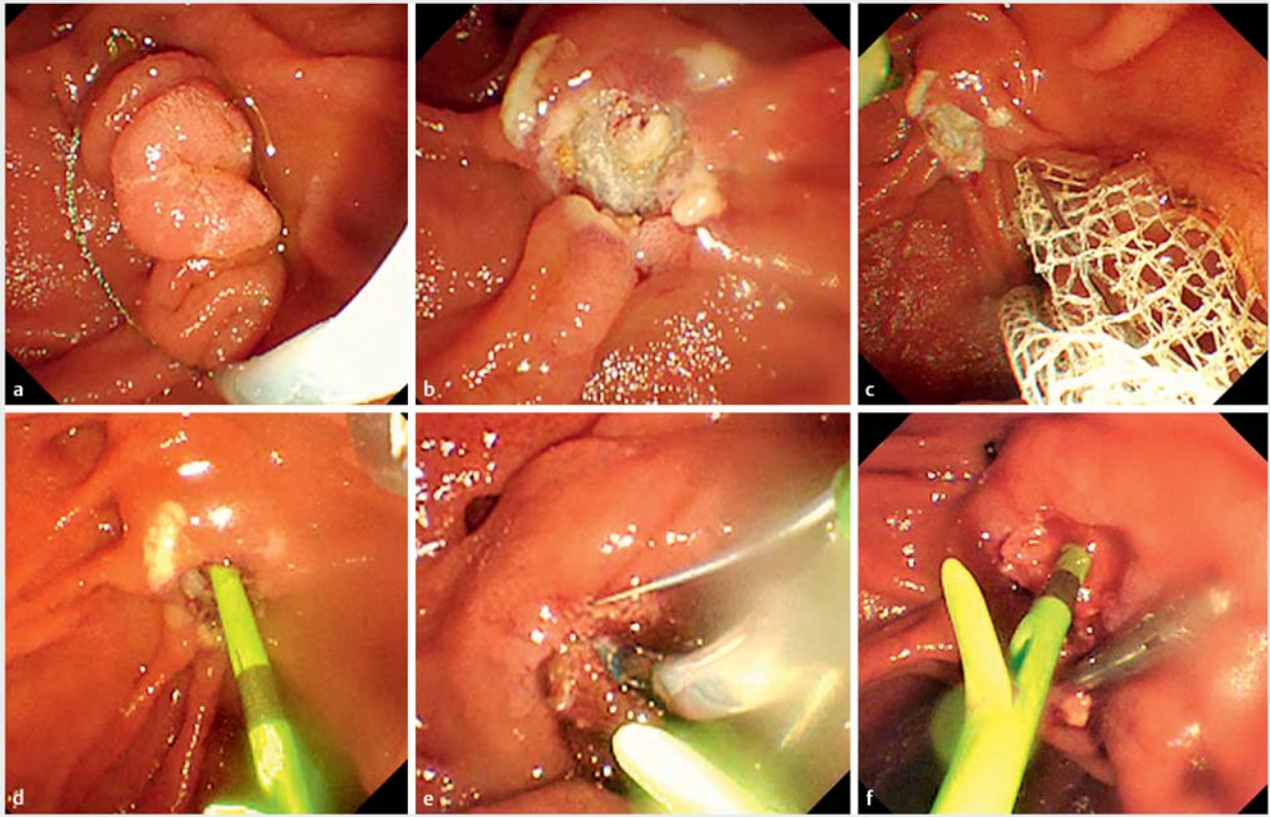
Statistical analysis

Categorical data were compared using the Fisher's exact or chi-square test. Continuous data were compared using the Student's *t*-test or Mann-Whitney U test. PS length, treatment regimen after EP, and several factors recognized as independent risk factors for post-ERCP pancreatitis were evaluated in univariate analyses [21]. In addition, we performed a multivariate logistic regression analysis to identify risk factors for post-EP pancreatitis. $P<0.05$ was considered statistically significant. Statistical analysis was performed using SPSS software version 23.0 (IBM Corp., Armonk, New York, United States).

Results

Patient characteristics

Thirty-nine patients with papillary neoplasm who underwent EP at our institution were included. A PS ≤ 5 cm was placed in 17 patients (short PS group), and a PS = 7 cm was placed in the remaining 22 patients (long PS group).



► **Fig. 1** The procedure of endoscopic papillectomy. **a** Snaring the ampullary tumor. **b** Resection of the tumor electroscopically. **c** Collecting the tumor with a net. **d** Placing a pancreatic stent. **e** Performing endoscopic biliary sphincterotomy. **f** Clipping the ulcer and performing hemostasis.

Patient characteristics are described in ► **Table 1**. For all 39 patients, mean age was 61.5 years, 79.5% were men, and mean tumor size was 13.9 mm. After EP, 33 lesions (84.6%) were diagnosed as adenomas and two lesions were diagnosed pathologically as adenocarcinomas. There were no significant differences between the groups in terms of collected background characteristics. Although not described in the table, there were no patients with prior post-ERCP pancreatitis, suspected sphincter of Oddi dysfunction, or pancreatic sphincterotomy. In addition, there were no patients with chronic pancreatitis, and all patients had a normal serum bilirubin level and underwent a pancreatic injection to cannulate into the duct. These items are known risk factors for post-ERCP pancreatitis [23]. Furthermore, serum amylase levels before EP were normal in all patients.

Outcomes

► **Table 2** lists proportions of AEs according to PS length. Post-EP pancreatitis occurred in nine patients (23.1%), with two cases of severe pancreatitis (5.1%). One patient with severe pancreatitis required invasive treatment, and subsequently recovered. The other patient recovered with conservative treatment alone. The proportion of post-EP pancreatitis was significantly higher in the short PS group (41.2%) than in the long PS

group (9.1%) ($P=0.026$). There were no significant differences between the groups in terms of other AEs and serum amylase levels.

Analysis of risk factors for post-EP pancreatitis

► **Table 3** and ► **Table 4** show results of the univariate and multivariate analyses, respectively. In univariate analyses, PS length was the only factor significantly related to post-EP pancreatitis ($P=0.026$). Given the small number of cases, only two factors – PS length and difficulty of pancreatic duct cannulation – were included in the multivariate analysis. A long (7 cm) PS was the only decreasing factor for post-EP pancreatitis ($P=0.042$; odds ratio, 0.16; 95% confidence interval, 0.027–0.94) in the multivariate analysis.

Discussion

In this retrospective study, the proportion of post-EP pancreatitis cases was significantly lower in patients who received a long PS than in patients who received a short PS (9.1% vs 41.2%, $P=0.026$). Furthermore, in the univariate and multivariate analyses, a long PS was the only factor significantly associated with a decreased risk of post-EP pancreatitis. The current study is the first to evaluate AEs after EP according to PS length, and

► **Table 1** Patient characteristics according to PS length.

Characteristics	Total (n=39)	Short PS (n=17)	Long PS (n=22)	P value
Age (years), mean (SD)	61.5 (10.0)	61.3 (11.9)	61.7 (8.6)	0.91
Sex (men), n (%)	31 (79.5)	12 (70.6)	19 (86.4)	0.26
Tumor size (mm), mean (SD)	13.9 (5.4)	14.5 (4.5)	13.4 (6.1)	0.55
Previous pancreatitis, n (%)	1 (2.6)	0	1 (4.5)	1.00
Difficult pancreatic duct cannulation, n (%)	4 (10.3)	3 (17.6)	1 (4.5)	0.30
Biliary treatment, n (%)				
▪ EST	30 (76.9)	12 (70.6)	18 (81.8)	0.47
▪ Stent placement	6 (15.4)	3 (17.6)	3 (13.6)	1.00
▪ ENBD	4 (10.3)	2 (11.8)	2 (9.1)	1.00
Haemostatic treatment, n (%)				
▪ Clipping	35 (89.7)	15 (88.2)	20 (90.9)	1.00
▪ APC	19 (48.7)	11 (64.7)	8 (36.4)	0.08
▪ HSE	8 (20.5)	2 (11.8)	6 (27.3)	0.43
Pathological diagnosis after EP, n (%)				
▪ Adenoma	33 (84.6)	14 (82.4)	19 (86.4)	1.00
▪ Carcinoma in adenoma	2 (5.1)	0	2 (9.1)	0.50
▪ Adenocarcinoma	2 (5.1)	2 (11.8)	0	0.18
▪ Hyperplasia	2 (5.1)	1 (5.9)	1 (4.5)	1.00

APC, argon plasma coagulation; ENBD, endoscopic nasobiliary drainage; EST, endoscopic sphincterotomy; EP, endoscopic papillectomy; HSE, hypertonic saline-epinephrine; PS, pancreatic stent; SD, standard deviation

► **Table 2** Outcomes of EP according to PS length.

Outcomes	Total (n=39)	Short PS (n=17)	Long PS (n=22)	P value
Post-EP pancreatitis, n (%)	9 (23.1)	7 (41.2)	2 (9.1)	0.026
▪ Severe pancreatitis, n (%)	2 (5.1)	1 (5.9)	1 (4.5)	1.00
Delayed bleeding, n (%)	8 (20.5)	4 (23.5)	4 (18.2)	0.71
Cholangitis, n (%)	1 (2.6)	1 (5.9)	0	0.44
Perforation, n (%)	2 (5.1)	0	2 (9.1)	0.50
Papillary stenosis, n (%)	2 (5.1)	0	2 (9.1)	0.50
Post-EP amylase (U/L), median (range)	171 (61–3140)	257 (61–3140)	147 (73–1168)	0.23

EP, endoscopic papillectomy; PS, pancreatic stent

the results reveal the efficacy of a long PS (7 cm) for prevention of post-EP pancreatitis.

As mentioned in the introduction, it is well known that PS placement is effective for preventing post-ERCP pancreatitis. However, several reports have shown that dislocation of a prophylactic PS can occur, which might result in delayed-onset pancreatitis due to secondary obstruction of flow [24]. However, actual rates of PS dislocation and migration after ERCP in previous reports are not very high (4.9%–5.2%) [25, 26]. Furthermore, most studies reporting AEs following PS placement

comprise only case reports [27–30]. Therefore, in conventional ERCP, many doctors consider the possibility of PS dislocation as a relatively unimportant problem compared to the efficacy of PS placement.

In contrast, rates of PS dislocation and migration after EP remain unclear. Thus far, our study is the first to show the relationship between PS length and post-EP pancreatitis. We presume that the stability of a short PS may be lost after EP because the sphincter of Oddi was resected together with the ampullary neoplasm (► **Fig. 2**). Therefore, a short PS might easily

► **Table 3** Risk factors for post-EP pancreatitis (univariate analysis).

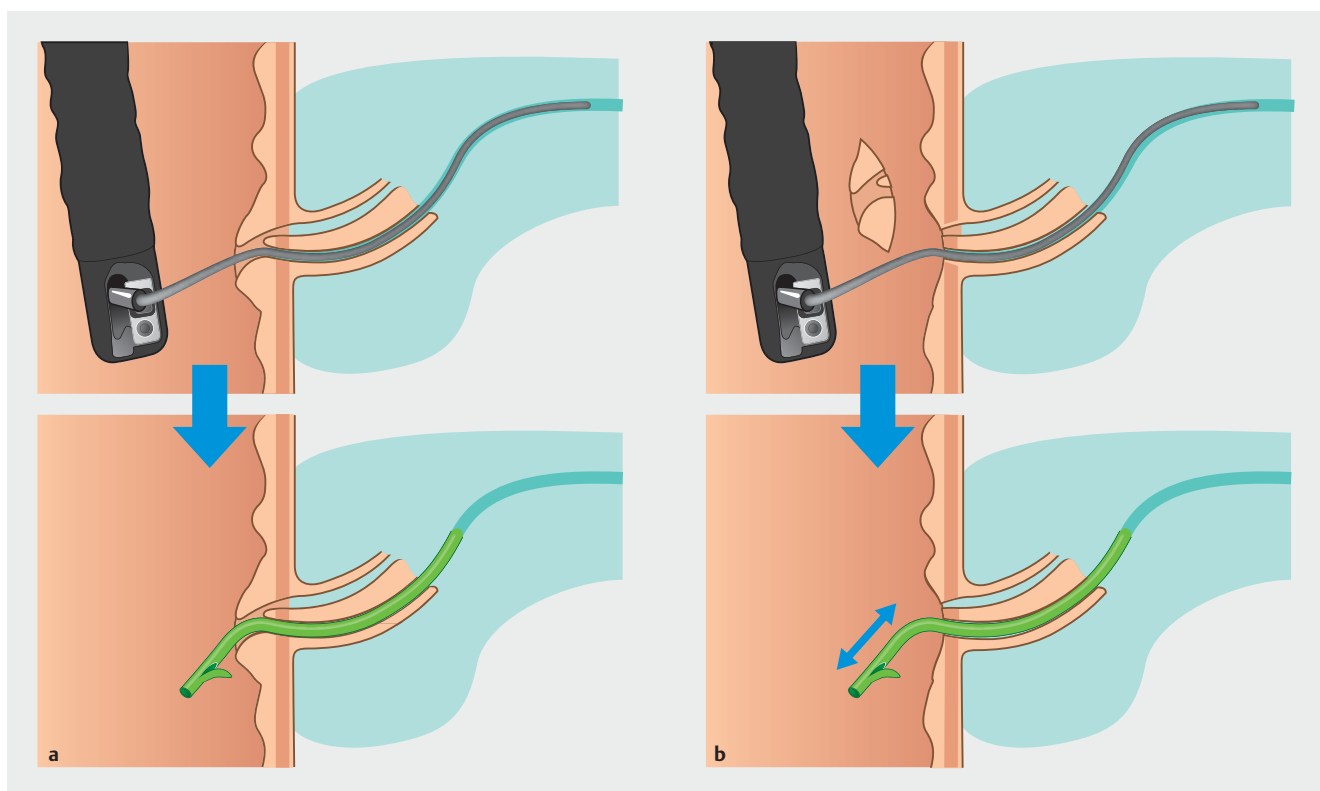
Factors	No pancreatitis (n = 30)	Pancreatitis (n = 9)	P value
Age (years), mean (SD)	62.0 (10.0)	59.8 (10.4)	0.56
Sex (men), n (%)	23 (76.7)	8 (88.9)	0.65
Tumor size (mm), mean (SD)	14.0 (5.8)	13.5 (3.8)	0.83
Difficult pancreatic duct cannulation, n (%)	2 (6.7)	2 (22.2)	0.22
Previous pancreatitis, n (%)	1 (3.3)	0	1.00
Haemostatic treatment, n (%)			
▪ Clipping	28 (93.3)	7 (77.8)	0.22
▪ APC	13 (43.3)	6 (66.7)	0.27
▪ HSE	6 (20.0)	2 (22.2)	1.00
Long PS, n (%)	20 (66.7)	2 (22.2)	0.026

APC, argon plasma coagulation; CI, confidence interval; EP, endoscopic papillectomy; HSE, hypertonic saline-epinephrine; PS, pancreatic stent; SD, standard deviation

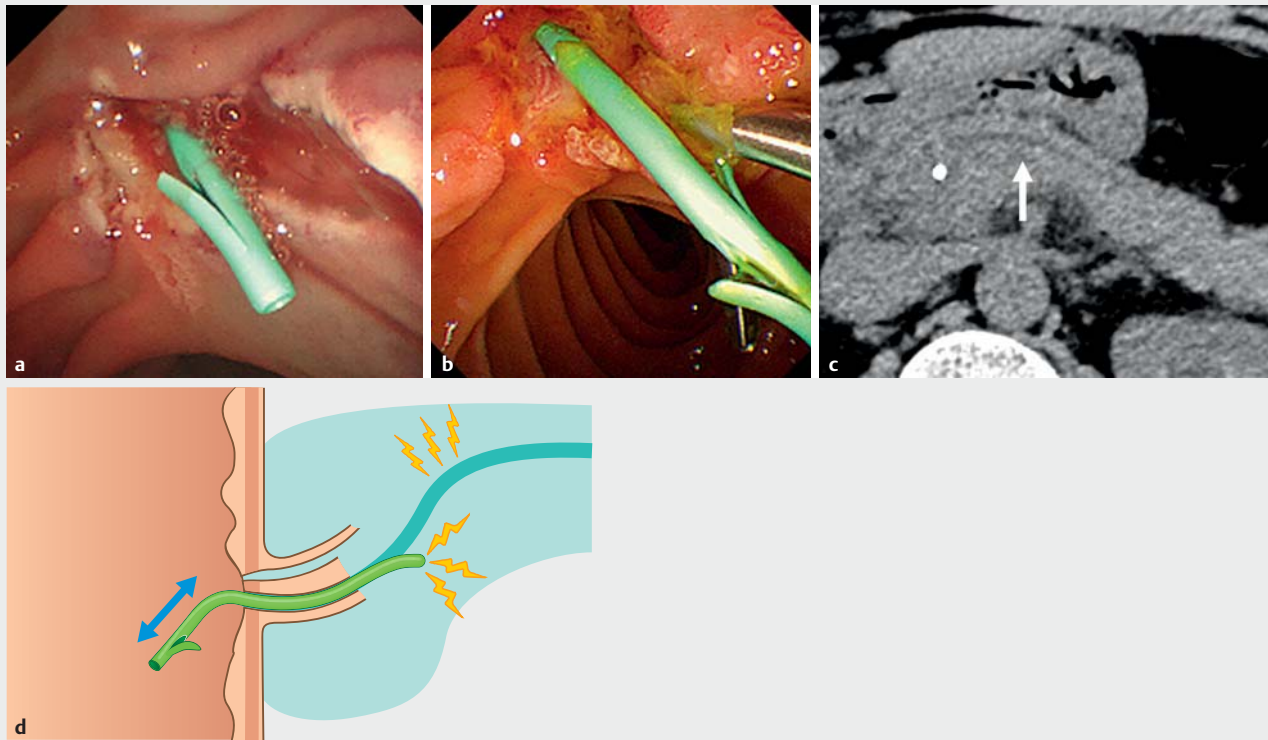
► **Table 4** Risk factors for post-EP pancreatitis (multivariate analysis).

	Post-EP pancreatitis (n = 9)	
	Odds ratio (95% CI)	P value
Difficult pancreatic duct cannulation	2.56 (0.26–25.3)	0.42
Long PS	0.16 (0.027–0.94)	0.042

CI, confidence interval; EP, endoscopic papillectomy; PS, pancreatic stent



► **Fig. 2** Images of pancreatic stent placement. **a** Conventional endoscopic retrograde cholangiopancreatography. Stent position is stable. **b** Endoscopic papillectomy. Stent position is unstable because of the loss of the ampulla of Vater.



► **Fig. 3** Pancreatic stent dislocation. **a** Immediately after short pancreatic stent placement. **b** At the time of stent removal after pancreatitis. **c** Dilated pancreatic duct (arrow) due to stent dislocation. **d** Image of pancreatitis caused by pancreatic stent dislocation.

► **Table 5** Details of post-EP pancreatitis cases.

Case	Age (y)/sex	Tumor size (mm)	PS length (cm)	Severity	Stent dislocation	Dilated pancreatic duct	Segment of pancreatitis
1	65/F	12	3	Mild	–	–	Head
2	49/M	15	4	Mild	–	–	Whole
3	77/M	12	5	Mild	+	+	Head and body
4	55/M	9	5	Mild	+	–	Head
5	45/M	13	5	Severe	–	–	Whole
6	54/M	16	5	Mild	–	No exam	No exam
7	57/M	15	5	Mild	–	+	Head
8	66/M	10	7	Severe	–	+	Head
9	70/M	21	7	Mild	–	No exam	No exam

EP, endoscopic papillectomy; F, female; M, male; PS, pancreatic stent

dislocate, possibly causing a pancreatic fluid flow disorder, resulting in pancreatitis (► **Fig. 3**). Indeed, the rate of post-EP pancreatitis has been reported to be higher than that for post-ERCP pancreatitis [3, 13, 21, 31]. However, we could not determine the accurate number of cases with PS dislocation, because computed tomography or early endoscopic examination was not performed in patients without AEs. Concerning such patients, when we removed PS 5 to 7 days after EP, slight PS dislo-

cation was found in five patients (2 in the short PS group and 3 in the long PS group), although we could not determine when it happened (early post-EP period or effect of endoscopic insertion). Therefore, in this retrospective report, we could not statistically analyse the relationship between PS dislocation and post-EP pancreatitis. It is one of our hypotheses, and another detailed examination is required in the future. Furthermore, in EP, the burn effect associated with tumor resection is another

factor contributing to incidence of pancreatitis. Thus, this should also be verified.

Although there are no studies reporting the rate of stent dislocation after EP, we consider that a short stent tends to cause kinking in the duct at a curve between the pancreatic head and body when PS dislocation occurs. In contrast, a long stent can adequately and deeply reach the pancreatic body; thus, even if it gets dislocated to some extent, this dislocation may not cause a problem. When we performed PS placement in this study, no cases had a unique form of the pancreatic duct, such as a loop or Z shape. Although the curve of the pancreatic duct was slightly different in every case, the long PS was placed over the curve of the pancreatic body. ► **Table 5** shows details of the cases with post-EP pancreatitis. Regrettably, we could not definitively confirm our hypothesis that incidence of stent dislocation is higher with a shorter PS than with a longer PS. At this point, further examination is required. Because pancreatitis is caused by various factors, not just a pancreatic fluid flow disorder, it is impossible to prevent it completely by using a long PS. However, use of a long PS might contribute to decreasing the rate of post-EP pancreatitis.

The current study has several limitations. First, it was single-center and retrospective, therefore, the number of patients was small. Furthermore, as mentioned above, pancreatitis is caused by various factors and few items were examined in this study. Second, we did not use a PS longer than 7 cm. Therefore, it remains unclear whether a longer PS can better prevent pancreatitis. There is a possibility that a 7-cm PS is more suitable than a shorter or longer PS. Given these limitations, the results of our study should be interpreted carefully. Third, the strategy of PS placement after EP was not common in all cases. The operator selected the length of the PS considered to be effective based on several factors. The shape of the pancreatic duct might be one factor; however, we could not determine the true reason for selecting the length of PS. Fourth, we tended to use more 7-cm PS in the late study period. Therefore, the learning curve might have affected incidence of pancreatitis. In the future, randomized controlled trials are required to confirm this result.

Conclusion

Our study revealed that a long PS significantly decreased incidence of pancreatitis after EP. In the future, prospective randomized studies with a large number of patients are required to establish the optimal method for EP.

Acknowledgements

The authors thank Editage (www.editage.jp) for English language editing.

Competing interests

None

References

- [1] Suzuki K, Kantou U, Murakami Y. Two cases with ampullary cancer who underwent endoscopic excision. *Prog Dig Endosc* 1983; 23: 236-239
- [2] Catalano MF, Linder JD, Chak A et al. Endoscopic management of adenoma of the major duodenal papilla. *Gastrointest Endosc* 2004; 59: 225-232
- [3] Bohnacker S, Seitz U, Nguyen D et al. Endoscopic resection of benign tumors of the duodenal papilla without and with intraductal growth. *Gastrointest Endosc* 2005; 62: 551-560
- [4] Cheng CL, Sherman S, Fogel EL et al. Endoscopic snare papillectomy for tumors of the duodenal papillae. *Gastrointest Endosc* 2004; 60: 757-764
- [5] Stolte M, Pscherer C. Adenoma-carcinoma sequence in the papilla of Vater. *Scand J Gastroenterol* 1996; 31: 376-382
- [6] Yamaguchi K, Enjoji M. Carcinoma of the ampulla of Vater. A clinico-pathologic study and pathologic staging of 109 cases of carcinoma and 5 cases of adenoma. *Cancer* 1987; 59: 506-515
- [7] Heinzow HS, Lenz P, Lenze F et al. Feasibility of snare papillectomy in ampulla of Vater tumors: Meta-analysis and study results from a tertiary referral center. *Hepatogastroenterol* 2012; 59: 332-335
- [8] Ardengh JC, Kemp R, Lima-Filho ER et al. Endoscopic papillectomy: The limits of the indication, technique and results. *World J Gastrointest Endosc* 2015; 7: 987-994
- [9] Napoleon B, Alvarez-Sanchez MV, Leclercq P et al. Systematic pancreatic stenting after endoscopic snare papillectomy may reduce the risk of postinterventional pancreatitis. *Surg Endosc* 2013; 27: 3377-3387
- [10] Ito K, Fujita N, Noda Y et al. Impact of technical modification of endoscopic papillectomy for ampullary neoplasm on the occurrence of complications. *Dig Endosc* 2012; 24: 30-35
- [11] Itoi T, Tsuji S, Sofuni A et al. A novel approach emphasizing preoperative margin enhancement of tumor of the major duodenal papilla with narrow-band imaging in comparison to indigo carmine chromoendoscopy (with videos). *Gastrointest Endosc* 2009; 69: 136-141
- [12] Lee TY, Cheon YK, Shim CS et al. Endoscopic wire-guided papillectomy versus conventional papillectomy for ampullary tumors: A prospective comparative pilot study. *J Gastroenterol Hepatol* 2016; 31: 897-902
- [13] Hyun JJ, Lee TH, Park JS et al. A prospective multicenter study of submucosal injection to improve endoscopic snare papillectomy for ampullary adenoma. *Gastrointest Endosc* 2017; 85: 746-755
- [14] Choudhary A, Bechtold ML, Arif M et al. Pancreatic stents for prophylaxis against post-ERCP pancreatitis: A meta-analysis and systematic review. *Gastrointest Endosc* 2011; 73: 275-282
- [15] Sofuni A, Maguchi H, Itoi T et al. Prophylaxis of post-endoscopic retrograde cholangiopancreatography pancreatitis by an endoscopic pancreatic spontaneous dislodgement stent. *Clin Gastroenterol Hepatol* 2007; 5: 1339-1346
- [16] Napoleon B, Gincul R, Ponchon T et al. Endoscopic papillectomy for early ampullary tumors: Long-term results from a large multicenter prospective study. *Endoscopy* 2014; 46: 127-134
- [17] Harewood GC, Pochron NL, Gostout CJ. Prospective, randomized, controlled trial of prophylactic pancreatic stent placement for endoscopic snare excision of the duodenal ampulla. *Gastrointest Endosc* 2005; 62: 367-370
- [18] Afghani E, Akshintala VS, Khashab MA et al. 5-Fr vs. 3-Fr pancreatic stents for the prevention of post-ERCP pancreatitis in high-risk patients: A systematic review and network meta-analysis. *Endoscopy* 2014; 46: 573-580

- [19] Olsson G, Lubbe J, Arnelo U et al. The impact of prophylactic pancreatic stenting on post-ERCP pancreatitis: A nationwide, register-based study. *United European Gastroenterol J* 2017; 5: 111–118
- [20] Ito K, Fujita N, Kanno A et al. Risk factors for post-ERCP pancreatitis in high risk patients who have undergone prophylactic pancreatic duct stenting: A multicenter retrospective study. *Intern Med* 2011; 50: 2927–2932
- [21] Chandrasekhara V, Khashab MA et al. ASGE Standards of Practice Committee. Adverse events associated with ERCP. *Gastrointest Endosc* 2017; 85: 32–47
- [22] Tsuji S, Itoi T, Sofuni A et al. Tips and tricks in endoscopic papillectomy of ampullary tumors: Single-center experience with large case series (with videos). *J Hepatobiliary Pancreat Sci* 2015; 22: E22–E27
- [23] Cotton PB, Lehman G, Vennes J et al. Endoscopic sphincterotomy complications and their management: An attempt at consensus. *Gastrointest Endosc* 1991; 37: 383–393
- [24] Zhang C, Yang YL, Ma YF et al. The modified pancreatic stent system for prevention of post-ERCP pancreatitis: A case-control study. *BMC Gastroenterol* 2017; 17: 108
- [25] Johanson JF, Schmalz MJ, Geenen JE. Incidence and risk factors for biliary and pancreatic stent migration. *Gastrointest Endosc* 1992; 38: 341–346
- [26] Mazaki T, Masuda H, Takayama T. Prophylactic pancreatic stent placement and post-ERCP pancreatitis: A systematic review and meta-analysis. *Endoscopy* 2010; 42: 842–853
- [27] Topazian M, Baron TH, Fidler JL et al. Endoscopic retrieval of a migrated pancreatic stent from the retroperitoneum. *Gastrointest Endosc* 2008; 67: 728–729
- [28] Zapatier JA, Jani P, Pimentel R et al. Pancreatic stent migration into the bile duct causing cholangitis. *Endoscopy* 2013; 45: (Suppl. 02): E324–E325
- [29] Leung WD, Parashette KR, Molleston JP et al. Pancreatic stent migration into the portal vein causing portal vein thrombosis: A rare complication of a prophylactic pancreatic stent. *Pancreatology* 2012; 12: 463–465
- [30] Pelz J, Farnbacher MJ, Raithel M et al. Perforation of the splenic artery as a complication of endoscopic pancreatic stent placement in chronic obstructing pancreatitis. *Endoscopy* 2013; 45: (Suppl. 02): E203–E204
- [31] Kubota K, Fujita Y, Sato T et al. Tumor diameter and Ki-67 expression in biopsy could be diagnostic markers discriminating from adenoma and early stage cancer in patients with ampullary tumors. *J Hepatobiliary Pancreat Sci* 2013; 20: 531–537