Article published online: 2020-01-29

3D-printed model in the guidance of tumor resection: a novel concept for resecting a large submucosal tumor in the mid-esophagus

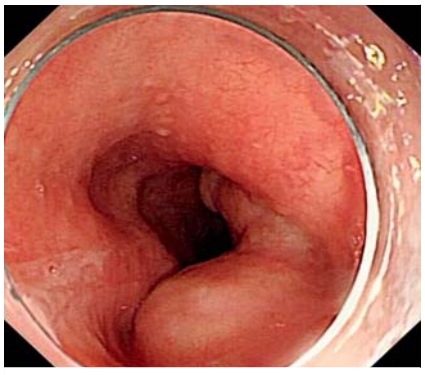

▶ **Fig. 1** The submucosal tumor in the mid-esophagus, as shown by endoscopy.

▶ **Fig. 2** The submucosal tumor (arrow) and its adjacent organs, as shown by computed tomography.

▶ **Fig. 3** The submucosal tumor and its adjacent organs, as shown by 3D-printed model.

Although most large submucosal tumors in the esophagus such as leiomyomas are benign, obstructive symptoms may develop owing to their size [1]. Endoscopic resection of large tumors in the esophagus remains difficult [2], and exophytic tumors in the mid-esophagus are the worst. The main problem is the presence of important adjacent organs such as bronchus, aorta, and spine. We report a novel concept for facilitating endoscopic resection: 3D-printed model in the guidance of tumor resection (3DM-GTR). The 3D-printed model, based on enhanced computed tomography, could clearly display the tumor anatomy and details of adjacent structures, playing a role in planning and implementing endoscopic resection.

A 47-year-old man with intermittent dysphagia for 2 months was diagnosed with a large submucosal tumor in the mid-esophagus (▶ **Fig. 1**). Enhanced computed tomography showed that the lesion was close to the bronchus, aorta, and spine (▶ **Fig. 2**). The 3D-printed model directly demonstrated the tumor and its adjacent organs (▶ **Fig. 3**). Under the guidance of the model (▶ **Video 1**), we successfully resected the tumor (▶ **Fig. 4**), without obvious intraoperative bleeding or other injuries to adjacent organs (▶ **Fig. 5**). The mucosal entry was closed using endoclips. The pathology confirmed the diagnosis of leiomyoma.

Fasting and prophylactic antibiotics were prescribed for 2 days. Proton pump inhibitors and nutritional support were given. The mild cervical subcutaneous emphysema detected during the procedure resolved spontaneously. The patient began drinking after 3 days and was discharged on postoperative Day 5. At 3-month follow-up, the patient had not experienced discomfort and upper endoscopy confirmed healing of the mucosa.

3DM-GTR seems a good and promising method, especially for large tumors in complex locations. The simulation model can remind the endoscopist in real time about what to expect in the next step; thus, it could reduce unexpected injuries to important adjacent organs.

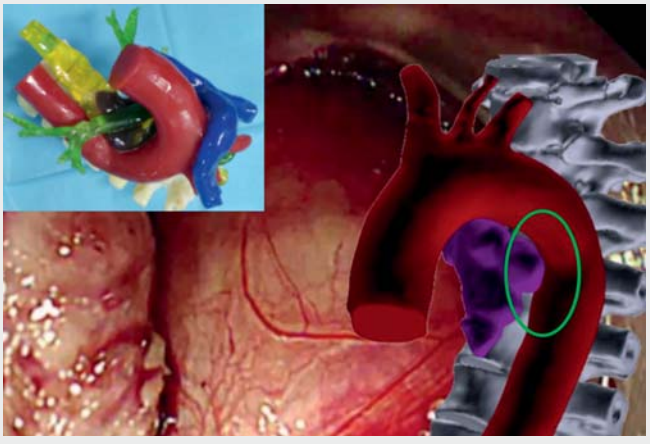

Video 1 3D-printed model in the guidance of endoscopic resection of a large submucosal tumor in the mid-esophagus.

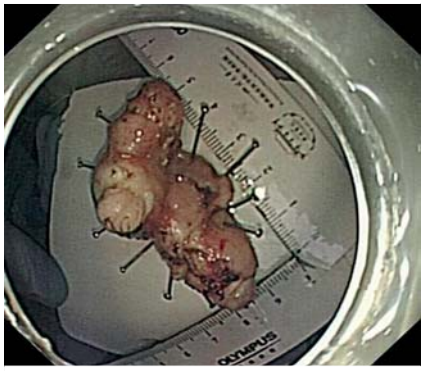

▶ **Fig. 4** The resected tumor.

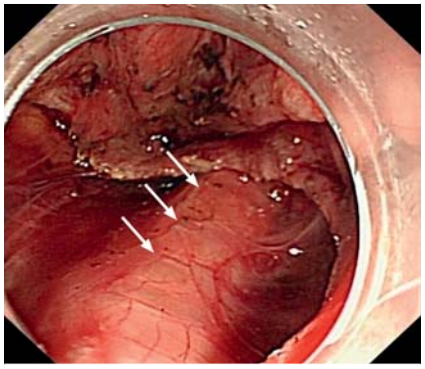

▶ **Fig. 5** The exposed aorta after tumor resection (arrows).

Endoscopy_UCTN_Code_TTT_1AO_2AN

Acknowledgment

We acknowledge the support from Sichuan Province Science and Technology Department (China) (2017SZ0009).

Competing interests

The authors declare that they have no conflict of interest.

The authors

Liansong Ye[1,*], Dan Yang[2,*], Yong Huang[3], Ke Liao[1], Xianglei Yuan[1], Bing Hu[1]

1 Department of Gastroenterology, West China Hospital, Sichuan University, Chengdu, Sichuan, China
2 Department of Radiology, West China Hospital, Sichuan University, Chengdu, Sichuan, China
3 Sichuan Farsoon Turing Additive Manufacturing Technology Co., Ltd., Chengdu, Sichuan, China

Corresponding author

Bing Hu, MD
West China Hospital, Sichuan University, No. 37 Guo Xue Alley, Wu Hou District, Chengdu City, 610041, Sichuan Province, China
Fax: +86-28-85423387
hubingnj@163.com

References

[1] Rijcken E, Kersting CM, Senninger N et al. Esophageal resection for giant leiomyoma: report of two cases and a review of the literature. Langenbecks Arch Surg 2009; 394: 623–629
[2] Ye L, Sharma M, Yang D et al. Open dissection for resection of a large submucosal tumor in the esophagus. Endoscopy 2019; 51: E243–E244

Bibliography

DOI https://doi.org/10.1055/a-1090-6940
Published online: 29.1.2020
Endoscopy 2020; 52: E273–E274

ISSN 0013-726X

* These authors contributed equally to this work.