

# Successful repair of wide traumatic rectal perforation using over-the-scope clip

OPEN  
ACCESS



## Authors

Mauro Manno, Simona Deiana, Tommaso Gabbani, Sara Vavassori, Laura Ottaviani, Paola Soriani

## Institution

Ramazzini Hospital, Gastroenterology and Digestive Endoscopy, Carpi (Modena), Italy

submitted 6.8.2019

accepted after revision 30.9.2019

## Bibliography

DOI <https://doi.org/10.1055/a-1093-0778> |

Endoscopy International Open 2020; 08: E548–E549

© Georg Thieme Verlag KG Stuttgart · New York

eISSN 2196-9736

## Corresponding author

Mauro Manno, Ramazzini Hospital - Gastroenterology and Digestive Endoscopy, Via Guido Molinari 2 Carpi, Modena 41012, Italy

Fax: +059659250

m.manno@ausl.mo.it

## ABSTRACT

**Background and study aims** We report on a case of a traumatic rectal perforation that occurred in a 16-year-old girl, which was successfully treated using an over-the-scope clip, avoiding major surgery and stoma.

## Introduction

The over-the-scope clip (OTSC) (Ovesco Endoscopy GmbH, Tübingen, Germany), designed for tissue approximation, is already recommended as first-line endoscopic treatment for endoscopic acute iatrogenic perforation [1]. To the best of our knowledge, no data regarding gastrointestinal traumatic, not iatrogenic, perforation repaired with the use of OTSC, are available.

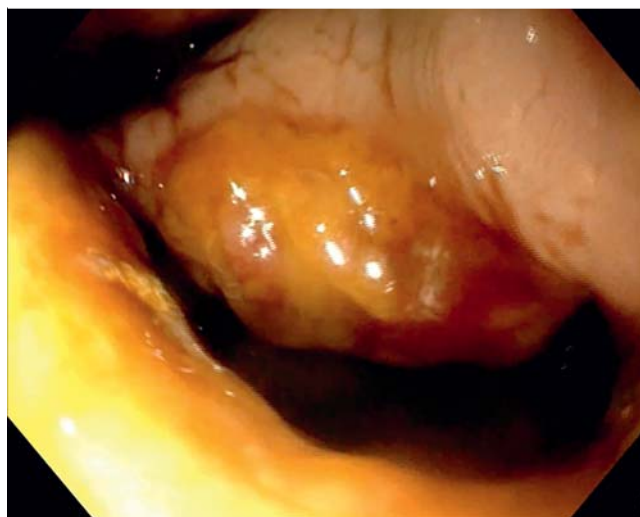## Case report

A 16-year-old girl was referred to the emergency room for copious rectal bleeding and secondary syncope, due to violent trauma. Computed tomography (CT) scan and subsequent colonoscopy revealed a voluminous pelvic hematoma and a 35– to 40-mm irregular full-thickness defect, located in the posterior rectal wall, about 30 mm from the dentate line (**▶ Fig. 1**).

Because of the lesion's features and the acute setting, an OTSC was placed (12/6 mm, traumatic type) using the OTSC twin grasper (Ovesco Endoscopy GmbH, Tübingen, Germany) (**▶ Fig. 2**). This auxiliary device has two jaws which can be opened separately, allowing better gaping edges approximation.

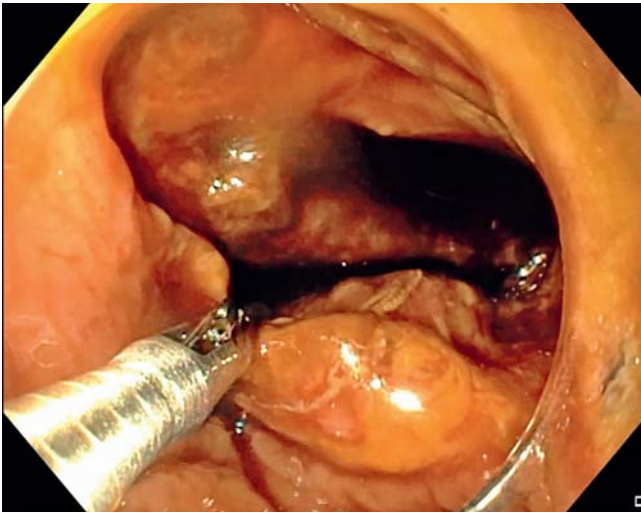
The entire procedure was performed under deep sedation, using CO<sub>2</sub> insufflation **▶ Video 1**.

The endoscopic treatment was effective, as confirmed after contrast medium injection and CT scan.

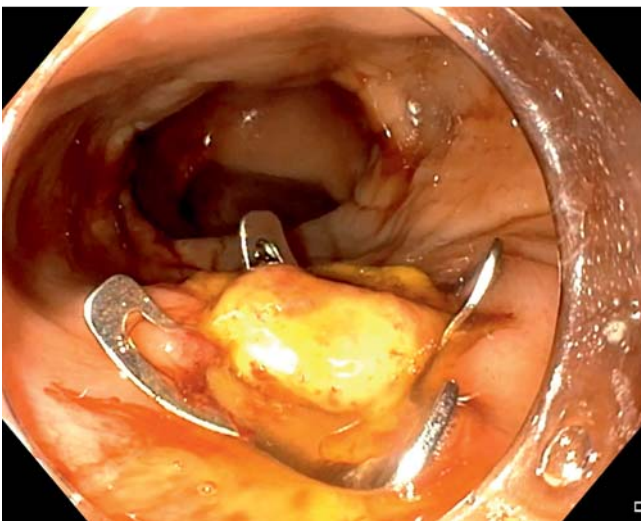


**▶ Fig. 1** 35- to 40-mm irregular full-thickness defect of the posterior rectal wall.

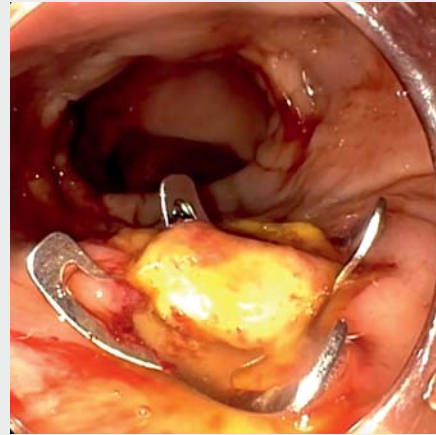
A Few days later, second endoscopic look confirmed complete sealing of the defect and the patient was discharged home (**▶ Fig. 3**).



► **Fig. 2** Edges approximation with OTSC twin grasper.



► **Fig. 3** Complete sealing of the defect.



► **Video 1** Full-length video showing the entire successful repair of wide traumatic rectal perforation using OTSC

### Competing interests

The authors declare that they have no conflict of interest.

### Reference

- [1] Paspatis GA, Dumonceau JM, Barthet M et al. Diagnosis and management of iatrogenic endoscopic perforations: European Society of Gastrointestinal Endoscopy (ESGE) Position Statement. *Endoscopy* 2014; 46: 693–711

## Conclusion

In conclusion, OTSC with a twin grasper can successfully treat wide traumatic rectal perforation, avoiding major surgery with definitive or temporary stoma, especially in a young patient.