Comparison of Magnetic Resonance Imaging and Contrast-Enhanced Ultrasound as Diagnostic Options for Unclear Cystic Renal Lesions: A Cost-Effectiveness Analysis

Vergleich von Magnetresonanztomografie und kontrastverstärktem Ultraschall als diagnostische Optionen bei unklaren zystischen Nierenläsionen – Eine Kosteneffektivitätsanalyse

Authors

Felix Gassert[1], Moritz Schnitzer[2], Su Hwan Kim[3], Wolfgang G. Kunz[3], Benjamin Philipp Ernst[4], Dirk-André Clevert[5], Dominik Nörenberg[6], Johannes Rübenthaler[2], Matthias Frank Froelich[6]

Affiliations

1 Department of Diagnostic and Interventional Radiology, Klinikum rechts der Isar, Technical University of Munich, Germany
2 Department of Clinical Radiology, Ludwig-Maximilians-University of Munich-Großhadern Campus, Munich, Germany
3 Department of Radiology, Interdisciplinary ultrasound center, University Hospital LMU Munich, Germany
4 Department of Otorhinolaryngology, University Medical Center Mainz, Germany
5 Department of Clinical Radiology, University of Munich-Großhadern Campus, Munich, Germany
6 Institute of Clinical Radiology and Nuclear Medicine, University Medical Centre Mannheim, Germany

Key words

ultrasound, contrast-enhanced ultrasound, cost effectiveness, renal lesions, magnetic resonance imaging

received 20.10.2019
accepted 14.01.2020
published online 12.02.2020

Bibliography

Ultraschall in Med 2021; 41: 411–417
DOI 10.1055/a-1110-7172
ISSN 0172-4614

Georg Thieme Verlag KG, Rüdigerstraße 14, 70469 Stuttgart, Germany

Correspondence

Dr. Matthias Frank Froelich
Institute of Clinical Radiology and Nuclear Medicine, University Medical Centre Mannheim, Theodor-Kutzer-Ufer 1–3, 68167 Mannheim, Germany
Tel.: ++ 49/6 21/3 83 22 76
Matthias.Froelich@medma.uni-heidelberg.de

ABSTRACT

Purpose Correct differentiation between malignant and benign incidentally found cystic renal lesions has critical implications for patient management. In several studies contrast-enhanced ultrasound (CEUS) showed higher sensitivity with respect to the accurate characterization of these lesions compared to MRI, but the cost-effectiveness of CEUS has yet to be investigated. The aim of this study was to analyze the cost-effectiveness of CEUS as an alternative imaging method to MRI for the characterization of incidentally found cystic renal lesions.

Materials and Methods A decision model including the diagnostic modalities MRI and CEUS was created based on Markov simulations estimating lifetime costs and quality-adjusted life years (QALYs). The recent literature was reviewed to obtain model input parameters. The deterministic sensitivity of diagnostic parameters and costs was determined and probabilistic sensitivity analysis using Monte-Carlo Modelling was applied. Willingness-to-pay (WTP) was assumed to be $ 100 000/QALY.

Results In the base-case scenario, the total costs for CEUS were $9654.43, whereas the total costs for MRI were $9675.03. CEUS resulted in an expected effectiveness of 8.06 QALYs versus 8.06 QALYs for MRI. Therefore, from an economic point of view, CEUS was identified as an adequate diagnostic alternative to MRI. Sensitivity analysis showed that results may vary if CEUS costs increase or those of MRI decrease.

Conclusion Based on the results of the analysis, the use of CEUS was identified as a cost-effective diagnostic strategy for the characterization of incidentally found cystic renal lesions.

ZUSAMMENFASSUNG

Ziel Die Unterscheidung zwischen malignen und benignen zufällig entdeckten zystischen Läsionen der Niere ist essenziell für weitere Behandlungsstrategien. In einigen Studien zeigte kontrastverstärkter Ultraschall (CEUS) im Vergleich zur Magnetresonanztomografie (MRT) eine höhere Sensitivität bei der Charakterisierung dieser Läsionen. Eine Analyse der Kos-

teneffektivität von CEUS steht jedoch noch aus. Das Ziel dieser Studie war es, die Kosteneffektivität von CEUS als alternative bildgebende Methode zur MRT bei der Charakterisierung zufällig entdeckter zystischer Nierenläsionen zu analysieren.

Material and Methode Basierend auf Markov-Simulationen wurde unter Einbezug der Modalitäten MRT und CEUS ein Entscheidungsmodell entwickelt, welches die „lifetime costs" und die „Quality-adjusted life-years "(QALYs) der Methoden analysiert. Die Modellparameter wurden durch Recherche aktueller Literatur gewonnen. Es wurden die deterministische Sensitivität der Parameter sowie die Kosten bestimmt. Mittels Monte-Carlo-Modellierung wurde eine probabilistische Sensitivitätsanalyse durchgeführt. Die „Willingness to pay" (WTP) wurde auf $100 000/QALY festgelegt.

Ergebnisse Im Base-case-Szenario ergaben sich für CEUS absolute Kosten von $ 9654,43 und für MRT von $ 9675,03. Die erwartete Effektivität lag sowohl bei CEUS als auch bei MRT bei 8,06 QALYs. Aus ökonomischer Sicht konnte CEUS daher als sinnvolle Alternative zur MRT identifiziert werden. Die Sensitivitätsanalyse zeigte, dass diese Ergebnisse abhängig von den Kosten von CEUS und MRT variieren können.

Schlussfolgerung Basierend auf den Ergebnissen dieser Studie konnte CEUS als kosteneffektive diagnostische Alternative gegenüber MRT in Bezug auf die Charakterisierung zufällig entdeckter zystischer Nierenläsionen identifiziert werden.

Introduction

Cystic renal lesions often appear as incidental findings during various imaging procedures as they are common especially in people over the age of 50 [1]. Nevertheless, only 6 % of these incidental cystic renal lesions are malignant and require further therapy [2]. Precise stratification of these lesions is crucial for further management since misdiagnosis and unnecessary diagnostics or therapeutic steps lead to maldistribution of financial resources and might even harm the patient, consequently leading to higher healthcare costs and a reduction in quality of life [3, 4].

If diagnostic steps lead to the diagnosis of a renal malignancy, therapy varies, ranging from watch and wait to surgical resection of the lesion [3].

Both magnetic resonance imaging (MRI) and contrast-enhanced ultrasound (CEUS) are valid imaging techniques for the evaluation of undetermined cystic renal lesions found on CT [5–8].

MRI provides high sensitivity and is an established diagnostic tool for the characterization of these lesions [9, 10]. Advances in MR imaging and the use of new sequences with the detection and clarification of internal enhancement in cystic renal masses strengthen its position [10]. However, MRI has limited availability and relatively high costs compared to other imaging techniques [11].

Since its approval by the FDA in 2016, CEUS has gained increasing recognition as an effective diagnostic imaging tool in multiple pathologies [12]. It is considered appropriate for renal cyst classification and the determination of the probability of malignancy [8, 13]. Additionally, it is universally available and its costs are considerably lower than those of MRI. There are several studies that claim higher sensitivity for CEUS compared to MRI for the characterization of incidental cystic renal lesions. CEUS was shown to provide advantages over other diagnostic tools especially in the evaluation of complex renal cysts [7, 14].

In a review including 17 studies and a total of 1142 cystic renal lesions, Zhou et al. showed that CEUS compared to MRI provides higher sensitivity but lower specificity in most cases [11]. Regarding the consequences of the misdiagnosis of undetermined cystic renal lesions, cost efficiency is an important factor in the choice of diagnostic means. Even though this is a factor of increasing importance in the healthcare sector, no study investigating the cost effectiveness of CEUS compared to MRI for the evaluation of undetermined cystic renal lesions (incidentally found on CT scans) and its therapeutic consequences has been published until now. The aim of this study is to determine the cost effectiveness of CEUS for the characterization of incidental cystic renal lesions compared to MRI.

Materials and Methods

Model structure

A decision model including the diagnostic modalities CEUS and MRI was created as a decision tree. Dedicated decision analysis software (TreeAge Pro Version 19.1.1, Williamstown, MA) was used for further analysis. The model is shown in ▶ **Fig. 1a**.

Markov models are used for optimal modelling of different clinical situations, costs and outcomes of patients by simulating different patient states and their change of clinical state with a certain probability. This allows simulation of complex real world processes using relatively simple models.

In this study a Markov transition state model including the states "Alive without renal malignancy", "Alive with localized renal malignancy", "Alive with metastasized renal malignancy" and "Dead" was applied for outcome analysis as shown in ▶ **Fig. 1b**.

Input parameters

Systematic review of recent literature was performed for definition of the model input parameters (▶ **Table 1**). Age-specific risk of death was derived from the US Life Tables [15].

Diagnostic test performance

Sensitivity and specificity values for CEUS and MRI were derived from the literature [11].

Costs and utilities

As the US healthcare perspective was applied, cost estimations were based on Medicare data and previous available literature

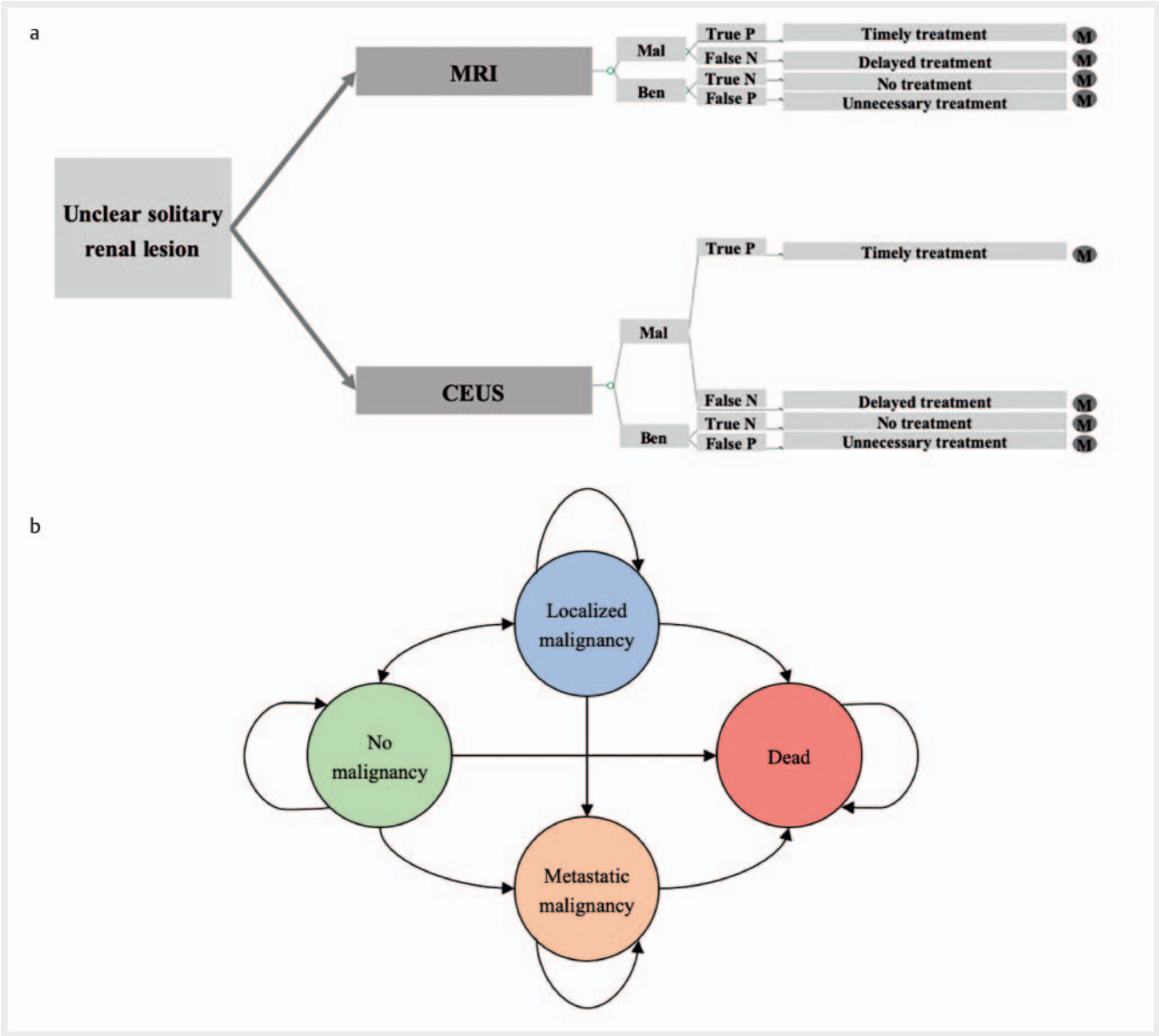

▶ **Fig. 1** **a** Model overview. ben = benign, CEUS = contrast-enhanced ultrasound, M = Markov model, mal = malignant, MRI = magnetic resonance imaging, N = negative, P = positive. **b** Markov model overview.

(▶ **Table 1**) [16, 17]. The costs for a delayed surgery in false-negative cases were assumed to rise by a factor of 1.5 compared to timely surgery accounting for the expenses derived from prolonged hospitalization, additional diagnostic procedures and risk of complications. Diagnosis of a localized tumor is assumed to always be followed by surgery. Yearly costs for patients with a localized tumor are derived from follow-up examinations [16].

Utilities are measured in the additional quality-adjusted life years (QALY) gained through the diagnostic procedures. Quality of life (QOL) was set to 1 for patients without a tumor. Likewise, based on previous literature, QOL for patients with a localized tumor was set to 0.97, as surgery and possible complications lead to a reduction of QOL [18]. In accordance with literature, the QOL of patients with a metastasized tumor was set to 0.67 [4]. Values were used for calculations in a specifically designed Markov model.

Transition probabilities

Transition probabilities were derived from systematic review of recent literature and are shown in ▶ **Table 1** [19–22].

The probability of occurrence of metastases in patients with a localized tumor was assumed to be 1 % [19]. The risk of death in the case of localized disease was assumed to be similar to the risk without disease as metastasis was assumed to be the cause of the fatal outcome of the disease. The age-dependent risk of death was adopted from the US Life Tables 2016 [15]. The risk of death by other causes was assumed to be similar between patients with and without renal malignancy since comorbidities decreasing life expectancy seemed unlikely.

▶ **Table 1** Model input parameters.

variable	estimate	distribution
pre-test probability of malignant lesion	55.10 %	Sevcenco et al. 2017 Meyer et al. 2017
expected age at diagnostic procedure	60 years	assumption
assumed willingness-to-pay per QALY	$ 100 000	assumption
discount rate	3.00 %	Sanders et al. 2016
Markov model time horizon	10 years	assumption
diagnostic test performance		
MRI sensitivity	0.92 (0.88 to 0.95)	Zhou L et al. 2018
MRI specificity	0.91 (0.87 to 0.93)	Zhou L et al. 2018
CEUS sensitivity	0.95 (0.92 to 0.97)	Zhou L et al. 2018
CEUS specificity	0.84 (0.79 to 0.88)	Zhou L et al. 2018
costs (acute)		
MRI	$ 385	medicare (74 182)
CEUS	$ 285	medicare (C9744)
timely surgery + treatment (true positive)	$ 4020	medicare (52 355)
delayed surgery + treatment (false negative)	$ 6030	assumption (1.5 ×)
unnecessary surgery (false positive)	$ 4020	medicare (52 355)
no further action (true negative)	$ 0	assumption
costs (long term)		
yearly costs without tumor	$ 0	assumption
yearly costs with localized tumor (1st year)	$ 770	Donat et al. 2013
yearly costs with localized tumor (after 1st year)	$ 385	Donat et al. 2013
yearly costs with metastatic tumor (1st year)	$ 62 000	Hollenbeak et al. 2011
yearly costs with metastatic tumor (after 1st year)	$ 20 136	Hollenbeak et al. 2011
utilities		
QOL of patients without tumor	1	assumption
QOL of patients with metastatic tumor	0.67	De Groot et al. 2018
QOL of false-negative patients	0.95	assumption
QOL of patients with localized tumor	0.97	Jiang et al. 2009
death	0	assumption
transition probabilities		
risk of death without tumor	age-adjusted	US Life Tables 2015
risk of death with localized tumor	age-adjusted	US Life Tables 2015
probability of initial non-R0 resection	5.70 %	Orosco et al. 2018
risk of metastases in false-negative patients	1.00 %	Bensalah et al. 2008
probability of local recurrence after resection	5.00 %	Krabbe et al. 2014
probability of occurrence of metastasis	4.00 %	assumption
probability of successful surgery of local recurrence	41.20 %	Thomas et al. 2015
risk of death with metastasis	35.00 %	Noone et al. 2018

QALY = quality adjusted life year, CEUS = contrast-enhanced ultrasound, MRI = magnetic resonance imaging, QOL = quality of life.

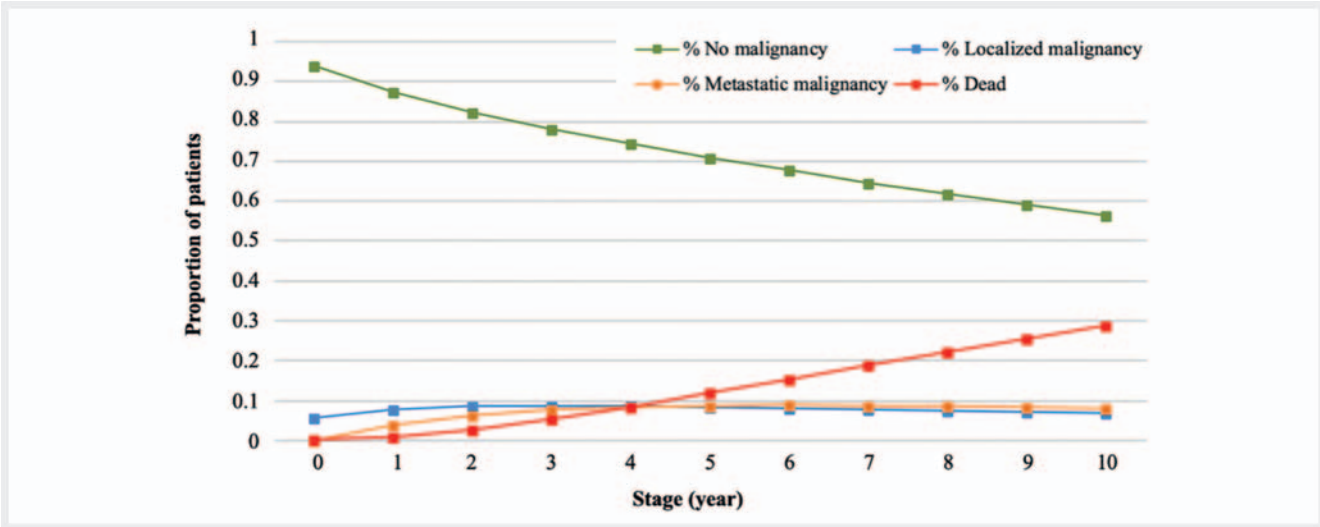

▶ **Fig. 2** Modeled states for 10-year period for true-positive patients.

Cost-effectiveness analysis

A discount rate of 3.0 % was assumed in line with recommendations [23]. The pre-test probability of malignant lesions was derived from the literature [24, 25]. Willingness to pay (WTP) was set at $ 100 000 per QALY. The WTP is the amount of financial resources one is willing to pay in order to gain an additional QALY. The cost-effectiveness analysis was performed to a total time horizon of 10 years after detection of the cystic renal lesion.

Survival diagrams indicating the patients' state and allowing the evaluation of the modelled outcomes in the Markov model were created.

A deterministic sensitivity analysis of costs determining the influence of each variable on the model was performed and is visualized as a tornado diagram.

Monte Carlo Modelling was used for the probabilistic sensitivity analysis. Using simultaneous modelling of variations of multiple input parameters, Monte Carlo Modelling allows comprehensive testing of the robustness of the model. The model was calculated with a total of 30 000 iterations.

Results

Cost-effectiveness analysis

Applying a WTP of $100 000 per QALY and a time period of 10 years, CEUS resulted in total costs of $ 9654.43 in the base-case analysis, whereas MRI resulted in total costs of $ 9675.03. CEUS showed an expected effectiveness of 8.06 QALYs versus 8.06 QALYs for MRI. Therefore, regarding cost effectiveness, the diagnostic management of cystic renal lesions was less expensive with CEUS with comparable effectiveness to MRI in the base-case scenario.

Markov model

Input parameters of the Markov model lead to the respective state probabilities shown in ▶ **Fig. 2**.

Deterministic sensitivity analysis

To account for the possibly differing costs of CEUS and MRI, a deterministic sensitivity analysis was performed. Within the wide range of $300 to $700 for MRI, CEUS remained cost-effective. The range of cost for CEUS was set from $150 to $450. Assuming a WTP of $100 000, in the upper part of this range, CEUS lost its dominance over MRI at $305 for CEUS and $364 for MRI (▶ **Fig. 3**).

Probabilistic sensitivity analysis

A probabilistic sensitivity analysis showed that both diagnostic strategies lead to comparable results, with a positive tendency for CEUS: At a WTP of $2000 per QALY, CEUS was cost-effective in 55.8 % of iterations. An increase in WTP lead to an increasing percentage of iterations being cost-effective for MRI, resulting in cost effectiveness for CEUS in 50.2 % of iterations at a WTP of $ 200 000 per QALY. This is mainly due to the relatively low specificity of CEUS.

Discussion

This study demonstrates that CEUS is a cost-effective alternative compared to MRI for the diagnosis of incidental cystic renal lesions. Since CEUS has only recently been approved in the US and is increasingly gaining the attention of experts, it might be a valuable diagnostic means in the future [12]. Our results are in line with several other studies which showed the cost effectiveness of CEUS over unenhanced ultrasound, CT and MRI in various abdominal diseases [26–28]. Smajerova et al. performed a similar study demonstrating the cost effectiveness of CEUS over MRI in incidental focal lesions of the liver [29]. Although the guidelines do not yet recommend CEUS as the primary diagnostic means for cystic

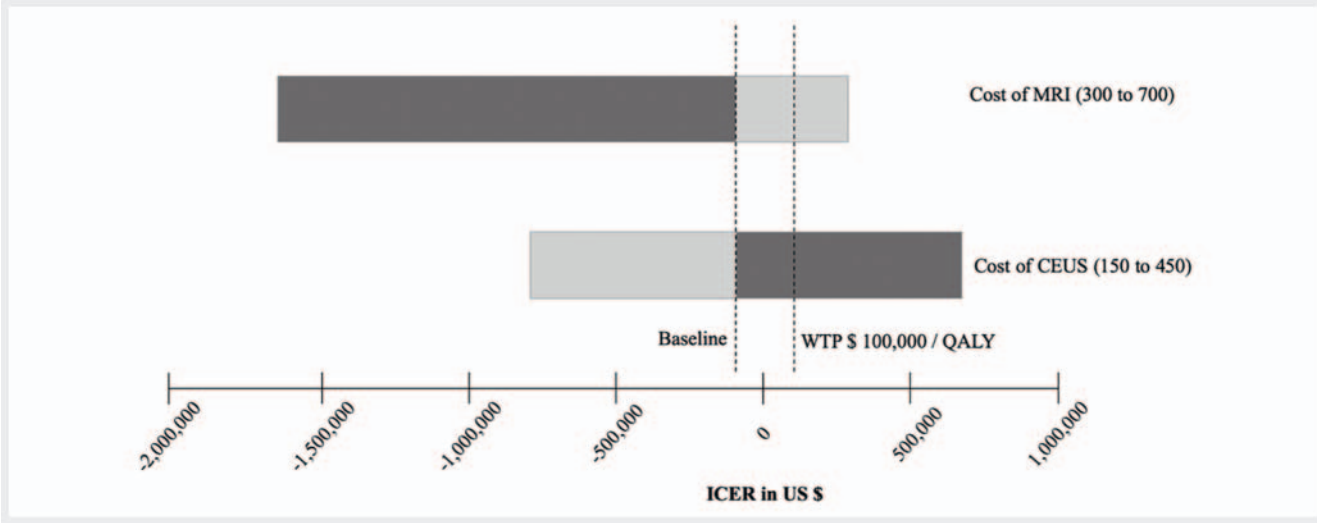

▶ **Fig. 3** One-way sensitivity analysis for CEUS vs. MRI. CEUS = contrast-enhanced ultrasound, ICER = incremental cost effectiveness ratio, MRI = magnetic resonance imaging.

renal lesions, it is mentioned as an additional tool for evaluating the presence of malignancy within lesions [3].

Nevertheless, deterministic sensitivity analysis showed that if the costs of CEUS exceed $305 or the costs of MRI fall below $364, MRI becomes the dominating strategy over CEUS.

Our model is based on several assumptions. This includes values for the probability of occurrence of metastases, quality of life of patients living with undiagnosed renal cancer and costs of delayed surgery and treatment. These values are not available in the literature since studies performed to determine these values would be unethical. We therefore based these values on expert opinions. Also, our study only includes CEUS and MRI and does not take into account other means of differentiation between malignancy and benignancy in cystic renal lesions, such as unenhanced ultrasound, biopsy and direct surgery [6, 30]. Additionally, our Markov model does not allow patients in a metastatic state of cancer to be cured. Input parameters for calculations are based on costs in the US healthcare system. In further studies it would be desirable to apply results to other systems as well. However, this would exceed the scope of this study.

Especially since CEUS was just recently approved by the FDA, the results of this study may be interesting for future decisions regarding its use for diagnosing cystic renal lesions. Nevertheless, the choice of diagnostic methods also depends on other factors such as the availability of MRI or CEUS expertise.

Conclusion

In conclusion, both CEUS and MRI may be valuable tools in the differentiation between benign and malignant lesions of the kidney. Based on the results of the analysis, the use of CEUS was identified as a cost-effective diagnostic strategy for the characterization of incidentally found cystic renal lesions. Nevertheless, the results are sensitive to the costs of these methods and consequently might not be transferable to other healthcare systems.

Conflict of Interest

The authors declare that they have no conflict of interest.

References

[1] Seppala N, Kielar A, Dabreo D et al. Inter-rater agreement in the characterization of cystic renal lesions on contrast-enhanced MRI. Abdominal imaging 2014; 39: 1267–1273

[2] Elstob A, Gonsalves M, Patel U. Diagnostic modalities. International journal of surgery (London, England) 2016; 36: 504–512

[3] Richard PO, Violette PD, Jewett MA et al. CUA guideline on the management of cystic renal lesions. Canadian Urological Association journal = Journal de l'Association des urologues du Canada 2017; 11: E66–E73

[4] de Groot S, Redekop WK, Versteegh MM et al. Health-related quality of life and its determinants in patients with metastatic renal cell carcinoma. Quality of life research: an international journal of quality of life aspects of treatment, care and rehabilitation 2018; 27: 115–124

[5] Barr RG, Peterson C, Hindi A. Evaluation of indeterminate renal masses with contrast-enhanced US: a diagnostic performance study. Radiology 2014; 271: 133–142

[6] Chang EH, Chong WK, Kasoji SK et al. Management of Indeterminate Cystic Kidney Lesions: Review of Contrast-enhanced Ultrasound as a Diagnostic Tool. Urology 2016; 87: 1–10

[7] Gulati M, King KG, Gill IS et al. Contrast-enhanced ultrasound (CEUS) of cystic and solid renal lesions: a review. Abdominal imaging 2015; 40: 1982–1996

[8] Rubenthaler J, Mueller-Peltzer K, Negrao de Figueiredo G et al. [CEUS-diagnostic workup of cystic renal lesions]. Der Radiologe 2018; 58: 545–552

[9] Ferreira AM, Reis RB, Kajiwara PP et al. MRI evaluation of complex renal cysts using the Bosniak classification: a comparison to CT. Abdominal radiology (New York) 2016; 41: 2011–2019

[10] Hindman NM. Cystic renal masses. Abdominal radiology (New York) 2016; 41: 1020–1034

[11] Zhou L, Tang L, Yang T et al. Comparison of contrast-enhanced ultrasound with MRI in the diagnosis of complex cystic renal masses: a meta-analysis. Acta radiologica (Stockholm, Sweden: 1987) 2018; 59: 1254–1263

[12] Chang EH. An Introduction to Contrast-Enhanced Ultrasound for Nephrologists. Nephron 2018; 138: 176–185

[13] Ascenti G, Mazziotti S, Zimbaro G et al. Complex cystic renal masses: characterization with contrast-enhanced US. Radiology 2007; 243: 158–165

[14] Defortescu G, Cornu JN, Bejar S et al. Diagnostic performance of contrast-enhanced ultrasonography and magnetic resonance imaging for the assessment of complex renal cysts: A prospective study. International journal of urology: official journal of the Japanese Urological Association 2017; 24: 184–189

[15] Arias E, Xu J, Kochanek KD. United States Life Tables, 2016. National vital statistics reports: from the Centers for Disease Control and Prevention, National Center for Health Statistics, National Vital Statistics System 2019; 68: 1–66

[16] Donat SM, Diaz M, Bishoff JT et al. Follow-up for Clinically Localized Renal Neoplasms: AUA Guideline. The Journal of urology 2013; 190: 407–416

[17] Hollenbeak CS, Nikkel LE, Schaefer EW et al. Determinants of medicare all-cause costs among elderly patients with renal cell carcinoma. Journal of managed care pharmacy: JMCP 2011; 17: 610–620

[18] Jiang J, Zheng X, Qin J et al. Health-related quality of life after hand-assisted laparoscopic and open radical nephrectomies of renal cell carcinoma. International urology and nephrology 2009; 41: 23–27

[19] Bensalah K, Pantuck AJ, Crepel M et al. Prognostic variables to predict cancer-related death in incidental renal tumours. BJU international 2008; 102: 1376–1380

[20] Krabbe LM, Bagrodia A, Margulis V et al. Surgical management of renal cell carcinoma. Seminars in interventional radiology 2014; 31: 27–32

[21] Orosco RK, Tapia VJ, Califano JA et al. Positive Surgical Margins in the 10 Most Common Solid Cancers. Scientific reports 2018; 8: 5686

[22] Noone AMHN, Krapcho M, Miller D et al. SEER Cancer Statistics Review, 1975–2015, National Cancer Institute. Bethesda, MD. https://seer.cancer.gov/csr/1975_2015/, based on November 2017 SEER data submission, posted to the SEER web site, April 2018

[23] Sanders GD, Neumann PJ, Basu A et al. Recommendations for Conduct, Methodological Practices, and Reporting of Cost-effectiveness Analyses: Second Panel on Cost-Effectiveness in Health and Medicine. Jama 2016; 316: 1093–1103

[24] Meyer HJ, Pfeil A, Schramm D et al. Renal incidental findings on computed tomography: Frequency and distribution in a large non selected cohort. Medicine 2017; 96: e7039

[25] Sevcenco S, Spick C, Helbich TH et al. Malignancy rates and diagnostic performance of the Bosniak classification for the diagnosis of cystic renal lesions in computed tomography – a systematic review and meta-analysis. Eur Radiol 2017; 27: 2239–2247

[26] Faccioli N, Dietrich CF, Foti G et al. Activity-Based Cost Analysis of Including Contrast-Enhanced Ultrasound (CEUS) in the Diagnostic Pathway of Focal Pancreatic Lesions Detected by Abdominal Ultrasound. Ultraschall in der Medizin (Stuttgart, Germany: 1980) 2019. doi:10.1055/a-0869-7861

[27] Tanaka H, Iijima H, Nouso K et al. Cost-effectiveness analysis on the surveillance for hepatocellular carcinoma in liver cirrhosis patients using contrast-enhanced ultrasonography. Hepatology research: the official journal of the Japan Society of Hepatology 2012; 42: 376–384

[28] Westwood M, Joore M, Grutters J et al. Contrast-enhanced ultrasound using SonoVue(R) (sulphur hexafluoride microbubbles) compared with contrast-enhanced computed tomography and contrast-enhanced magnetic resonance imaging for the characterisation of focal liver lesions and detection of liver metastases: a systematic review and cost-effectiveness analysis. Health technology assessment (Winchester, England) 2013; 17: 1–243

[29] Smajerova M, Petrasova H, Little J et al. Contrast-enhanced ultrasonography in the evaluation of incidental focal liver lesions: A cost-effectiveness analysis. World journal of gastroenterology 2016; 22: 8605–8614

[30] Caoili EM, Davenport MS. Role of percutaneous needle biopsy for renal masses. Seminars in interventional radiology 2014; 31: 20–26