

Herbal Products in Postsurgical Wound Healing – Incision, Excision and Dead Space Wound Models

Authors

Anna Herman¹, Andrzej P. Herman²

Affiliations

- 1 Faculty of Health Sciences, Warsaw School of Engineering and Health, Warsaw, Poland
- 2 Department of Genetic Engineering, The Kielanowski Institute of Animal Physiology and Nutrition, Polish Academy of Sciences, Jabłonna near Warsaw, Poland

Key words

herbal products, wound healing, incision wound model, excision wound model, dead space wound model

received February 20, 2020

revised April 19, 2020

accepted April 20, 2020

Bibliography

DOI <https://doi.org/10.1055/a-1162-9988>

published online May 18, 2020 | *Planta Med* 2020; 86: 732–748 © Georg Thieme Verlag KG Stuttgart · New York | ISSN 0032-0943

Correspondence

Anna Herman, PhD, DSc, Prof.

Warsaw School of Engineering and Health,

Faculty of Health Sciences

Bitwy Warszawskiej 1920 18 street, 02-366 Warsaw, Poland

Phone: + 48 228 56 70 44, Fax: + 48 226 46 34 18

anna.herman@onet.pl

ABSTRACT

The purpose of this review is to summarize current knowledge acquired on preclinical (incision, excision, and dead space wound models) and clinical studies regarding topically used herbal products with wound healing activity. The antimicrobial, anti-inflammatory, and antioxidant mechanisms of their action as well as the adverse effects of herbal therapy will be described. Numerous preclinical and few clinical trials have confirmed the activity of herbal products in the stimulation of wound healing. In contrast to synthetic drugs, for which chemical compositions, purity, efficacy, minimal active concentration, and toxicity are well specified, several herbal formulations require further investigations. Nevertheless, it cannot be precluded that herbal products may be considered as an important support during conventional wound healing therapy or even as synthetic medicament replacements.

Introduction

Wound healing is a complex, multifactorial sequence of events involving cellular and biochemical processes initiated in response to an injury that restores the function and integrity of damaged tissues [1]. Wound healing involves continuous cell-cell and cell-matrix interactions occurring in 4 overlapping phases: (1) coagulation controlling excessive blood loss from the damaged vessels; (2) inflammation (0–3 days); (3) re-epithelialization including the proliferation, migration, and differentiation of epithelial cells of the epidermis (3–12 days); and (4) collagen deposition and remodeling within the dermis (3–6 mo.) [2]. In wound healing, the activity of an intricate network of blood cells, cytokines [tumor necrosis factor alpha (TNF α), and interleukin (IL) family], growth factors [transforming growth factor beta (TGF β), platelet-derived growth factors, epidermal growth factor, insulin-like growth fac-

tor (IGF-1), fibroblast growth factor, vascular endothelial growth factor (VEGF), granulocyte macrophage colony stimulating factor (GM-CSF), and connective tissue growth factor (CTGF)], extracellular matrix (ECM) proteins (integrin, matrikines, laminin, and fibronectin), and matrix metalloproteinases (MMPs) is involved, ultimately leading to the tissue repair and regeneration [3–5].

Wound healing therapies can be broadly classified into 2 categories: traditional (herbal- and animal-derived compounds, living organisms, silver-based products, and traditional dressings) and modern (grafts, modern dressings, bioengineered skin substitutes, and cell/growth factor therapies). These therapies have distinct levels of efficacy, clinical acceptance, and side effects [6]. Herbal drugs are the most commonly used traditional therapies for the treatment of skin wounds owing to their effectiveness and safety [7]. Data on the antibacterial and wound healing activities, such as coagulation, inflammation, fibroplasia, epithe-

lialization, collagenation, and wound contraction, of herbs are abundant in the scientific literature [8,9]. Moreover, a highly reduced wound healing time is associated with a low chance of infection, complications, and cost. Owing to the variety of biologically active compounds produced by plants, it appears that herbal products can be successfully used as stimulators for the wound healing process.

In the present review, the current knowledge on topically used herbal products for wound healing was summarized based on the search of several electronic databases concerning preclinical (incision, excision, and dead space wound models) and clinical studies. The antimicrobial, anti-inflammatory, and antioxidant mechanisms of their action as well as the adverse effects of herbal therapy will be described.

Literature Search Strategy

The PubMed, Scopus, and Google Scholar databases were searched for articles published from 2015 to the present. Search terms included “herbs and skin wounds”, “topical herbal treatments for wound healing”, “herbal treatments in incision wound model”, “herbal treatments in excision wound model”, and “herbal treatments in dead space wound model”.

Inclusion and exclusion criteria

For this review, studies pertaining to the topical administration of herbal products in wound healing (animal and human studies) were included, whereas those pertaining to the oral and systemic administration of herbal products were excluded. Only publications concerning topical application of herbal products to wounds after surgeries performed according to the incision, excision, and dead space wound model were included. A burn wound healing model was excluded from the study. Moreover, publications in languages other than English were excluded.

Study selection


Overall, 84 117 articles were found via the search of the databases. From these 61 742 articles at the titles level, duplicates and unrelated articles were removed, leaving 7410 articles for eligibility check. Finally, 86 articles were used for the review (► Fig. 1).

Herbs Used for Treatment of Wounds

Herbal products have been used in skin wound care for centuries because of their therapeutic effects, including anti-inflammatory, antioxidant, and antimicrobial activities [8,9]. The clinical efficacy of herbal products has been investigated *via* in vivo trials using both animal and human models. The most commonly used models for postsurgical wound healing are incision, excision, and dead space wound models (► Fig. 2).

Animal-based Studies

Animals, particularly rats and mice, are important models in the research on the effects of herbal products on wound healing. These models attempt to reflect human wound healing issues,

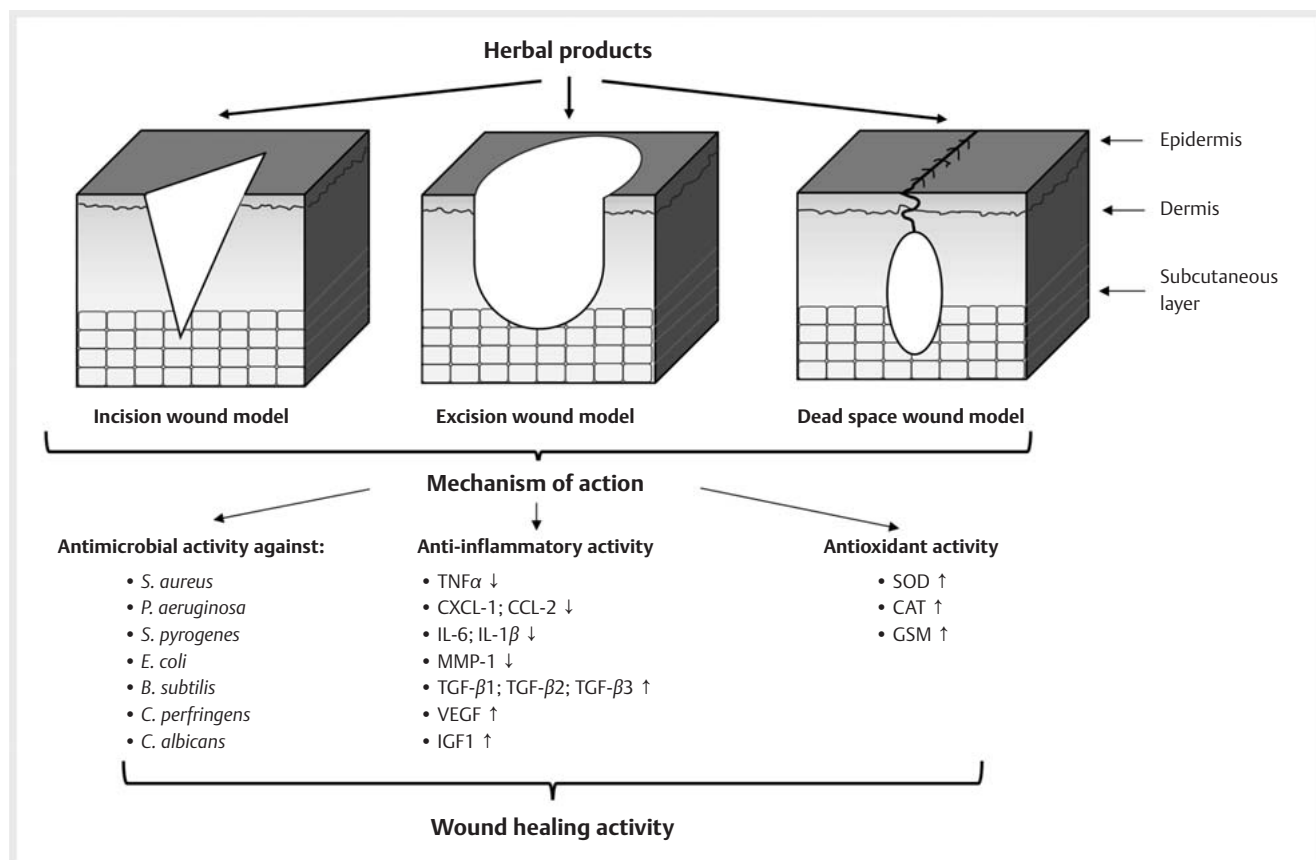


► Fig. 1 Search strategy used to identify relevant articles.

and it is thus easier to achieve approximations to the clinical situation [10]. However, it should be taken into account that many aspects of the anatomy of the skin (pigmentation, dermis, adipose tissue, skin appendages) are unique to humans compared to mice/rats. The epidermis of mice and rats have similar organization but is much thinner than the human epidermis, and their dermal connective tissue do not contain elastic fibers [2]. Moreover, the human hair follicle density is much lower than that of small animals with an abundant fur [2]. Therefore, partial-thickness wounds are rarely studied in small furred animals, because (1) performance partial-thickness wounds is a challenge; and (2) the extremely high hair density in small furred animals exaggeratedly intensifies the rate of re-epithelialization [2]. Therefore, hairless species, among them humans and pigs, are generally preferred.

Incision wound model

In rats, incisional wounds were made by sharp blade or scalpel cuts on the depilated skin of their back with no tissue loss and minimal tissue damage. The incisional wound model has been suggested to be a particularly reproducible model for scarring research and a clinically useful model for the determination of wound tensile strength [10]. Herbal products with wound healing potential tested in incision wound model are reported in ► Table 1. All herbal products improved wound healing activity via significant wound closure, increased wound breaking strength, and tensile strength, and resulted in faster wound healing in treated



► Fig. 2 Herbal products in postsurgical wound healing activity: mechanisms of action.

group compared with the control (untreated) group and active therapy (povidone-iodine, silver sulfadiazine, neomycin sulfate, gentamicin, and bacitracin zinc) group.

Excision wound model

In rats, excisional wounds were induced by the removal of some part of the skin (typically the dorsal thoracic region) at the depth of the epidermis and upper dermis—a partial thickness (or split-thickness) wound—or both epidermis and dermis up to the fascia or subcutaneous tissue—a full-thickness wound. The wounds can be left open or covered with a dressing. Excisional wounds are suggested to aid the assessment of wound re-epithelialization and wound contraction [10]. Herbal products with wound healing potential studied on excision wound models are presented in ► Table 2. All herbal products showed rapid wound contraction in shorter time, increased wound breaking strength, increased epithelialization, and granulation that is better or comparable to that of standard drugs (povidone-iodine, silver sulfadiazine, solcoseryl gel, tetracycline, neomycin sulfate, gentamycin, and amoxicillin).

Dead space wound model

The subcutaneous dead space wounds were created in the region of axilla and groin by making a pouch via a small nick in the skin. This dead space is an open area in closed tissue that prevents a tissue apposition and provides a space for blood and other fluid

influx as well as for microbial infection. Such model is suggested for the assessment of changes in the granuloma tissue as well as for the biochemical analysis of metabolites, cytokines, and growth factors [10]. To examine the action of herbal products in wound repair, test agents can be injected or implanted into the chamber as well as orally administered. Unfortunately, most dead space wound model studies described in the present review are based on the oral administration of herbal products [13, 19, 23, 29, 77]. Only a few studies have described the topical application of herbal products (► Table 3).

Human-based Studies

In comparison to several animal-based studies, there are only a few clinical trials describing the influence of herbal products and polyherbal formulation on wound healing (► Table 4). This imbalance arises from the fact that herbal products should be prepared according to some international standards in regard to the quality, purity, and sterility. Moreover, clinical trials designed to prove the efficacy of herbs as active compounds of wound healing formulations and to demonstrate their safety are expensive, prolonged, and require special permission from the regulatory authorities. Despite these limitations, some scientific studies are being performed.

► **Table 1** Herbs used for treatment of incision wounds, animal-based studies.

Herbs	Animals	Pharmacological data	Effect	Mechanism of action	Anti-microbial activity	Ref
<i>Acalypha indica</i> extract	Mice	5%, 10%, and 20% ethanol leaf extract of <i>A. indica</i> in ointment; control: ointment base; positive control: 10% povidone iodine ointment; treatment: twice a day for 14 days	5% and 10% extracts ointment showed better changes in the wound size comparison to placebo and standard groups; only 10% of extract ointment promotes the formation of granulation tissue, allowing the reepithelization phase	–	–	[11]
<i>Achillea asiatica</i> extract	Sprague-Dawley rats	3% <i>A. asiatica</i> extract; control: saline (vehicle); positive control: 3% <i>Centella asiatica</i> extract; treatment: once a day for 14 days	significantly increased epithelialization and accelerated wound healing	anti-inflammatory activity	–	[12]
<i>Achyranthes aspera</i> extract	Wistar rats	10% (w/w) ethanolic extracts in ointment; control: ointment base; positive control: 5% povidone iodine ointment; treatment: once a day for 10 days	wound breaking strength was significantly increased in extract treated group in comparison to control	–	–	[13]
<i>Aegle marmelos</i> , <i>Mucuna pruriens</i> extract	Wistar rats	hydrogel with 2.5% ethyl acetate/methanolic/aqueous <i>A. marmelos</i> or <i>M. pruriens</i> extracts; control: untreated group; positive control: Hydroheal; treatment: once daily for 12 days	both hydrogels with methanolic extracts showed significant increase in tensile strength	–	–	[14]
<i>Agave americana</i> extract	Wistar rats	5% and 10% ointment with hydroalcoholic <i>A. americana</i> leaf extract; control: ointment base; positive control: Soframycin ointment; treatment: once daily for 16 days	improved wound healing activity and increased tensile strength; rate of epithelialization almost comparable to Soframycin	–	–	[15]
<i>Aloe vera</i> gel	Rabbits	<i>A. vera</i> gel in Acacia honey; positive control: pyodine; treatment: twice daily for 10 days	wound contraction was higher in treated group than in control group and increased at day 10	–	–	[16]
<i>Alpinia galanga</i> extract	Wistar rats	2% and 5% (w/w) petroleum ether and ethanolic extract in ointment; positive control: povidone iodine ointment; treatment: once a day for 9 days	ethanol extract showed significantly faster wound healing; significant increase in the tensile strength	antioxidant activity	–	[17]
<i>Andrographis paniculata</i> extract	Wistar rats	<i>A. paniculata</i> methanolic extracts (100 mg/kg/200 mg/kg/400 mg/kg); control: untreated group; positive control: 1% Framycetin sulphate cream; treatment: once a day for 10 days	extracts were found to have greater wound healing activity and increased breaking strength	antifungal activity	<i>C. albicans</i>	[18]
<i>Archidium ohioense</i> essential oil	Wistar rats	<i>A. ohioense</i> oil (0.5 and 1.0 mg/kg bwt); control: untreated group; positive control: gentamicin; treatment: once daily for 10 days	enhanced wound breaking strength and contraction rate, tissue collagen formation, and early epithelization period	–	–	[19]
<i>Atropa belladonna</i> extract	Sprague-Dawley rats	extract in water tincture (8 g/1 L) control: untreated group; treatment: once a day, 2 and 5 days after surgery	tensile strength of tincture was significantly higher than in the untreated group	–	–	[20]

cont.

► Table 1 Continued

Herbs	Animals	Pharmacological data	Effect	Mechanism of action	Anti-microbial activity	Ref
<i>Coleus blumei</i> extract	Wistar rats	<i>C. blumei</i> (mayana) leaves ointment; control: untreated group; treatment: 15 mg, once a day for 13 days	higher wound contraction in comparison to the control group	–	–	[21]
<i>Curcuma longa</i>, <i>Cynodon dactylon</i> extract	Cattle (<i>Bos indicus</i>)	fresh <i>C. longa</i> and <i>C. dactylon</i> pastes; control: solution (10% benzoin, 90% alcohol with aloes, storax, and Tolu balsam); treatment: daily for 21 days	<i>C. dactylon</i> paste exerted wound healing activity but less effective than that of <i>C. longa</i>	–	–	[22]
<i>Curcuma longa</i>, <i>Eclipta alba</i>, <i>Tridax procumbens</i> extract	Wistar rats	poly herbal formulation with 5% and 10%; control: gel base; positive control: Aloe vera (90%) gel; treatment: once a day for 10 days	breaking strength of wound was significantly increased in all treatment groups when compared to control group	–	–	[23]
henna, pomegranate and myrrh extracts	Wistar rats	methanolic extracts alone or in a combination as a total concentration of 15% w/w in hydrophilic ointments; negative control: base ointment alone; positive control: gentamycin ointment; treatment: twice daily for 24 days	blended formulation showed the highest increase in the percent of wound contraction and decrease in the epithelization period; comparable results to the standard ointment	anti-microbial activity	<i>C. albicans</i> , <i>S. aureus</i> , <i>E. coli</i>	[24]
<i>Hydrolea zeylanica</i> extract	Wistar rats	5% (w/w) aqueous and methanol extract in ointment; negative control: ointment base; positive control: povidone iodine 5% (w/w); treatment: 10 days	increased rate of wound contraction, decreased period of epithelization and increased skin breaking strength	–	–	[25]
<i>Jatropha curcas</i> latex	Mice	10% and 15% <i>J. curcas</i> latex in cream; control: base cream; positive control: sulfadiazine 0.1% cream; treatment: twice a day for 10 days	both creams revealed moderate immune reaction to CD34 and angiogenesis activity	anti-inflammatory activity; angiogenesis activity	–	[26]
<i>Macroptilium atropurpureum</i> extract	Wistar rats	ointment with 10% (w/w) petroleum ether and 10% (w/w) aqueous extracts; control: untreated group; positive control: 15% Silver sulfadiazine; treatment: until complete healing	increased wound healing activity compared to standard drug	–	–	[27]
<i>Momordica charantia</i>, <i>Pongamia glabra</i>, <i>Piper nigrum</i> extracts	Wistar rats	10% and 15% alcoholic and aqueous extracts of <i>M. charantia</i> 1 : 1 in ointment, 10% and 15% alcoholic and aqueous extracts of <i>P. glabra</i> 1 : 1 in ointment, 10% and 15% alcoholic and aqueous extracts of <i>P. nigrum</i> 1 : 1 in ointment; control: ointment base; positive control: Povidone iodine ointment; treatment: once daily for 10 days	decreased wound area, no mortality observed in the course of study	–	–	[28]
<i>Palisota hirsuta</i> extract	Wistar rats	1%, 2%, and 4% (w/w) methanol leaf extract of <i>P. hirsuta</i> in petroleum jelly; control: petroleum jelly; positive control: Cicatrin® powder (Neomycin Sulphate, Bacitracin Zinc); treatment: once daily for 10 days	4% (w/w) extract showed the highest wound breaking strength	–	–	[29]

cont.

► **Table 1** Continued

Herbs	Animals	Pharmacological data	Effect	Mechanism of action	Anti-microbial activity	Ref
<i>Plumbago zeylanica</i> , <i>Datura stramonium</i> , <i>Argemone mexicana</i> extract	Wistar rats	2% and 5% polyherbal formulation (methanolic extracts of <i>P. zeylanica</i> , <i>D.stramonium</i> , <i>A. mexicana</i> in ratio 4:4:2) in carbopol-940 gels; control 1: untreated; negative control: gel base; positive control: 5% povidone iodine ointment; treatment: 250 mg, once daily for 9 days	the high rate of wound contraction, early epithelialization period, and increased wound breaking strength	antimicrobial activity	<i>S. aureus</i> ; <i>B. subtilis</i> ; <i>E. coli</i> ; <i>P. aeruginosa</i>	[30]
<i>Pterolobium hexapetalum</i> extract	Wistar rats	2.5% and 5% (w/w) methanol extract in ointment; control: ointment base; positive control: Neomycin 5% (w/w); treatment: once a day for 10 days	tensile strength of wound treated with 5% ointment comparable to that of neomycin ointment	–	–	[31]
<i>Punica granatum</i> peel and pulp	Wistar rats	hydroalcoholic extract of pomegranate peel/hydroalcoholic extract of pomegranate pulp/peel + pulp; control: Eucerin; positive control: phenytoin; treatment: after wound establishment (14 days), twice a day for 14 days	peel significantly improved the wound healing process, whereas the pulp showed no promising effects	–	–	[32]
<i>Salvadora persica</i> extracts	Wistar rats	carbopol gel containing 1% methanolic extract of <i>S. persica</i> ; control 1: untreated group; control 2: carbapol gel; positive control: betadine; treatment: 16 days	higher rate of contraction and reduced the period of epithelialization	antimicrobial activity	<i>C. perfringens</i> , <i>C. albicans</i> , <i>P. aeruginosa</i> , <i>S. aureus</i>	[33]
<i>Sesamum Indicum</i> extract	Wistar rats	ethosomal vesicles with <i>S. Indicum</i> seed extract in gel base; control: ointment base; positive control: povidone iodine ointment; treatment: once a daily for 10 days	tensile strength of skin was similar to that of standard treated group	–	–	[34]
<i>Sida rhombifolia</i> extract	albino mice	80% ethanolic leaves extract ointment and water preparations; control: untreated group; control negative: ointment base; positive control: povidone iodine; treatment: 10 days	significant wound closure for all ointment and water formulations	–	–	[35]

Mechanism of Action of Herbs Used for Treatment of Wounds

Many herbal products can be successfully used in the treatment of wounds owing to various mechanisms inducing healing and regeneration of the skin such as antimicrobial, anti-inflammatory, and antioxidant activities (► **Fig. 2**).

Antimicrobial activity of herbal products

Wound infection is probably the most common reason for impaired wound healing. Pathogens including *Staphylococcus aureus*, *Streptococcus pyogenes*, *Corynebacterium* sp., *Escherichia coli*, and *Pseudomonas aeruginosa* are the primary causes of delayed healing

and infection in acute wounds [84]. Therefore, topical antimicrobial therapy is one of the most important methods of wound care. An ideal agent for prevention and control of wound infection should directly destroy the pathogens as well as reduce local inflammation and tissue destruction. The use of herbal products for the treatment of wounds provides such opportunities (► **Tables 1 to 3**). The hydroalcoholic extracts of *Althaea officinalis* [37] and *Angelica dahurica* and ethanolic extract of *Rheum officinale* alone and in a 1:1 combination [39]; the methanolic extracts of henna, pomegranate, and myrrh alone or in a combination at a total concentration of 15% (w/w) in hydrophilic ointments [24]; 2% and 5% polyherbal formulation with methanolic extracts of *Plumbago zeylanica*, *Datura stramonium*, and *Argemone mexicana* (in ratio a 4:4:2) in carbopol-940 gels [30]; 1% methanolic

► **Table 2** Herbs used for treatment of excision wounds, animal-based studies.

Herbs	Animals	Pharmacological data	Effect	Mechanism of action	Anti-microbial activity	Ref
<i>Achyranthes aspera</i> extract	Wistar rats	10% (w/w) ethanolic extracts in ointment; control: ointment base; positive control: 5% povidone iodine ointment; treatment: twice a day for 15 days	enhanced wound contraction and epithelization period	–	–	[13]
<i>Aegle marmelos</i> , <i>Mucuna pruriens</i> extract	Wistar rats	hydrogel with 2.5% ethyl acetate/methanolic/aqueous <i>A. marmelos</i> or <i>M. pruriens</i> extracts; control: untreated group; positive control: Hydroheal; treatment: once daily for 12 days	extract hydrogels were found to be superior to all other treatments by rapid wound contraction, lesser number of days required for complete epithelization	–	–	[14]
<i>Aegle marmelos</i> , <i>Ocimum basilicum</i> extract	Wistar rats	5% (w/w) ethanolic extract of leaves of <i>A. marmelos</i> / <i>O. basilicum</i> in ointment; control: untreated group; positive control: 5% povidone iodine ointment; treatment: once a day for 15 days	<i>A. marmelos</i> extract have better wound healing effect than extract of <i>O. basilicum</i> ; <i>A. marmelos</i> extract showed faster rate of healing when compared with drug	–	–	[36]
<i>Agave americana</i> extract	Wistar rats	5% and 10% ointment with hydroalcoholic <i>A. americana</i> leaf extract; control: ointment base; positive control: Soframycin ointment; treatment: once daily for 16 days	improved wound healing activity; rate of epithelization was almost comparable to Soframycin; increase in tensile strength	–	–	[15]
<i>Althaea officinalis</i> extract	Wistar rats	hydroalcoholic extract; control: untreated group; positive control: zinc oxide ointment; treatment: 0.5 g, once a day for 21 days	significantly increased wound healing percent	antimicrobial activity	<i>S. aureus</i> , <i>L. monocytogenes</i>	[37]
<i>Aloe vera</i> , <i>Commiphora myrrha</i> , <i>Boswellia carteri</i> extracts	Wistar rats	10% and 40% extracts in ratio 1 : 1 : 1 in ointment; control 1: untreated group; control 2: ointment base; positive control: tetracycline ointment; treatment: every day for 21 days	40% ointment showed significant healing effect in comparison to the control, tetracycline, and paste base groups	–	–	[38]
<i>Andrographis paniculata</i> extract	Wistar rats	<i>A. paniculata</i> methanolic extracts (100 mg/kg/200 mg/kg/400 mg/kg); control: untreated group; positive control: 1% Framycetin sulphate cream; treatment: once a day till complete of epithelization	extract was found to have greater wound healing activity and to increase the percentage wound concentration and period of epithelization	antifungal activity	<i>C. albicans</i>	[18]
<i>Angelica dahurica</i> , <i>Rheum officinale</i> extract	Sprague-Dawley rats	<i>A. dahurica</i> extract, <i>R. officinale</i> extract alone and in combination 1 : 1; control: saline; positive control: Biomyacin; treatment: 1 μ L/mm ² daily for 21 days	wound contraction mixed extracts group was significantly higher than that in control and biomyacin groups	anti-inflammatory activity	<i>S. aureus</i>	[39]
<i>Anredera cordifolia</i> extract	Guinea pigs	ethanolic extract of binahong (<i>A. cordifolia</i>) leaves at concentrations of 10%, 20%, and 40%; negative control: distilled water; positive control: povidone iodine 10%; treatment: twice daily for 15 days	groups treated with ethanolic extract of binahong leaves at concentrations of 20% and 40% experienced better wound healing activity than negative and positive controls	–	–	[40]
<i>Archidium ohioense</i> oil	Wistar rats	<i>A. ohioense</i> oil (0.5 and 1.0 mg/kg bwt); control: untreated group; positive control: gentamicin; treatment: once daily for 21 days	enhanced wound breaking strength and contraction rate, tissue collagen formation, and early epithelization period	–	–	[19]

cont.

► **Table 2** Continued

Herbs	Animals	Pharmacological data	Effect	Mechanism of action	Anti-microbial activity	Ref
<i>Arnebia euchroma</i> extract	Rats	10% <i>A. euchroma</i> gel; control 1: saline; control 2: carboxymethyl cellulose gel; treatment: once a day for 14 days	reduction of wound surface	–	–	[41]
<i>Bauhinia tomentosa</i> extract	Wistar rats	extract alone, Emu oil alone, combination of extract and Emu oil; control: vaseline alone; positive control: soframycin ointment; treatment: 2 g/2 ml, once a day for 21 days	Emu oil with extract showed more significant results when compared to soframycin ointment	–	–	[42]
<i>Boerhavia diffusa</i> extract	Wistar rats	10% methanol and 10% chloroform extracts in ointment; control 1: untreated group; control 2: ointment base; positive control: 5.0% w/w povidone-iodine; treatment: 500 mg, once a day for 14 days	efficacy of methanol extract ointments to heal wounds was comparable with that of the standard drug	–	–	[43]
<i>Centella asiatica</i> extract	New Zealand rabbits	40%, 10%, 2.5% (w/w) methanol fraction of the extract in aqueous cream; control 1: no treatment; control 2: blank aqueous cream; positive control: solcoseryl jelly 10%; treatment: twice daily (20 mg) until the wounds completely healed	extracts showed comparable results to the positive control; methanol fraction of the extract induced collagen synthesis	–	–	[44]
<i>Chromolaena odorata</i> extract	Wistar rats	2.5%, 5%, 7.5% (w/w) aqueous and ethanolic extracts in petroleum jelly; control: petroleum jelly; positive control: 5% povidone-iodine ointment; treatment: 20 days	5% extract-treated groups exhibited a faster reduction in wound area compared to control and treated groups	–	–	[45]
<i>Croton bonplandianum</i> extract	Wistar rats	herbal preparations from leaf, fruit and latex of <i>C. bonplandianum</i> and α -tocopherol; control: untreated group	increased levels of collagen content and wound contraction rate	antioxidant activity	–	[46]
<i>Curcuma longa</i> , <i>Eclipta alba</i> , <i>Tridax procumbens</i> extract	Wistar rats	poly herbal formulation with 5% and 10%; control: gel base; positive control: <i>Aloe vera</i> (90%) gel; treatment: once a day for 22 days	significantly reduced period of epithelization as compared with control group	–	–	[23]
<i>Datura Stramonium</i> extract	Wistar rats	10% (w/w) hydro-alcoholic extract in ointment; control: ointment base; positive control: povidone-iodine ointment; treatment: 16 days	extract ointment showed significant wound healing activity comparable to that of the standard drug	–	–	[47]
<i>Enicostema littorale</i> extract	Wistar rats	15% (w/w) ethanolic leaf extract in ointment and its active constituent 3% (w/w) pure Swertiamarin in ointment; control: ointment base; treatment: once a day for 15 days	ethanolic extract and Swertiamarin ointment resulted in decrease of the wound area; Swertiamarin-treated group had a high percentage of wound contraction score	–	–	[48]
<i>Euphorbia tirucalli</i> extract	Albino mice	50%, 75%, and 100% <i>E. tirucalli</i> latex (milk bush); control: destill water; positive control: povidone-iodine; treatment: 6 days	positive wound healing effect as manifested by the formation of scar tissue, which effectively led to wound closure	–	–	[49]
<i>Euterpe oleracea</i> extracts	Sprague Dawley rats	1%, 3%, 5% acai berry water extract; control: ointment base; positive control: 2% sodium fusidate ointment; treatment: 200 μ L, once a day for 18 days	significantly reduced wound area at 6 days after creating the wound and reepithelization after 18 days	anti-inflammatory activity	–	[50]

cont.

► Table 2 Continued

Herbs	Animals	Pharmacological data	Effect	Mechanism of action	Anti-microbial activity	Ref
Falcaria vulgaris extract	Wistar rats	3% aqueous extract of <i>F. vulgaris</i> ointment; control 1: untreated group; control 2: Eucerin ointment; positive control: 3% tetracycline ointment; treatment: for 30 days	significant decrease in the levels of wound area, wound contracture, hydroxyproline, hexosamine, fibrocyte, fibroblast	–	–	[51]
Glycyrrhiza glabra extract	Guinea Pig	5% and 10% (w/w) <i>G. glabra</i> extract in cream; control: untreated group; positive control: 1% phenytoin; treatment: once a day for 12 days	increased epidermal formation, collagen deposition, and neovascularization, decreased acute inflammation; 10% cream was more effective than 5% cream	–	–	[52]
Glycyrrhiza glabra, Nerium indicum extract	Wistar rats	Honey, Ghee, <i>G. glabra</i> and <i>N. indicum</i> alone and a combination; control: untreated group; treatment: 500 mg once a day for 16 days	rapid epithelization and better remodeling	–	–	[53]
henna, pomegranate and myrrh extracts	Wistar rats	extracts alone or in a combination with total concentration of 15% w/w in hydrophilic ointments; negative control: base ointment; positive control: gentamycin ointment; treatment: twice daily for 24 days	the blended formulation showed the highest increase in the percent of wound contraction; decrease in the epithelization period comparable to the standard ointment	antimicrobial activity	<i>C. albicans</i> , <i>S. aureus</i> , <i>E. coli</i>	[24]
Hippophae rhamnoides extract	Sprague-Dawley rats	hydrogel containing 100 mg of powdered extract; control 1: sterile gauze; control 2: hydrogel only; control 3: hydrogel with 100 mg ascorbic acid; treatment: applied weekly for 21 days	significantly reduced wound size	–	–	[54]
Hydrolea zeylanica extract	Wistar rats	5% (w/w) aqueous and methanol extract in ointment; negative control: ointment base; positive control: povidone iodine 5% (w/w); treatment: until wound is completely healed	increased rate of wound contraction, decreased period of epithelization and increased skin breaking strength	–	–	[25]
Justicia tranquebariensis, Aloe vera, Curcuma longa extracts	Wistar rats	lotions with 10% and 20% ethanolic extracts; control: untreated group; positive control: Soframycin; treatment: once daily for 15 days	complete wound healing was observed with both lotions in 15 days as that of Soframycin ointment	antimicrobial activity	<i>E. coli</i> , <i>K. pneumoniae</i> , <i>S. aureus</i> , <i>B. subtilis</i>	[55]
Lawsonia inermis extract	Sprague Dawley rats	<i>Lawsonia inermis</i> extract; control 1: saline; control 2: hydrogel; positive control: Silver Zinc sulfadiazine; treatment: twice a day for 15 days	the wound size reduction and rate of epithelialization; significant increase in collagen and fibroblasts, reduced inflammatory cell number	–	–	[56]
Linum usitatissimum extract	Wistar rats	5% and 10% <i>L. usitatissimum</i> (LU) gel; control 1: untreated group; control 2: gel base; treatment: once a day for 15 days	significantly higher wound areas, collagen bundle synthesis	–	–	[57]
Macroptilium atropurpureum extract	Wistar rats	ointment of 10% (w/w) petroleum ether and 10% (w/w) aqueous extracts; control: untreated group; positive control: 15 Silver sulfadiazine; treatment: until complete healing	wound healing effect comparable to standard drug	–	–	[27]

cont.

► **Table 2** Continued

Herbs	Animals	Pharmacological data	Effect	Mechanism of action	Anti-microbial activity	Ref
Momordica charantia , <i>Pongamia glabra</i> , <i>Piper nigrum</i> extracts	Wistar rats	10% and 15% alcoholic and aqueous extracts of <i>M. charantia</i> 1 : 1 in ointment, 10% and 15% alcoholic and aqueous extracts of <i>P. glabra</i> 1 : 1 in ointment, 10% and 15% alcoholic and aqueous extracts of <i>P. nigrum</i> 1 : 1 in ointment, combination of all extracts (5% each) in ointment; control: ointment base; positive control: Povidone iodine ointment; treatment: once daily for 10 days	decreased wound area, no mortality observed in the course of study	–	–	[58]
Nigella sativa oil	Wistar rats	honey, <i>N. sativa</i> seed oil and their combination 1 : 1 ratio; control: lanolin; positive control: phenytoin cream; treatment: 20 days	wound surface areas in the mix group were significantly lower than in the other groups followed by the phenytoin, honey, <i>N. sativa</i> , and control groups	–	–	[59]
Nigella sativa seed powder	Wistar rats	<i>N. sativa</i> seed powder; control: untreated group; positive control: Amoxicillin; treatment: 500 mg, once a day till complete epithelialization up to 14 days	powder has faster recovery rate than the standard drug	–	–	[60]
Nigella sativa , Hypericum perforatum extract	Wistar rats	50% <i>N. sativa</i> extract in cream and 50% <i>H. perforatum</i> extract in cream; control: cream base; treatment: twice a day for 14 days	<i>N. sativa</i> cream had more antioxidant properties than the other treatments; <i>H. perforatum</i> cream increased epithelialization and granulation	–	–	[61]
Plantago lanceolata extract	Mice	ointment with 10% and 20% <i>P. lanceolata</i> extract; control: untreated group; control: vaseline; treatment: 21 days	both concentrations of <i>P. lanceolata</i> extract exhibited positive effects on wound healing	–	–	[62]
Plumbago zeylanica , Datura stramonium , Argemone mexicana extract	Wistar rats	2% and 5% polyherbal formulation (methanolic extracts of <i>P. zeylanica</i> , <i>D. stramonium</i> , <i>A. mexicana</i> in ratio 4 : 4 : 2) in carbopol-940 gels; control 1: untreated; negative control: gel base; positive control: 5% w/w povidone iodine ointment; treatment: 500 mg, once daily until the complete healing	the high rate of wound contraction, early epithelialization period, and increased wound breaking strength	antimicrobial activity	<i>S. aureus</i> ; <i>B. subtilis</i> ; <i>E. coli</i> ; <i>P. aeruginosa</i>	[30]
Psoralea corylifolia , Achrynanthes aspera extract	Wistar rats	polyherbal ointment with hydrochloric extracts 1 : 1; control: ointment base; positive control: cipladine; treatment: once daily for 14 days	polyherbal ointment produced greater wound contraction than the other tested formulations	–	–	[63]
Pterolobium hexapetalum extract	Wistar rats	2.5% and 5% (w/w) methanol extract in ointment; control: ointment base; positive control: Neomycin 5% (w/w); treatment: once a day for 21 days	the highest wound contraction percentage and lowest epithelialization period of 5% ointment in comparison to control group	–	–	[31]
Punica granatum extract	Wistar rats	10% dried powder of <i>P. granatum</i> in ointment; control: vaseline; positive control: Fucidin ointment; treatment: once a day for 19 days	dry powder promoted healing in shorter time (13 days) than drugs (17 days)	–	–	[64]

cont.

► Table 2 Continued

Herbs	Animals	Pharmacological data	Effect	Mechanism of action	Anti-microbial activity	Ref
<i>Rheum emodi</i> extract	Rabbits	10% ethanolic, aqueous, petroleum ether extracts and crude powder; positive control: povidone-iodine ointment; treatment: 12 days	wound healing activity: petroleum ether extract > aqueous extract > ethanolic extract > crude dust powder > control group	antibacterial activity	–	[65]
Rosehip oil	Wistar rats	Rosehip oil; control: untreated group; treatment: once daily for 21 days	wound contracting ability of rosehip oil was significantly higher when compared to the control group	anti-inflammatory activity	–	[66]
<i>Salix acmophylla</i> extract	Rabbits	5% ethanolic and 5% aqueous extract in ointment (sofr paraffin); control: untreated group; treatment: till the wound heals completely	wound closure: ethanolic extract (14 days) > aqueous extract (17 days) > control group (20 days)	antioxidative activity	–	[67]
<i>Salvadora persica</i> extract	Wistar rats	vaseline with 10% (w/w) <i>S. persica</i> extract; control: vaseline; positive control: Solcoseryl jelly 10%; treatment: once daily until the complete healing of wound	<i>S. persica</i> extract significantly enhanced acceleration rate of wound enclosure	–	–	[68]
<i>Salvadora persica</i> extracts	Wistar rats	carbopol gel containing 1% methanolic extract; control 1: untreated group; control 2: carbapol gel; positive control: betadine; treatment: 16 days	higher rate of contraction and reduced period of epithelialization	antimicrobial activity	<i>C. perfringens</i> , <i>C. albicans</i> , <i>P. aeruginosa</i> , <i>S. aureus</i>	[33]
<i>Sambucus ebulus</i> extract	Wistar rats	5% methanol extract in ointment; control: untreated group; negative control: ointment base; treatment: once a day for 12 days	extract improved wound contraction and closure, reduced the number of inflammatory cells, increased wound-healing rate and epithelialization, significantly improved collagen formation and granulation tissue formation	–	–	[69]
<i>Satureja khuzistanica</i> extract	Wistar rats	<i>S. khuzistanica</i> ethanolic extract and encapsulated extract of <i>S. khuzistanica</i> in hydrogel alginate; control 1: untreated group; control 2: hydrogel alginate; treatment: 22 days	encapsulated extract in hydrogel alginate may accelerate wound improvement and increase the rate of wound healing without scar formation	–	–	[70]
<i>Schinus terebinthifolius</i> oil	C57BL/6 mice	ointment containing 10% oil; control: ointment base (lanolin/vaseline base); treatment: once a day for 14 days	oils promoted a reduction in leucocyte accumulation and in pro-inflammatory cytokine; significantly increased the number of blood vessels and collagen fibers deposition in comparison to control group	anti-inflammatory activity	–	[71]
<i>Scrophularia striata</i> extract	Sprague-Dawley rats	5% and 10% <i>S. striata</i> extract; control 1: untreated group; control 2: basal cream; positive control: tetracycline (3%); treatment: 1 ml, 30 days	significant decrease in the wound area, alignment of the healing tissue, re-epithelialization and epithelial formation, enhanced maturity of the collagen fibers and fibroblasts and large capillary-sized blood vessels	–	–	[72]
<i>Sesamum indicum</i> extract	Wistar rats	ethosomal vesicles with <i>S. Indicum</i> seed extract in gel base; control: ointment base; positive control: povidone iodine ointment; treatment: once a day, till the complete wound healing	increase wound contraction, period of epithelialization	–	–	[34]

cont.

► **Table 2** Continued

Herbs	Animals	Pharmacological data	Effect	Mechanism of action	Anti-microbial activity	Ref
<i>Sida rhombifolia</i> extract	Albino mice	50%, 33%, and 25% formulated 80% ethanolic leaves extract ointment and water preparations; control: untreated group; control negative: ointment base; positive control: Povidone Iodine; treatment: 15 days	significant wound closure for all ointment and water formulations	–	–	[35]
<i>Stevia rebaudiana</i> extract	Wistar rats	10% ethanol extract of <i>S. rebaudiana</i> control 1: untreated group; control 2: cream base; positive control: tetracycline (3%); treatment: 1 mL, once a day for 20 days	significant reduction in the wound area; improved re-epithelization and epithelial formation; decrease in the total number of cells, fibrocytes/fibroblasts ratio, neutrophils, and lymphocytes and enhanced number of blood vessels and fibroblasts at day 20	–	–	[73]
<i>Tridax procumbens</i> , <i>Vitex negundo</i> , <i>Emblca officinalis</i> Gaertn extracts	Wistar rats	polyherbal formulation (aqueous extracts were mixed in equal proportion and added to the cream); control: untreated; positive control: Cipladine; treatment: once a day for 15 days	polyherbal formulation showed rapid regeneration of skin and wound contraction; proliferation and mobilization of fibroblast and keratinocytes; promotion of angiogenesis	–	–	[74]
<i>Urtica dioica</i> , <i>Sambucus ebulus</i> extracts	Wistar rats	2%, 5% <i>U. dioica</i> extracts ointment; 2%, 5% <i>S. ebulus</i> extracts ointment; 2%, 5% combination of extract ointment; control: untreated; negative control: Eucerin; positive control: phenytoin; treatment: once a day for 21 days	ointments with extracts and their combination possess strong wound healing properties; the best results were observed with the <i>S. ebulus</i> (2%) and the combination 2% groups	–	–	[75]
<i>Zingiber zerumbet</i> extract	Wistar rats	5% <i>Z. zerumbet</i> ethyl acetate extract; control: PBS; positive control: solcoseryl gel; treatment: once a day for 14 days	increased wounds closure and hydroxyproline levels	–	–	[76]
<i>Ziziphus mauritiana</i> extract	Wistar rats	5% (w/w) ethanolic extract in ointment base; control: untreated group; positive control: povidine iodine 5% (w/w); treatment: 2.5 g once a day for complete healing	treatment with extract promoted the wound contraction and reduced the days required for epithelization	–	–	[77]

extract of *Salvadora persica* in carbopol gel [33]; and 10% and 20% ethanolic extracts of *Justicia tranquebariensis*, *Aloe vera*, and *Curcuma longa* in lotions [55] exhibit antibacterial activities against gram-negative (*P. aeruginosa*, *E. coli*, *Klebsiella pneumoniae*) and gram-positive (*S. aureus*, *Bacillus subtilis*, *S. pyogenes*, *Listeria monocytogenes*, and *Clostridium perfringens*) bacteria. Moreover, methanolic extract of *Andrographis paniculata* [18], 1% methanolic extract of *S. persica* in carbopol gel [33], and methanolic extracts of henna, pomegranate, and myrrh [24] additionally inhibit *Candida albicans* growth.

Anti-inflammatory activity of herbal products

Inflammation at the early phase of wound repair is essential for preventing microbial infection and scavenging of dead cells and cellular debris. Furthermore, it generates proinflammatory mediators such as interleukin (IL-1, IL-6, IL-12), TNF α , inducible nitric

oxide synthase (iNOS), and chemokines, which play a major role in the inflammation process during wound healing [3, 85]. Moreover, it was shown that the macrophages with a proinflammatory M1 phenotype are more often found in the early stages of repair, whereas those with anti-inflammatory M2 phenotypes, which are prorepair, are present in the latter stages of wound healing [86]. Therefore, later during the healing process, macrophages expressing anti-inflammatory mediators (such as IL-1 receptor antagonist, decoy IL-1 receptor type II, and IL-10) as well as growth factors (such as TGF β , VEGF, and IGF1) are present, promoting fibroblast proliferation, ECM synthesis, and angiogenesis [87]. In the final phase of healing, macrophages also regulate ECM content and remodeling by secretion of proteases and their inhibitors such as MMPs and tissue inhibitors of metalloproteinase (TIMPs) [88]. MMPs catalyze the hydrolysis of major ECM molecules (including collagen, elastin, laminin, and fibronectin) as well as the

► **Table 3** Herbs used for treatment of dead space wounds, animal-based studies.

Herbs	Animals	Pharmacological data	Effect	Mechanism of action	Anti-microbial activity	Ref
<i>Aegle marmelos</i> , <i>Mucuna pruriens</i> extract	Wistar rats	hydrogel with 2.5% ethyl acetate/methanolic/aqueous <i>A. marmelos</i> or <i>M. pruriens</i> extracts; control: untreated group; positive control: Hydroheal; treatment: once daily for 12 days	extract hydrogels were found to be superior to all other treatments by significant increase in hydroxyproline content	–	–	[14]
<i>Alpinia galanga</i> extract	Wistar rats	2% and 5% (w/w) petroleum ether and ethanolic extract in ointment; positive control: povidone iodine ointment; treatment: once a day for 9 days	ethanol extract showed significantly faster wound healing; hydroxyproline content and protein content were significantly higher in both ethanolic extract group	antioxidant activity	–	[17]
<i>Archidium ohioense</i> oil	Wistar rats	<i>A. ohioense</i> oil (0.5 and 1.0 mg/kg bwt); control: untreated group; positive control: gentamicin 0.5 mg/kg bwt and 1.0 mg/kg bwt; treatment: once daily for 10 days	wound breaking strength and contraction rate, tissue collagen formation, and early epithelization period	–	–	[19]
henna, pomegranate and myrrh extracts	Wistar rats	henna, pomegranate, and myrrh methanolic extract alone or in a combination at a total concentration of 15% (w/w) in hydrophilic ointments; negative control: ointment base; positive control: gentamicin ointment; treatment: twice daily for 24 days	the blended formulation showed the highest increase in the percent of wound contraction and decrease in the epithelization period comparable with standard ointment	antimicrobial activity	<i>C. albicans</i> , <i>S. aureus</i> , <i>E. coli</i>	[24]
<i>Martynia annua</i> , <i>Tephrosia purpurea</i> extracts	Wistar rats	ointment with 5% (w/w) methanol fraction of <i>M. annua</i> (MAF-C) and ethyl acetate fraction of <i>T. purpurea</i> (TPF-A); ointments with pongamol (0.2 and 0.5% w/w); ointments with luteolin (0.2 and 0.5% w/w); control: ointment base; positive control: 5% povidone iodine ointment; treatment: twice a day for 9 days	5% w/w ointment of TPF-A and MAF-C fractions were more effective than isolated flavonoids in wound healing; significantly increased the hydroxyproline and protein contents	–	–	[78]
<i>Pterolobium hexapetalum</i> extract	Wistar rats	2.5% and 5% (w/w) methanol extract in ointment; control: ointment base; positive control: Neomycin 5% (w/w); treatment: once a day for 9 days	the highest hydroxyproline content are comparable with standard Neomycin	–	–	[31]

processing of cytokines and growth factors, which finally leads to regeneration of the injured skin and scar formation [89]. The herbal products with anti-inflammatory properties may prove beneficial for successful wound healing (► **Tables 1 to 3**).

In wounds treated with herbal products, a reduction in leucocytes accumulation and proinflammatory mediators, such as IL and TNF α , was promoted. A significant reduction in TNF- α , CXCL-1, and CCL-2 levels as well as in neutrophil and macrophage accumulation was observed following topical treatment of 10% *Schinus terebinthifolius* oil ointment [71]. Moreover, *A. dahurica* and *R. officinale* extracts alone and in a combination 1:1 led to a reduction in plasma TNF- α , TGF- β 1, and IL-6 levels [39]. Further, 1%, 3%, and 5% *Euterpe oleracea* (acai berry) water extract decreased IL-1 β expression levels, whereas TNF- α expression levels were similar among different treatment groups in comparison to

the vehicle control-treated group [50]. Some research suggests that the M1 to M2 macrophage phenotype transition is a pivotal step in the successful healing process [86]. Reportedly, rosehip oil promoted wound healing by facilitating this transition [66]. Moreover, rosehip oil increased collagen III content in wound tissue and inhibited epithelial-mesenchymal transition during wound healing to improve scars.

It is well known that TGF- β produced by macrophages promotes the generation of myofibroblasts from some fibroblasts and increases collagen synthesis, resulting in ECM contraction and subsequent wound closure [90]. Moreover, TGF- β 1 and TGF- β 2 promote scar tissue, whereas TGF- β 3 may reduce scar formation [91]. An *Achillea asiatica* extract (3%) stimulated collagen expression in Hs68 fibroblasts by activating TGF- β and stimulated keratinocyte differentiation and motility by inducing β -catenin,

► **Table 4** Herbs used for treatment of wounds, human-based studies.

Herbs	Model of the study	Pharmacological data	Effect	Ref
Achillea millefolium, Hypericum perforatum extract	double-blind clinical trial; 140 primiparous women: <ul style="list-style-type: none"> 35 women: without intervention 35 women: placebo ointment 35 women: <i>H. perforatum</i> ointment 35 women: <i>A. millefolium</i> ointment 	<i>A. millefolium</i> and <i>H. perforatum</i> ointments; control: ointment base; treatment: twice a day for 10 days	both extracts ointments reduced perineal pain level, redness, edema, and ecchymosis of episiotomy wound	[79]
Aloe vera gel	prospective, randomized double-blind clinical; 90 women after cesarean operation: <ul style="list-style-type: none"> 45 women: without intervention 45 women: <i>A. vera</i> gel 	<i>A. vera</i> mucilage gel; treatment: once after cesarean operation	no statistically significant differences between control and treatment group	[80]
Calendula officinalis extract	randomized controlled clinical trial; 72 primiparous women with surgical childbirth: <ul style="list-style-type: none"> 36 patients: calendula ointment 36 patients: routine care 	2% hydroalcoholic extract of <i>C. officinalis</i> in ointment; routine care group; treatment: every 12 hours for 10 days	increased speed of cesarean wound healing	[81]
grape seed extract	double blind clinical trial; 40 patients with excision of the lesions: <ul style="list-style-type: none"> 20 patients: cream base 20 patients: extract cream 	cream with 2% grape seed extract; control: cream base; treatment: twice daily for 21 days	complete repair of wounds on day 8 in the treatment group and on day 14 in the placebo group	[82]
green tea extract	randomized, double-blind, placebo-controlled clinical trial; 99 primiparous women	green tea ointment group; placebo ointment group; routine care group; treatment: 2 cm of the green tea/placebo ointments, twice daily for 10 days	better and faster healing in the green tea group in comparison to the other 2 groups; effective in relieving episiotomy pain	[83]

Akt, and keratinocyte differentiation markers [12]. An *E. oleracea* water extract (5%) increased type I collagen, VEGF, and fibronectin mRNA expression levels and decreased MMP-1 (collagenase) and IL-1 β mRNA expression levels simultaneously, confirming the wound healing activity of herbs [50].

However, although studies on the mechanisms of action of herbal products on wound healing primarily focus on several cytokines and growth factors, the signaling pathways that the products utilize to cause the effect is unclear or not described at all in these studies. Similarly, molecules/active constituents from herbs responsible for wound healing activities as well as their mechanisms of action remain unelucidated.

Antioxidant activity of herbal products

The production of reactive oxygen species (ROS) (e.g., superoxide anion, hydroxyl radicals, singlet oxygen, and hydrogen peroxide) in the wound may affect the wound healing process [92]. Low ROS levels are essential in stimulating effective wound healing, whereas excessive ROS release results in cellular damage and impaired wound repair [93]. Low ROS levels (1) appear important in coordinating the recruitment of lymphoid cells to the wound site, (2) regulate the formation of blood vessels (angiogenesis) at the wound site and the optimal perfusion of blood into the wound healing area, and (3) protect the wound against bacterial and other microbial infections (antimicrobial activity) [88]. On the contrary, excessive ROS levels can damage cells by oxidation of cellular macromolecules such as lipids, proteins, collagen, proteogly-

can, and hyaluronic acid [92]. Antioxidative enzymes [catalase (CAT), peroxidases, peroxiredoxins, and low molecular weight antioxidants] rapidly detoxify ROS and simultaneously affect the wound healing process [94]. Furthermore, some herbal products and their active constituents demonstrate significant antioxidant activity that may facilitate wound healing (► **Tables 1 to 3**). Superoxide dismutase (SOD), CAT, and glutathione (GSH) concentrations in granulation tissue were significantly increased following the topical application of ointment containing 2% and 5% (w/w) ethanolic extract of *Alpinia galanga* [17]. Moreover, topical application of ointment containing 5% ethanolic and 5% aqueous *Salix acmophylla* extract increased CAT concentration and decreased lipid peroxidation product (malondialdehyde) concentration in granulation tissue [67]. Increased SOD and CAT concentration and reduced lipid peroxidation product concentration were found in granulation tissue of wounded rats treated with herbal preparations with leaf, fruit, and latex of *Croton bonplandianum* and α -tocopherol [46]. The wounded rats treated with latex of *C. bonplandianum* demonstrated increased antioxidant activity, significant wound contraction rate, and higher collagen content compared with other herbal preparations.

Safety of Herbal Therapy

Following the topical application of herbs used in wound healing, such as *Archidium ohioense* oil [19], *Macroptilium atropurpureum* extract [27], *Centella asiatica* extract [44], mixture of *P. zeylanica*,

D. stramonium and *A. mexicana* [30], *Martynia annua* and *Tephrosia purpurea* extracts [78], *Bauhinia tomentosa* oil [42], *Agave americana* extract [15], *Achyranthes aspera* extract [13], *Enicostema littorale* extract [48], *C. longa*, *Eclipta alba*, and *Tridax procumbens* extracts [23], *A. paniculata* extract [18], *Hydrolea zeylanica* extract [25], *Pterolobium hexapetalum* extract [31], *Sesamum indicum* extract [34], *S. persica* extract [33], and *Aegle marmelos* and *Mucuna pruriens* extract [14], no irritation, inflammation, toxicity, erythema, eschar, and edema occurred in acute dermal toxicity test and/or skin irritation test in animal wound models (► **Tables 1 to 3**). Moreover, *Calendula officinalis* extract [81], green tea extract [83], *A. vera* gel [80], and *Achillea millefolium* and *Hypericum perforatum* extracts [79] showed no redness and edema in humans tested using the REEDA scale (► **Table 4**). Moreover, none of these above mentioned herbal products demonstrated toxicity or irritation. Unfortunately, the irritation and/or toxicity of the most herbs described in ► **Tables 1 to 4** have not yet been investigated. There is a strong belief among consumers that herbal agents obtained from “natural” plants are “naturally safe” and have no adverse effects. However, the literature has shown that some herbal remedies may cause allergic reactions, erythema, and edema, and several can be responsible for photosensitization [95].

Conclusion

Herbal products have been used in skin wound care for a prolonged period. Numerous preclinical *in vivo* studies on animals and few clinical trials have been conducted confirming the activity of herbal products in the stimulation of wound healing. Data from the articles cited in the present review referred to a total of 79 plants and showed that most of these plants exerted a beneficial effect on skin wound healing. Among these herbal products, *A. vera* gel [16, 38, 55, 80], *C. longa* fresh paste/ethanolic extract [22, 23, 55], and *Nigella sativa* seed oil and powder [59–61] were the most examined. *A. vera* gel showed significant wound healing activity in comparison to tetracycline ointment [38], soframycin ointment [55], and povidone-iodine [16] via its antibacterial mechanism of action [55]. Unfortunately, the results of clinical trials showed no significant differences between the control (women without intervention) and treatment (women after cesarean operation) groups after the topical application of *A. vera* gel [80]. Fresh *C. longa* paste [22], polyherbal formulation containing *C. longa* extract [23], and lotion containing its ethanolic extract [55] increased wound breaking strength, significantly reduced epithelialization, and completed the wound healing process in 15 days. *N. sativa* oil [59], powder [60], and cream with extract [61] increased epithelialization and granulation as well as demonstrated significant wound contraction rate *via* its antioxidant activity. It is worth mentioning that most analyzed studies showed the potential of the examined plants in wound healing treatment. Only 1 study on *Punica granatum* pulp showed no promising effects of this plant on wound healing [32]. Notably, none of the herbal products tested as a component of topical preparations for wound healing in the studies cited in this review posed a risk for animals or patients. Indeed, in contrast to synthetic drugs, for which chemical compositions, purity, efficacy, minimal active

concentration, and toxicity are well specified, several herbal formulations require further investigation. Nevertheless, it cannot be precluded that herbs may be considered as an important support during conventional therapy or even as synthetic medication replacements.

Conflict of Interest

The authors declare that they have no conflict of interest.

References

- [1] Gonzalez ACDO, Costa TF, Andrade ZDA, Medrado ARAP. Wound healing – a literature review. *An Bras Dermatol* 2016; 91: 614–620
- [2] Rittié L. Cellular mechanisms of skin repair in humans and other mammals. *J Cell Commun Signal* 2016; 10: 103–120
- [3] Barrientos S, Stojadinovic O, Golinko MS, Brem H, Tomic-Canic M. Growth factors and cytokines in wound healing. *Wound Rep Regen* 2008; 16: 585–601
- [4] Caley MP, Martins VL, O’Toole EA. Metalloproteinases and wound healing. *Adv Wound Care* 2015; 4: 225–234
- [5] Briquez PS, Hubbell JA, Martino MM. Extracellular matrix-inspired growth factor delivery systems for skin wound healing. *Adv Wound Care* 2015; 4: 479–489
- [6] Pereira RF, Bartolo PJ. Traditional therapies for skin wound healing. *Adv Wound Care* 2016; 5: 208–229
- [7] Calixto JB. Efficacy, safety, quality control, marketing and regulatory guidelines for herbal medicines (phyto therapeutic agents). *Braz J Med Biol Res* 2000; 33: 179–189
- [8] Maver T, Maver U, Stana Kleinschek K, Smrke DM, Kreft S. A review of herbal medicines in wound healing. *Int J Dermatol* 2015; 54: 740–751
- [9] Budovsky A, Yarmolinsky L, Ben-Shabat S. Effect of medicinal plants on wound healing. *Wound Rep Regen* 2015; 23: 171–183
- [10] Kumar V, Khan AA, Nagarajan K. Animal models for the evaluation of wound healing activity. *Int Bul Drug Res* 2013; 3: 93–107
- [11] Laut M, Ndaong NA, Utami T. Cutaneous wound healing activity of herbal ointment containing the leaf extract of *Acalypha indica* L. on mice (*Mus musculus*). *J Phys Conf Ser* 2019; 1146: 012025
- [12] Dorjsembe B, Lee HJ, Kim M, Dulamjav B, Jigjid T, Nho CW. *Achillea asiatica* extract and its active compounds induce cutaneous wound healing. *J Ethnopharmacol* 2017; 206: 306–314
- [13] Mondal S, Ghosh D, Ganapaty S, Reddy MS, Ramakrishna K. Evaluation of healing potential of *Achyranthes aspera* L. (Amaranthaceae) seeds in excision, incision, dead space and burn wound model – an *in vivo* study. *Pharmacogn J* 2016; 8: 300–306
- [14] Toppo FA, Pawar RS. Appraisal on the wound healing activity of different extracts obtained from *Aegle marmelos* and *Mucuna pruriens* by *in vivo* experimental models. *Niger J Clin Pract* 2016; 19: 753–760
- [15] Misra AK, Varma SK. Effect of an extract of *Agave americana* on wound healing model in experimental animals. *J Basic Clin Pharma* 2017; 8: 45–48
- [16] Khan A, Ashfaq K, ud Din J, Ali A, Tariq A, Ghani S, Ullah N, Sulaman Y, Farooq Ahmad M. Comparative efficacy of Acacia honey and *Aloe vera* gel on healing of induced lacerated wound in rabbits. *Am Sci Res J Eng Tech Sci* 2017; 33: 182–187
- [17] Shukla R, Rai G, Jain AP. Preclinical evaluation of rhizomes for wound healing activity with *Alpinia galanga* reducing oxidative status. *Asian J Pharm Pharmacol* 2015; 1: 65–69
- [18] Natarajan S, Pattiyappan S, Rajamani R. Evaluation of *C. albicans* induced wound healing activity of methanolic leaf extract of *Andrographis paniculata*. *J Sci Tech Invest* 2017; 1: 39–49

- [19] Akinpelu BA, Odukoya SOA, Akanni AA, Adelodun ST, Oyedapo OO. Evaluation of wound healing activity of *Achidium ohioense* (Schimp. ex Mull) oil on albino rats. *J Med Plant Herbal Ther Res* 2018; 6: 9–30
- [20] Toporcer T, Grendel T, Vidinský B, Gal P, Sabo J, Hudák R. Mechanical properties of skin wounds after *Atropa belladonna* application in rats. *J Met Mater Min* 2017; 16: 25–29
- [21] Moron MJ, Acero LH. Mayana (*Coleus blumei*) leaves ointment in wound healing of albino rats (*Rattus albus*). *Int J Food Eng* 2017; 3: 18–22
- [22] Al Mamun MA, Juyena NS, Khan MAHNA, Islam MA. Comparative effect of turmeric (*Curcuma longa*) and durba (*Cynodon dactylon*) on the healing of surgical wounds in cattle (*Bos indicus*). *Asian J Med Biol Res* 2018; 4: 164–171
- [23] Nasir MA, Mahammed NL, Roshan S, Ahmed MW. Wound healing activity of poly herbal formulation in albino rats using excision wound model, incision wound model, dead space wound model and burn wound model. *Int J Res Dev Pharm L Sci* 2016; 5: 2080–2087
- [24] Elzayat EM, Auda SH, Alanazi FK, Al-Agamy MH. Evaluation of wound healing activity of henna, pomegranate and myrrh herbal ointment blend. *Saudi Pharm J* 2018; 26: 733–738
- [25] Qureshi MS. Chemical composition and wound healing activity of methanolic leaf extract of *Hydrolea zeylanica* Vahl. by *in vivo* excision and incision models. *Int J Green Pharma* 2017; 11: 114–120
- [26] Balqis U, Darmawi CDI, Salim MN. Angiogenesis activity of *Jatropha curcas* L. latex in cream formulation on wound healing in mice. *Vet World* 2018; 11: 939–943
- [27] Ali MS, Rafiq M, Khasim SM. Formulation and evaluation of wound healing activity of *Macropitilium atropurpureum* in albino wistar rats. *World J Pharmac Res* 2018; 7: 582–599
- [28] Shukla R, Kashaw V. Evaluation of wound healing prospective of *Momordica charantia*, *Pongamia glabra* and *Piper nigrum* anemic albino rats using incision wound model. *Asian J Pharm Pharmacol* 2019; 5: 401–408
- [29] Unamba-Oparah C, Unamba-Oparah IC, Eze CA, Anaga AO. Effects of the methanol leaf extract of *Palisota hirsuta* in post-surgical wound management. *Sokoto J Vet Sci* 2018; 16: 91–97
- [30] Dev SK, Choudhury PK, Srivastava R, Sharma M. Antimicrobial, anti-inflammatory and wound healing activity of polyherbal formulation. *Bio-med Pharmacother* 2019; 111: 555–567
- [31] Sathyanarayanan S, Muniyandi K, George E, Sivaraj D, Sasidharan SP, Thangaraj P. Chemical profiling of *Pterolobium hexapetalum* leaves by HPLC analysis and its productive wound healing activities in rats. *Biomed Pharmacother* 2017; 95: 287–297
- [32] Asadi MS, Mirghazanfari SM, Dadpay M, Nassireslami E. Evaluation of wound healing activities of pomegranate (*Punica granatum*-Lythraceae) peel and pulp. *J Res Med Dental Sci* 2018; 6: 230–236
- [33] Tatke P, Nehete M, Gabhe S. Evaluation of antioxidant, antimicrobial and wound healing potential of *Salvadora persica* twig extracts. *World J Pharm Res* 2017; 6: 1186–1199
- [34] Somwanshi SB, Hiremath SN. *In vivo* evaluation of the wound healing activity of the *Sesamum Indicum* L. seed extract in novel ethosomal vesicular system. *J Drug Deliv Therap* 2018; 8: 411–420
- [35] Francis P, Masimba PJ, Mwakigonja AR. Evaluation of the wound healing activity of formulated ointments and water preparation from *Sida rhombifolia* leaf extract. *Tanzania J Health Res* 2018; 20: 1–8
- [36] Solanki R, Mathur V, Purohit SK, Mathur M. Evaluation of wound healing activity of ethanolic extract of *Ocimum basilicum* and *Aegle marmelos* leaves in male albino rats. *Int J Drug Res Tech* 2017; 2: 198–202
- [37] Rezaei M, Dadgar Z, Noori-Zadeh A, Mesbah-Namin SA, Pakzad I, Davodian E. Evaluation of the antibacterial activity of the *Althaea officinalis* L. leaf extract and its wound healing potency in the rat model of excision wound creation. *Avicenna J Phytomed* 2015; 5: 105–112
- [38] Jahandideh M, Hajimehdipoor H, Mortazavi SA, Dehpour A, Hassanzadeh G. Evaluation of the wound healing activity of a traditional compound herbal product using rat excision wound model. *Iran J Pharm Res* 2017; 16 (Suppl.): 153–163
- [39] Yang WT, Ke CY, Wu WT, Harn HJ, Tseng YH, Lee RP. Effects of *Angelica dahurica* and *Rheum officinale* extracts on excisional wound healing in rats. *Evid Based Compl Alt Med* 2017; 2017: 1583031
- [40] Miladiyah I, Prabowo BR. Ethanolic extract of *Anredera cordifolia* (Ten.) Steenis leaves improved wound healing in guinea pigs. *Universa Med* 2015; 31: 4–11
- [41] Mohsenikia M, Khakpour S, Azizian Z, Ashkani-Esfahani S, Razavipour ST, Toghiani P. Wound healing effect of *Arnebia euchroma* gel on excisional wounds in rats. *Adv Biomed Res* 2017; 6: 2
- [42] Manjula RR, Uppuluri S, Anand TJ, Adilakshmi V, Gandrapu P, Munagala A. Wound healing effect of methanolic flower extract of *Bauhinia tomentosa* Linn. with emu oil in rats. *J Pharmacogn Phytochem* 2017; 6: 247–253
- [43] Juneja K, Mishra R, Chauhan S, Gupta S, Roy P, Sircar D. Metabolite profiling and wound-healing activity of *Boerhavia diffusa* leaf extracts using *in vitro* and *in vivo* models. *J Traditional Compl Med* 2019; 10: 52–59
- [44] Azis HA, Taher M, Ahmed AS, Sulaiman WMAW, Susanti D, Chowdhury SR, Zakaria ZA. *In vitro* and *in vivo* wound healing studies of methanolic fraction of *Centella asiatica* extract. *S Afr J Bot* 2017; 108: 163–174
- [45] Vijayaraghavan K, Rajkumar J, Seyed MA. Efficacy of *Chromolaena odorata* leaf extracts for the healing of rat excision wounds. *Vet Med* 2017; 62: 565–578
- [46] Vennila V, Udayakumar R. Wound healing efficacy of herbal preparations of *Croton bonplandianum* Baill. on excision wound in experimental rats. *Curr Trad Med* 2017; 3: 38–50
- [47] Shekhar P, Joshi A, Malviya S, Kharia A. Wound healing activity of the hydro-alcoholic extract of *Datura stramonium* leaves in Wistar albino rats. *J Drug Deliv Therap* 2017; 7: 214–215
- [48] Muhamad Ibrahim A, Nagarajan A, Majeed M. Swertiamarin ointment: A traditional approach in cutaneous wound healing. *Asian J Pharm Pharmacol* 2019; 5: 298–309
- [49] Gorda CT, Flores AAU jr. Study on wound healing effect of Milk Bush (*Euphorbia tirucalli* Linn) in albino mice. *Adv Pharm J* 2018; 3: 157–161
- [50] Kang MH, Choi S, Kim BH. Skin wound healing effects and action mechanism of acai berry water extracts. *Toxicol Res* 2017; 33: 149–156
- [51] Goorani S, Zangeneh MM, Koohi MK, Seydi N, Zangeneh A, Souri N, Hosseini MS. Assessment of antioxidant and cutaneous wound healing effects of *Falcaria vulgaris* aqueous extract in Wistar male rats. *Comp Clin Pathol* 2019; 28: 435–445
- [52] Hanafi N, Talebpour Amiri F, Shahani S, Enayatfard R, Ghasemi M, Karimpour AA. Licorice cream promotes full-thickness wound healing in Guinea pigs. *Marmara Pharm J* 2018; 22: 411–421
- [53] Kotian S, Bhat K, Pai S, Nayak J, Souza A, Gourisheti K, Padma D. The role of natural medicines on wound healing: a biomechanical, histological, biochemical and molecular study. *Ethiop J Health Sci* 2018; 28: 759–770
- [54] Kim J, Lee CM. Wound healing potential of a polyvinyl alcohol-blended pectin hydrogel containing *Hippophae rhamnoides* L. extract in a rat model. *Int J Biol Macromol* 2017; 99: 586–593
- [55] Dons T, Soosairaj S. Evaluation of wound healing effect of herbal lotion in albino rats and its antibacterial activities. *Clin Phyto Sci* 2018; 4: 6
- [56] Taweepraditpol S, Chuangsuwanich A, Pradnivat K. Wound healing activity of *Lawsonia inermis* Linn in rat model. *J Med Assoc Thai* 2017; 100 (Suppl. 3): 140–144
- [57] Rafiee S, Nekouyian N, Hosseini S, Sarabandi F, Chavoshi-Nejad M, Mohsenikia M, Yadollah-Damavandi S, Seifae S, Jangholi E, Eghtedari D, Najafi H, Ashkani-Esfahani S. Effect of topical *Linum usitatissimum* on full thickness excisional skin wounds. *Trauma Mon* 2017; 22: e64930
- [58] Shukla R, Kashaw V. Assessment of wound healing potential of *Momordica charantia*, *Pongamia glabra* and their combination with *Piper nigrum*

- on anemic albino rats using excision wound model. *Asian J Pharm Pharmacol* 2019; 5: 188–198
- [59] Javadi SMR, Hashemi M, Mohammadi Y, MamMohammadi A, Sharifi A, Makarchian HR. Synergistic effect of honey and *Nigella sativa* on wound healing in rats. *Acta Cir Bras* 2018; 33: 518–523
- [60] Paheerathan V, Piratheepkumar R, Kumaran K. Evaluation of wound healing activity of *Nigella sativa* seed powder on Wistar albino rats. *Scholarly J Biol Sci* 2017; 6: 60–63
- [61] Han MC, Durmus AS, Sağlıyan A, Günay C, Özkaraca M, Kandemir FM, Comakli S, Firat Oztopalan D. Effects of *Nigella sativa* and *Hypericum perforatum* on wound healing. *Turk J Vet Anim Sci* 2017; 41: 99–105
- [62] Kurt B, Bilge N, Sözmen M, Aydın U, Önyay T, Özyayın İ. Effects of *Plantago lanceolata* L. extract on full-thickness excisional wound healing in a mouse model. *Biotech Histochem* 2018; 93: 249–257
- [63] Kolhe SS. Evaluation of polyherbal ointment for wound healing activity in Wistar rats. *J Drug Deliv Therap* 2018; 8: 26–31
- [64] Alshammari ND, Fatima N, Nayeem N. *Punica granatum* rind, a traditional herbal medicine: effect on wound healing. *Int J Pharm Res Allied Sci* 2017; 6: 53–58
- [65] Handoo N, Parrah JD, Athar H, Abrar Gayas M, Imtiyaz T, Bisma S. Wound healing and anti-bacterial efficacy of *Rheum emodi* and its different extracts on excisional wounds in rabbits. *J Entomol Zoology Stud* 2018; 6: 1204–1213
- [66] Lei Z, Cao Z, Yang Z, Ao M, Jin W, Yu L. Rosehip oil promotes excisional wound healing by accelerating the phenotypic transition of macrophages. *Planta Med* 2018; 85: 563–569
- [67] Sakeena Q, Ansari MM, Sakeena S, Muzamil S, Makhdoomi DM. *In vivo* assessment of lipid peroxidation and antioxidant profile in aqueous and ethanolic extract ointment of *Salix acmophylla* leaves in rabbits for wound healing improvement on excisional full thickness skin wounds. *Pharma Innovat J* 2018; 7: 492–500
- [68] Fatima N, Iqbal W, Yaqeen SS. Evaluation of wound healing effects between *Salvadora persica* ointment and Solcoseryl jelly in animal model. *Pak J Pharm Sci* 2015; 28: 1777–1780
- [69] Ghabae DNZ, Ebrahimzadeh MA, Akbari J, Amiri FT. Wound healing activity of *Sambucus ebulus*. *Int J Pharm Sci Res* 2017; 8: 132–135
- [70] Beyranvand F, Gharzi A, Abbaszadeh A, Khorramabadi RM, Gholami M, Gharravi AM. Encapsulation of *Satureja khuzistanica* extract in alginate hydrogel accelerate wound healing in adult male rats. *Inflam Reg* 2019; 39: 2
- [71] Estevão LRM, Simões RS, Cassini-Vieira P, Canesso MCC, Barcelos LDS, Rachid MA, Câmara CAGD, Evêncio-Neto J. *Schinus terebinthifolius* Raddi (Aroeira) leaves oil attenuates inflammatory responses in cutaneous wound healing in mice. *Acta Cir Bras* 2017; 32: 726–735
- [72] Ghashghaii A, Hashemnia M, Nikousefat Z, Zangeneh MM, Zangeneh A. Wound healing potential of methanolic extract of *Scrophularia striata* in rats. *Pharm Sci* 2017; 23: 256–263
- [73] Goorani S, Zangeneh MM, Zangeneh A, Poorshamohammad C, Abiari M, Moradi R, Najafi F, Tahvilian R. Study of wound healing potential of *Stevia rebaudiana* ethanol extract in male rats. *Res J Pharmacogn* 2018; 5: 23–30
- [74] Talekar YP, Apte KG, Paygude SV, Tondare PR, Parab PB. Studies on wound healing potential of polyherbal formulation using *in vitro* and *in vivo* assays. *J Ayurveda Integ Med* 2017; 8: 73–81
- [75] Babaei E, Asghari MH, Mehdikhani F, Moloudizargari M, Ghobadi E, Pouya SRH. The healing effects of herbal preparations from *Sambucus ebulus* and *Urtica dioica* in full-thickness wound models. *Asian Pac J Trop Biomed* 2017; 7: 421–427
- [76] Hamid A, Lian CP, Hudin NHS, Ghazali AR, Jufri NF. *Zingiber zerumbet* rhizomes extract exhibits faster open wound healing in rats. *Pharmacog Res* 2018; 10: 354–360
- [77] Verma RK, Pandey M, Indoria MD, Singh R, Suthar S. Phytochemical investigation and pharmacological evaluation of leaves of *Ziziphus mauritiana* for wound healing activity in albino rats. *Trop J Pharm Life Sci* 2018; 5: 8–18
- [78] Lodhi S, Jain A, Jain AP, Pawar RS, Singhai AK. Effects of flavonoids from *Martynia annua* and *Tephrosia purpurea* on cutaneous wound healing. *Avicenna J Phytomed* 2016; 6: 578–591
- [79] Hajhashemi M, Ghanbari Z, Movahedi M, Rafieian M, Keivani A, Haghollahi F. The effect of *Achillea millefolium* and *Hypericum perforatum* ointments on episiotomy wound healing in primiparous women. *J Matern Fetal Neonatal Med* 2018; 31: 63–69
- [80] Molazem Z, Mohseni F, Younesi M, Keshavarzi S. Aloe vera gel and cesarean wound healing; a randomized controlled clinical trial. *Glob J Health Sci* 2015; 7: 203–209
- [81] Jahdi F, Khabbaz AH, Kashian M, Taghizadeh M, Haghani H. The impact of calendula ointment on cesarean wound healing: a randomized controlled clinical trial. *J Family Med Prim Care* 2018; 7: 893–897
- [82] Hemmati AA. The topical effect of grape seed extract 2% cream on surgery wound healing. *Glob J Health Sci* 2015; 7: 52–58
- [83] Shahrahmani H, Kariman N, Jannesari S, Rafieian-Kopaei M, Mirzaei M, Ghalandari, Shahrahmani N, Mardani G. The effect of green tea ointment on episiotomy pain and wound healing in primiparous women: a randomized, double-blind, placebo-controlled clinical trial. *Phytother Res* 2018; 32: 522–530
- [84] Negut I, Grumezescu V, Grumezescu A. Treatment strategies for infected wounds. *Molecules* 2018; 23: 2392
- [85] Rodero MP, Khosrotehrani K. Skin wound healing modulation by macrophages. *Int J Clin Exp Pathol* 2010; 3: 643–653
- [86] Hesketh M, Sahin KB, West ZE, Murray RZ. Macrophage phenotypes regulate scar formation and chronic wound healing. *Int J Mol Sci* 2017; 18: 1545
- [87] Koh TJ, DiPietro LA. Inflammation and wound healing: the role of the macrophage. *Expert Rev Mol Med* 2011; 13: e23
- [88] Landén NX, Li D, Stähle M. Transition from inflammation to proliferation: a critical step during wound healing. *Cell Mol Life Sci* 2016; 73: 3861–3885
- [89] Knapinska A, Fields GB. Chemical biology for understanding matrix metalloproteinase function. *Chembiochem* 2012; 13: 2002–2020
- [90] Beanes SR, Dang C, Soo C, Ting K. Skin repair and scar formation: the central role of TGF- β . *Exp Rev Mol Med* 2003; 5: 1–22
- [91] Shah M, Foreman DM, Ferguson MW. Neutralization of TGF-beta 1 and TGF-beta 2 or exogenous addition of TGF-beta 3 to cutaneous rat wounds reduces scarring. *J Cell Sci* 1995; 108: 985–1002
- [92] Schafer M, Werner S. Oxidative stress in normal and impaired wound repair. *Pharmacol Res* 2008; 58: 165–171
- [93] Dunnill C, Patton T, Brennan J, Barrett J, Dryden M, Cooke J, Leaper D, Georgopoulos NT. Reactive oxygen species (ROS) and wound healing: the functional role of ROS and emerging ROS-modulating technologies for augmentation of the healing process. *Int Wound J* 2017; 14: 89–96
- [94] Kurahashi T, Fujii J. Roles of antioxidative enzymes in wound healing. *J Develop Biol* 2015; 3: 57–70
- [95] De Smet PA. Health risks of herbal remedies: an update. *Clin Pharmacol Ther* 2004; 76: 1–17