

Endoscopic ultrasound-guided hepaticogastrostomy or hepaticojejunostomy without dilation using a stent with a thinner delivery system




Authors

Kosuke Maehara¹, Susumu Hijioka¹, Yoshikuni Nagashio¹, Akihiro Ohba¹, Yuta Maruki¹, Hiromi Suzuki², Miyuki Sone³, Takuji Okusaka¹, Yutaka Saito⁴

Institutions

- 1 Department of Hepatobiliary and Pancreatic Oncology, National Cancer Center Hospital, Tokyo, Japan
- 2 Department of Radiological Technology, National Cancer Center Hospital, Tokyo, Japan
- 3 Department of Diagnostic Radiology, National Cancer Center Hospital, Tokyo, Japan
- 4 Endoscopy Division, National Cancer Center Hospital, Tokyo, Japan

submitted 25.1.2020

accepted after revision 9.4.2020

Bibliography

DOI <https://doi.org/10.1055/a-1169-3749> |

Endoscopy International Open 2020; 08: E1034–E1038

© Georg Thieme Verlag KG Stuttgart · New York

eISSN 2196-9736

Corresponding author

Dr. Susumu Hijioka, Department of Hepatobiliary and Pancreatic Oncology, National Cancer Center Hospital, 5-1-1 Tsukiji, Chuo-ku, Tokyo, Japan
 Fax: +81-3-3542-3815
shijioka@ncc.go.jp

ABSTRACT

Background and study aim Use of endoscopic ultrasound-guided biliary drainage (EUS-BD) has recently increased. In EUS-BD, after puncturing the bile duct, dilation is performed and the stent is deployed. Due to adverse events (AEs) such as unexpected displacement of the guidewire, simplified procedures are required. Currently, stents with small-diameter delivery systems are being rapidly developed, expanding the possibilities for of EUS-BD without dilation. In this retrospective study, we aimed to evaluate the success rates and AEs in patients who underwent EUS-guided hepaticogastrostomy (EUS-HGS) or EUS-guided hepaticojejunostomy (EUS-HJS) without dilation.

Patients and methods Six consecutive patients with malignant biliary obstruction and failed transpapillary BD underwent EUS-HGS or EUS-HJS without dilation, deploying a 6-mm fully-covered self-expandable metallic stent with a 6-Fr delivery system.

Results The technical and clinical success rates were 100%. There was one case each of stent migration and stent occlusion, and no other AEs were noted.

Conclusions EUS-HGS or EUS-HJS without dilation using a stent with a 6-Fr delivery system had high technical and clinical success rates; however, additional cases are required to validate the study findings.


Introduction

Endoscopic ultrasound-guided biliary drainage (EUS-BD) is widely used as an alternative drainage method for patients with biliary obstruction in whom transpapillary biliary drainage (BD) is difficult [1, 2]. There are many drainage methods for EUS-BD, including EUS-guided hepaticogastrostomy (EUS-HGS), EUS-guided hepaticojejunostomy (EUS-HJS), and EUS-guided choledoco-duodenostomy (EUS-CDS), depending on the form of occlusion and the shape of the intestine.

The EUS-BD procedure generally consists of five steps: 1. EUS-guided bile duct puncture; 2. Manipulation of the guidewire; 3. Placement of the guidewire; 4. Dilation of the gastroin-

testinal and bile duct walls; and 5. Stent placement. Of these procedures, the dilation process is associated with particular adverse events (AEs), including displacement of the guidewire and leakage of bile into the abdominal cavity [3, 4]. Therefore, there has been a need for simplification of the techniques and procedures used in EUS-BD from the perspective of safety and versatility. However, the fully-covered woven type self-expandable metallic stent (SEMS) used conventionally mainly uses a 7.5–8-Fr delivery system, which requires dilation.

Recently, to make the dilation process safer and easier, various dilation techniques using electrocautery, non-electrocautery dilator, or dilation balloon have been proposed [5–7]. Moreover, there have been a few reports of EUS-BD that elimin-



► **Fig. 1** A novel SEMS. **a** A 6-mm fully covered braided type. **b** The 6-Fr delivery system with the tapered tip.

ated the dilation process [3,4,8]. However, information on EUS-BD without dilation is inadequate. There are no reports of EUS-BD without dilation using a 6-Fr delivery system.

A fully-covered braided type SEMS with a small diameter delivery system (6-Fr; Braided 6, S&G Biotech, Seongnam, Korea) (► **Fig. 1**) is commercially available. In the current study, we evaluated outcomes of six patients who underwent attempted placement of a 6-mm fully-covered braided type SEMS with a 6-Fr delivery system using the EUS-HGS and EUS-HJS methods without dilation.

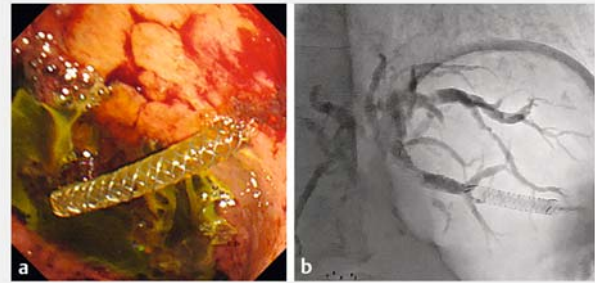
Patients and methods

The study examined six consecutive patients with biliary obstruction in whom transpapillary BD was difficult, who then underwent EUS-HGS or EUS-HJS without dilation between December 2018 and February 2019. Our inclusion criteria were (1) failure or contraindication of initial transpapillary BD because of inaccessible papilla such as that seen in duodenal obstruction and surgically altered anatomy; and (2) patient agreement to undergo EUS-BD. Our exclusion criteria were uncontrolled coagulopathy and massive ascites.

This study was carried out in accordance with the Helsinki Declaration and was approved by the hospital's Institutional Review Board (No.2018-149). The date of approval was July 18, 2018.

Procedural technique

GF-UCT260 (Olympus, Tokyo, Japan) was used for performing endoscopy. A 19-gauge needle for EUS-guided fine-needle aspiration (EUS-FNA) (EZ shot 3 plus; Olympus) was used to puncture the left intrahepatic bile duct during both the EUS-HGS and HJS procedures. After puncturing, the inside of the bile duct was verified using cholangiography, following which, a 0.025-inch guidewire (Visiglide2; Olympus) was placed in the bile duct. A Y-connector attached to the needle made the procedure of switching between bile duct contrasting and the guidewire operation easier and faster. Then, a 6-mm diameter, 8-cm-long, fully-covered SEMS with a 6-Fr delivery system was placed directly without performing dilation. Finally, appropriate placement of the stent was checked endoscopically and under fluoroscopic guidance by confirming that the contrast in the bile duct flowed into the gastrointestinal tract via the stent,



► **Fig. 2** Correct stent placement with outflow of bile shown on **a** endoscopic view and **b** fluoroscopy.

and the procedure was completed (► **Fig. 2**). The position of the stent was checked with abdominal computed tomography (CT) 1 day after the procedure.

A novel SEMS

The stent we used was a novel braided SEMS (Braided 6, S&G Biotech). We selected a 6-mm diameter, 8-cm long fully-covered type of the SEMS with a small-diameter (6-Fr) delivery system. The tip of the delivery system was tapered. The stent had a high radial force and low axial force. The surface of the stent was polished. The shortening rate after deployment was 35%.

Definition of outcomes

The primary endpoint was the technical success rate. The secondary endpoints were the clinical success rate, procedure time, and early/late AE rates (including recurrent biliary obstruction [RBO]). Technical success was defined as successful deployment of a self-expandable metal stent in the intended location with sufficient coverage of the puncture route confirmed by CT 1 day after the procedure. Clinical success was defined as a 50% decrease or normalization of the patient's bilirubin level within 14 days of stent placement (in accordance with the TOKYO criteria 2014.) [9]. Procedure time was measured from the first puncture to the bile duct until the deployment of the HGS/HJS stent.

Early AEs were defined as occurring within 30 days after the procedure, while late AE were defined as occurring after ≥ 31 days.

Stent occlusion was defined by biochemical features of cholestasis, such as liver enzyme levels higher than baseline values with findings of biliary dilation on imaging studies (ultrasonography or CT) or during endoscopy. Stent migration was defined as migration of the indwelling stent from its accurate position into the gastrointestinal tract or into the liver, as confirmed by CT scan, radiography, or endoscopy. Time to RBO (TRBO) was defined as the time between the initial stenting and RBO.

Other AE were defined as the following events of EUS-HGS/HJS without dilation:

- Fever (body temperature $\geq 38.5^{\circ}\text{C}$) lasting > 7 days without RBO
- Bleeding (requiring blood transfusion)

► **Table 1** Demographic features and clinical characteristics of and technical data from patients who underwent endoscopic ultrasound-guided hepaticogastrostomy or hepaticojejunostomy (EUS-HGS/HJS) without dilation.

N=6

Male, no. (%)	1 (17)
Median age, y (range)	74 (42–77)
Etiology, no. (%)	
▪ Pancreatic cancer	4 (67)
▪ Gastric cancer	2 (33)
Reasons of transpapillary drainage failure, no. (%)	
▪ Duodenal obstruction	4 (67)
▪ Surgically altered anatomy	2 (33)
▪ Median total bilirubin before procedure, mg/dl (range)	2.3 (0.3–16.6)
Drainage route, no. (%)	
▪ EUS-HGS	4 (67)
▪ EUS-HJS	2 (33)
Branch of punctured bile duct, no. (%)	
▪ B2	1 (17)
▪ B3	5 (83)
▪ Median diameter of bile duct, mm (range)	4.6 (2.3–6.2)

EUS-HGS, endoscopic ultrasound guided hepaticogastrostomy; EUS-HJS, endoscopic ultrasound-guided hepaticojejunostomy

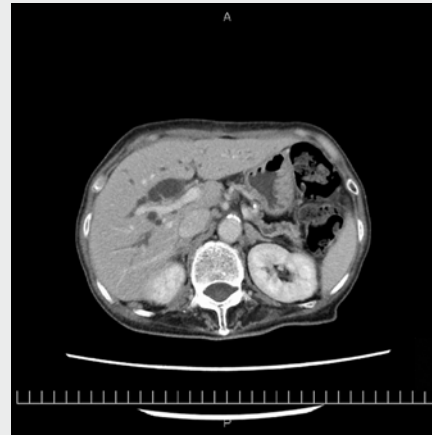
- Need for alternative drainage (excluding RBO)
- Inability to resume oral intake >7 days
- Need for laparotomy

Statistical analysis

Continuous variables, including age and procedure time, were expressed using medians and ranges, and categorical variables are expressed as proportions. Stent patency was estimated using the Kaplan-Meier method. All analyses were performed using SPSS 22.0 for windows (IBM Corp., Armonk, New York, United States).

Results

There were four patients with pancreatic cancer and two patients with gastric cancer. All patients had elevated total serum bilirubin levels or findings indicative of bile duct stenosis, such as biliary dilation. There were five women and one man, and the median age was 74 years (42–77 years). The cause of transpapillary BD difficulty was duodenal stenosis (n=4) and difficulty approaching the papilla of Vater because of intestinal reconstruction by previous surgery (n=2). Of the six patients, four underwent EUS-HGS and two underwent EUS-HJS. The punctured bile duct was B2 in one of the six patients and B3 in the remaining five patients. The median punctured bile duct diame-



► **Video 1** Endoscopic ultrasound-guided hepaticogastrostomy (EUS-HGS) without dilation.

ter was 4.6 mm (range: 2.3–6.2 mm) (► **Table 1**). Median procedure time was 18 min (12–35 min) (► **Video 1**).

Follow-up

Abdominal CT obtained 1 day after the procedure confirmed that the deployed stents were in the intended locations with sufficient coverage of the puncture route. There was no leakage of bile into the abdominal cavity in any patients. Bilirubin levels within 14 days of stent placement improved with >50% decrease or normalization in all patients. Median time until improvement was 3.5 days (1–7 days). Median time until discharge was 7 days (4–11 days). There were no AEs within 30 days. However, there was one case each of RBO (stent occlusion) at 45 days and RBO (stent migration) at 46 days. Median observation period was 76.5 days (8–212 days).

Without dilation, EUS-HGS/HJS was possible in all six patients, and the technical success and clinical success rates were both 100%.

Early AEs were not observed. The late AE rate was 33% (2/6), with RBO (stent occlusion) in one patient and TRBO at 45 days, and RBO (stent migration) in one patient and TRBO at 46 days (► **Table 2**). Median TRBO was not reached (95% CI: 83.4–214.2 days) (► **Fig. 3**).

Discussion

The study examined six consecutive patients who underwent EUS-HGS or EUS-HJS without dilation. We found that this method was possible for all patients, and both the technical success and clinical success rates were 100%.

AE rate was 33% (2/6). However, there were no early AEs (0/6), and both AEs were RBO as stent dysfunction in late AEs; no other AEs were seen. In these 6 patients, the characteristic AEs were not observed. Previously, dilation was considered essential in EUS-BD, but procedures that do not require dilation may be possible by using a metallic stent with a small diameter delivery system.

► **Table 2** Outcomes of patients who underwent endoscopic ultrasound-guided hepaticogastrostomy or hepaticojejunostomy (EUS-HGS/HJS) without dilation.

N = 6	
Technical success, no. (%)	6 (100)
Clinical success, no. (%)	6 (100)
Procedural time, min, median (range)	18 (12–35)
Median total bilirubin after procedure within 14 days, mg/dl (range)	0.9 (0.3–5.4)
Adverse events, no (%)	2 (33)
Early adverse events, no (%)	0 (0)
Late adverse events, no (%)	2 (33)
RBO (stent occlusion)	1 (17) TRBO: 45 days
RBO (stent migration)	1 (17) TRBO: 46 days
Time to improvement, days, median (range)	3.5 (1–7)
Time to discharge, days, median (range)	7 (4–11)
Observation time, days, median (range)	76.5 (8–212)

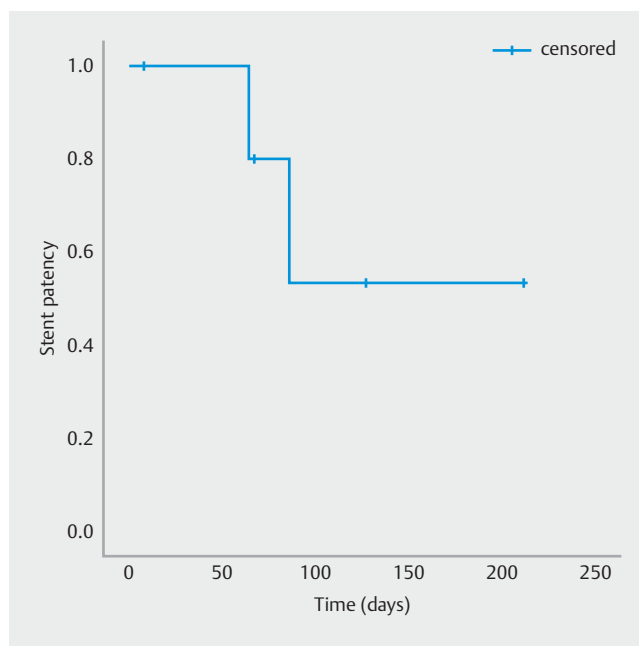
EUS-HGS, endoscopic ultrasound guided hepaticogastrostomy; EUS-HJS, endoscopic ultrasound-guided hepaticojejunostomy; RBO, recurrent biliary obstruction; TRBO, time to recurrent biliary obstruction

The dilation process is associated with danger of displacement of the guidewire and leakage of bile into the abdominal cavity after dilation. In this study without dilation, there were no leakage of bile on CT 1 day after the procedure in all patients. Therefore, there might be advantages to omitting the dilation process.

Median procedural duration was 18 minutes (12–35 min) in this study. Conversely, median procedural duration of EUS-BD with dilation was 25 minutes in six recent trials [2]. As in a prior trial of EUS-BD without dilation [3], EUS-HGS/HJS without dilation may have further advantages such as the ability to complete the procedure in a shorter time compared to EUS-BD with dilation. A problem with elimination of the dilation process was stent dilation failure with respect to fistula formation. All six patients had good postoperative drainage and no early AEs, including RBO were noted; however, one patient treated with EUS-HJS had stent occlusion on Day 45. Thus, it is unclear if it can be attributed to elimination of the dilation process. Further studies are warranted to validate these findings.

Stent migration was confirmed on postoperative Day 46 in a patient treated with EUS-HGS. From a physical perspective, the fistula was narrower with no dilation than that when dilation was performed. Therefore, stent migration was less likely. Migration of the stent was assumed to be caused by the small diameter of the stent (6 mm). However, further studies are needed to validate this finding.

Resistance during stent deployment was stronger than that with existing stents because of the narrow 6-Fr delivery system, and the release required time in one patient. Sales of this stent



► **Fig. 3** Stent patency was estimated using the Kaplan-Meier method.

were temporarily suspended in February 2019 to improve this aspect of the device, and an improved version is currently under development.

This study had a few limitations. It was retrospective with a limited number of patients ($n=6$). Hence, after sales of the improved version of the device begin, we plan to conduct a two-arm prospective study with the endpoint of the technical success rate comparing the EUS-HGS/HJS without dilation to that with dilation.

Conclusion

With further development, stents with smaller diameters as well as more stable functions and associated delivery systems are expected to enter the market. When this happens, EUS-HGS and EUS-HJS without dilation have the potential to become more widespread procedures. We are awaiting further evaluation of the efficacy and safety of these procedures in future studies.

Acknowledgements

This research was supported in part by The National Cancer Center Research and Development Fund (31-A-13) and by a grant from The Japanese Foundation for Research and Promotion of Endoscopy (JFE).

Competing interests

The authors declare that they have no conflict of interest.

References

- [1] Dumonceau JM, Tringali A, Papanikolaou IS et al. Endoscopic biliary stenting: indications, choice of stents, and results: European Society of Gastrointestinal Endoscopy (ESGE) Clinical Guideline – Updated October 2017. *Endoscopy* 2018; 50: 910–930
- [2] Leung Ki EL, Napoleon B. Endoscopic ultrasound-guided biliary drainage: a change in paradigm? *World J Gastrointest Endosc* 2019; 11: 345–353
- [3] Park DH, Lee TH, Paik WH et al. Feasibility and safety of a novel dedicated device for one-step EUS-guided biliary drainage: a randomized trial. *J Gastroenterol Hepatol* 2015; 30: 1461–1466
- [4] Lee TH, Choi JH, Lee SS et al. A pilot proof-of-concept study of a modified device for one-step endoscopic ultrasound-guided biliary drainage in a new experimental biliary dilatation animal model. *World J Gastroenterol* 2014; 20: 5859–5866
- [5] Amano M, Ogura T, Onda S et al. Prospective clinical study of endoscopic ultrasound-guided biliary drainage using novel balloon catheter (with video). *J Gastroenterol Hepatol* 2017; 32: 716–720
- [6] Ogura T, Nakai Y, Itoi T. Novel fine gauge electrocautery dilator for endoscopic ultrasound-guided hepaticogastrostomy (with video). *J Hepatobiliary Pancreat Sci* 2019; 26: E3–E4
- [7] Honjo M, Itoi T, Tsuchiya T et al. Safety and efficacy of ultra-tapered mechanical dilator for EUS-guided hepaticogastrostomy and pancreatic duct drainage compared with electrocautery dilator (with video). *Endosc Ultrasound* 2018; 7: 376–382
- [8] Paik WH, Lee TH, Park DH et al. EUS-guided biliary drainage versus ERCP for the primary palliation of malignant biliary obstruction: a multicenter randomized clinical trial. *Am J Gastroenterol* 2018; 113: 987–997
- [9] Isayama H, Hamada T, Yasuda I et al. TOKYO criteria 2014 for transpapillary biliary stenting. *Dig Endosc* 2015; 27: 259–264