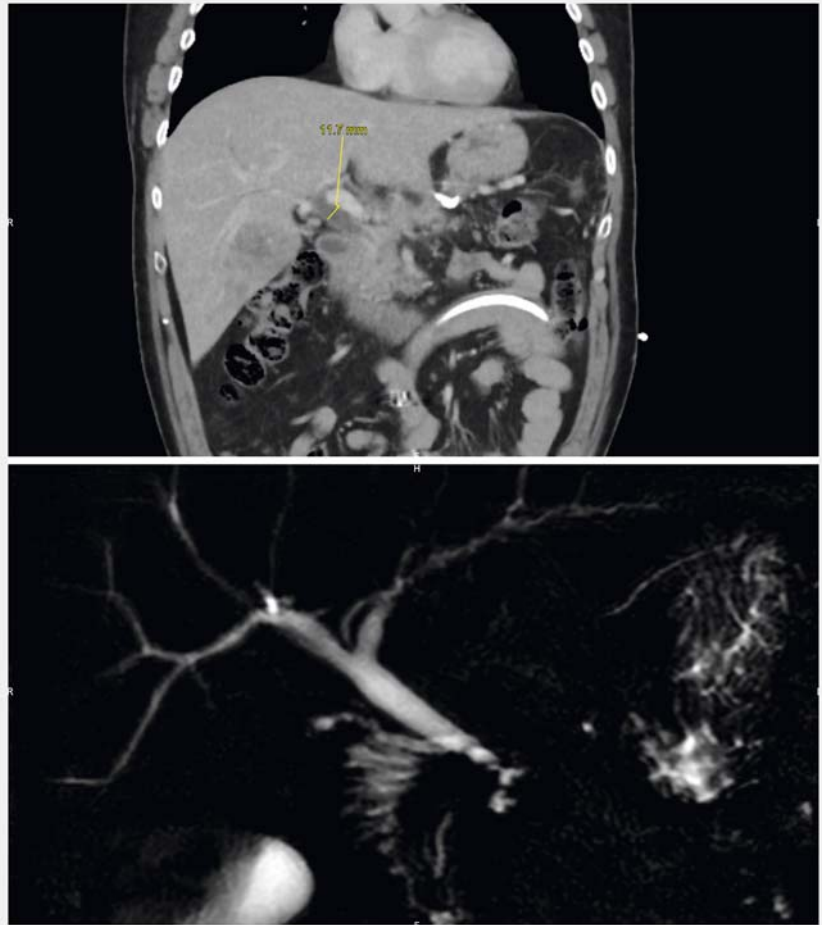


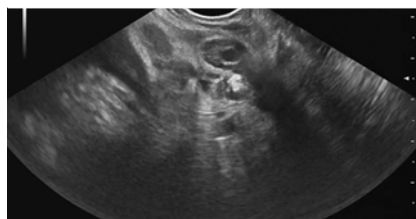
An unexpected diagnosis of undetermined biliary stenosis via endoscopic ultrasound

Endoscopic diagnosis of indeterminate biliary stenosis is difficult, often requiring repeat examinations [1]. Among rare causes of such stenoses, portal biliopathy is exceptional; 65–85% of patients with extrahepatic portal obstructions exhibit no symptoms [2, 3]. Physiopathologically, the condition is caused by dilation of both plexuses that return the blood of the main bile duct. This develops secondarily to portal hypertension and compresses the common bile duct. Here, we report the case of a 52-year-old patient with a recent history of severe acute pancreatitis complicated by portal thrombosis and infected necrosis drained via a lumen-apposing metal stent. During follow-up several months later, he exhibited cholestasis in hepatic testing, and computed tomography and magnetic resonance imaging revealed dilation of the main biliary tract but no visible obstacle, as well as a possible distal stricture (► Fig. 1). Endoscopic ultrasound revealed a dilated main bile duct with a thickened and edematous wall, which was most noticeable at the level of the papilla, suggestive of an inflammatory or tumor cause (► Fig. 2). Doppler ultrasound showed that the hypoechoic thickening was attributable to main bile duct hypervascularization (► Fig. 3). Transduodenal endoscopic ultrasound revealed several dilated vessels compressing the lower bile duct (► Video 1). Endoscopic management of such stenoses is associated with a very high risk of hemorrhage [4], especially in patients who have undergone sphincterotomy. We placed a portosystemic shunt in this patient.

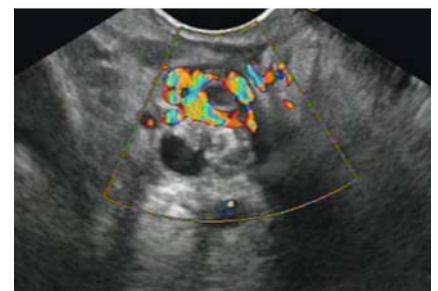
Endoscopy_UCTN_Code_CCL_1AZ_2AN



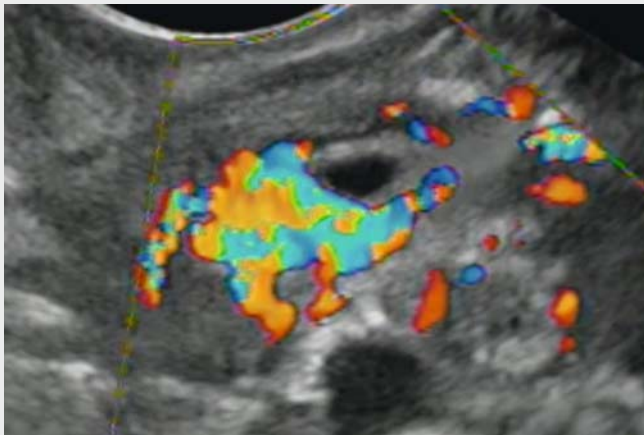
► Fig. 1 Computed tomographic scan and magnetic resonance imaging of biliary tract.



► Fig. 2 Bile duct thickening.



► Fig. 3 Bile duct hypervascularization.



Video 1 An unexpected diagnosis when endoscopic ultrasound was used to explore a case of undetermined biliary stenosis.

Bibliography

Endoscopy 2021; 53: E31–E32
DOI 10.1055/a-1173-8067
ISSN 0013-726X
 published online 29.5.2020
 © 2020. Thieme. All rights reserved.
 Georg Thieme Verlag KG, Rüdigerstraße 14,
 70469 Stuttgart, Germany

ENDOSCOPY E-VIDEOS

<https://eref.thieme.de/e-videos>



Endoscopy E-Videos is a free access online section, reporting on interesting cases and new

techniques in gastroenterological endoscopy. All papers include a high quality video and all contributions are freely accessible online.

This section has its own submission website at

<https://mc.manuscriptcentral.com/e-videos>

Competing interests

Mathieu Pioche: scientific consultant for Olympus, Boston and 3D matrix, ESD training with Cook and Olympus. Véronique Loustaud-Ratti: advisory board and speaking for Gilead and Abbvie. Sophie Geyl: speaking for Abbvie and Ipsen, invitation (conference) for Amgen. Jérémie Jacques and Romain Legros: scientific consultant for Boston and Olympus.

Corresponding author

Jérémie Albouys, MD

Service d'Hépatogastroentérologie, CHU Dupuytren 87042, Limoges, France
 Fax: +33-5-55058733
jeremie.albouys@gmail.com

References

- [1] Novikov A, Kowalski TE, Loren DE. Practical management of indeterminate biliary strictures. *Gastrointest Endosc Clin N Am* 2019; 29: 205–214
- [2] Dhiman RK, Behera A, Chawla YK et al. Portal hypertensive biliopathy. *Gut* 2007; 56: 1001–1008
- [3] Chaudhary A, Dhar P, Sarin SK et al. Bile duct obstruction due to portal biliopathy in extrahepatic portal hypertension: surgical management. *Br J Surg* 1998; 85: 326–329
- [4] Dumortier J, Vaillant E, Boillot O et al. Diagnosis and treatment of biliary obstruction caused by portal cavernoma. *Endoscopy* 2003; 35: 446–450

The authors

Jérémie Albouys¹, Sophie Geyl¹, Rebecca Rodrigues¹, Véronique Loustaud-Ratti¹, Romain Legros¹, Mathieu Pioche², Jérémie Jacques¹

- 1 Gastroentérologie et endoscopie digestive, CHU Dupuytren, Limoges, France
- 2 Unité d'endoscopie digestive, service de Gastroentérologie – Pavillon H, Hôpital Edouard Herriot, Hospices Civils de Lyon, Lyon, France