

Position Paper of the German Society for Interventional Radiology (DeGIR) on Prostatic Artery Embolization

Positionspapier der Deutschen Gesellschaft für Interventionsradiologie (DeGIR) zur Prostataarterienembolisation

Authors

Attila Kovács¹, Arno Bücken², Marc-Oliver Grimm³, Christian R. Habermann⁴, Marcus Katoh⁵, Alexander Massmann², Andreas H. Mahnken⁶, Bernhard C. Meyer⁷, Michael Moche⁸, Peter Reimer⁹, Ulf Teichgräber¹⁰, Frank K. Wacker⁷,
In collaboration with the DeGIR Science Steering Group and the DeGIR Board

Affiliations

- 1 MediClin Robert Janker Clinic, Clinic of Diagnostic and Interventional Radiology and Neuroradiology, Bonn, Germany
- 2 Saarland University Medical Center, Clinic of Diagnostic and Interventional Radiology, Homburg/Saar, Germany
- 3 Jena University Hospital, Department of Urology, Jena, Germany
- 4 Kath. Marienhospital Hamburg, Department of Diagnostic and Interventional Radiology, Hamburg, Germany
- 5 Helios-Hospital Krefeld, Diagnostic and Interventional Radiology, Krefeld, Germany
- 6 Marburg University Hospital, Clinic of Diagnostic and Interventional Radiology, Marburg, Germany
- 7 Hannover Medical School, Department of Diagnostic and Interventional Radiology, Hannover, Germany
- 8 Helios-Park-Klinikum Leipzig, Department of Interventional Radiology, Leipzig, Germany
- 9 Städtisches Klinikum Karlsruhe, Academic teaching hospital of the University of Freiburg, Institute of Diagnostic and Interventional Radiology, Karlsruhe, Germany
- 10 Jena University Hospital, Department of Radiology, Jena, Germany

Key words

prostate, interventional procedures, benign prostate syndrome, lower urinary tract symptoms, prostate artery embolization

received 09.03.2020

accepted 11.05.2020

Bibliography

DOI <https://doi.org/10.1055/a-1183-5438>

Published online: 2.7.2020

Fortschr Röntgenstr 2020; 192: 835–846

© Georg Thieme Verlag KG, Stuttgart · New York

ISSN 1438-9029

Correspondence

PD Dr. Attila Kovács

Klinik für Diagnostische und Interventionelle Radiologie und Neuroradiologie, MediClin Robert-Janker-Hospital, Villenstr. 8, 53129 Bonn, Germany

Tel.: ++49/2 28/53 06 45 01

Fax: ++49/2 28/5 30 65 02

attila.kovacs@mediclin.de

ABSTRACT

Background In recent years prostate artery embolization (PAE) evolved into a clinically established minimally invasive endovascular treatment option for lower urinary tract symptoms caused by benign prostate syndrome (BPS).

Methods In this interdisciplinary position paper, initiated by the steering group for research of the German Society for Interventional Radiology (IR), the method of PAE is presented and discussed in the context of current evidence.

Results PAE is a safe IR procedure for the treatment of BPS. In terms of symptom relief, measured with the IPSS (International Prostate Symptom Score), the PAE has comparable effect, similar to the historic gold standard, transurethral resection (TUR) of the prostate. With regard to reducing subvesical obstruction PAE is inferior to TUR, but does not limit subsequent surgery. Based on current evidence, PAE is recommended by the British National Institute for Health and Care Excellence as an alternative therapy. The feasibility under local anaesthesia and the preservation of sexual function are important arguments for patients in favour of interventional therapy. Patient selection and therapy concepts require close interdisciplinary collaboration between urologists and radiologists.

Conclusion Effectiveness and safety of PAE for the treatment of BPS are proven. Further randomized trials should focus on long term outcome and help to identify most suitable indications for PAE.

Key Points:

- PAE, an endovascular procedure, is a patient-friendly, minimally invasive, alternative therapy option of the BPS
- PAE can reduce the symptoms of the lower urinary tract (LUTS), comparable to transurethral resection (TUR). The

deobstructive and volume-reducing potential of the PAE is inferior to that of the TUR

- The main advantages of PAE are use of local anesthesia (no general anesthesia required), short patient recovery and maintenance of sexual function, including antegrade ejaculation.
- Based on current evidence PAE should be considered after conservative drug therapy and before TUR.
- The role of PAE in the context of other minimally invasive procedures (MIST) requires further evaluation with an open minded approach towards PAE.
- PAE is carried out by interventional radiologists, usually on a referral basis from urologists, and requires close interdisciplinary cooperation.

Citation Format

- Kovacs A, Bücken A, Grimm M et al. Position Paper of the German Society for Interventional Radiology (DeGIR) on Prostatic Artery Embolization. *Fortschr Röntgenstr* 2020; 192: 835–846

ZUSAMMENFASSUNG

Hintergrund Mit der Prostataarterienembolisation (PAE) steht seit einigen Jahren ein klinisch etabliertes minimalinvasives endovaskuläres Verfahren zur Behandlung des benignen Prostatasyndroms (BPS) zur Verfügung.

Methoden In diesem von der Lenkungsgruppe Wissenschaft und Forschung der Deutschen Gesellschaft für Interventionelle Radiologie initiierten interdisziplinären Positionspapier wird die Methode der PAE dargestellt und im Kontext der aktuellen Datenlage diskutiert.

Ergebnisse Die PAE ist ein sicheres interventionell-radiologisches Verfahren zur Behandlung des BPS. In Bezug auf die Beschwerdesymptomatik, gemessen mit dem IPSS (International Prostate Symptom Score), hat die PAE im Vergleich zu dem historischen Goldstandard der transurethralen Resektion (TUR) der Prostata einen vergleichbaren Effekt. Im Hinblick auf die subvesikale Desobstruktion ist die PAE der TUR unterlegen, sie behindert allerdings eine spätere chirurgische Therapie nicht. Aufgrund der bereits vorhandenen Evidenz wird die PAE vom britischen National Institute for Health and Care Excellence als Therapiealternative empfohlen. Die Durchführbarkeit in Lokalanästhesie und der Erhalt der Sexualfunktion sind für die Patienten wichtige Argumente für die interventionelle Therapie. Patientenauswahl und Therapiekonzept erfordern eine enge interdisziplinäre Zusammenarbeit zwischen Urologen und Radiologen.

Schlussfolgerung Effektivität und Sicherheit der PAE zur Behandlung des BPS sind nachgewiesen. In weiteren randomisierten Studien sollten Langzeitergebnisse generiert und die am besten geeigneten Indikationen für die PAE bei BPS definiert werden.

Introduction

Benign prostate syndrome (BPS) is a benign enlargement of the prostate, associated with impairment of micturition.

The symptoms (LUTS, Lower Urinary Tract Symptoms), can be primarily obstructive, irritative or can consist of a combination of these. Typical obstructive symptoms include poor urine stream, hesitancy, difficult (straining) and prolonged micturition as well as a feeling of incomplete bladder emptying. Irritative symptoms include strong “urgent” need to urinate as well as pollakiuria. Nocturia is a rather unspecific symptom and can have numerous causes or cofactors besides benign enlargement of the prostate, e. g. insomnia, heart failure, etc.

Depending on the manifestation of LUTS, quality of life can be significantly impaired. Urge symptoms can prevent any activity during which a toilet cannot be quickly reached due to the risk of urge incontinence. Increasing residual urine favors the formation of bladder stones and recurrent infections up to urine retention and consecutive post-renal kidney failure. The reduction in the quality and quantity of sleep caused by nocturia can be particularly serious. Accordingly, nocturia with a frequency of ≥ 2 times/night is a common reason for visits to a physician [1].

Due to its prevalence of about 50 % in the age cohort of 50-year-olds (about 3 million men) and about 90 % at an age of more than 85 years (about 500 000 men), BPS can be classified as a widespread disease [1, 2, 4]. In industrialized nations, a con-

siderable increase in the prevalence of BPS is to be expected in view of demographic development [14].

Initially, treatment consists of a conservative approach with watchful waiting. For mild to moderately severe symptoms, the focus is on drug therapy. In cases of intolerance or insufficient drug therapeutic success, different surgical procedures are used depending on comorbidities and the volume of the prostate. An epidemiological cohort study by Vuichoud et al. describes 54.8 % of patients receiving drug therapy, 35 % being monitored and about 1.1 % undergoing surgery [1]. In Germany approximately 80 000 patients are treated surgically per year [2].

The most common surgical procedure which has been established for decades is endoscopic transurethral resection of the prostate (TURP). TURP is primarily able to treat obstructive symptoms quickly and effectively, and the success rates are very good in experienced centers. The main complications are perioperative bleeding requiring transfusion, bladder neck stenosis and generally transient urinary incontinence. However, retrograde ejaculation (RE) is an almost regular consequence of the operation; that is, the ejaculate enters the bladder through the prostatic urethra, which during resection is funnel-shaped and extends from the seminal colliculus to the bladder neck. Sexually active patients generally find RE to be very disruptive. While TUR is limited to prostate volumes of up to 80 ml, transurethral therapy options (including laser enucleation, aquablation) are available for larger glands in addition to suprapubic prostatic adenomectomy [3–7].

As an endovascular procedure, radiological minimally invasive prostatic artery embolization (PAE) has been available for several years, which is performed under local anesthesia without general anesthesia. This position paper will present and analyze the PAE method according to current data.

Prostatic Artery Embolization

PAE was used to treat bleeding of prostate origin after an initial description in the journal "Der Urologe" (The Urologist) in 1977 [8]. First reports of successful PAE for LUTS and BPH followed in 2000, which can be considered the first description of the new therapeutic concept [9]. Thereafter, PAE was used worldwide as an endovascular minimally invasive therapy for BPS [10]. Advantages of the procedure are high patient satisfaction and preserved sexual function. It can also support other therapies by reducing volume. Combinations of PAE and transurethral procedures such as holmium laser enucleation (HoLEP) have been successfully tested in significantly enlarged prostates > 200 ml, and PAE and TURP in prostates > 80 ml in multi-morbid patients [11, 12].

PAE places high demands on the skills of the interventional radiologist. Both the arterial vascular anatomy of the pelvis and technique of embolization must be well known to the interventional radiologist from practical experience. In accordance with the 2018 model training regulation of the German Medical Association, the treatment should be carried out exclusively by radiologists. From the perspective of the German Society for Interventional Radiology (DeGIR), a special qualification in embolization therapy (DeGIR modules B and D) is recommended for performing PAE (<https://www.degir.de/de-DE/5080/stufe-2/>) to avoid potentially serious complications of incorrect embolization and to achieve optimal therapy results. Modern digital subtraction angiography (DSA) systems are a basic requirement for adequate visualization of the very fine vascular anatomy with diameters < 1 mm and minimization of radiation exposure. C-arm CT angiography, also known as cone beam CT has proven itself for three-dimensional imaging of the pelvic arteries and organs and is highly recommended. Beyond the technical possibilities, the interventionalist should also have practical experience with these complex imaging techniques.

Preparation

Basically, the success of the therapy essentially depends on adequate patient selection. Therefore, critical analysis and correlation of diagnostics with clinical symptoms and familiarity with urological therapy options are a prerequisite for the correct detection of BPS as well as for the corresponding clarification. Both should be performed in an interdisciplinary, urological-radiological context, since LUTS can also be associated with a variety of other bladder emptying or retention disorders.

Generally, there is the possibility of PAE if the obstruction of the bladder outlet is caused by an enlarged prostate. A detailed pre-interventional medical history and diagnosis should rule out other causes for which the PAE is not indicated.

Pre-interventional diagnostics

Various established questionnaires for subjective self-assessment of complaint symptoms and examination procedures for standardized collection of objective parameters are available for pre-interventional diagnostics:

- IPSS (International Prostate Symptoms Score) Questionnaire on the severity of symptoms (Symptom Index, 7 questions) and Quality of Life (QoL)
- IIEF (International Index of Erectile Function) questionnaire on sexual and erectile function
- Rectal palpation of the prostate and transrectal ultrasound (TRUS) to determine volume
- Determination of PSA value (prostate-specific antigen)
- Uroflowmetry with determination of the maximum urine flow rate (Q_{max}) and the micturition volume (assessable from 150 ml micturition volume)
- Sonographic determination of residual urine

The results of these tests correlate only partially with prostate enlargement, bladder outlet obstruction (BOO) and LUTS [13]. For example, there is no fixed correlation between prostate volume, degree of compression of the prostatic urethra and BOO. Sensitivity and specificity for BOO with a prostate volume > 40 cm³ are only 49% and 32% respectively [14]; likewise, there is only a slight correlation between quantity of residual urine and BOO. The IPSS is used to assess clinical symptoms. Irritative retention symptoms such as frequent and strong urge to urinate as well as frequent nocturnal urination (nocturia) are often perceived by patients as much more stressful than urination symptoms such as weakening of the urinary stream (reduced maximum urine flow rate, Q_{max}) [15–18].

The PSA level should be determined prior to a PAE. In the case of pathological elevation, further clarification should be made to rule out the possibility of prostate cancer.

Sectional imaging techniques can provide important information for the evaluation of BPS. Multi-parametric MRI plays a central role in excluding therapy-relevant prostate carcinoma [19]. In addition, MRI provides accurate information on size, lateral dominance, intravesical prostate protrusion (IPP), prostatic urethral angle (PUA) or tissue dominance (adenoma or stromal dominant prostate enlargement) (► **Fig. 1a**). Prior to PAE, if atherosclerotic vascular changes are expected, the vascular anatomy can be evaluated by MR or CT angiography, since atherosclerosis can make PAE difficult or technically impossible due to a lack of endovascular access.

PAE as an elective endovascular therapy with the use of iodine-based contrast requires prior clarification of kidney, thyroid and coagulation functions as well as the consumption of metformin in accordance with ESUR guidelines (<http://www.esur.org/esur-guidelines/>).

Patient selection for PAE

In principle, PAE is suitable for patients with a prostate volume (Pvol) > 30 ml who continue to suffer from moderate to severe BPS after at least six months of unsuccessful drug therapy or intolerance of the latter (IPSS ≥ 8, quality of life QoL ≥ 3 and Q_{max} ≤ 15 ml/s) [20]. There is not an upper limit of prostate

volume for PAE. There are a number of constellations in which PAE can be considered:

- multi-morbid patients with permanent catheterization
- patients with a high risk of anesthesia or surgery, e. g. due to cardiopulmonary comorbidities or a blood clotting disorder or anticoagulation medication
- rejection of surgical subvesical disobstruction, e. g. because of the high risk of retrograde ejaculation.

Basically, non-obstructive LUTS (e. g. neurogenic hyper- or hypoactive bladder, bladder neck dysfunction, detrusor-sphincter dyssynergy) and urethral strictures can be ruled out by a specialist urological examination.

The absolute contraindication for PAE is currently the presence of a curative, non-bleeding prostate carcinoma, as there is insufficient data in this context [21]. Acute infections such as prostatitis or urethritis can be aggravated after PAE and are further absolute contraindications for PAE.

Primary surgical therapy is carried out in the combination of BPS and simultaneous presence of bladder stones. PAE should not be recommended for patients with large bladder diverticula or neurogenic voiding disorders.

The following particularly benefit from PAE:

- patients with moderate IPSS (18–25) [22]
- patients <65 years of age [22]
- patients with acute urine retention [22, 23]
- patients with prostates greater than 80 ml [24, 25]
- patients with adenoma-dominant BPS [26].

In everyday clinical practice, 3 advantages in comparison to the standard procedures are often particularly decisive for the choice of a PAE:

- shorter downtimes
- avoidance of retrograde ejaculation
- minimally invasive intervention under local anesthesia

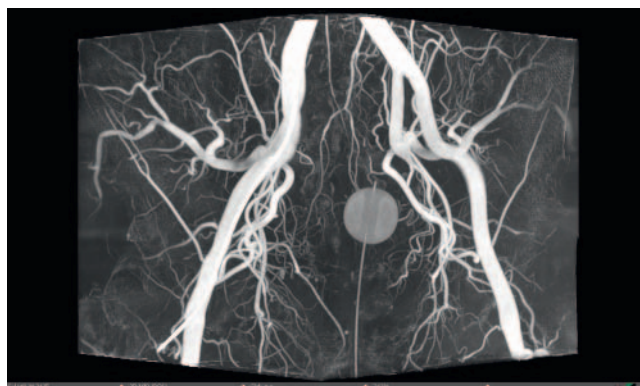
PAE Performance

Procedural imaging

Various strategies are available to evaluate vascular anatomy:

- pre-interventional CT
- overview cone beam CT made with a catheter position above the aortic bifurcation
- selective cone beam CT made with a catheter position in the relevant internal iliac artery
- production of DSA series.

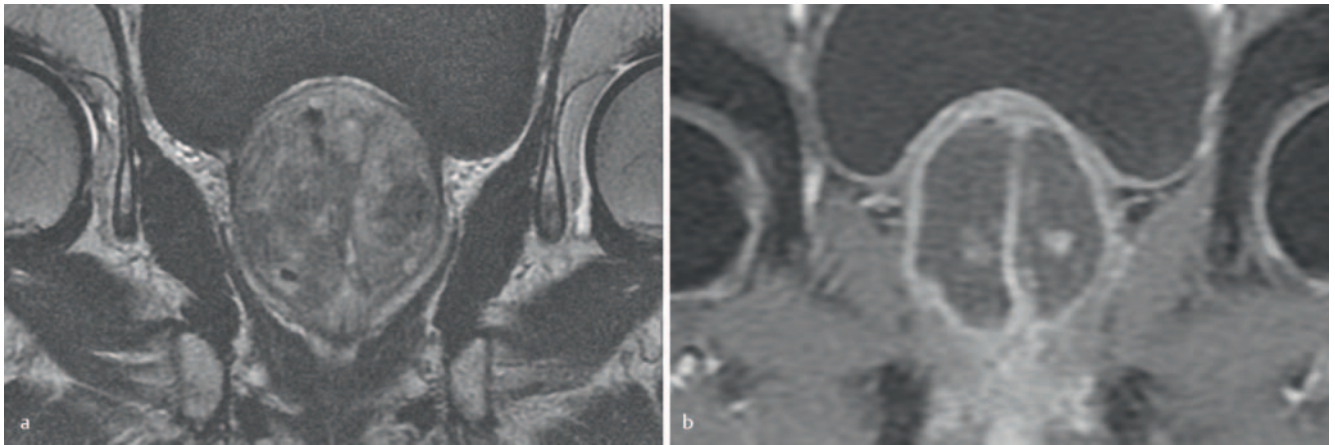
DSA represents peri-procedural standard imaging with respect to PAE. In addition, 3 D imaging can be performed using cone beam CT. While three-dimensional vascular imaging is used in particular for vascular identification and endovascular navigation, combined imaging of vascular anatomy and soft tissues allows imaging of the area to be embolized.



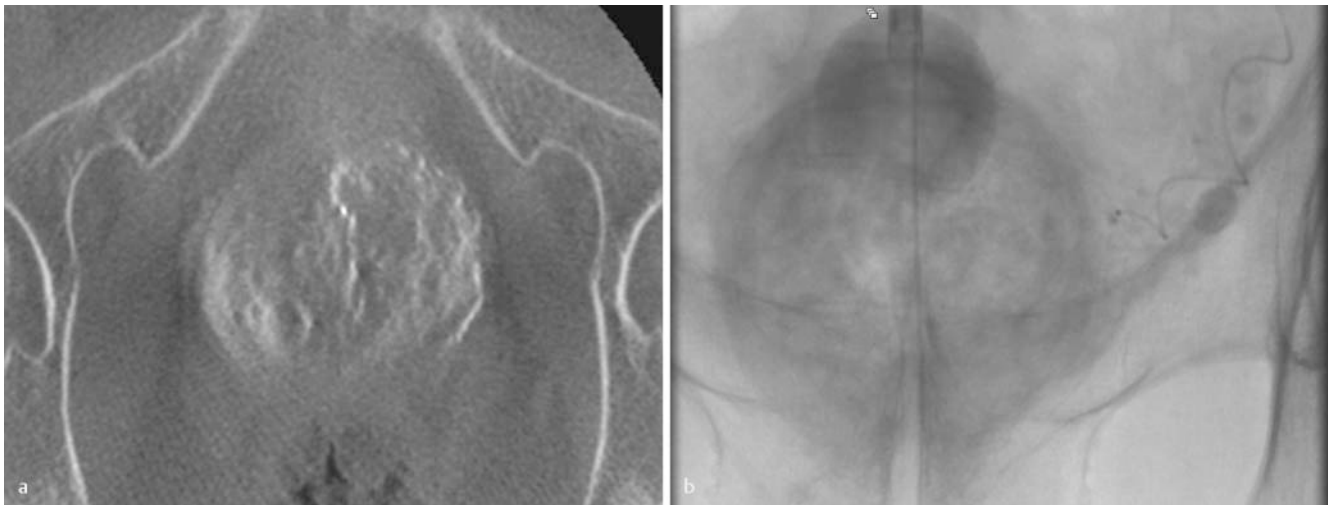
► **Fig. 1** The three-dimensional maximum intensity projection overview angiography provides excellent visualization of the complex anatomy of the prostate arteries and facilitates the identification of variants. (Reference B. Mayer, Hannover).

Image-guided positioning of the microcatheter is performed either purely fluoroscopically using conventional, possibly angulated DSA series or with the aid of navigation techniques based on 3 D imaging. Appropriate software applications can (semi) automatically detect the course of the prostate artery and superimpose it as a graphical representation or as a vascular rendering of fluoroscopy (► **Fig. 2**), thus reducing the patient's radiation exposure. Similar to computed tomography, cone beam CT also allows imaging of soft tissues and their perfusion. Since, in the context of PAE, misembolizations of neighboring vascular territories and organs are particularly relevant complications, this image information significantly increases patient safety. The exact organ assignment from the anticipated embolization position is limited in projection angiography. Computer tomography using cone beam CT after superselective contrast agent administration in the parenchyma phase allows the embolization to be simulated and can thus rule out subsequent misembolization more reliably than other techniques (► **Fig. 3a, b**). This approach requires slow administration of contrast with a low flow rate (e. g. 3 ml contrast medium, 0.1 ml/s flow rate) to prevent contrast medium reflux and thus provide proper perfusion images. On the other hand, a too low contrast medium flow and an incorrectly selected injection delay quickly result in non-meaningful images with unnecessary radiation exposure. This complexity of 3 D technology necessarily requires interventionalists to have sufficient practical experience to optimize patient safety with respect to radiation protection and complication rate.

While prior to embolization, cone beam CT detects primary collaterals outside the target region, control during embolization is used to promptly identify secondary collaterals that open up due to changed hemodynamics during embolization [27]. Since only a limited area of the pelvis usually needs to be displayed for parenchyma imaging, collimated cone beam CT is preferable to non-collimated cone beam CT with regard to both radiation exposure and image quality [28]. If a combined angiography-CT hybrid system is available, parenchyma imaging can also be performed using CT.



► **Fig. 2 a** Preinterventional magnetic resonance imaging (MRI) provides important information about the size, configuration and morphology of the prostate to be treated. MRI is also suitable for ruling out contraindications for a PAE, such as prostate carcinomas or pathologies of the urinary bladder. **b** In post-interventional MRI, the devascularisation of the prostate can be assessed well and intervention-associated complications can be excluded (Reference A. Kovács).



► **Fig. 3 a** Cone beam computed tomography (CBCT) with contrast medium application via the catheter in the planned embolization position allows for pretherapeutic simulation and confirms an optimal position of the microcatheter for selective embolization. The exclusion of contrast outside the target region increases the safety of the therapy. **b** Fluoroscopic control during embolization is used to guide therapy and is critical in determining the end point of the intervention (Reference A. Kovács).

Peri-interventional management

A single-dose antibiotic prophylaxis (e. g. cefazolin 2 g IV) is recommended peri-interventionally [29]. Furthermore, a balloon catheter is useful because it can be used as a landmark during the intervention and remains in place afterward due to the risk of urinary retention. It can make longer procedures more tolerable for the patient by allowing unimpeded urine flow. A non-contrast-filled urinary bladder can reduce radiation exposure and improve image quality. Intraprocedural anticoagulation with up to 5000 I.U. heparin should be considered. Since peri-procedural PAE is usually painless, it can be performed under local anesthesia without analgosedation.

Exploration

Usually an inguinal access is chosen for the PAE using 4F or 5F sheaths; transbrachial, radial and axillary approaches are possible in principle [30]. Transbrachial access in particular offers advantages in probing the pelvic vessels and is very well accepted by patients. The limited length of the catheter can lead to difficulties in large patients [31]. Depending on the anatomy, if inguinal access is selected, it may be necessary in individual cases to puncture the contralateral groin as well, for example if the cross-over maneuver is anatomically problematic or the catheter position is unstable. Different configurations can be used as diagnostic catheters, e. g. SHK, RIM, Robertson etc. When the coaxial technique is used, the prostatic artery of the corresponding side is then probed using a micro-catheter. In the event of vasospasms, administration of a

vasodilator (e. g. nitroglycerin 0.2 mg i. a. single dose) is recommended. For PAE it is essential to insert the microcatheter in a superselective position in the prostatic artery. Vessels contralateral to the bladder, penis, rectum etc. must be protected. This can be accomplished by a catheter position distal to the outlet of these arteries or by a proximal protective embolization of these arteries using micro-metal spirals. If possible, embolization of the seminal vesicles should also be avoided.

Embolization technique

Once the selective microcatheter position is ensured, the prostatic artery is embolized with permanent embolization particles of 50–500 μm [32, 33]. Both polyvinyl alcohol particles (100–300 μm are usual) as well as calibrated microspheres (300–500 μm are usual) can be used [22]. After successful embolization of one side of the prostate, the procedure is then repeated on the contralateral side.

There is currently no general recommendation regarding optimal particle size. The effectiveness of embolization seems to be the same with both small and large particles [34]. However, there are indications that undesired events occur somewhat more frequently when smaller particles (100–300 μm) are used [35]. This is primarily explained by a deeper penetration of the smaller particles, which probably result in a stronger ischemic and accordingly a greater necrotic effect. However, it is possible that recurrences caused by revascularization can be better avoided in this way. The goal of embolization is to achieve flow stasis in the prostate artery during angiography. To achieve the most complete embolization of the prostate arteries possible, the so-called PER-FeTED technique (Proximal Embolization First, Then Embolize Distal) can be considered [36]. In this procedure, the particles are first injected from a proximal segment of the prostate artery in a flow-controlled manner. Then, after a certain flow deceleration, the microcatheter is advanced into the intraprostatic vascular segments and continues with the injection of particles from a “wedge” position. There are descriptions of this technique introducing 30–50% more embolization particles [37].

Special catheters are currently being tested in order to enable the safest and most effective treatment possible. For example, a micro-catheter with an occlusion balloon at the tip should avoid the risk of reflux of particles during the injection. Occlusion with the balloon is also said to have the effect of lowering the pressure distal to the balloon, which causes a flow reversal in the more distal (unwanted) collaterals, which in turn reduces the risk of untargeted embolization. A different micro-catheter has fine slits at the tip of the catheter, through which only contrast agent can pass but not particles. This is intended to create turbulence around the catheter tip during the injection to prevent reflux of particles. Due to the very limited experience with these special catheters no final recommendation can be given here [38].

Aftercare

After removal of the intervention material and the sheath, the puncture site can be treated by manual compression for 10–15 minutes and subsequent application of a pressure dressing. After transfemoral access, strict bed rest for 4–6 hours is

recommended. Using a closing system may reduce the required bed rest time. In principle, the catheter can be removed on the following day. Only in the case of pre-interventional urinary retention should an attempt to urinate be made only after 14 days [23]. Post-interventional antiphlogistic therapy (e. g. ibuprofen 400 mg p. o. 1–1-1 possibly combined with a proton pump inhibitor e. g. pantoprazole 20 mg p. o. 1–0-0) is recommended for 10 days. Additional analgesics are generally not required. Aftercare should be provided for all patients by an experienced urologist, ideally in a team with an interventional radiologist. Procedure-specific problems can be better identified by the interventional radiologist. Complications such as urinary retention, inflammation or possibly misembolization should be identified early and treated if possible. If post-interventional imaging is necessary, it should be performed by a radiologist experienced with PAE patients.

Side effects and complications

Immediately after the procedure, which is basically painless, and in the first days after the intervention, there may be temporary dysfunctional disorders such as a mild post-embolization syndrome (9.4–10.4%) [29]. These temporary complaints (urodynamy, hematuria, possibly also cramping lower abdominal pain) can usually be effectively controlled by anti-inflammatory or non-steroidal anti-inflammatory drugs (NSAIDs) such as ibuprofen (e. g. 400–600 mg 2–3 times daily p. o. combined with a proton pump inhibitor e. g. pantoprazole 20 mg p. o. 1–0-0). Additional analgesics are generally not required. Since pain after PAE can be partly caused by spasms, a combination of spasmolysis (parasympatholytic e. g. trospium chloride (Spasmex®) 2 \times 20 mg orally and analgesia (e. g. metamizole e. g. 1–2 g IV., generously intensified with a weakly effective opioid such as tramadol e. g. 50–100 mg slowly intensified IV as required) can be performed. For severe pain, which generally occurs very rarely (<0.01%), the opioid piritramide (e. g. 7.5–15 mg slowly IV) is appropriate [39]. Urinary tract infections, generally induced by the catheter, can occur occasionally (0.1–1%) and should be treated early with a broad-spectrum antibiotic against gram-negative bacteria such as third generation cephalosporins.

Transient hematuria or hematospermia, probably due to accidental embolization of the seminal vesicles or the posterior wall of the bladder, is usually self-limiting [40, 41]. Depending on the extent of the prostate ischemia, clouding of the urine may occur in the days and weeks following PAE due to discharge of necrotic tissue. Under certain circumstances, this can result in temporary catheter occlusion. In case of partial necrosis of the middle lobe, valve-like urinary retention is possible. The occurrence of transient urinary retention shortly after PAE is described in the literature with a frequency of up to 10% [40, 41]. A higher rate of post-interventional urinary retention has been reported in patients who have been embolized without a balloon catheter [23].

The overall rate of moderate and severe complications is rare. Rectal bleeding, skin discoloration and ulcers in the area of the perineum or penis as well as persistent pelvic pain indicate misembolization.

Before discharge or shortly afterward, contrast-enhanced sonography or MRI can be performed to document the success of

the embolization. Follow-up examinations (IPSS, IIEF, uroflowmetry (Qmax), residual urine, in case of special interest Pvol, IPP, PUA) are useful after 1–3 months, 6 months and 12 months. After 12 months, morphological changes are no longer expected, so that clinical-urological follow-up is sufficient. Sonography is usually sufficient as imaging monitoring. Depending on the prostate volume, the success of PAE is apparent with a delay of a few weeks to months. The clinical symptoms can still improve up to half a year after PAE; thus, existing drug therapy for BPS should be continued in parallel and then discontinued 1–2 months after PAE.

Other Therapeutic Procedures for Treating BPS

Drug Therapy

For more than 20 years, selective α -blockers, 5- α reductase inhibitors (5- α -RI), and more recently also phosphodiesterase-5 inhibitors have been available for the drug treatment of LUTS, which usually represents the first-line therapy in BOO (bladder outlet obstruction) [13]. Anticholinergics, as well as the β 3 adrenoceptor agonist mirabegron can be used for OAB (overactive bladder) symptoms. Combination preparations of the above-mentioned drugs (depending on the main characteristics of the LUTS α -blockers combined with 5- α -RI or or with anticholinergics) are available on the market.

Alpha-blockers, such as tamsulosin, are rapidly effective and improve IPSS by an average of 6 points, corresponding to a net benefit of 1.8 points over placebo (IPSS reduction of 4.2 points); in addition, the maximum urinary flow rate increases [31]. In principle, α -blockers are limited in their effectiveness for more “kinked” intraprostatic urethras [32]. Use of 5- α -RI leads to a “shrinking” of the prostate; accordingly, an improvement over placebo is only seen in glands >40 ml and after at least 6–12 months. After 2 to 4 years there is a 30% improvement in IPSS, an 18–28% reduction in prostate volume and a 1.5–2.0 m/s improvement in Qmax. The risk of urinary retention is reduced by 57% with 5- α -RI compared to placebo [33]. Phosphodiesterase-5 (PDE-5) inhibitors improve IPSS by 22–37% and Qmax by 0–2.4 ml/s; long-term data are pending.

Several randomized studies show advantages for the combination of α -blocker and 5- α -RI over both placebo and monotherapy, especially with regard to “progression” of BPH. In the CombaT study, for example, the common combination of tamsulosin and dutasteride showed a relative risk reduction for urinary retention of 68%, surgical BPH therapy of 71% and a 41% worsening of symptoms after 4 years [42, 43].

Typical and for many men stressful side effects of the drug treatment of LUTS include

- fatigue, orthostatic dysregulation, retrograde and otherwise abnormal ejaculations, floppy-iris syndrome (IFIS); increased risk of dementia is discussed [35] [36] (α -blockers)
- decreased libido, impotence, erectile dysfunction, rare ejaculation disorders and gynecomastia in 1–2% of patients (5- α -RI),
- headaches, dyspepsia, back pain and myalgia as well as nasal breathing obstruction (PDE-5 inhibitors) [44].

Overall, however, these drugs used have a favorable side effect profile, although the rate of side effects is significantly higher with combination therapy [43].

Surgical Therapy

Surgical therapies of LUTS have traditionally included deobstructive techniques which remove adenoma tissue either partially or completely. Basically, a distinction is made between resection, vaporization and enucleation processes. TUR has been established as the gold standard for many years, and its effectiveness and safety compared to other procedures has been well proven by randomized studies.

Due to the complex pathophysiology, there is no universal therapy algorithm that prefers one method over the numerous therapy alternatives. It is recommended to adapt the treatment to the patient's wishes, primary pathology and comorbidities.

Despite the technical progress made in recent years, surgical procedures are still associated with a relevant overall perioperative morbidity, including 2–2.9% blood transfusions, TUR syndrome (0.8%), urinary retention (4.5%) and bladder tamponades (4.9%) as well as urinary tract infections (4.1%). Long-term complications include erectile dysfunction (6.5%), urethral strictures (3.8%) and urinary incontinence (2.2%) [44–47]. Although surgical procedures are still considered the gold standard and are intended as final solutions, the re-operation rate (re-TURP, urethrotomy, bladder neck incision due to sclerosis) after 1, 5 and 8 years is 5.8, 12.3 and 14.7% respectively [45]. As a consequence of the operation, retrograde ejaculation occurs in about 65% of patients.

Irritant symptoms can initially worsen as a result of surgical therapy, most likely due to the wound in the area of the prostate lobe. The healing process in this case takes months; thus an improvement of irritative symptoms can only be expected in the long term, which is often perceived by patients as stressful [48, 49]. A critical attitude towards surgical interventions has developed among informed patients [45, 47]. There is therefore a strong motivation on the part of urology to establish less complicated procedures with at least the equivalent outcome and fewer side effects.

The current attention to minimally invasive surgical therapies (MIST) results from the limitations of previously established therapies, including the limited effectiveness of drug therapy and potential for side effects of surgical procedures [2, 50]. These therapies can be divided into intraprostatic injections (PRX302, NX-1207), mechanical procedures (Urolift®, iTIND®) and ablative techniques (Rezüm®, AquaBeam®). The complete preservation of sexual function, including undisturbed antegrade ejaculation, is a particular concern of many men. Although MIST approaches currently have a lower side effect profile than the surgical gold standard TURP, most procedures are still significantly inferior to TURP regarding their effectiveness [45, 46]. Urological expert opinion holds that using paradigms existing for decades regarding therapy algorithms result in 80% of all LUTS patients being initially treated with α -blockers, and indications for ablative therapies are made without knowledge or consideration of a BOO are outdated. A reevaluation in favor of differentiated therapeutic strategies is needed to improve outcomes and patient satisfaction [13].

Endovascular PAE, which since 2000 has developed in parallel to the more recent transurethral MIST approaches, is an alternative treatment option taking into account the above-mentioned advantages [9]. Open performance of the PAE is a prerequisite for the correct positioning of the PAE within the therapeutic algorithm. Since the PAE is performed by interventional radiologists after referral by urologists, close interdisciplinary cooperation is of great importance for a meaningful indication.

Existing studies

The first case report of a successful PAE in LUTS and BPH in 2000 led Y.A. Gao et al. to conduct a very early monocentric randomized controlled trial (RCT) to compare PAE to TURP, which is considered the gold standard [51]. The study data published in *Radiology* in 2014 showed a comparable degree of improvement after 12 and 24 months for a total of 6 measured urological function parameters in both groups. However, both complications and minor and severe side effects were significantly higher in the PAE group than in the TURP group. With regard to the increased peri- and post-procedural complication rates of PAE reported in this RCT, however, it must be taken into account that in the recruitment period from 2007 to 2012 the method was certainly not yet technically mature. The 2009 case report by Carnevale et al. [10] and a prospective case series by Pisco et al. in 2011 [52] contributed to broad establishment of PAE. In the meantime, three random clinical trials have been published comparing PAE with “classic” TURP [48, 51, 53]. All three RCTs concern monocentric studies with only a limited number of patients. Evaluated using the propensity score matching method (UK-ROPE trial), the results of these three RCTs, a British registry study and a prospective case-control study, are summarized in a 2018 meta-analysis by Zumstein et al. [54–56]. Current studies show that the influence on the severity of LUTS, measured by the IPSS questionnaire, is significantly lower in PAE compared to the standard surgical procedure (median difference 3.8 points [95% confidence interval [CI]: 2.77–4.83]; $p > 0.001$). PAE was also inferior to surgical procedure in terms of functional parameters in the meta-analysis.

The UK-ROPE registry study reported on 315 patients who received either PAE or TURP, that PAE has minimal peri- and post-interventional complications, making PAE a useful therapeutic option between oral medication (e. g. 5-alpha-reductase inhibitor) and surgery [56].

The overall effectiveness and safety of PAE has been extensively described in prospective and retrospective observational studies, particularly from centers that now offer this procedure in clinical routine [57–62]. In a current systematic review with meta-analysis by Mallin et al. the efficacy and safety of PAE has been summarized and analyzed based on 1254 patients in 13 studies [63]. It was shown that IPSS was significantly reduced by an average of 67% after 12 months post PAE; the median improvement in symptoms was 16.2 points (95% CI, 18.3–14.0). Likewise, quality of life improved by 3 points (95% CI, –3.7, –2.3). On the whole, major complications are extremely rare. Compared to the baseline before PAE, there was also a statistically significant improvement in functional parameters such as prostate volume (PV), residual urine and maximum urine flow rate (Q_{max}). This functional im-

provement is documented with up to 3 years follow-up time. Long-term results over 6 years are only available from a retrospective observational study by Pisco et al. [64]. Out of a total of 630 consecutively followed patients, a clinical success of 76.3% (95% CI, 68.6%–82.4%) of PAE in a small subcollective of 36 men has been reported after 6 years. Clinical success was defined here as an improvement in LUTS symptomatology (IPSS ≤ 15 points and min. 25% reduction compared to baseline before PAE), improvement in quality of life (QoL score ≤ 3 points or a reduction of 1 point from baseline) without additional medication or surgical intervention to treat BPH.

An initial Health Technology Assessment (HTA) report from Austria is already available in German-speaking countries [65]. In this 2017 report, the evidence base for estimating the safety and efficacy of PAE was still considered low. Furthermore, it is stated that the available RCTs report conflicting results regarding efficacy endpoints and adverse events. It was noted that a low rate of serious adverse events such as bladder wall ischemia after PAE has been reported in all studies. The available evidence is not yet sufficient to prove that PAE is as effective as TURP or open adenectomy in patients with moderate to severe LUTS. The HTA report proposes a re-evaluation of the PAE procedure as soon as the data situation has improved and in particular results from further RCTs are available.

The previously published meta-analyses and comparisons between PAE and TURP show various structural deficits that are due to the inconsistent body of data. This has led to data being merged based on very different PAE techniques. Prostate architecture is often neglected, although it is considered relevant how patients with and without a middle prostate lobe respond to different therapies. LUTS symptoms are often reported as the total value of the IPSS without subdivision into retention and emptying symptoms (IPSS SS and VS). However, there is sufficient evidence that individual symptoms of the lower urinary tract are not equivalent in terms of impaired well-being. In a ranking of symptoms, the urge to urinate and nocturia, both irritative retention symptoms, are the clearly clinically leading symptoms. Weak urine stream occupies last place in this ranking [15]. If one only evaluates the total IPSS score, one cannot draw any conclusions as to whether parameters relevant to the patient (urge and nocturia) or rather irrelevant (Q_{max}) parameters have been improved.

Recent urological studies have evaluated the treatment preferences of affected men and provide a differentiated picture: in large cohort studies, nocturia is perceived as more stressful than the symptoms during the day [16–18]. Men suffering from BPS are prepared to invest the highest therapeutic costs for the treatment of urinary urgency and nocturia. It is interesting to note that men otherwise accept therapy costs of the same amount only for maintaining erection and ejaculation [66]. Minimally invasive surgical procedures for BPS have been partly developed to preserve sexual function as far as possible (e. g. Urolift®, Rezüm®, AquaBeam®). Similar to PAE, these procedures, with the exception of aquablation, have a lower deobstructive effect than resection [45, 46, 67, 68].

A recent study from St. Gallen should be highlighted as an example because of the detailed data analysis. In this randomized non-inferiority study by Abt and colleagues, the symptoms of the

lower urinary tract were evaluated individually with respect to non-inferiority of PAE to TURP. There was no significant superiority of the primary variable IPSS and the subjective secondary variables (e. g. nocturia, erectile function index), while the functional parameters were more favorable 12 weeks after TURP; the side effects after PAE were lower and less pronounced [48, 49]. For future studies to be meaningful, a differentiated approach to the symptoms of the lower urinary tract is therefore necessary.

The extent to which PAE must also be measured with other urological surgical procedures such as thulium laser enucleation (THuLEP), transurethral needle ablation (TUNA), transurethral microwave therapy (TUMT) or GreenLight laser vaporization remains questionable [69–71].

Economics of PAE

PAE has been carried out since 2000 and, in the inpatient sector, is represented in the German Diagnosis Related Groups (G-DRG) system for patients of statutory health insurance companies at the time of publication of this position paper:

PAE can be coded as “prostate hyperplasia” (N40) primary diagnosis under the ICD-10-GM (International Classification of Diseases and Related Health Problems; German Modification). No specific diagnosis-related G-DRG case grouping is yet available for the PAE, but it can be grouped in DRG M06Z. This grouping includes “other OR procedures on the male sexual organs or punch biopsy on the prostate”. OR procedures are defined as significant interventions. For the calendar year 2019, the relative weight for DRG M06Z is 0.882. According to the German base case value (BBFW) for 2019 (€ 3544.97), the proceeds from treatment under DRG M06Z thus amount to € 3126.66, but vary according to the different state base case values (LBFW) from state to state. To obtain the full proceeds, the lower limit retention period (uGVD) must be observed, which is currently valid for the PAE for one occupancy day, i. e. two nights, and is often criticized. If the lower limit retention period is undershot, the intervention no longer covers costs. This is due to the fact that PAE in an inpatient setting is based on a cost calculation that includes personnel costs, material costs and other overhead to calculate non-procedural expenses. With respect to personnel costs, it must be taken into account that, on the one hand, personnel costs are already incurred for pre-inpatient examinations and clarification and, on the other, the duration of the procedure can vary considerably. A high level of expertise is required of the interventional radiologist, both in terms of both the duration of the procedure and safety. So far, this has not been taken into account in the remuneration of PAE for inpatients. Consequently PAE should be assigned to its own diagnosis-related group (DRG) as soon as possible in order to describe the procedure in such a way that it can be carried out in an economically cost-covering manner.

When estimating the profitability of PAE for a clinic, in addition to cost accounting, the examination quota of the Medical Service of the Health Insurance Funds (MDK) for the treatment of benign enlargement of the prostate must also be taken into account. Current MDK objections have to do with hospitalization time. In support, it is important to emphasize that patients for PAE are on

average older, and that during PAE a complete parenchymatous organ is embolized. This justifies good preparation and close post-interventional care in order to detect complications such as acute urinary retention (approx. 8%) at an early stage and thus ensure a good overall result. If the lower limit length of stay (uGVD) in hospital is not recognized, relevant deductions to the DRG are to be expected.

Summary

Compared to TURP, endovascular PAE is an alternative therapy for the treatment of BPS with a comparable improvement in symptoms but less subvesical disobstruction in terms of urine flow and retained urine. The procedure was only recently recommended by the British National Institute for Health and Care Excellence (NICE) as a treatment option for BPS [54, 56, 72, 73]. From the patient's point of view, PAE is a minimally invasive, less stressful and more sexual function-preserving therapy for BPS, which does not negatively influence any surgical therapies that may be necessary later and is performed under local anesthesia. From the perspective of the interventional radiologist, this is a technically demanding procedure the complexity of which places high demands on anatomical knowledge, technical skills and equipment. The radiologist must possess extensive experience in embolization therapy. Image guidance using a high-resolution angiography system combined with the possibility of C-arm CT are advantageous and are required as a necessary safety standard for performing PAE. Further comparative randomized head-to-head studies must show how PAE complements urological therapies most effectively. The PAE has its place in the individualized minimally invasive concepts for BPS therapy [25]. Close interdisciplinary collaboration between urologists and radiologists is necessary for the optimal care of patients treated with PAE.

Conflict of Interest

The following authors declare a possible conflict of interest in the last three years: PD Dr. med. Attila Kovács received honoraria from Terumo and Merit; Prof Dr. med. Grimm served as a consultant for the following companies: Astellas, Astra Zeneca, Bayer Health Care, Bristol Myers Squibb, Intuitive Surgical, Ipsen, Janssen Cilag, Medac, MSD, Merck Serono, Novartis, ONO Pharma, Pfizer, Sanofi. He received honoraria from the following companies: Apogepha, Astellas pharma, Astra Zeneca, Bayer Health Care, Bristol Myers Squibb, Hexal, Ipsen, Janssen Cilag, MSD, Merck Serono, Novartis, ONO Pharma, Pfizer. Research support was provided by Bristol-Myers Squibb and Intuitive Surgical; Prof Dr. med. Marcus Katoh served as a consultant for Boston Scientific and received honoraria from Boston Scientific; Prof Dr. med. Bernhard Meyer received honoraria from Merit and Siemens and research support from Siemens; Prof. Dr. med. Frank Wacker is the spokesman for the science and research steering committee and a co-opted member of the managing board of the German Society for Interventional Radiology.

References

- [1] Vuichoud C, Loughlin KR. Benign prostatic hyperplasia: epidemiology, economics and evaluation. *The Canadian journal of urology* 2015; 22 (Suppl. 1): 1–6

- [2] Bschleipfer T, Bach T, Berges R et al. S2e guideline of the German urologists: Instrumental treatment of benign prostatic hyperplasia. *Der Urologe Ausg A* 2016; 55: 195–207. doi:10.1007/s00120-015-3983-0
- [3] Li M, Qiu J, Hou Q et al. Endoscopic enucleation versus open prostatectomy for treating large benign prostatic hyperplasia: a meta-analysis of randomized controlled trials. *PLoS one* 2015; 10: e0121265. doi:10.1371/journal.pone.0121265
- [4] Kuntz RM, Lehrich K, Ahyai SA. Holmium laser enucleation of the prostate versus open prostatectomy for prostates greater than 100 grams: 5-year follow-up results of a randomised clinical trial. *Eur Urol* 2008; 53: 160–166. doi:10.1016/j.eururo.2007.08.036
- [5] Naspro R, Suardi N, Salonia A et al. Holmium laser enucleation of the prostate versus open prostatectomy for prostates >70g: 24-month follow-up. *Eur Urol* 2006; 50: 563–568. doi:10.1016/j.eururo.2006.04.003
- [6] Briganti A, Naspro R, Gallina A et al. Impact on sexual function of holmium laser enucleation versus transurethral resection of the prostate: results of a prospective, 2-center, randomized trial. *J Urol* 2006; 175: 1817–1821. doi:10.1016/s0022-5347(05)00983-3
- [7] Skolarikos A, Papachristou C, Athanasiadis G et al. Eighteen-month results of a randomized prospective study comparing transurethral photoselective vaporization with transvesical open enucleation for prostatic adenomas greater than 80 cc. *Journal of endourology* 2008; 22: 2333–2340. doi:10.1089/end.2008.9709
- [8] Bischoff W, Goerttler U. Successful intra-arterial embolization of bleeding carcinoma of the prostate (author's transl). *Der Urologe Ausg A* 1977; 16: 99–102
- [9] DeMeritt JS, Elmasri FF, Esposito MP et al. Relief of benign prostatic hyperplasia-related bladder outlet obstruction after transarterial polyvinyl alcohol prostate embolization. *J Vasc Interv Radiol* 2000; 11: 767–770
- [10] Carnevale FC, Antunes AA, da Motta Leal Filho JM et al. Prostatic artery embolization as a primary treatment for benign prostatic hyperplasia: preliminary results in two patients. *Cardiovasc Intervent Radiol* 2010; 33: 355–361. doi:10.1007/s00270-009-9727-z
- [11] Li P, Wang C, Cao Q et al. Prostatic Arterial Embolization Followed by Holmium Laser Enucleation of the Prostate as a Planned Combined Approach for Extremely Enlarged Benign Prostate Hyperplasia. *Urologia internationalis* 2017; 99: 422–428. doi:10.1159/000478788
- [12] Nejm AI, Nejm BA, Tachalov MA et al. SUPERSELECTIVE PROSTATIC ARTERY EMBOLIZATION AS A PREPARATORY STEP BEFORE TURP IN THE TREATMENT OF BENIGN PROSTATIC HYPERPLASIA IN PATIENTS WITH LARGE PROSTATES. *Urologia (Moscow, Russia: 1999)* 2015; 60–62, 64
- [13] Oelke M, Bschleipfer T, Hofner K. Fake News BPH – what is really true! *Der Urologe Ausg A* 2019; 58: 271–283. doi:10.1007/s00120-019-0885-6
- [14] Rosier PF, de la Rosette JJ. Is there a correlation between prostate size and bladder-outlet obstruction? *World J Urol* 1995; 13: 9–13
- [15] Eckhardt MD, van Venrooij GE, van Melick HH et al. Prevalence and bothersomeness of lower urinary tract symptoms in benign prostatic hyperplasia and their impact on well-being. *J Urol* 2001; 166: 563–568
- [16] Everaert K, Anderson P, Wood R et al. Nocturia is more bothersome than daytime LUTS: Results from an Observational, Real-life Practice Database including 8659 European and American LUTS patients. *International journal of clinical practice* 2018; 72: e13091. doi:10.1111/ijcp.13091
- [17] Everaert K, Herve F, Bosch R et al. International Continence Society consensus on the diagnosis and treatment of nocturia. *Neurourology and urodynamics* 2019; 38: 478–498. doi:10.1002/nau.23939
- [18] Everaert K, Herve F, Bower W et al. How can we develop a more clinically useful and robust algorithm for diagnosing and treating nocturia? *ICI-RS 2017. Neurourology and urodynamics* 2018; 37: 546–559. doi:10.1002/nau.23569
- [19] Bonekamp D, Salomon G. Imaging for initial diagnosis of localized prostate cancer. *Der Urologe Ausg A* 2019; 58: 494–503. doi:10.1007/s00120-019-0901-x
- [20] Sapoval M, Dariane C, Pellerin O et al. Prostatic artery embolisation for symptomatic BPH. *Presse Med* 2019; 48: 447–453. doi:10.1016/j.lpm.2019.03.009
- [21] Pisco J, Bilhim T, Costa NV et al. Safety and Efficacy of Prostatic Artery Chemoembolization for Prostate Cancer-Initial Experience. *J Vasc Interv Radiol* 2018; 29: 298–305. doi:10.1016/j.jvir.2017.10.013
- [22] Bilhim T, Pisco J, Pereira JA et al. Predictors of Clinical Outcome after Prostate Artery Embolization with Spherical and Nonspherical Polyvinyl Alcohol Particles in Patients with Benign Prostatic Hyperplasia. *Radiology* 2016; 281: 289–300. doi:10.1148/radiol.2016152292
- [23] Carnevale FC, da Motta-Leal-Filho JM, Antunes AA et al. Quality of life and clinical symptom improvement support prostatic artery embolization for patients with acute urinary retention caused by benign prostatic hyperplasia. *J Vasc Interv Radiol* 2013; 24: 535–542. doi:10.1016/j.jvir.2012.12.019
- [24] Wang MQ, Guo LP, Zhang GD et al. Prostatic arterial embolization for the treatment of lower urinary tract symptoms due to large (> 80 mL) benign prostatic hyperplasia: results of midterm follow-up from Chinese population. *BMC Urol* 2015; 15: 33. doi:10.1186/s12894-015-0026-5
- [25] Abt D, Mullhaupt G, Mordasini L et al. Outcome prediction of prostatic artery embolization: post hoc analysis of a randomized, open-label, non-inferiority trial. *BJU Int* 2019; 124: 134–144. doi:10.1111/bju.14632
- [26] Little MW, Boardman P, Macdonald AC et al. Adenomatous-Dominant Benign Prostatic Hyperplasia (AdBPH) as a Predictor for Clinical Success Following Prostate Artery Embolization: An Age-Matched Case-Control Study. *Cardiovasc Intervent Radiol* 2017; 40: 682–689. doi:10.1007/s00270-017-1602-8
- [27] Bagla S, Rholh KS, Sterling KM et al. Utility of cone-beam CT imaging in prostatic artery embolization. *J Vasc Interv Radiol* 2013; 24: 1603–1607. doi:10.1016/j.jvir.2013.06.024
- [28] Werncke T, von Falck C, Luepke M et al. Collimation and Image Quality of C-Arm Computed Tomography: Potential of Radiation Dose Reduction While Maintaining Equal Image Quality. *Investigative radiology* 2015; 50: 514–521. doi:10.1097/rli.0000000000000158
- [29] Uflacker A, Haskal ZJ, Bilhim T et al. Meta-Analysis of Prostatic Artery Embolization for Benign Prostatic Hyperplasia. *J Vasc Interv Radiol* 2016; 27: 1686–1697. doi:10.1016/j.jvir.2016.08.004
- [30] Isaacson AJ, Fischman AM, Burke CT. Technical Feasibility of Prostatic Artery Embolization From a Transradial Approach. *American journal of roentgenology* 2016; 206: 442–444. doi:10.2214/ajr.15.15146
- [31] Bhatia S, Harward SH, Sinha VK et al. Prostate Artery Embolization via Transradial or Transulnar versus Transfemoral Arterial Access: Technical Results. *J Vasc Interv Radiol* 2017; 28: 898–905. doi:10.1016/j.jvir.2017.02.029
- [32] Li Q, Duan F, Wang MQ et al. Prostatic Arterial Embolization with Small Sized Particles for the Treatment of Lower Urinary Tract Symptoms Due to Large Benign Prostatic Hyperplasia: Preliminary Results. *Chinese medical journal* 2015; 128: 2072–2077. doi:10.4103/0366-6999.161370
- [33] Goncalves OM, Carnevale FC, Moreira AM et al. Comparative Study Using 100–300 Versus 300–500 µm Microspheres for Symptomatic Patients Due to Enlarged-BPH Prostates. *Cardiovasc Intervent Radiol* 2016; 39: 1372–1378. doi:10.1007/s00270-016-1443-x
- [34] Torres D, Costa NV, Pisco J et al. Prostatic Artery Embolization for Benign Prostatic Hyperplasia: Prospective Randomized Trial of 100–300 µm versus 300–500 µm versus 100- to 300-µm + 300- to 500-µm Embospheres. *J Vasc Interv Radiol* 2019; 30: 638–644. doi:10.1016/j.jvir.2019.02.014
- [35] Moreira AM, de Assis AM, Carnevale FC et al. A Review of Adverse Events Related to Prostatic Artery Embolization for Treatment of Bladder Outlet Obstruction Due to BPH. *Cardiovasc Intervent Radiol* 2017; 40: 1490–1500. doi:10.1007/s00270-017-1765-3

- [36] Carnevale FC, Moreira AM, Antunes AA. The "PERFecTED technique": proximal embolization first, then embolize distal for benign prostatic hyperplasia. *Cardiovasc Intervent Radiol* 2014; 37: 1602–1605. doi:10.1007/s00270-014-0908-z
- [37] Carnevale FC, Moreira AM, Harward SH et al. Recurrence of Lower Urinary Tract Symptoms Following Prostate Artery Embolization for Benign Hyperplasia: Single Center Experience Comparing Two Techniques. *Cardiovasc Intervent Radiol* 2017; 40: 366–374. doi:10.1007/s00270-017-1569-5
- [38] Isaacson AJ, Hartman TS, Bagla S et al. Initial Experience with Balloon-Occlusion Prostatic Artery Embolization. *J Vasc Interv Radiol* 2018; 29: 85–89. doi:10.1016/j.jvir.2017.09.015
- [39] Christidis D, Clarebrough E, Ly V et al. Prostatic artery embolization for benign prostatic obstruction: assessment of safety and efficacy. *World J Urol* 2018; 36: 575–584. doi:10.1007/s00345-018-2220-z
- [40] Salem R, Hairston J, Hohlastos E et al. Prostate Artery Embolization for Lower Urinary Tract Symptoms Secondary to Benign Prostatic Hyperplasia: Results From a Prospective FDA-Approved Investigational Device Exemption Study. *Urology* 2018; 120: 205–210. doi:10.1016/j.urology.2018.07.012
- [41] Lebdaï S, Delongchamps NB, Sapoval M et al. Early results and complications of prostatic arterial embolization for benign prostatic hyperplasia. *World J Urol* 2016; 34: 625–632. doi:10.1007/s00345-015-1665-6
- [42] Roehrborn CG, Siami P, Barkin J et al. The effects of combination therapy with dutasteride and tamsulosin on clinical outcomes in men with symptomatic benign prostatic hyperplasia: 4-year results from the CombAT study. *Eur Urol* 2010; 57: 123–131. doi:10.1016/j.eururo.2009.09.035
- [43] Serati M, Andersson KE, Dmochowski R et al. Systematic Review of Combination Drug Therapy for Non-neurogenic Lower Urinary Tract Symptoms. *Eur Urol* 2019; 75: 129–168. doi:10.1016/j.eururo.2018.09.029
- [44] Gravas S, Cornu JN, Gacci M et al. EAU guidelines. Presented at the EAU Annual Congress Barcelona 2019. ISBN 978-94-92671-04-2
- [45] Magistro G, Stief CG, Gratzke C. Novel minimally invasive treatment options for male lower urinary tract symptom. *Der Urologe Ausg A* 2019; 58: 254–262. doi:10.1007/s00120-019-0876-7
- [46] Christidis D, McGrath S, Perera M et al. Minimally invasive surgical therapies for benign prostatic hypertrophy: The rise in minimally invasive surgical therapies. *Prostate international* 2017; 5: 41–46. doi:10.1016/j.pnil.2017.01.007
- [47] Lebdaï S, Chevrot A, Doizi S et al. Do patients have to choose between ejaculation and miction? A systematic review about ejaculation preservation technics for benign prostatic obstruction surgical treatment. *World J Urol* 2019; 37: 299–308. doi:10.1007/s00345-018-2368-6
- [48] Abt D, Hechelhammer L, Mullhaupt G et al. Comparison of prostatic artery embolisation (PAE) versus transurethral resection of the prostate (TURP) for benign prostatic hyperplasia: randomised, open label, non-inferiority trial. *BMJ (Clinical research ed)* 2018; 361: k2338. doi:10.1136/bmj.k2338
- [49] Abt D, Mordasini L, Hechelhammer L et al. Prostatic artery embolization versus conventional TUR-P in the treatment of benign prostatic hyperplasia: protocol for a prospective randomized non-inferiority trial. *BMC Urol* 2014; 14: 94. doi:10.1186/1471-2490-14-94
- [50] Hofner K, Bach T, Berges R et al. S2e guideline of the German urologists: Conservative and pharmacologic treatment of benign prostatic hyperplasia. *Der Urologe Ausg A* 2016; 55: 184–194. doi:10.1007/s00120-015-3984-z
- [51] Gao YA, Huang Y, Zhang R et al. Benign prostatic hyperplasia: prostatic arterial embolization versus transurethral resection of the prostate—a prospective, randomized, and controlled clinical trial. *Radiology* 2014; 270: 920–928. doi:10.1148/radiol.13122803
- [52] Pisco JM, Pinheiro LC, Bilhim T et al. Prostatic arterial embolization to treat benign prostatic hyperplasia. *J Vasc Interv Radiol* 2011; 22: 11–19; quiz 20. doi:10.1016/j.jvir.2010.09.030
- [53] Carnevale FC, Iscaife A, Yoshinaga EM et al. Transurethral Resection of the Prostate (TURP) Versus Original and PERFecTED Prostate Artery Embolization (PAE) Due to Benign Prostatic Hyperplasia (BPH): Preliminary Results of a Single Center, Prospective, Urodynamic-Controlled Analysis. *Cardiovasc Intervent Radiol* 2016; 39: 44–52. doi:10.1007/s00270-015-1202-4
- [54] Zumstein V, Betschart P, Vetterlein MW et al. Prostatic Artery Embolization versus Standard Surgical Treatment for Lower Urinary Tract Symptoms Secondary to Benign Prostatic Hyperplasia: A Systematic Review and Meta-analysis. *Eur Urol Focus* 2018. doi:10.1016/j.euf.2018.09.005
- [55] Russo GI, Kurbatov D, Sansalone S et al. Prostatic Arterial Embolization vs Open Prostatectomy: A 1-Year Matched-pair Analysis of Functional Outcomes and Morbidities. *Urology* 2015; 86: 343–348. doi:10.1016/j.urology.2015.04.037
- [56] Ray AF, Powell J, Speakman MJ et al. Efficacy and safety of prostate artery embolization for benign prostatic hyperplasia: an observational study and propensity-matched comparison with transurethral resection of the prostate (the UK-ROPE study). *BJU Int* 2018; 122: 270–282. doi:10.1111/bju.14249
- [57] Pisco JM, Rio Tinto H, Campos Pinheiro L et al. Embolisation of prostatic arteries as treatment of moderate to severe lower urinary symptoms (LUTS) secondary to benign hyperplasia: results of short- and mid-term follow-up. *Eur Radiol* 2013; 23: 2561–2572. doi:10.1007/s00330-012-2714-9
- [58] Bagla S, Smirniotopoulos JB, Orlando JC et al. Comparative Analysis of Prostate Volume as a Predictor of Outcome in Prostate Artery Embolization. *J Vasc Interv Radiol* 2015; 26: 1832–1838. doi:10.1016/j.jvir.2015.08.018
- [59] Kurbatov D, Russo GI, Lepetukhin A et al. Prostatic artery embolization for prostate volume greater than 80 cm³: results from a single-center prospective study. *Urology* 2014; 84: 400–404. doi:10.1016/j.urology.2014.04.028
- [60] Rampoldi A, Barbosa F, Secco S et al. Prostatic Artery Embolization as an Alternative to Indwelling Bladder Catheterization to Manage Benign Prostatic Hyperplasia in Poor Surgical Candidates. *Cardiovasc Intervent Radiol* 2017; 40: 530–536. doi:10.1007/s00270-017-1582-8
- [61] Wang MQ, Duan F, Yuan K et al. Benign Prostatic Hyperplasia: Cone-Beam CT in Conjunction with DSA for Identifying Prostatic Arterial Anatomy. *Radiology* 2017; 282: 271–280. doi:10.1148/radiol.2016152415
- [62] Franiel T, Aschenbach R, Trupp S et al. Prostatic Artery Embolization with 250-µm Spherical Polyzone-Coated Hydrogel Microspheres for Lower Urinary Tract Symptoms with Follow-up MR Imaging. *J Vasc Interv Radiol* 2018; 29: 1127–1137. doi:10.1016/j.jvir.2018.03.014
- [63] Mallin B, Roder MA, Brasso K et al. Prostate artery embolisation for benign prostatic hyperplasia: a systematic review and meta-analysis. *Eur Radiol* 2019; 29: 287–298. doi:10.1007/s00330-018-5564-2
- [64] Pisco JM, Bilhim T, Pinheiro LC et al. Medium- and Long-Term Outcome of Prostate Artery Embolization for Patients with Benign Prostatic Hyperplasia: Results in 630 Patients. *J Vasc Interv Radiol* 2016; 27: 1115–1122. doi:10.1016/j.jvir.2016.04.001
- [65] Hawlik K, Vreugdenburg T. Prostate artery embolisation for benign prostatic hyperplasia – Systematic Review. Health Technology Assessment (Ludwig Boltzmann Institut) 2017
- [66] Mankowski C, Ikenwilo D, Heidenreich S et al. Men's preferences for the treatment of lower urinary tract symptoms associated with benign prostatic hyperplasia: a discrete choice experiment. *Patient preference and adherence* 2016; 10: 2407–2417. doi:10.2147/ppa.S112161

- [67] Gilling P, Barber N, Bidair M et al. WATER: A Double-Blind, Randomized, Controlled Trial of Aquablation((R)) vs Transurethral Resection of the Prostate in Benign Prostatic Hyperplasia. *J Urol* 2018; 199: 1252–1261. doi:10.1016/j.juro.2017.12.065
- [68] Gilling P, Barber N, Bidair M et al. Two-Year Outcomes After Aquablation Compared to TURP: Efficacy and Ejaculatory Improvements Sustained. *Adv Ther* 2019; 36: 1326–1336. doi:10.1007/s12325-019-00952-3
- [69] Zheng X, Qiu Y, Qiu S et al. Photoselective vaporization has comparative efficacy and safety among high-risk benign prostate hyperplasia patients on or off systematic anticoagulation: a meta-analysis. *World J Urol* 2018. doi:10.1007/s00345-018-2530-1
- [70] Naspro R, Gomez Sancha F, Manica M et al. From “gold standard” resection to reproducible “future standard” endoscopic enucleation of the prostate: what we know about anatomical enucleation. *Minerva Urol Nefrol* 2017; 69: 446–458. doi:10.23736/S0393-2249.17.02834-X
- [71] Cornu JN, Ahyai S, Bachmann A et al. A Systematic Review and Meta-analysis of Functional Outcomes and Complications Following Transurethral Procedures for Lower Urinary Tract Symptoms Resulting from Benign Prostatic Obstruction: An Update. *Eur Urol* 2015; 67: 1066–1096. doi:10.1016/j.eururo.2014.06.017
- [72] Mayor S. NICE recommends prostate artery embolisation as a treatment option for BPH symptoms. *BMJ (Clinical research ed)* 2018; 361: k1879. doi:10.1136/bmj.k1879
- [73] Abt D, Mullhaupt G, Mordasini L et al. Outcome prediction of prostatic artery embolization: post hoc analysis of a randomized, open-label, non-inferiority trial. *BJU Int* 2018. doi:10.1111/bju.14632