The "double string" sign: a warning image after cold endoscopic mucosal resection

▶ **Fig. 1** Sessile serrated lesion Paris 0-Is, NICE-1, in the right colon.

A 52-year-old man underwent screening colonoscopy. A sessile serrated lesion (Paris 0-Is, NICE-1; 17 mm diameter) was observed in the right colon. After submucosal injection with gelofusine plus indigo carmine, en bloc cold endoscopic mucosal resection (cold-EMR) was attempted using a 25-mm braided snare (SnareMaster SD-210U-25; Olympus, Tokyo, Japan) (▶ **Fig. 1**). After snare closure, moderate traction of the snare sheath was applied to remove the lesion; however, the lesion remained trapped due to a large amount of tissue caught. The snare was repositioned slightly, and resection was successful. On inspection of the mucosal defect, the submucosal layer was observed with apparent "bubble sign" after waterjet irrigation (▶ **Fig. 2 a**, ▶ **Video 1**), followed by a "double string" sign, suggesting exposure of damaged muscle fibers (▶ **Fig. 2 b**). After insufflation and water irrigation, these muscle fibers separated showing deep muscular injury with visible serosa (▶ **Fig. 2 c**). The defect was immediately closed with endoscopic clips (▶ **Fig. 2 d**). The patient was monitored for 4 hours and discharged with prophylactic antibiotics and no symptoms. No complications occurred. Histology confirmed a 21 × 12 × 2 mm specimen and suspicion of serrated lesion without dysplasia.

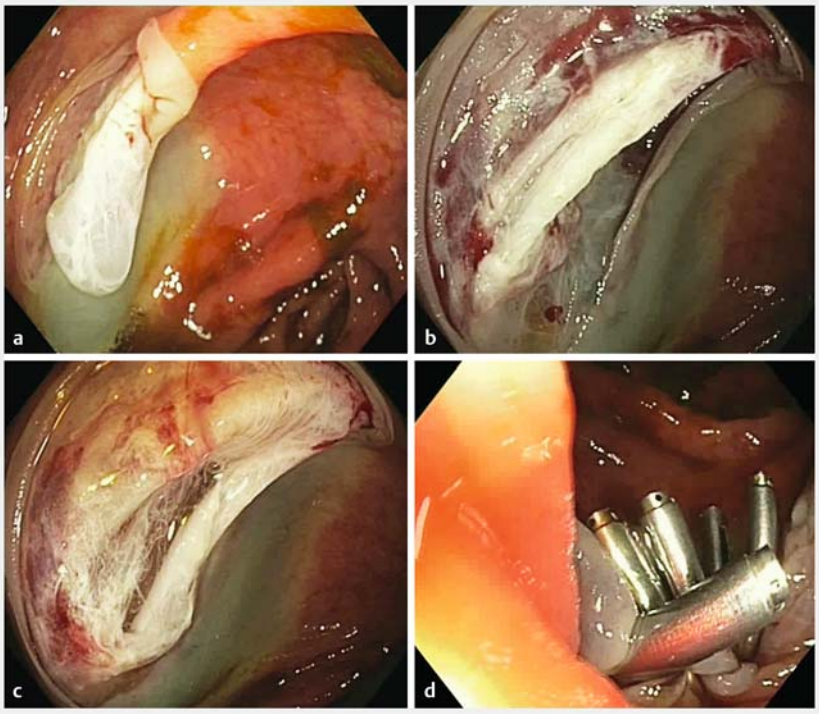

▶ **Fig. 2** The mucosal defect after cold endoscopic mucosal resection. **a** Submucosal layer with apparent "bubble sign" after waterjet irrigation. **b** Injured muscle layer, "double string" image. **c** Perforation site. **d** Complete endoscopic closure with clips.

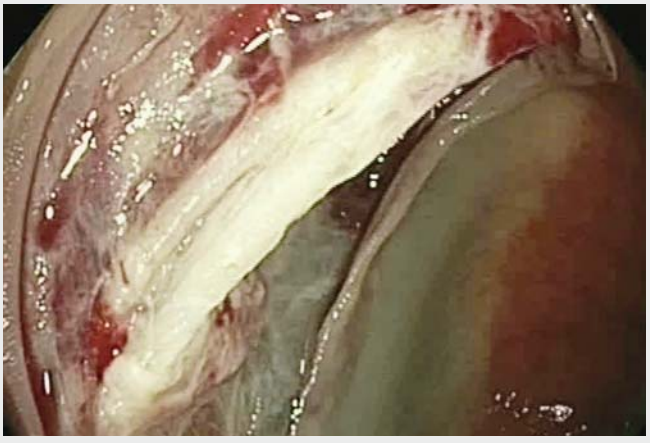

▶ **Video 1** The "double string" sign and perforation after cold endoscopic mucosal resection.

Colonic perforation after cold-EMR is infrequent [1–4]. The description of a new sign in the mucosal defect ("double string sign") after cold-EMR should alert endoscopists to prevent delayed perforation. The sign refers to bundles of muscle fibers with loose disposition within the mucosal defect that indicates deep injury to the muscular layer. This is caused by a combination of snare closure and excessive traction applied to remove the tissue. The use of specifically designed snares for cold snare polypectomy with greater excision ability (without the need for traction of the snare sheath) [1] and tissue resections <15 mm could decrease the risk of injury to the muscular layer during cold-EMR.

Endoscopy_UCTN_Code_CPL_1AJ_2AH

Competing interests

The authors declare that they have no conflict of interest.

The authors

Óscar Nogales Rincón, Julia García García, Olga Ortega Lobete, Carlos Carbonell Blanco, Laura Rayón Moreno, Javier Aranda Hernández, Beatriz Merino Rodríguez
Department of Gastroenterology, Endoscopy Unit, Hospital General Universitario Gregorio Marañón, Madrid, Spain

Corresponding author

Óscar Nogales Rincón, MD
Department of Gastroenterology, Endoscopy Unit, Hospital General Universitario Gregorio Marañón, Calle Doctor Esquerdo, 46, 28007 Madrid, Spain
Fax: +34-91-5868307
oscarnogalesrincon@gmail.com

References

[1] Ferlitsch M, Moss A, Hassan C et al. Colorectal polypectomy and endoscopic mucosal resection (EMR): European Society of Gastrointestinal Endoscopy (ESGE) Clinical Guideline. Endoscopy 2017; 49: 270–297
[2] Paspatis GA, Dumonceau JM, Barthet M et al. Diagnosis and management of iatrogenic endoscopic perforation: European Society of Gastrointestinal Endoscopy (ESGE) Position Statement. Endoscopy 2014; 46: 693–711
[3] Rodriguez SanchezJ, Sánchez AlonsoM, Pellisé M. Bubble sign: detecting perforation after cold snare polypectomy. Endoscopy 2019; 51: 796–797
[4] Chandrasekar VT, Spadaccini M, Aziz M et al. Cold snare endoscopic resection of non-pedunculated colorectal polyps larger than 10mm: a systematic review and pooled analysis. Gastrointest Endosc 2019; 89: 929–936

Bibliography

Endoscopy 2021; 53: E71–E72
DOI 10.1055/a-1193-4456
ISSN 0013-726X
published online 19.6.2020

Georg Thieme Verlag KG, Rüdigerstraße 14, 70469 Stuttgart, Germany