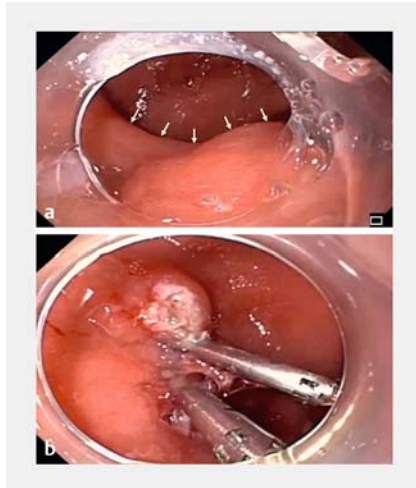
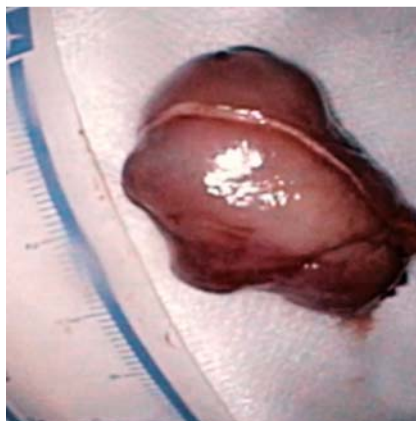


Endoscopic resection of a giant duodenal mass

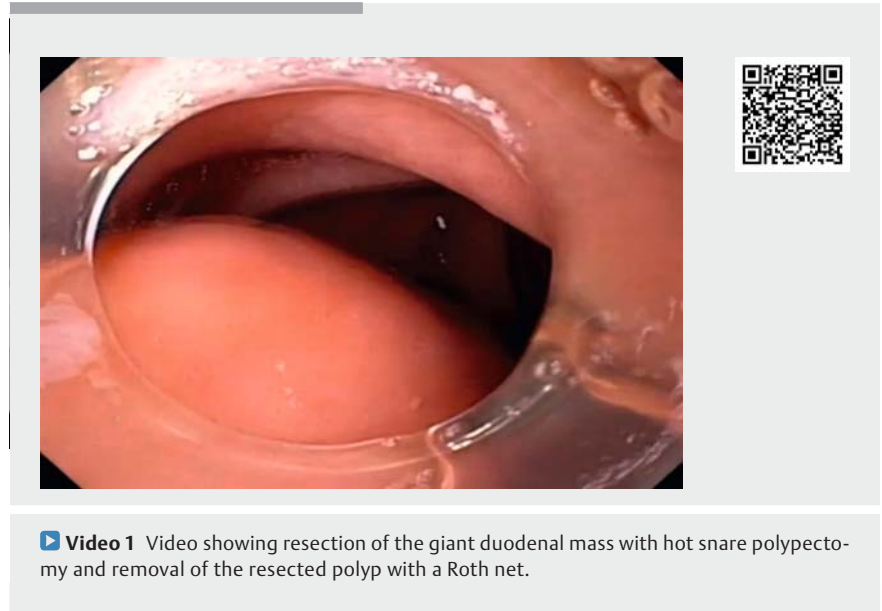


► **Fig. 1** Endoscopic views showing: **a** a semi-pedunculated benign-appearing duodenal polyp (arrows); **b** the polyp resection site following the application of hemostatic clips.



► **Fig. 2** Gross appearance of the polyp showing its smooth surface.

A 79-year-old Caucasian man with a past medical history of hypertension and diabetes was referred to interventional gastroenterology for recurrent episodes of gastrointestinal (GI) bleeding and intermittent gastric outlet obstruction. The patient underwent upper GI endoscopy at an outside facility, where duodenal intubation was noted to be difficult owing



► **Video 1** Video showing resection of the giant duodenal mass with hot snare polypectomy and removal of the resected polyp with a Roth net.

to a large polyp in the duodenal bulb. The patient was referred owing to concerns about malignancy and for potential endoscopic resection. Upper GI radial endoscopic ultrasound (EUS) showed a 2.8 × 2.5-cm rounded, homogeneous, hypoechoic lesion arising from layer two (muscularis mucosa) or layer three (submucosa) with intact muscularis propria, with no surrounding lymphadenopathy (► **Video 1**).

A repeat upper GI endoscopy showed the esophagus and stomach appeared normal. Duodenal intubation was achieved with difficulty owing to partial obstruction of the lumen by the polyp. The polyp was semi-pedunculated with a benign appearance, a broad-based stalk, and a lesion size of 5–6 cm (► **Fig. 1 a**). The edges of the polyp were marked and the base was elevated with submucosal injection. Because of the size of the polyp, hot snare polypectomy was performed, with close monitoring of the stalk for bleeding. The large size of the polyp led to difficulty in its retrieval across the pylorus despite multiple attempts (► **Video 1**). Retrieval was finally achieved using a

large snare, with extreme caution at the pyloric orifice, gastroesophageal junction, and in the cricopharyngeal area. Examination of the polypectomy site showed minimal bleeding, which was secured by the application of two hemostatic clips (► **Fig. 1 b**).

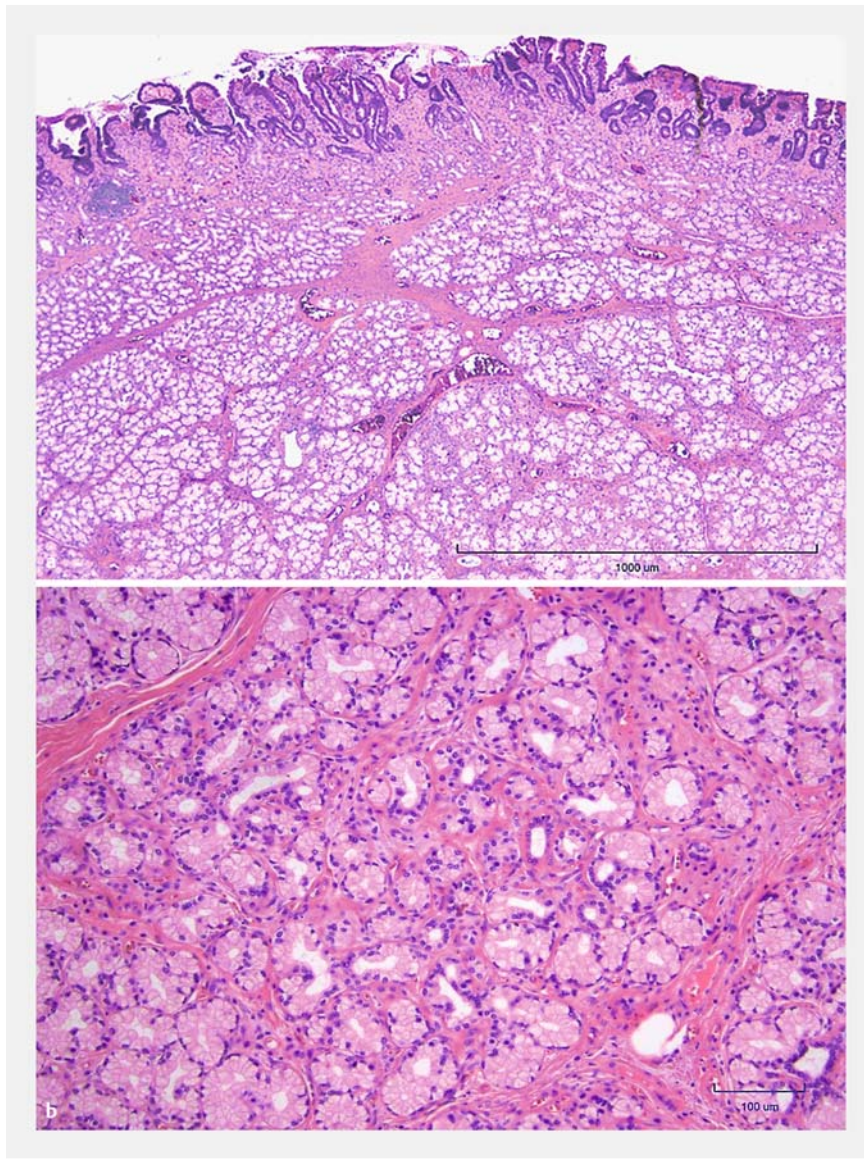
Gross inspection of the polyp showed a smooth-surfaced lesion with no signs of ulceration or bleeding (► **Fig. 2**). Histology revealed a well differentiated Brunner's gland lesion without signs of malignancy (► **Fig. 3**).

Brunner's gland lesions are usually less than 10 mm in size (referred to as hyperplasia) but can grow larger and can present with bleeding and obstruction [1]. Endoscopic removal should be attempted when the patient is symptomatic [2].

Endoscopy_UCTN_Code_TTT_1AO_2AG

Competing interests

The authors declare that they have no conflict of interest.



► **Fig. 3** Histologic appearance showing: **a** the duodenal polyp with reactive changes in the overlying duodenal mucosa, including partial villous blunting and crypt elongation; **b** the polyp consisting of a well-demarcated proliferation of bland-appearing Brunner's glands in the mucosa and submucosa of the duodenum.

The authors

Abhilash Perisetti¹, Benjamin Tharian¹, Felicia D. Allard², Hemant Goyal³, Sumant Inamdar¹

¹ Division of Gastroenterology and Hepatology, University of Arkansas for Medical Sciences, Little Rock, Arkansas, USA

² Division of Gastrointestinal Hepatobiliary Pathology and Cytology, University of Arkansas for Medical Sciences, Little Rock, Arkansas, USA

³ Department of Internal Medicine, The Wright Center for Graduate Medical Education, Scranton, Pennsylvania, USA

Corresponding author

Abhilash Perisetti, MD

University of Arkansas for Medical Sciences,
4301 W Markham St # 567, Little Rock,
AR 72205, USA
abhilash.perisetti@gmail.com

References

- [1] Basford PJ, Bhandari P. Endoscopic management of nonampullary duodenal polyps. *Therap Adv Gastroenterol* 2012; 5: 127–138
- [2] Javia SB, Chathadi K. Cold snare piecemeal endoscopic mucosal resection of a very large duodenal adenoma. *Endoscopy* 2019; 51: E217–E218

Bibliography

Endoscopy 2021; 53: E73–E74

DOI 10.1055/a-1193-4496

ISSN 0013-726X

published online 26.6.2020

© 2020. Thieme. All rights reserved.

Georg Thieme Verlag KG, Rüdigerstraße 14,
70469 Stuttgart, Germany

ENDOSCOPY E-VIDEOS

<https://eref.thieme.de/e-videos>



Endoscopy E-Videos is a free access online section, reporting on interesting cases and new techniques in gastroenterological endoscopy. All papers include a high quality video and all contributions are freely accessible online.

This section has its own submission website at

<https://mc.manuscriptcentral.com/e-videos>