Article published online: 2020-06-26

Bariatric gastric band removal using a gastric mural erosion technique induced with a fully covered self-expandable metal stent

Laparoscopic removal of non-eroded bariatric gastric bands may lead to major complications [1]. A minimally invasive approach involving endoscopic removal is a less risky option [2]. The stent-induced mural erosion technique using self-expandable plastic stents has been reported a few times [3–5]. The use of a fully covered self-expandable metal stent (FCSEMS) is anecdotally reported [1].

A 53-year-old woman with a history of morbid obesity who had undergone bariatric surgery using a nonadjustable banded vertical gastroplasty 20 years previously presented with daily repeated vomiting and gastroesophageal reflux disease. Upper gastrointestinal (GI) endoscopy revealed the proximal stomach (above the gastric band), which was deformed by excessive dilation, and a concentric ring secondary to band compression, without endoscopic exteriorization, and covered by preserved mucosa.

Endoscopic removal of the gastric band was planned. In the first step, an esophageal FCSEMS (155×23 mm; WallFlex) was successfully placed, with the proximal end deployed above the gastric band compression and the distal end of the stent released 5 cm distally to the ring (▶ **Fig. 1** and ▶ **Fig. 2**). In the second step performed after 2 weeks, a second upper GI endoscopy was scheduled to retrieve the FCSEMS and for en bloc removal of the band. The intra-stent endoscopic view allowed visualization of the white band, which was already visible because of erosion of the gastric wall induced by the stent. Removal of the FCSEMS using a grasping foreign body forceps (Rat Tooth/Alligator Grasping Forceps; Rescue Combo, Boston Scientific) and guided by fluoroscopy and endoscopy was performed without incident. The subsequent endoscopic view showed a total and surprising visualization of the nonadjustable bariatric band, externalized to the gastric cavity, which therefore allowed its en bloc removal using the same grasping forceps without any adverse events (▶ **Fig. 3**, ▶ **Fig. 4** and ▶ **Fig. 5**; ▶ **Video 1**).

Endoscopic removal of a nonadjustable bariatric band using an esophageal FCSEMS-induced gastric mural erosion technique seems to be feasible and effective, and could allow easier extraction of the band than using a plastic stent.

Endoscopy_UCTN_Code_CPL_1AH_2AK

▶ **Fig. 1** Endoscopic image of the gastric ring related to the gastric band compression.

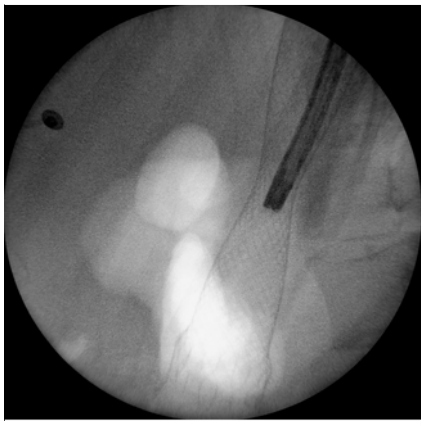

▶ **Fig. 2** Fluoroscopic image of the deployed fully covered self-expandable metal stent showing an hourglass shape due to the gastric band compression.

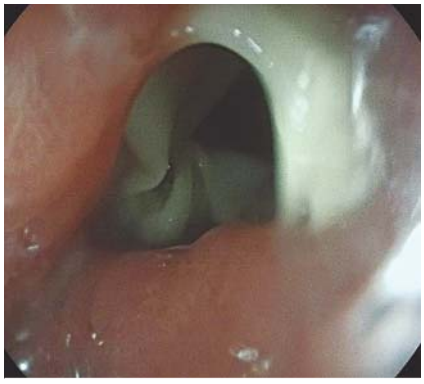

▶ **Fig. 3** Endoscopic view of the gastric band identified after retrieval of the fully-covered self-expandable metal stent.

▶ **Fig. 4** The nonadjustable gastric band after its removal using the fully covered self-expandable metal stent-induced erosion technique.

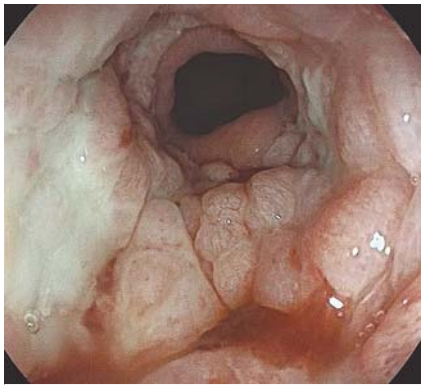

▶ **Fig. 5** Endoscopic view showing the stenotic area left after en bloc removal of the gastric band.

Video 1 Removal of a bariatric band using a gastric mural erosion technique induced with a fully covered self-expandable metal stent.

Competing interests

J. B. Gornals is a consultant for Boston Scientific. The remaining authors declare that they have no conflict of interest.

The authors

Julio G. Velasquez-Rodriguez[1], Amador Garcia Ruiz de Gordejuela[1,2], Joan B. Gornals[1,3]

1 Endoscopy Unit, Department of Digestive Diseases, Hospital Universitari de Bellvitge-IDIBELL, University of Barcelona, Barcelona, Spain
2 Surgical Department, Hospital Universitari de Vall d'Hebron, Universitat Autonoma de Barcelona, Barcelona, Spain
3 Faculty of Health Sciences, Universitat Oberta de Catalunya, Barcelona, Spain

Corresponding author

Joan B. Gornals, MD, PhD
Endoscopy Unit, Dept. of Digestive Diseases, Hospital Universitari de Bellvitge-IDIBELL (Bellvitge Biomedical Research Institute), Feixa Llarga s/n, 08907 L'Hospitalet de Llobregat, Barcelona, Catalonia, Spain
Fax: +34-93-2607681
jgornals@bellvitgehospital.cat

References

[1] Hassan TM, Ontiveros E, Davis D et al. Endoscopic removal of noneroded nonadjustable gastric bands using induced mucosal erosion with a stent, and review of the literature. Surg Innov 2019; 26: 162–167
[2] Flor L, Gornals JB, Ruiz-de-Gordejuela AG. Endoscopic removal of eroded gastric band using strangulation technique with a mechanical lithotriptor as a minimally invasive procedure. Dig Endosc 2014; 26: 296–297
[3] Blero D, Eisendrath P, Vandermeeren A et al. Endoscopic removal of dysfunctioning bands or rings after restrictive bariatric procedures. Gastrointest Endosc 2010; 71: 468–474
[4] Wilson TD, Miller N, Brown N et al. Stent induced gastric wall erosion and endoscopic retrieval of nonadjustable gastric band: a new technique. Surg Endosc 2013; 27: 1617–1621
[5] Marins Campos J, Moon RC, Magalhães Neto GE et al. Endoscopic treatment of food intolerance after a banded gastric bypass: inducing band erosion for removal using a plastic stent. Endoscopy 2016; 48: 516–520

Bibliography

Endoscopy 2021; 53: E77–E78
DOI 10.1055/a-1195-2191
ISSN 0013-726X
published online 26.6.2020

Georg Thieme Verlag KG, Rüdigerstraße 14, 70469 Stuttgart, Germany