Article published online: 2020-07-13

Underwater endoscopic submucosal dissection for a duodenal neuroendocrine tumor using pocket creation and ring-shaped thread countertraction methods

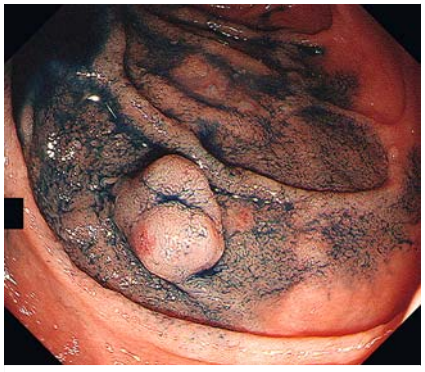

▶ **Fig. 1** Endoscopic image showing a duodenal neuroendocrine tumor at the superior duodenal angle.

A 55-year-old man was previously diagnosed with a neuroendocrine tumor (NET) following biopsy of a duodenal submucosal tumor. He was referred to our hospital for treatment of the lesion. Esophagogastroduodenoscopy revealed a submucosal tumor measuring 9 mm in diameter at the superior duodenal angle (▶ **Fig. 1 a**). Endoscopic ultrasound (EUS) revealed a uniform, low echogenic tumor of 8.6 mm in the submucosal layer. Underwater endoscopic submucosal dissection (uESD) [1] using the pocket creation method (PCM) [2] and ring-shaped thread countertraction technique [3] was performed (▶ **Fig. 2**; ▶ **Video 1**).

First, hyaluronic acid was injected into the submucosa around the lesion, and an incision of about 1.5 cm was made in the mucosa on the oral side of the lesion. The submucosa below the lesion was dissected using the water-immersion PCM. After a circumferential mucosal incision had been created around the lesion, a 10-mm ring thread was attached to the oral side of the lesion by an endoclip. The other end of the ring thread was then attached, by a second endoclip, to the normal mucosa opposite the lesion (▶ **Fig. 3 a**). The lesion was completely resected en bloc with no adverse events (▶ **Fig. 3 b**). Histologi-

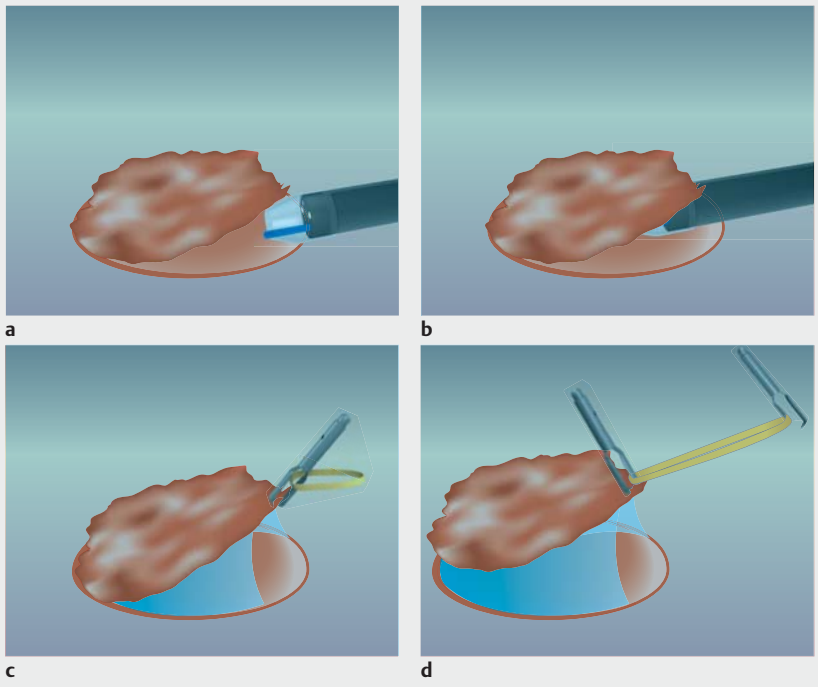

▶ **Fig. 2** Schematic of the steps involved in the ring-shaped thread countertraction technique: **a, b** underwater endoscopic submucosal dissection using the pocket creation method; **c** attachment of one end of the 10-mm ring thread to the oral side of the lesion by an endoclip; **d** attachment of the other end of the ring thread to the normal mucosa opposite to the lesion by the clip, which allows sufficient traction to be obtained with the ring-shaped thread.

▶ **Video 1** Underwater endoscopic submucosal dissection of a duodenal neuroendocrine tumor using the pocket creation method and the ring-shaped thread countertraction technique.

This document was downloaded for personal use only. Unauthorized distribution is strictly prohibited.

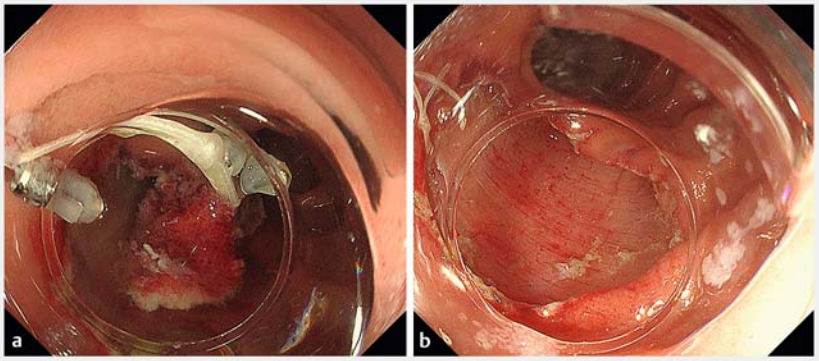

▶ **Fig. 3** Endoscopic images showing: **a** the ring-shaped thread countertraction technique, with one of the clips attached to the oral side of the lesion and the other to the duodenal wall opposite the lesion; **b** the duodenal ulcer after successful endoscopic submucosal dissection.

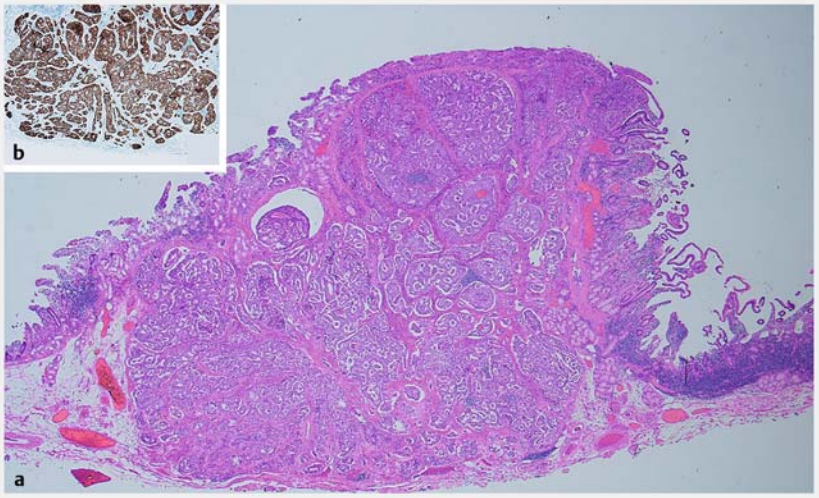

▶ **Fig. 4** Histopathological view of the en bloc resected neuroendocrine tumor: **a** on hematoxylin and eosin (H&E) staining; **b** showing positive staining with chromogranin A.

cal examination confirmed a gastrointestinal NET G1 with submucosal invasion (2460 µm) (▶ **Fig. 4**). The vertical and horizontal margins were negative for tumor.

Duodenal NETs are rare; they represent 3.8 % of all gastrointestinal NETs [4]. Endoscopic treatment may be performed for duodenal NETs measuring ≤ 10 mm in diameter and confined to the submucosal layer, without metastasis.

Common endoscopic treatments for duodenal NETs have included endoscopic submucosal resection with a ligation device, endoscopic mucosal resection (EMR), and cap-assisted EMR [5]. However, these carry the risk of perforation and the possibility of positive vertical margins. A combination of these methods can allow en bloc resection of duodenal NETs more safely.

Endoscopy_UCTN_Code_TTT_1AO_2AG

Acknowledgments

We would like to thank Editage (www.editage.com) for English language editing.

Competing interests

The authors declare that they have no conflict of interest.

The authors

Mitsuhiro Kono, Yasuaki Nagami, Daiki Kitagawa, Taku Manabe, Masaki Ominami, Shusei Fukunaga, Yasuhiro Fujiwara
Department of Gastroenterology, Osaka City University Graduate School of Medicine, Osaka, Japan

Corresponding author

Yasuaki Nagami, MD
Department of Gastroenterology, Osaka City University Graduate School of Medicine, 1-4-3, Asahimachi, Abeno-ku, Osaka, 545-8585, Japan
Fax: +81-6-66453813
yasuaki1975@hotmail.com

References

[1] Nagata M. Underwater endoscopic submucosal dissection in saline solution using a bent-type knife for duodenal tumor. Video-GIE 2018; 22: 375–377
[2] Miura Y, Hayashi Y, Lefor AK et al. The pocket-creation method of ESD for gastric neoplasm. Gastrointest Endosc 2016; 83: 457–458
[3] Mori H, Kobara H, Nishiyama N et al. Novel effective and repeatedly available ring-thread counter traction for safer colorectal endoscopic submucosal dissection. Surg Endosc 2017; 31: 3040–3047
[4] Modlin IM, Lye KD, Kidd M. A 5-decade analysis of 13,715 carcinoid tumors. Cancer 2003; 97: 934–959
[5] Oono Y, Shinmura K, Hori K et al. Endoscopic submucosal resection using a ligation device without injection for duodenal neuroendocrine tumors. Surg Endosc 2019; 33: 2008–2014

Bibliography

Endoscopy 2021; 53: E110–E111
DOI 10.1055/a-1198-4153
ISSN 0013-726X
published online 13.7.2020
© 2020. Thieme. All rights reserved.
Georg Thieme Verlag KG, Rüdigerstraße 14, 70469 Stuttgart, Germany

This document was downloaded for personal use only. Unauthorized distribution is strictly prohibited.