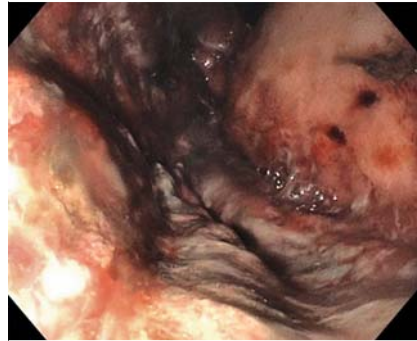


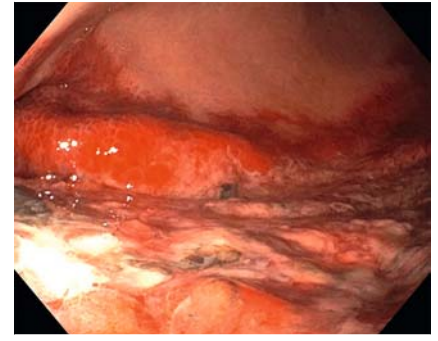
Gastric ischemia and portal vein thrombosis in a COVID-19-infected patient

A 51-year-old man admitted with acute respiratory failure from a SARS-CoV-2 infection had large volume of bloody output via orogastric tube following initiation of heparin for a lower extremity deep vein thrombosis. Esophagogastroduodenoscopy revealed diffuse and severe mucosal ischemia involving the gastric fundus (► **Fig. 1**), greater curvature, and posterior wall of the gastric body and antrum (► **Fig. 2**) (► **Video 1**). The anterior gastric wall and duodenum appeared normal. Computed tomography (CT) angiogram of the abdomen revealed gastric pneumatosis (► **Fig. 3**), a non-occlusive thrombus in the right and left portal veins, and portal venous gas (► **Fig. 4**). The small bowel and colon appeared normal. In addition to management of the underlying COVID infection and respiratory complications, management included nasogastric decompression and intravenous heparin. A repeat abdominal CT 1 week later showed resolution of the intramural gastric and portal venous gas, and no residual portal vein thrombosis (► **Fig. 5**).

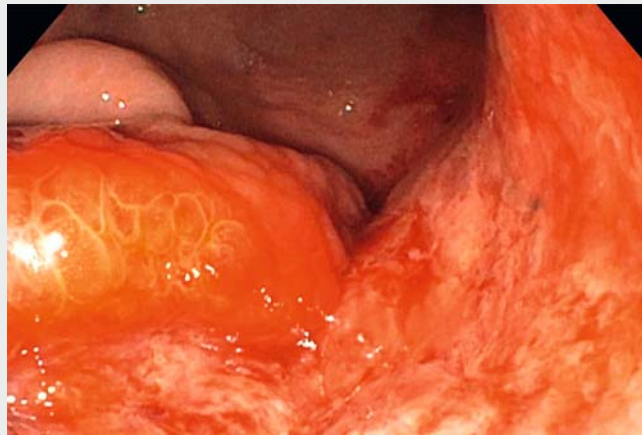
Gastrointestinal tract involvement, ranging from minor symptoms to small bowel ischemia, has been reported with the SARS-CoV-2 virus, which may be due to a high surface expression of angiotensin-converting enzyme 2 (ACE2) receptors on gastric cells and enterocytes [1, 2]. The underlying mechanism of small bowel ischemia is not known but might result from direct viral infiltration via ACE2 receptors on enterocytes and endothelial cells, complement-mediated small vessel thrombosis, non-occlusive mesenteric ischemia, or systemic coagulopathy [3, 4]. Gastric ischemia is a rare condition that results from vascular insufficiency due to local or systemic disorders and is associated with poor clinical outcomes if not recognized and treated early [5]. Our patient had gastric ischemia and portal vein thrombosis in the setting of a COVID-19 infection in the absence of other thromboembolic risk



► **Fig. 1** Mucosal changes of ischemia involving entire gastric fundus.



► **Fig. 2** Mucosal changes of ischemia involving greater curvature with sparing of anterior wall.



► **Video 1** Esophagogastroduodenoscopy findings of gastric mucosal ischemia with normal duodenum in the setting of COVID-19 infection.

factors. Based on a review of the literature, we found no reported cases of COVID-19-associated gastric ischemia. A high index of suspicion may result in early recognition of this complication and treatment with anticoagulation.

Endoscopy_UCTN_Code_CCL_1AB_2AC_3AZ

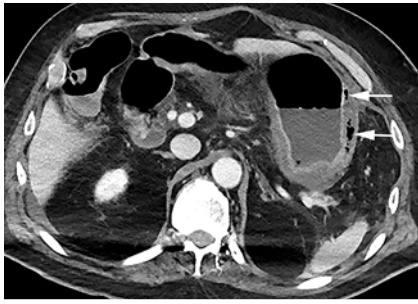Competing interests

The authors declare that they have no conflict of interest.

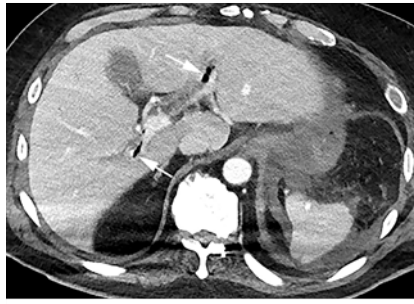
The authors

See-Wei Low¹, Karen L. Swanson¹, Josiah D. McCain², Ayan Sen³, Akira Kawashima⁴, Shabana F. Pasha²

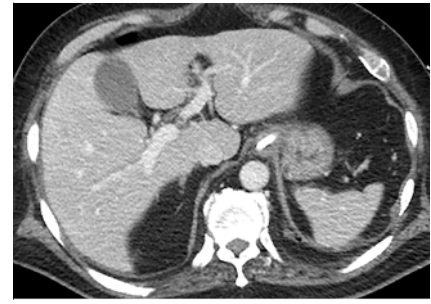- 1 Division of Pulmonary and Critical Care, Mayo Clinic Arizona
- 2 Division of Gastroenterology and Hepatology, Mayo Clinic Arizona
- 3 Department of Critical Care Medicine, Mayo Clinic Arizona
- 4 Department of Radiology, Mayo Clinic Arizona



► **Fig. 3** Gastric pneumatosis seen on computed tomography angiogram.



► **Fig. 4** Non-occlusive thrombus in the right and left portal veins, and portal venous gas on computed tomography angiogram.



► **Fig. 5** Radiologic resolution of intramural gastric and portal venous gas, and portal vein thrombosis.

Corresponding author

Shabana F. Pasha, MD

Division of Gastroenterology and Hepatology, Mayo Clinic Arizona, 13400 E. Shea Blvd, Scottsdale, Arizona 85259, USA
Phone: +1-480-301-8673
Pasha.Shabana@mayo.edu

References

- [1] Bhayana R, Som A, Li MD et al. Abdominal imaging findings in COVID-19: preliminary observations. *Radiology* 2020. doi:10.1148/radiol.2020201908
- [2] Kumar VCS, Mukherjee S, Harne PS et al. Novelty in the gut: a systematic review and meta-analysis of the gastrointestinal manifestations of COVID-19. *BMJ Open Gastroenterol* 2020; 7: 1–9

- [3] Magro C, Mulvey JJ, Berlin D et al. Complement associated microvascular injury and thrombosis in the pathogenesis of severe COVID-19 infection: a report of five cases. *Transl Res* 2020; 220: 1–13
- [4] Zsuzsanna V, Flammer AJ, Steiger P et al. Endothelial cell infection and endotheliitis in COVID-19. *Lancet* 2020; 395: 1417–1418
- [5] Sharma A, Mukewar S, Chari ST et al. Clinical features and outcomes of gastric ischemia. *Dig Dis Sci* 2017; 62: 3550–3556

Bibliography

Endoscopy 2020; 52: E465–E466
DOI 10.1055/a-1230-3357
ISSN 0013-726X
published online 2.9.2020
© 2020. Thieme. All rights reserved.
Georg Thieme Verlag KG, Rüdigerstraße 14,
70469 Stuttgart, Germany

ENDOSCOPY E-VIDEOS

<https://eref.thieme.de/e-videos>



Endoscopy E-Videos is a free access online section, reporting on interesting cases and new

techniques in gastroenterological endoscopy. All papers include a high quality video and all contributions are freely accessible online.

This section has its own submission website at
<https://mc.manuscriptcentral.com/e-videos>