

Effectiveness of Superior Hypogastric Plexus Block for Pain Control Compared to Epidural Anesthesia in Women Requiring Uterine Artery Embolization for the Treatment of Uterine Fibroids – A Retrospective Evaluation

Effektivität und Sicherheit der Blockade des Plexus hypogastricus superior zur Schmerzkontrolle im Vergleich zur Epiduralanästhesie bei arterieller Embolisation in der Myombehandlung – eine retrospektive Evaluation

Authors

Amer Malouhi¹, Rene Aschenbach¹, Anna Erbe¹, Zbigniew Owsianowski², Stefan Rußwurm³, Ingo B. Runnebaum⁴, Ulf Teichgräber¹

Affiliations

- 1 Institut für Diagnostische und Interventionelle für Radiologie, Universitätsklinikum Jena IDIR, Jena, Germany
- 2 Gynäkologie & onkologische Gynäkologie, Klinik Hallerwiese, Nürnberg, Germany
- 3 Abteilung für Anästhesie, Hufeland Klinikum GmbH, Bad Langensalza, Germany
- 4 Klinik für Frauenheilkunde und Fortpflanzungsmedizin, Universitätsklinikum, Jena, Germany

Key words

fibroids, interventional pain management, microspheres, nerve block, pelvic pain, superior hypogastric plexus

received 11.05.2020

accepted 20.07.2020

published online 03.09.2020

Bibliography

Fortschr Röntgenstr 2021; 193: 289–297

DOI 10.1055/a-1231-5649

ISSN 1438-9029

© 2020. Thieme. All rights reserved.

Georg Thieme Verlag KG, Rüdigerstraße 14, 70469 Stuttgart, Germany

Correspondence

Prof. Dr. Ulf Teichgräber
Institut für Diagnostische und Interventionelle Radiologie,
Universitätsklinikum Jena, Am Klinikum 1, 07747 Jena,
Germany
Tel.: ++49/36 41/9 32 48 31
Fax: ++49/36 41/9 32 48 32
ulf.teichgraeber@med.uni-jena.de

ZUSAMMENFASSUNG

Ziel Bestimmung der Wirksamkeit der Schmerzbehandlung durch Blockade des Plexus hypogastricus superior (superior hypogastric plexus block; SHPB) verglichen mit einer Epiduralanästhesie (EDA) bei Embolisation der Uterusarterien (uterine artery embolization; UAE).

Material und Methoden In diese retrospektive, monozentrische, nicht randomisierte Studie wurden 79 Frauen mit symptomatischem Uterusmyom eingeschlossen, für die eine perkutane UAE geplant war. Die Schmerzkontrolle erfolgte entweder mit Unterstützung des SHPB oder der EDA. Ergebnisparameter zur Wirksamkeit war die Schmerzstärke auf einer Skala von 1 bis 10. Abgefragt wurde die Schmerzstärke während sowie 2 Stunden nach UAE und jeweils im Abstand von 6 Stunden bis 36 Stunden nach der UAE.

Ergebnisse Die Behandlungsgruppen unterschieden sich nicht signifikant in Hinblick auf Alter, Schmerzstärke bei vorangegangenen Menstruationen, Größe und Lage der Myome sowie Symptome. Frauen, bei denen ein SHPB vorgenommen wurde, hatten stärkere Schmerzen als diejenigen, die eine EDA erhielten (mittlere Schmerzstärke während der UAE: 3,3 vs. 1,5, $p < 0,001$; nach 2 Stunden: 4,4 vs. 2,8, $p = 0,012$; nach 6 Stunden: 4,4 vs. 2,6, $p = 0,021$). Die maximale Schmerzstärke betrug $5,8 \pm 2,9$ mit SHPB und $4,5 \pm 2,9$ mit EDA ($p = 0,086$). Patientinnen, mit Menorrhagien in der Vorgeschichte neigten zu stärkeren Schmerzen als andere (Regressionskoeffizient 2,5 [95 %-Konfidenzintervall $-0,3$ bis $5,3$], $p = 0,076$).

Schlussfolgerung Frauen, bei denen eine Embolisation der Uterusarterien durchgeführt wurde, empfanden während und nach dem Eingriff unter einem SHPB stärkere Schmerzen als mit EDA.

Kernaussagen:

- Die Schmerzkontrolle durch Blockade des Plexus hypogastricus superior war der Epiduralanästhesie unterlegen.
- Die Schmerzen erreichten 12 Stunden nach Embolisation ihren Höhepunkt.
- Die maximale Schmerzstärke war unabhängig von der Größe und Lage des Myoms.

ABSTRACT

Purpose To assess the effectiveness of pain management with superior hypogastric plexus block (SHPB) compared to epidural anesthesia (EDA) in women requiring uterine artery embolization (UAE).

Materials and Methods In this retrospective, single-center, non-randomized trial we included 79 women with symptomatic uterine fibroids who were scheduled for percutaneous, transcatheter UAE. According to their informed decision, the women were assigned to two different approaches of pain management including either SHPB or EDA. The effectiveness outcome measure was patient reported pain using a numeric rating scale ranging from 1 to 10. The pain score was assessed at UAE, 2 hours thereafter, and at subsequent intervals of 6 hours up to 36 hours after intervention.

Results Treatment groups did not differ significantly regarding age, pain score for regular menstrual cramps, uterine fibroid size, location, and symptoms of uterine fibroids. During UAE and up to 6 hours thereafter, women who received SHPB

experienced stronger pain than those who received EDA (mean pain score during UAE: 3.3 vs. 1.5, $p < 0.001$; at 2 hours: 4.4 vs. 2.8, $p = 0.012$; at 6 hours: 4.4 vs. 2.6, $p = 0.021$). The maximum pain level was 5.8 ± 2.9 with SHPB and 4.5 ± 2.9 with EDA ($p = 0.086$). Women with a history of severe menorrhagia tended to experience worse pain than those without (regression coefficient 2.5 [95% confidence interval -0.3 to 5.3], $p = 0.076$).

Conclusion Among women who underwent UAE, pain management including SHPB resulted in stronger pain during and after the procedure than pain treatment including EDA.

Key Points:

- Pain control with superior hypogastric plexus block was worse than epidural anesthesia.
- Peak of pain was at 12 hours after uterine artery embolization.
- Maximum pain was independent from uterine fibroid size or location.

Citation Format

- Malouhi A, Aschenbach R, Erbe A et al. Effectiveness of Superior Hypogastric Plexus Block for Pain Control Compared to Epidural Anesthesia in Women Requiring Uterine Artery Embolization for the Treatment of Uterine Fibroids – A Retrospective Evaluation. *Fortschr Röntgenstr* 2021; 193: 289–297

Introduction

Severe visceral pain from myometrial ischemia is a major concern in uterine artery embolization (UAE) for the treatment of symptomatic fibroids. UAE represents a viable alternative to surgical myectomy or hysterectomy. It reduces the risk of bleeding complications and facilitates early patient recovery [1, 2]. Embolic agents injected into the uterine arteries cut off blood flow to cause infarction and shrinkage of fibroids. However, ischemia occurs not only within fibroids but also temporarily in about 20% of the myometrial tissue. Subsequent reactive inflammation may be accompanied by fever and fatigue. The severity of pain increases immediately after UAE and is associated with the percentage and volume of the ischemic myometrium and volume of the applied embolic agent [3].

Epidural anesthesia (EDA) supplemented by opioids provides effective pain management. It allows for less opioid consumption and a reduction of related side effects such as nausea, vomiting, and inhibition of intestinal motility. However, the epidural catheter has to remain in for 48 hours, thereby delaying discharge. In contrast, superior hypogastric plexus block (SHPB) by means of retroperitoneal injection of local anesthetic is applied only at the time of UAE. It is known that SHPB prevents transmission of pelvic pain signals to the central nervous system. Previous studies showed reduced pain and morphine consumption with SHPB compared to placebo or sham treatment in women with gynecologic

cancer [4] and in those who underwent hysterectomy [5] or UAE [6]. Furthermore, a single-center, retrospective evaluation of UAE patients revealed lower peroral morphine-equivalent consumption with SHPB compared to EDA [7].

This study sought to retrospectively evaluate the effectiveness of SHPB compared to EDA for pain control in women who underwent UAE with special emphasis on the onset, strength, and duration of pain relief.

Materials and Methods

Study design and setting

Consecutive patients with symptomatic uterine fibroids who were scheduled for percutaneous transcatheter UAE were included in the retrospective, non-randomized, single-center study. The study complies with the Declaration of Helsinki. All patients provided written informed consent. UAE was conducted using hydrogel embolization microspheres sized 500 μm and 700 μm (Embozene Microspheres; Boston Scientific, Marlborough, MA, USA) with transfemoral access according to the hospital's standard of care using the flow-stop technique (i. e., embolization until there is no remaining flow within the artery). To prevent collateral supply, UAE was always conducted bilaterally, even in the case of predominately one-sided blood supply of the fibroid. Pain control included either SHPB or EDA according to the patient's preference

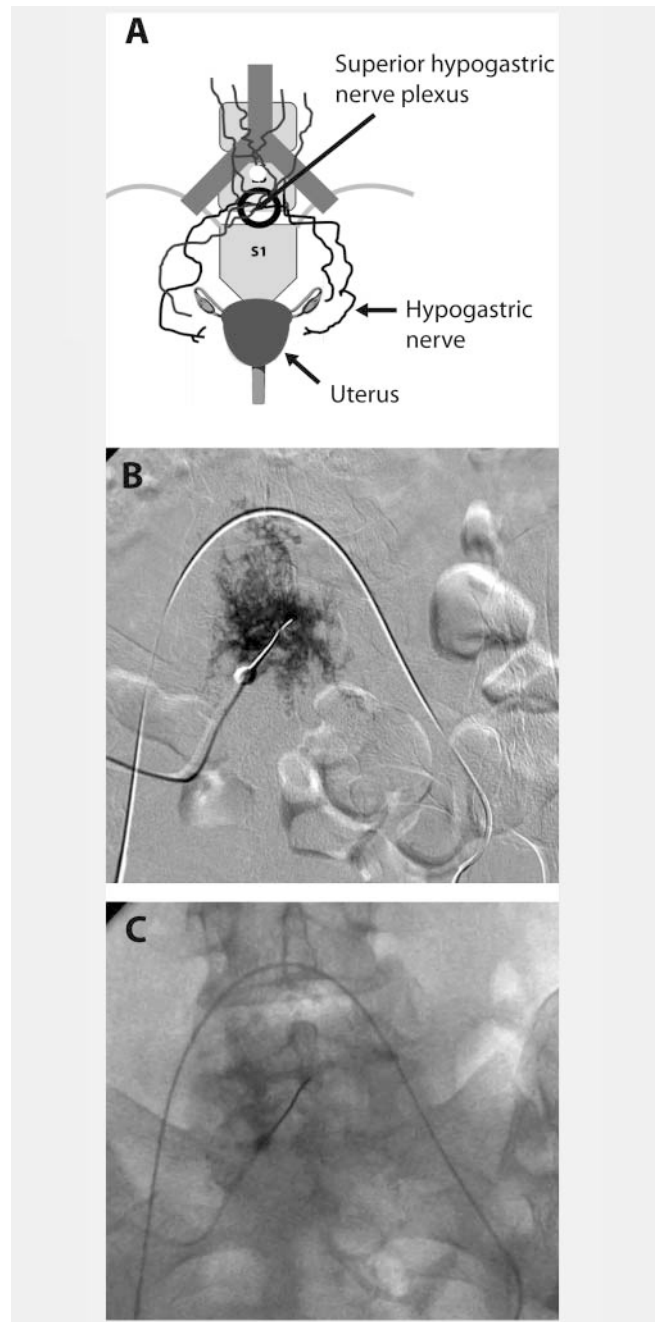
after receiving written and oral information on the benefits and risks of both procedures from the operator. Minor risks of SHPB include temporary hypoesthesia and bleeding, and rare major risks include peritonitis, bacteremia, convulsion, and cardiac arrest [5, 6]. The pain score was assessed at the time of UAE, 2 hours thereafter, and at subsequent intervals of 6 hours up to 36 hours after UAE.

Pain management in uterine artery embolization

The superior hypogastric nerve plexus mainly contains sympathetic efferents and visceral sensory afferents. Its fibers transmit the majority of visceral pelvic pain signals to the spinal cord [8, 9]. The plexus is situated retroperitoneally in front of the spine, at the level between the distal third of the fifth vertebra (L5) and the sacral promontory (S1) with a slight shift to the left. SHPB was conducted by experienced interventional radiologists following previous descriptions [10, 11]. Patients were placed supine on the sliding table of the angiography unit. Prior to UAE but after catheterization of the left iliac artery with a guiding catheter in a crossover maneuver from the right groin, a 15 cm, 22G-Chiba needle was inserted percutaneously midline through the abdominal wall just below the umbilicus, targeting the lower third of the fifth lumbar vertebra (L5). Under fluoroscopic guidance, the needle was advanced to the spinal column distally to the aortic bifurcation until bone contact was established. The guiding catheter serves as a position marker of the aortic bifurcation under fluoroscopy. Aspiration and a symmetric spread of 1–2 ml injected contrast medium had to confirm the extravascular and midline position of the needle tip. In the case of a suboptimal position, fluoroscopy-guided readjustment was necessary. Subsequently, 20 ml of the local anesthetic drug ropivacaine 0.5% was injected with intermittent aspiration (► Fig. 1a–c). Ropivacaine is a long-acting sodium-channel blocker that slows the propagation of nerve impulses. Its efficacy depends on diameter and myelination and thus has selective action on small, less myelinated pain-transmitting nerves [12].

Patients who underwent SHPB, additionally received pre- and postprocedural medication for pain control, adjuvant analgesics, and medication against drug side effects. Concomitant pain therapy included long-acting opioids (oxycodone), short-acting opioids (piritramide and morphine sulfate), and a non-steroidal anti-inflammatory drug (ibuprofen). Adjuvant analgesics included antipyretic and spasmolytic drugs (metamizole, hyoscine butylbromide), a sedative, anxiolytic, muscle relaxant drug (midazolam), and prednisolone. Moreover, patients received naloxone to prevent obstipation and granisetron to prevent nausea and vomiting (► Table 1). Discontinuation of medication was scheduled at 3 days for metamizole, at 7 days for oxycodone/naloxone, and at 8 days for ibuprofen. If pain intensity was <4 out of 10, discontinuation was permitted earlier.

For epidural anesthesia conducted by experienced anesthesiologists, a needle was inserted between the eleventh and twelfth thoracic vertebra to place a catheter into the epidural space at least 30 minutes before UAE. After ensuring epidural position of the catheter, local anesthetic (ropivacaine) and opioid (sufentanil) were slowly injected to achieve analgesia in the area



► **Fig. 1** Anatomic representation of the target region for superior hypogastric plexus block **A**, anterior-posterior fluoroscopy view that shows even distribution of contrast medium that confirms retroperitoneal, extravascular, and extra-intestine location of the needle tip **B**, and needle placement central at the level from the lower third of the fifth lumbar vertebra (L5) to the proximal sacrum (S1), distal to the aortic bifurcation and close to the anterior aspect of the spinal column **C**.

► **Abb. 1** Anatomische Darstellung des Zielgebietes für die Plexusblockade **A**, anterior-posterior Fluoroskopie, die eine gleichmäßige Verteilung des Kontrastmittels zur Bestätigung der retroperitonealen, extravaskulären und extra intestinalen Lage der Nadelspitze zeigt **B**, sowie Nadelposition zentral auf einer Höhe zwischen unteren Drittel des 5. Lendenwirbels (L5) und proximalem Kreuzbein (S1), distal der Aortenbifurkation, nahe der Vorderseite der Wirbelsäule **C**.

► **Table 1** Medication in patients who underwent SHPB.► **Tab. 1** Medikation der Patientinnen, die ein Blockade des Plexus hypogastricus superior erhielten.

	1 st day		2 nd day		3 rd day to discharge	
time	medication	dosage	medication	dosage	medication	dosage
morning	Oxycodone/ Naloxone*	10/5 mg p. o.	Oxycodone/ Naloxone*	10/5 mg p. o.	Oxycodone/Naloxone*	10/5 mg p. o.
	Ibuprofen**	400 mg p. o.	Ibuprofen**	400 mg p. o.	Ibuprofen**	400 mg p. o.
			Metamizole	1 g p. o.		
	immediately prior to UAE				PRN	
	SHPB: Ropivacaine	40 mg (20 ml, 0.5%)			Morphine sulfate	10 mg p. o.
	Piritramide	3 mg/10 min i. v. (optional: PCA infusion pump)			Hyoscine butylbromide	20 mg (max. 4/24 h)
	Metamizole	2 g i. v.			Granisetron	1 mg
	Granisetron	2 mg i. v.		or Metoclopramide	10 mg p. o.	
	Midazolam	3–7.5 mg i. v.			or Dimenhydrinate	62 mg (max. 3/24 h)
	post UAE					
	Granisetron	1 mg i. v.				
	Prednisolone	100 mg i. v.				
	PRN					
	Piritramide	3 mg/10 min i.v				
Hyoscine butylbromide	20–40 mg i. v.					
afternoon	Metamizole	1 g p. o.	Ibuprofen	400 mg p. o.		
			Metamizole	1 g p. o.		
evening	Oxycodone/ Naloxone*	10/5 mg p. o.	Oxycodone/ Naloxone*	10/5 mg p. o.	Oxycodone/Naloxone*	10/5 mg p. o.
	Ibuprofen**	400 mg p. o.	Ibuprofen**	400 mg p. o.	Ibuprofen**	400 mg p. o.
	Metamizole	1 g p. o.			PRN see above	
night			Ibuprofen**	400 mg p. o.	PRN see above	
			Metamizole	1 g p. o.		

PCA = patient-controlled analgesia; PRN = pro re nata (when required); SHPB = superior hypogastric plexus block; UAE = uterine arterial embolization. PCA = Patientenkontrollierte Analgesie; PRN = pro re nata (bei Bedarf); SHPB = Blockade des Plexus hypogastricus superior; UAE = Embolisation der Uterusarterien.

* TARGIN 10/5 mg modified release tablets.

TARGIN 10/5 mg, Tabletten mit modifizierter Wirkstofffreisetzung.

** Contraindicated in patients with a medical history of peptic ulcer.

Kontraindikation bei Patienten mit Magengeschwüren in der Vorgeschichte.

between the tenth thoracic and the second lumbar vertebra. Subsequently, after 20 minutes of off-time, medication was continuously infused at a rate of 4 ml/h. Additionally, up to three bolus injections of 3 ml each may have been administered per hour. The catheter was removed 48 hours after UAE. Concomitantly, patients received short-acting opioids (piritramide) and paracetamol when required (► **Table 2**).

Study outcome measurement and definitions

The effectiveness outcome was patient-reported pain using a numeric rating scale ranged from 1 (no pain) to 10 (worst imaginable pain). Pain assessment was conducted immediately after the intervention (pain during UAE), and at 2, 6, 12, 18, 24, 30, and 36 hours after UAE. Response to pain management was defined

► **Table 2** Medication in patients who underwent EDA.

► **Tab. 2** Medikation der Patientinnen, die eine Epiduralanästhesie erhielten.

time	medication	dosage
preparation for UAE	Bupivacaine 0.25 % isobaric	3.0 ml epidural (to detect accidental intravascular injection)
immediately prior and during UAE	Ropivacaine 0.15 % and 10 µg sufentanil	8–10 ml epidural
	infusion pump containing 100 ml ropivacaine 0.15 % and 30 µg sufentanil	epidural infusion pump: <ul style="list-style-type: none"> ▪ continuous rate: 4 ml/h, ▪ bolus: 3 ml (max. 3/h)
	Piritramide	2 mg i. v. (optional: PCA infusion pump)
after UAE	Piritramide	1 mg i. v. (optional: PCA infusion pump)
	Paracetamol	1 g p. o. (3/24 h)
48 hours after UAE	Epidural catheter removed	

EDA = epidural anesthesia; PCA, patient-controlled analgesia; UAE = uterine arterial embolization.
 EDA = Epiduralanästhesie; PCA = Patientenkontrollierte Analgesie; UAE = Embolisation der Uterusarterien.

as pain score < 4 out of 10. Total uterine volume was measured by magnetic resonance tomography and total fibroid volume was visually estimated as a percentage of the uterine volume (four categories: 0–25 %, 25–50 %, 50–75 %, 75–100 %). The maximum uterine fibroid size was then calculated from the upper limit of the estimated percentage of the total fibroid volume.

Statistical analysis

Continuous variables and not normally distributed interval scale data are reported as mean ± standard deviation (SD) to provide precision and are depicted as median and interquartile range (IQR) to provide robustness. Data were compared using the Mann-Whitney U test. Categorical variables are reported as counts and percentages and were compared using Fisher's exact test. Linear regression and ANOVA were run to assess the association of selected variables with maximum pain in the period from UAE up to 36 hours thereafter. A two-sided value of $p < 0.05$ indicated statistical significance. Analysis was performed using XLSTAT (Version 2015.6.01.24 026, Addinsoft, Paris, France).

Results

Study population and treatment

From March 2012 to April 2017, 79 women who underwent UAE and pain control with SHPB (41 patients, 51.9 %) or EDA (38 patients, 48.1 %) were enrolled at a single German center. Women in the SHPB and EDA groups were 46.5 ± 4.7 and 44.8 ± 8.5 years old, respectively ($p = 0.497$). The pain score for regular menstrual cramps was 4.1 ± 2.8 in the SHPB group and 3.8 ± 2.7 in the EDA group ($p = 0.700$). The maximum uterine fibroid size, fibroid location, and uterine fibroid symptoms including menorrhagia, feeling of abdominal tension or pressure, and pollakiuria were well balanced across groups (► Fig. 2a–c).

Effectiveness outcome

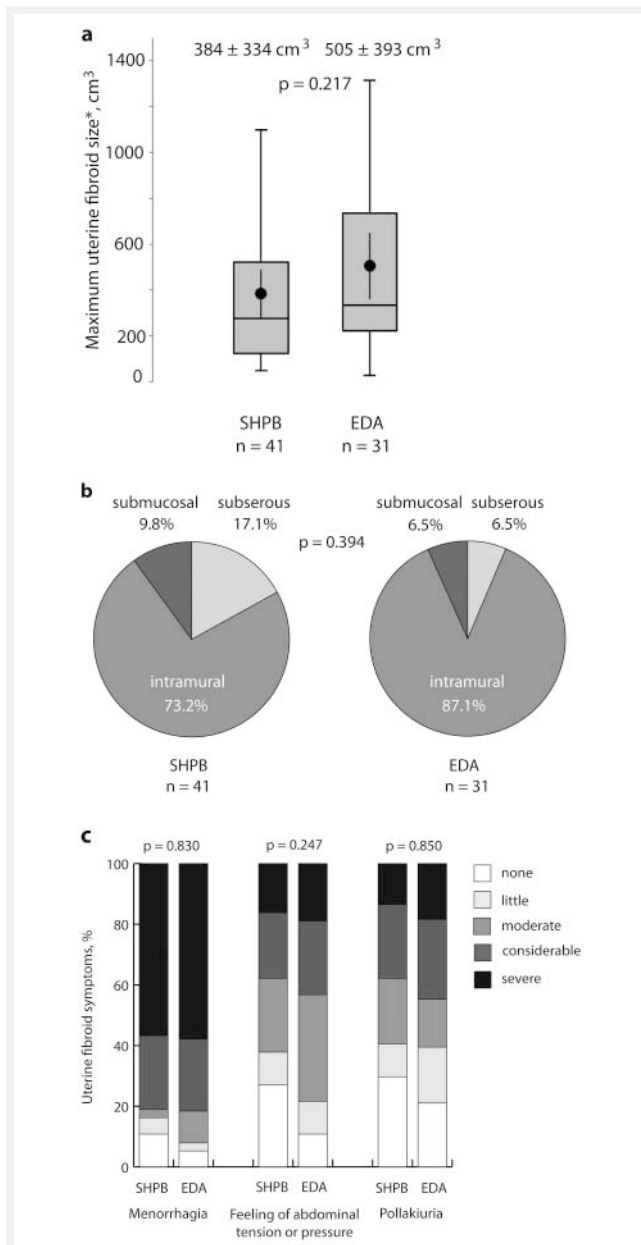
Women who underwent SHPB reported significantly greater pain intensity during UAE than those who received EDA (mean pain score of 3.3 vs. 1.5, $p < 0.001$). Even at 2 and 6 hours, the pain was worse with SHPB compared to EDA (mean pain score of 4.4 vs. 2.8, $p = 0.012$ and 4.2 vs. 2.6, $p = 0.021$, respectively). In both treatment groups, the pain peaked 12 hours after UAE and decreased from the 18th hour onwards. The difference between groups decreased with pain relief and disappeared successively (► Fig. 3).

Patient-reported maximum pain within 36 hours was 5.8 ± 2.9 and 4.5 ± 2.9 in the SHPB group and the EDA group, respectively ($p = 0.086$) (► Fig. 4). SHPB increased the maximum pain level by 1.3 (95 % CI: –0.2 to 2.8) on average. There was no evidence of association between maximum pain and uterine fibroid size or location. Women with a history of severe menorrhagia tended to experience a higher maximum pain level (regression coefficient 2.5 [95 % confidence interval –0.3 to 5.3], $p = 0.076$) (► Fig. 5).

During UAE and 2 hours thereafter, significantly more women responded to EDA than to SHPB (pain score < 4). At 12 hours, in both groups the lowest percentage of patients responded to pain control (SHPB 41.9 %, EDA 62.5 %, $p = 0.176$). With EDA, the incidence of response remains largely stable within the following 12 hours before increasing slightly from 30 hours after UAE, while with SHPB the response to pain control increases considerably already from 18 hours after UAE (► Fig. 6a).

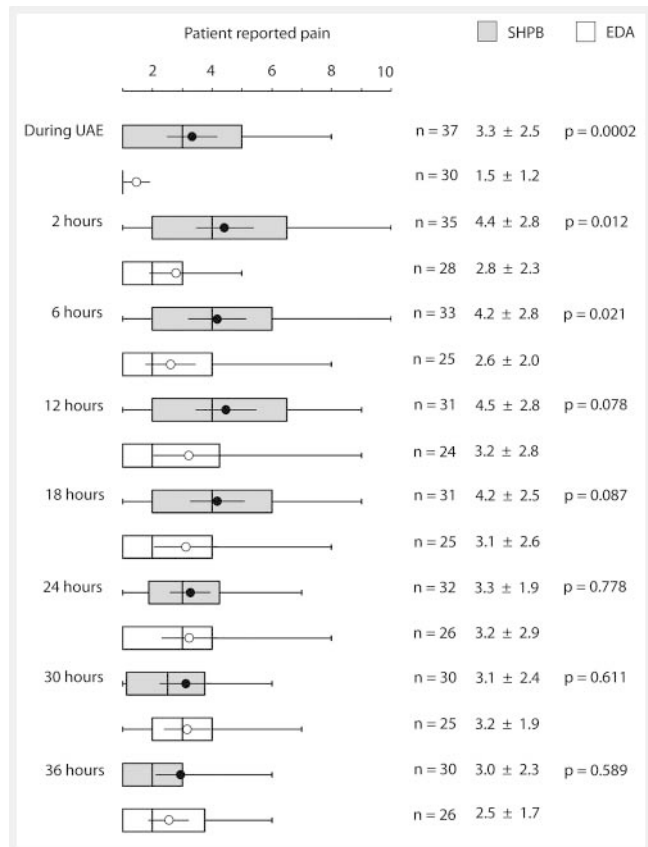
During the procedure, freedom from pain was significantly more frequently achieved with EDA (24 of 30 patients, 80.0 %) than with SHPB (13 of 37 patients, 35.1 %), $p < 0.001$. After 2 hours from UAE, the difference decreased considerably (EDA 39.3 % versus SHPB 17.1 %; $p = 0.085$). Thereafter, in both groups, the proportions of patients without pain remained largely stable over the following 12 hours.

Between 24 and 30 hours after UAE, there was a slight decline in freedom from pain with EDA, whereas with SHPB, freedom from pain steadily increased up to 36 hours (► Fig. 6b).



► **Fig. 2** Maximum size of uterine fibroid **a**, uterine fibroid location **b**, and medical history of uterine fibroid symptoms **c**. EDA = epidural anesthesia; SHPB = superior hypogastric plexus block. *Maximum size of uterine fibroid was determined from total uterine volume and the upper limit of the proportional part of the fibroid out of the four categories 0–25%, 25–50%, 50–75%, and 75–100%. Box plots indicate median and interquartile range. Whiskers end with the lowest and highest data point within 1.5 × interquartile range. Dots represent means with their corresponding 95% confidence interval.

► **Abb. 2** Maximale Größe des Myoms **a**, Lage des Myoms **b** und Vorgeschichte zur Symptomatik **c**. EDA = Epiduralanästhesie; SHPB = Blockade des Plexus hypogastricus superior. *Die maximale Größe des Myoms wurde aus dem Gesamtvolumen des Uterus und dem prozentualen Volumenanteil des Myoms aus den vier Kategorien 0–25%, 25–50%, 50–75%, und 75–100% ermittelt. Die Box-Plots zeigen Median und Interquartilabstand an. Die „Whisker“ enden mit dem höchsten und niedrigsten Datenpunkt innerhalb des 1,5-fachen Interquartilabstandes. Die Punkte repräsentieren die Mittelwerte mit ihrem 95%igem Konfidenzintervall.

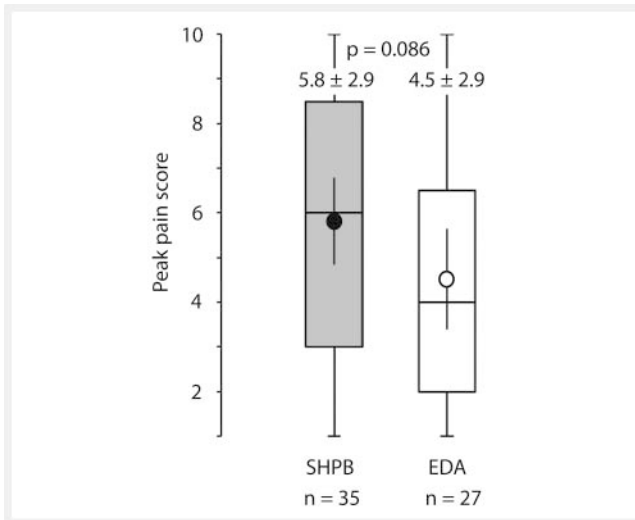


► **Fig. 3** Patient reported pain on a graded scale from 1 (no pain) to 10 (worst pain imaginable) during uterine arterial embolization (UAE) and 36 hours following UAE. EDA = epidural anesthesia; SHPB = superior hypogastric plexus block. Box plots indicate median and interquartile range. Whiskers end with the lowest and highest data point within 1.5 × interquartile range. Dots and circles represent means with their corresponding 95% confidence interval.

► **Abb. 3** Schmerzstärke auf einer Skala von 1 (kein Schmerz) bis 10 (schwerster vorstellbarer Schmerz) während der Embolisation (UAE) und bis zu 36 Stunden danach. EDA = Epiduralanästhesie; SHPB = Blockade des Plexus hypogastricus superior. Die Box-Plots zeigen Median und Interquartilabstand an. Die „Whisker“ enden mit dem höchsten und niedrigsten Datenpunkt innerhalb des 1,5-fachen Interquartilabstandes. Punkte und Kreise repräsentieren die Mittelwerte mit ihrem 95%igem Konfidenzintervall.

Discussion

UAE is associated with significant postprocedural pain resulting from ischemia. EDA is known to effectively control pain but is associated with delayed discharge. Therefore, we retrospectively evaluated the effectiveness of SHPB in comparison to EDA. Our study revealed significantly stronger pain with SHPB compared to EDA during UAE and up to 6 hours thereafter. The maximum pain within 36 hours from UAE tended to be worse with SHPB. In both groups, the pain peaked at 12 hours, which is an argument against early discharge. Thereafter, pain intensity decreased slightly faster after SHPB than after EDA.



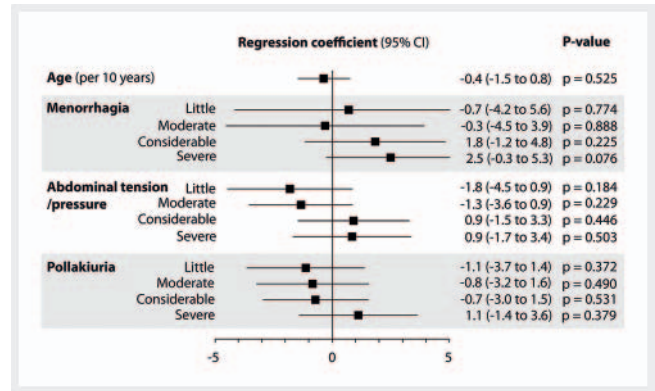
► **Fig. 4** Patient reported maximum pain during UAE and within 36 hours thereafter. EDA = epidural anesthesia; SHPB = superior hypogastric plexus block. Box plots indicate median and interquartile range. Whiskers end with the lowest and highest data point within 1.5 × interquartile range. Dot and circle represent means with their corresponding 95 % confidence interval.

► **Abb. 4** Maximale Schmerzstärke während der Embolisation (UAE) und bis zu 36 Stunden danach. Die Box-Plots zeigen Median und Interquartilabstand an. EDA = Epiduralanästhesie; SHPB = Blockade des Plexus hypogastricus superior. Die „Whisker“ enden mit dem höchsten und niedrigsten Datenpunkt innerhalb des 1,5-fachen Interquartilabstandes. Punkte und Kreise repräsentieren die Mittelwerte mit ihrem 95 %igem Konfidenzintervall.

Pain relief

Taking into account the 10-point pain rating scale used in this study and the 11-point rating scale of previous SHPB studies, the mean pain scores with SHPB were comparable to previously described results [10, 13]. In addition, this study revealed significantly worse pain with SHPB compared to EDA, even with intensive concomitant pain medication. However, concomitant pain management might be rated in a different way. Konstantatos et al. did not find pre-procedure oxycodone to reduce pain within 6 hours after UAE compared to morphine PCA alone [14], whereas Freire et al. reported improved analgesia with pre- and post-procedure oxycodone compared to standard anesthetic alone [15].

A previous retrospective study reported reduced consumption of peroral opiates associated with less nausea after SHPB compared to EDA. However, the study lacks information on the EDA technique conducted in the historical control and does not provide results regarding actual pain relief [7]. Another small-scale, randomized trial on UAE reported a significantly reduced morphine-equivalent dose needed with SHPB compared to sham treatment. However, only immediately after UAE, SHBP patients experienced less pain than sham patients. There was no longer any difference upon arrival in the post-anesthesia care unit. Uneven spread of contrast medium was associated with lower efficacy. Based on this, the authors argued that a lack of response to SHPB in some patients might have been due to limited operator experience [6].



► **Fig. 5** Association of peak pain score with selected baseline variables determined by regression analysis.

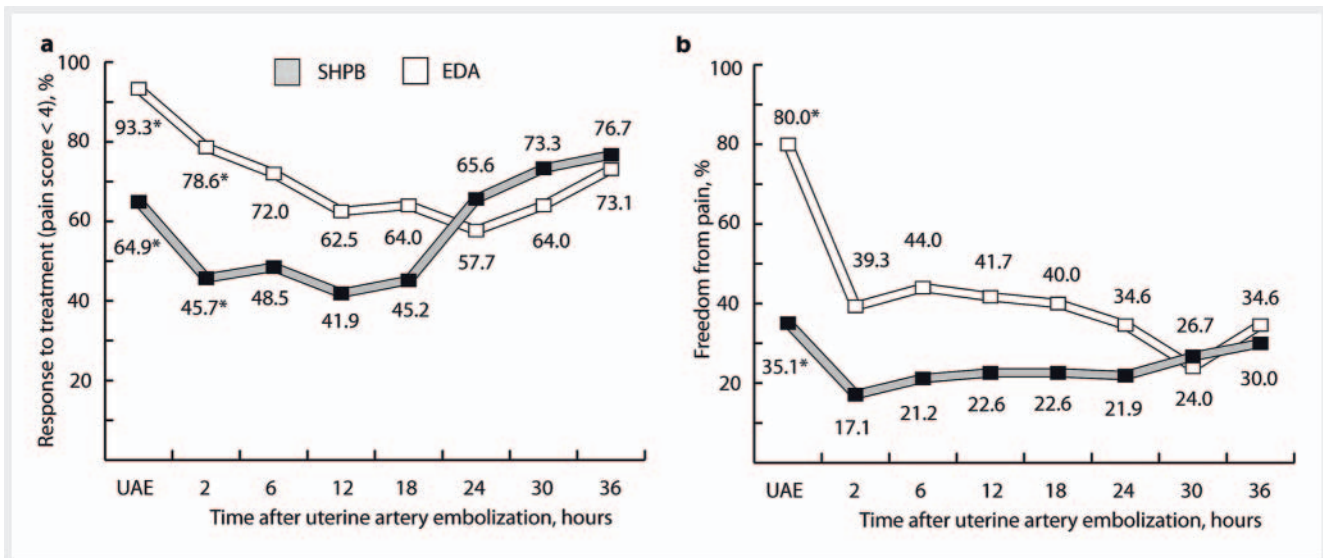
► **Abb. 5** Assoziation von maximalem Schmerz mit ausgewählten Basisvariablen, bestimmt durch Regressionsanalyse.

Blinded application

Kaufman et al. compared 24-hour pain control with intraperitoneal nebulization of 100 mg ropivacaine versus placebo in women, who underwent gynecologic surgery. They found no improvement in pain scores or morphine consumption [16]. Another study that investigated pain management after hysterectomy found reduced post-surgery pain and morphine-equivalent consumption after SHPB applied through the open abdomen. 2 hours after SHPB, the proportion of women with pain score <4 was significantly larger than after placebo [5]. It might be inferred that the accuracy of anesthetic application only supported by fluoroscopy may not be assured with sufficient reliability. In addition, unintended distribution of injectate cannot be ruled out even in the retroperitoneal space. Impaired strength and duration of the treatment effect may result. Binkert et al. reported on a single case of unintentional anesthesia of the lumbar nerve [7]. Even with significant experience on the part of the interventionist, the largely blind application of the anesthetic may not take adequate account of the variance in anatomical conditions between individuals, particularly in the presence of uterine fibroids. Moreover, the relative position of the aortic bifurcation with respect to the lumbar vertebral spine is known to be variable resulting in a cephalad or unilateral spread of the injectate [17, 18].

Time course of pain

The progress of pain in this study corresponded to previous findings on post-procedure pain after UAE with patient-controlled analgesia. Authors reported an increase in pain within the first 2 hours and a plateau for several hours followed by a rapid decrease of pain. They observed a parallel course of the myometrial tissue pH-drop from ischemia [19]. Supporting the results of this study, women who underwent UAE and received SHPB reported the most severe pain in the first night after the procedure [13]. In this study, pain relief with SHPB was considerably worse compared to EDA. The lower slope immediately after intervention and the more rapid decline of pain were due to the higher pain



► **Fig. 6** Percentage of patients who responded to pain therapy (pain score < 4) **a**, and patients without pain **b**. * $p < 0.05$. EDA = epidural analgesia; SHPB = superior hypogastric plexus block.

► **Abb. 6** Prozentualer Anteil der Patientinnen, die auf die Schmerzbehandlung ansprachen (Schmerzstärke < 4) **a** und schmerzfreier Patientinnen **b**. * $p < 0,05$.

level with SHPB during the procedure and the following 18 hours. Increased consumption of concomitant analgesics in the SHPB group might have contributed to the comparatively fast pain relief.

Risk factors

An earlier study evaluated predictive factors for the severity of post-procedure pain. In accordance with our study and Ruuskanen et al. [3], neither fibroid nor uterus size was associated with pain intensity [20]. However, Ruuskanen et al. found the severity of myometrial ischemia and the volume of embolic agent to be predictive for severe pain. This study showed a tendency toward increased pain in women with a history of severe menorrhagia. Therefore, this issue should be followed up in future research to improve patient selection. Furthermore, genetic variation of morphine receptors might have contributed to the variance in response to treatment [21]. However, patient-reported pain of regular menstrual cramps suggests similar subjective pain sensitivity across groups in our study. Finally, pain is a subjective experience, and thus, pain intensity also depends on the individual patient's perception.

Limitations

This study was not randomized. Thus, different baseline characteristics may have influenced outcomes. The lack of blinding might have affected the subjective outcome of pain. Furthermore, the exact use and dosage of concomitant pain medication and attendant symptoms including nausea and vomiting were not recorded. Medication was supposed to enhance pain relief from SHPB and EDA, and thus, most definitely affected pain intensity [10]. A relatively late removal of the epidural catheter after

48 hours may have resulted in prolonged discomfort, delayed discharge, and increased costs. Morphine-equivalent consumption could have been an additional surrogate parameter of pain intensity and duration. However, prescribed pain management in both groups was precisely defined, according to the hospital's standard of care. Finally, no information was available on complications and hospital stay.

Conclusion

Women who underwent UAE and received pain management including SHPB experienced stronger pain during and after the procedure than those who received EDA. Therefore, this study does not support to use of SHPB over EDA for pain control in women who require UAE. Severe pain, particularly during the first night after the procedure, does not permit early discharge.

CLINICAL RELEVANCE

- Pain control during and after uterine artery embolization was worse with superior hypogastric plexus block than with epidural anesthesia
- In both treatment groups, the pain reached its peak at 12 hours after uterine artery embolization
- The maximum pain intensity was not associated with uterine fibroid size or location.

Conflict of Interest

The authors declare that they have no conflict of interest.

References

- [1] Edwards RD, Moss JG, Lumsden MA et al. Uterine-artery embolization versus surgery for symptomatic uterine fibroids. *N Engl J Med* 2007; 356: 360–370
- [2] de Bruijn AM, Ankum WM, Reekers JA et al. Uterine artery embolization vs hysterectomy in the treatment of symptomatic uterine fibroids: 10-year outcomes from the randomized EMMY trial. *Am J Obstet Gynecol* 2016; 215: 745 e741–745 e712
- [3] Ruuskanen A, Sipola P, Hippelainen M et al. Pain after uterine fibroid embolisation is associated with the severity of myometrial ischaemia on magnetic resonance imaging. *European radiology* 2009; 19: 2977–2985
- [4] Mishra S, Bhatnagar S, Rana SP et al. Efficacy of the anterior ultrasound-guided superior hypogastric plexus neurolysis in pelvic cancer pain in advanced gynecological cancer patients. *Pain medicine (Malden, Mass)* 2013; 14: 837–842
- [5] Rapp H, Ledin Eriksson S, Smith P. Superior hypogastric plexus block as a new method of pain relief after abdominal hysterectomy: double-blind, randomised clinical trial of efficacy. *BJOG: an international journal of obstetrics and gynaecology* 2017; 124: 270–276
- [6] Yoon J, Valenti D, Muchantef K et al. Superior Hypogastric Nerve Block as Post-Uterine Artery Embolization Analgesia: A Randomized and Double-Blind Clinical Trial. *Radiology* 2018; 289: 248–254
- [7] Binkert CA, Hirzel FC, Gutzeit A et al. Superior Hypogastric Nerve Block to Reduce Pain After Uterine Artery Embolization: Advanced Technique and Comparison to Epidural Anesthesia. *Cardiovascular and interventional radiology* 2015; 38: 1157–1161
- [8] Bosscher H. Blockade of the superior hypogastric plexus block for visceral pelvic pain. *Pain practice: the official journal of World Institute of Pain* 2001; 1: 162–170
- [9] Gunduz OH, Kenis-Coskun O. Ganglion blocks as a treatment of pain: current perspectives. *Journal of pain research* 2017; 10: 2815–2826
- [10] Rasuli P, Jolly EE, Hammond I et al. Superior hypogastric nerve block for pain control in outpatient uterine artery embolization. *Journal of vascular and interventional radiology: JVIR* 2004; 15: 1423–1429
- [11] Spencer EB, Stratil P, Mizones H. Clinical and periprocedural pain management for uterine artery embolization. *Seminars in interventional radiology* 2013; 30: 354–363
- [12] Kuthiala G, Chaudhary G. Ropivacaine: A review of its pharmacology and clinical use. *Indian journal of anaesthesia* 2011; 55: 104–110
- [13] Rasuli P, Sabri A, Hammond I et al. Outpatient uterine artery embolization for symptomatic fibroids: short- and long-term single institution-based outcomes. *Journal of obstetrics and gynaecology Canada: JOGC = Journal d'obstetrique et gynecologie du Canada: JOGC* 2013; 35: 156–163
- [14] Konstantatos AH, Kavounodias H, Stegeman JR et al. A randomized, double-blind, placebo-controlled study of preemptive oral oxycodone with morphine patient-controlled anesthesia for postoperative pain management in patients undergoing uterine artery embolization for symptomatic uterine fibroids. *Cardiovascular and interventional radiology* 2014; 37: 1191–1197
- [15] Freire GM, Cavalcante RN, Motta-Leal-Filho JM et al. Controlled-release oxycodone improves pain management after uterine artery embolisation for symptomatic fibroids. *Clinical radiology* 2017; 72: 428 e421–428 e425
- [16] Kaufman Y, Hirsch I, Ostrovsky L et al. Pain relief by continuous intraperitoneal nebulization of ropivacaine during gynecologic laparoscopic surgery – a randomized study and review of the literature. *Journal of minimally invasive gynecology* 2008; 15: 554–558
- [17] Pirro N, Ciampi D, Champsaur P et al. The anatomical relationship of the ilioacava junction to the lumbosacral spine and the aortic bifurcation. *Surgical and radiologic anatomy: SRA* 2005; 27: 137–141
- [18] Gofeld M, Lee CW. Ultrasound-Guided Superior Hypogastric Plexus Block: A Cadaveric Feasibility Study with Fluoroscopic Confirmation. *Pain practice: the official journal of World Institute of Pain* 2017; 17: 192–196
- [19] Worthington-Kirsch RL, Koller NE. Time course of pain after uterine artery embolization for fibroid disease. *Medscape women's health* 2002; 7: 4
- [20] Roth AR, Spies JB, Walsh SM et al. Pain after uterine artery embolization for leiomyomata: can its severity be predicted and does severity predict outcome? *Journal of vascular and interventional radiology: JVIR* 2000; 11: 1047–1052
- [21] Chou WY, Wang CH, Liu PH et al. Human opioid receptor A118G polymorphism affects intravenous patient-controlled analgesia morphine consumption after total abdominal hysterectomy. *Anesthesiology* 2006; 105: 334–337