Endoscopic ultrasound-guided choledochoduodenostomy without fistula dilation using a novel fully covered metallic stent with a 5.9-Fr ultra-thin delivery system

Endoscopic ultrasonography-guided choledochoduodenostomy (EUS-CDS) is a potential procedure for primary drainage in unresectable malignant distal biliary obstruction and can replace endoscopic retrograde cholangiopancreatography. However, adverse events following EUS-CDS are occasionally reported, the most common being bile leak due to fistula dilation [1, 2]. The safety of EUS-CDS without fistula dilation using two types of thin, fully covered self-expandable metallic stents (FCSEMSs) has been previously reported [3 – 5]. Here we report a case in which EUS-CDS without fistula dilation was successfully performed using a novel FCSEMS with a 5.9-Fr delivery system (Hanarostent Benefit; M.I.Tech, Seoul, Korea) (▶ **Fig. 1**).

A 62-year-old man who had received chemotherapy for unresectable pancreatic body cancer developed a distal biliary obstruction. Computed tomography revealed a 25-mm mass on the pancreatic body and a dilated common hepatic duct (CHD) (▶ **Fig. 2 a**). We performed EUS-CDS for primary drainage.

The dilated CHD was localized using a forward-viewing echoendoscope (TGF-UC260J; Olympus Medical Systems, Tokyo, Japan) from the duodenal bulb (▶ **Fig. 2 b**). First, the CHD was punctured with a 19-gauge needle (EZ Shot 3 Plus; Olympus Medical Systems). Cholangiography revealed a dilated CHD with distal obstruction. Second, a 0.025-inch guidewire (M-Through; ASAHI INTECC Corp., Tokyo, Japan) was inserted into the B4 branch. Fistula dilation was avoided, and the novel FCSEMS (8 mm × 6 cm) was passed through the duodenum and CHD wall smoothly. Finally, the stent was placed in the CHD from the duodenal bulb (▶ **Fig. 3**, ▶ **Fig. 4**; ▶ **Video 1**).

No adverse events occurred during or after the procedure.



▶ **Fig. 1** Novel fully covered self-expandable metal stent with an ultra-thin delivery system. **a** The outer sheath of the delivery catheter is size 5.9 Fr. **b** The expanded stent with a braiding design.

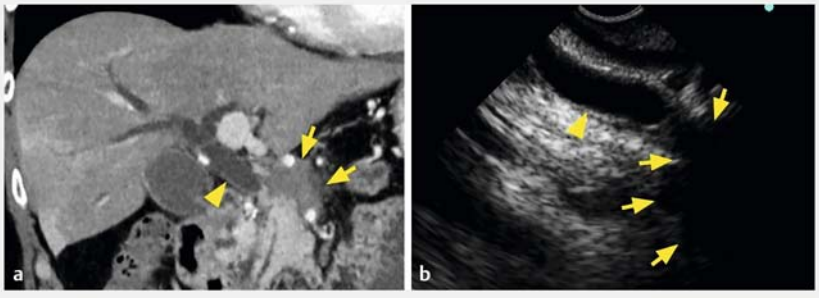

▶ **Fig. 2** Image findings before the procedure. **a** Coronal computed tomographic image revealing a hypovascular mass of the pancreatic body (arrows) and dilated common hepatic duct (CHD) (arrowhead). **b** Endoscopic ultrasonography image indicating a hypoechoic mass of the pancreatic body (arrows) and dilated CHD (arrowhead).

In previous reports, EUS-CDS without fistula dilation was performed using the FCSEMSs with a 7-Fr or 7.5-Fr delivery system, with 31.6 % – 100 % technical success rate [3 – 5]. This is the first report discussing EUS-CDS without fistula dilation using a FCSEMS with a 5.9-Fr delivery system, which is the thinnest ever commercially available delivery system and is capable of simpler and safer EUS-CDS procedures.

Endoscopy_UCTN_Code_TTT_1AS_2AD

Acknowledgements

This work was supported in part by The National Cancer Center Research and Development Fund (31-A-13).

Competing interests

The authors declare that they have no conflict of interest.

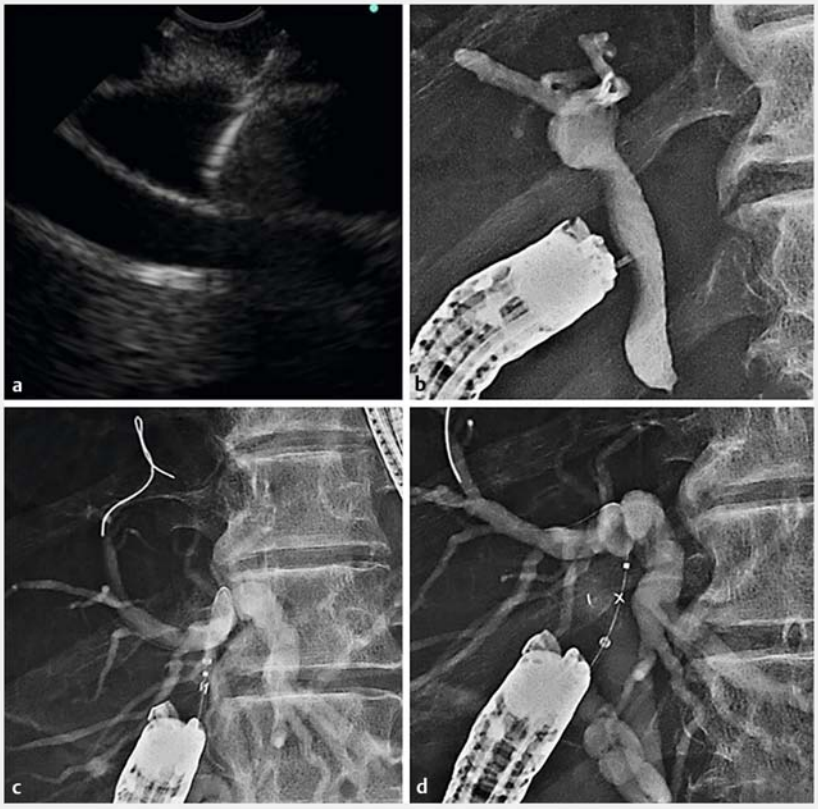

▶ **Fig. 3** Endoscopic ultrasonography-guided choledochoduodenostomy without fistula dilation. **a** The common hepatic duct (CHD) was punctured with a 19-gauge needle. **b** Cholangiography revealed a dilated CHD with a distal obstruction. **c** A 0.025-inch guidewire was inserted into the B4 branch, and the fully covered self-expandable metal stent (FCSEMS) was inserted into the CHD without fistula dilation. **d** The FCSEMS was deployed into the CHD.

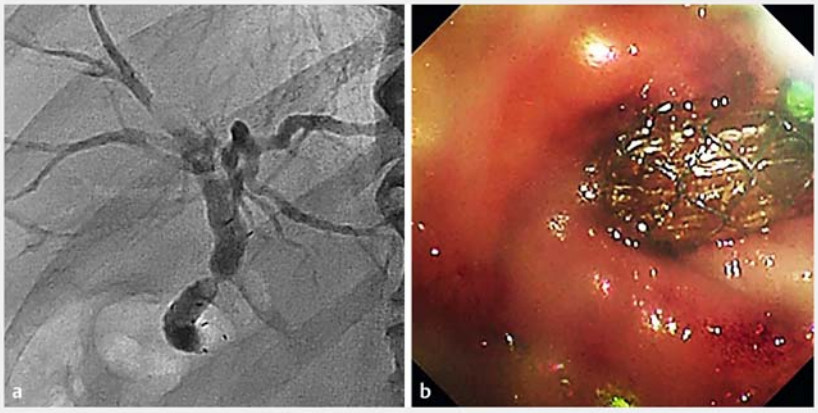

▶ **Fig. 4** Image findings after the procedure. **a** Fluoroscopic image. **b** Endoscopic image.

The authors

Takehiko Koga[1], Susumu Hijioka[1], Yuya Hisada[1], Yuta Maruki[1], Yoshikuni Nagashio[1], Takuji Okusaka[1], Yutaka Saito[2]

1 Department of Hepatobiliary and Pancreatic Oncology, National Cancer Center Hospital, Tokyo, Japan

2 Department of Endoscopy, Gastrointestinal Endoscopy Division, National Cancer Center Hospital, Tokyo, Japan

Corresponding author

Susumu Hijioka
Department of Hepatobiliary and Pancreatic Oncology, National Cancer Center Hospital, 5-1-1 Tsukiji, Chuo-ku, Tokyo 104-0045, Japan
Fax: +81-3-3542-3815
shijioka@ncc.go.jp

References

[1] Kawakubo K, Isayama H, Kato H et al. Multicenter retrospective study of endoscopic ultrasound-guided biliary drainage for malignant biliary obstruction in Japan. J Hepatobiliary Pancreat Sci 2014; 21: 328–334

[2] Wang K, Zhu J, Xing L et al. Assessment of efficacy and safety of EUS-guided biliary drainage: a systematic review. Gastrointest Endosc 2016; 83: 1218–1227

[3] Park DH, Lee TH, Paik WH et al. Feasibility and safety of a novel dedicated device for one-step EUS-guided biliary drainage: a randomized trial. J Gastroenterol Hepatol 2015; 30: 1461–1466

[4] Itonaga M, Kitano M, Hatamaru K et al. Endoscopic ultrasound-guided choledochoduodenostomy using a thin stent delivery system in patients with unresectable malignant distal biliary obstruction: a prospective multicenter study. Dig Endosc 2019; 31: 291–298

[5] Paik WH, Lee TH, Park DH et al. EUS-guided biliary drainage versus ERCP for the primary palliation of malignant biliary obstruction: a multicenter randomized clinical trial. Am J Gastroenterol 2018; 113: 987–997

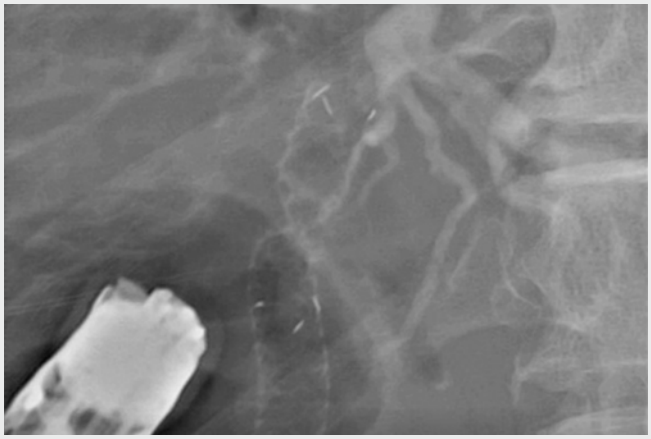

Video 1 The video shows an endoscopic ultrasonography-guided choledochoduodenostomy without fistula dilation performed using a novel fully covered self-expandable metal stent with a 5.9-Fr ultra-thin delivery system.

Bibliography

Endoscopy 2021; 53: E223–E225
DOI 10.1055/a-1244-9651
ISSN 0013-726X
published online 11.9.2020

Georg Thieme Verlag KG, Rüdigerstraße 14,
70469 Stuttgart, Germany