Histologic Findings of Choroidal Vasculopathy in Eyes Enucleated following Radiation Therapy for Uveal Melanoma: Radiation Choroidopathy

Histologische Ergebnisse der choroidalen Vaskulopathie bei enukleierten Augen nach Strahlentherapie für Aderhautmelanom: die strahlenbedingte Choroidopathie

Authors

Sean Platt[1], Diva R. Salomao[2], Jose Pulido[1,3]

Affiliations

1 Ophthalmology and Molecular Medicine, Mayo Clinic, Rochester, Minnesota, United States
2 Anatomic Pathology, Mayo Clinic, Rochester, Minnesota, United States
3 Department of Translational Ophthalmology, Wills Eye Hospital, Philadelphia, Pennsylvania, United States

Key words

radiation retinopathy, radiation choroidopathy, uveal melanoma, ocular radiation

Schlüsselwörter

strahlenbedingte Retinopathie, strahlenbedingte Choroidopathie, uveales Melanom, Aderhautmelanom, Augenbestrahlung

received	1.3.2020
accepted	21.9.2020
published online	22.2.2021

Bibliography

Klin Monatsbl Augenheilkd 2021; 238: 584–590

DOI 10.1055/a-1275-0626

ISSN 0023-2165

Georg Thieme Verlag KG, Rüdigerstraße 14, 70469 Stuttgart, Germany

Correspondence

Prof. Jose Pulido
Wills Eye Hospital, Department of Translational Ophthalmology
840 Walnut Street, Suite 1530, Philadelphia, Pennsylvania 19107, United States
Phone: + 1 267 733 96 17, Fax: + 1 215 928 39 83
pulido.jose@mayo.edu

ABSTRACT

Introduction Little has been published about the choroidal vascular changes that occur years after radiation exposure. The aim of this study was to review the histological changes observed in the choroidal vasculature following radiotherapy for uveal melanoma.

Methods Records from a single institution were retrospectively reviewed from June 7, 2007 to June 7, 2017; 101 patients with a diagnosis of uveal melanoma that underwent enucleation had their records reviewed. Out of these, a total of 26 eyes had undergone plaque brachytherapy prior to enucleation, which had been performed at a mean time of 7.2 years (range from 0 years to 30 years) after the initial plaque placement. A histopathologic analysis was conducted on all 26 eyes with special emphasis on the choroidal changes. Of these 26 eyes, 18 demonstrated evidence of radiation-induced vasculopathy.

Results Of the 18 eyes, 10/18 (55%) had radiation retinopathy and 16/18 (89%) had radiation choroidal vasculopathy. One patient had a phthisical eye, and the choroid could not be evaluated because the characteristics of the vasculature could not be determined. Nine cases had vitreous hemorrhage (50%), all cases had radiation retinopathy, and 8/9 (89%) had radiation choroidopathy. Of the 16 cases with radiation choroidal vasculopathy, 3/16 (19%) had only intratumoral radiation choroidal vasculopathy, 3/16 (19%) had only extratumoral radiation choroidal vasculopathy, and, thus, 10/16 (32%) had both intratumoral and extratumoral radiation choroidal vasculopathy. In patients with radiation choroidal vasculopathy, 2/16 (13%) had hyalinization of the choroidal vessels. Another 3/16 (19%) cases with radiation choroidal vasculopathy had ectatic vessels. The other 11/16 (68%) had evidence of both hyalinization of the choroidal vessels as well as ectatic vessels in the choroid. Histological evidence of radiation retinopathy and choroidopathy were seen in 69% of eyes enucleated after receiving radiation therapy, which, in some cases, also had vitreous hemorrhage. Polypoidal choroidal

vasculopathy, choroidal neovascularization, and retinal choroidal anastomoses (RAP-type lesions) were seen in 12 of the 16 eyes (75%).

Discussion/Conclusion Irradiation of malignant tumors of the eye causes not only radiation retinopathy but also radiation choroidopathy. The role of radiation choroidopathy in the subsequent visual loss following radiotherapy and the role of anti-VEGF therapy needs to be recognized and distinguished from radiation retinopathy. Our data adds to the prior limited knowledge that radiation affects the choroid and can induce specific phenotypes similar to the clinical spectrum of CNV, PCV, and RAP.

ZUSAMMENFASSUNG

Einleitung Bisher wurde nur wenig zu den choroidalen vaskulären Veränderungen, die viele Jahre nach einer Strahlentherapie auftreten können, publiziert. Ziel dieser Studie war es, einen Überblick zu geben über die im choroidalen Gefäßsystem beobachteten histologischen Veränderungen nach einer Strahlentherapie für Aderhautmelanom.

Methoden Die Datensätze einer einzelnen Institution wurden retrospektiv für den Zeitraum vom 7. Juni 2007 bis 7. Juni 2017 begutachtet. Die Daten von insgesamt 101 Patienten mit der Diagnose eines Aderhautmelanoms, die sich einer Enukleation unterzogen, wurden analysiert. In dieser Kohorte wurden insgesamt 26 Augen vor der Enukleation mit Brachytherapie und dem Implantat eines Strahlenträgers behandelt. Die Enukleation wurde durchschnittlich 7,2 Jahre (zwischen 0 und 30 Jahre) nach der ersten Einbringung des Strahlenträgers durchgeführt. Es wurde eine histopathologische Analyse aller 26 Augen mit einem besonderen Augenmerk auf choroidalen Veränderungen durchgeführt. Bei 18 dieser 26 Augen gab es Hinweise auf eine strahlenbedingte Vaskulopathie.

Ergebnisse Von 18 Augen gab es 10/18 Fälle (55%) mit einer strahlenbedingten Retinopathie und 16/18 (89%) mit einer strahlenbedingten choroidalen Vaskulopathie. Ein Patient hatte ein phthisisches Auge, das die Auswertung der Aderhaut verhinderte, da die Charakteristiken des Gefäßsystems nicht ermittelt werden konnten. Es gab 9 Fälle mit Glaskörperblutung (50%), die alle auch eine strahlenbedingte Retinopathie hatten, und 8/9 (89%) hatten eine strahlenbedingte Choroidopathie. Von den 16 Fällen mit strahlenbedingter choroidaler Vaskulopathie hatten 3/16 (19%) nur eine intratumorale strahlenbedingte choroidale Vaskulopathie, 3/16 (19%) nur eine extratumorale strahlenbedingte choroidale Vaskulopathie und 10/16 (32%) sowohl eine intratumorale als auch eine extratumorale strahlenbedingte choroidale Vaskulopathie. Aus der Gruppe der Patienten mit strahlenbedingter choroidaler Vaskulopathie war bei 2/16 (13%) eine Hyalinisierung der Choroidgefäße festzustellen. In 3/16 (19%) weiteren Fällen mit strahlenbedingter choroidaler Vaskulopathie wurden ektatische Gefäße gefunden. Bei den anderen 11/16 (68%) Fällen gab es Hinweise sowohl auf eine Hyalinisierung der Choroidgefäße als auch auf ektatische Gefäße in der Aderhaut. Eine strahlenbedingte Retinopathie und Choroidopathie konnte in 69% der nach der Strahlentherapie enukleierten Augen histologisch nachgeweisen werden; bei einigen Fällen wurde auch eine Glaskörperblutung festgestellt. Eine polypenartige choroidale Vaskulopathie (PCV), choroidale Neovaskularisation (CNV) oder retinale Anastomosen der Aderhaut (Läsionen des RAP-Typs) fanden sich in 12 von 16 Augen (75%).

Diskussion/Schlussfolgerung Eine Strahlentherapie zur Behandlung maligner Augentumoren verursacht nicht nur eine strahlenbedingte Retinopathie, sondern auch eine strahlenbedingte Choroidopathie. Die Rolle der strahlenbedingten Choroidopathie bei Sehverlust nach einer Strahlentherapie und die Rolle der Anti-VEGF-Therapie müssen erkannt werden und sind von der strahlenbedingten Retinopathie zu unterscheiden. Unsere Ergebnisse erweitern das bisher eingeschränkte Wissen darüber, wie eine Bestrahlung die Aderhaut beeinträchtigen und zu spezifischen Phänotypen, die dem klinischen Spektrum von CNV, PCV und RAP gleichen, führen kann.

ABBREVIATIONS

CNV	choroidal neovascularization
ICG	indocyanine green
iPSC	induced pluripotent stem cell
PCV	polypoidal choroidal vasculopathy
RAP	retinal angiomatous proliferation
VEGF	vascular endothelial growth factor

Introduction

The Collaborative Ocular Melanoma Study (COMS) published its first report in 1990 [1]. Since then, the study has demonstrated comparable mortality among patients treated with brachytherapy and enucleation. Thus, globe-preserving therapy with radiation has developed into the standard of care when treating uveal melanomas that are small or medium in size [2]. Radiation retinopathy is a well-known, slowly progressive, and predictable consequence of radiation exposure, with vision loss being the most important complication to the patient. Clinical evidence of radiation retinopathy has been shown to occur in up to 42% of patients 5 years after radiation treatment for posterior uveal melanomas [3]. The COMS histopathologic review demonstrated vascular abnormalities in 55% of irradiated eyes that were enucleated secondarily to plaque failure [4]. Chorioretinal anastomosis, vascular dilatation, and polypoidal changes have been occasionally clinically noted in eyes with radiation retinopathy, but the histopathologic findings after plaque brachytherapy are not well described in the literature [5–8]. Herein, we review the pathology findings of 26 enucleated eyes after treatment of ocular melanoma with

▶ **Table 1** Patient Characteristics.

Characteristic		Number of patients (%)
Total number included patients		18
Age at diagnosis	Range	30–85 years
	Mean	67.2 years
	Male	8 (44%)
	Female	10 (56%)
Site of involvement	Right eye	10 (56%)
	Left eye	8 (44%)
Radiation dose	Range	65–85 Gy
	Mean	83.3 Gy
Time from treatment to enucleation	Range	0–30 years
	Mean	7.2 years
	Median	5.5 years

plaque brachytherapy aiming to describe the vascular changes observed in the choroid.

Materials and Methods

Patient selection

After approval by our Institutional Review Board, the study patient population was identified from our patient database at Mayo Clinic from June 7, 2007 to June 7, 2017 (10 years). A total of 101 patients had undergone enucleation for uveal melanoma. The diagnosis was confirmed in all patients by our pathology department at Mayo Clinic. Of these 101 patients, we identified 26 eyes that had been enucleated after receiving radiation therapy, with a mean time to enucleation of 7.2 years (range 0–30 years). Radiation included brachytherapy (25 eyes) and proton beam radiation (1 eye). All patient charts were reviewed for demographic features (age, sex, age at diagnosis), treatment type, radiation dose, and time from radiation exposure to enucleation.

A complete review of clinical exam findings, ancillary testing, and specimen slides were performed on all patients. The specimen slides from all patients were available and were reviewed by a single pathologist. Our histopathologic assessment included retrospective evaluation of the enucleation specimens for the presence of radiation retinopathy and other radiation-associated findings. More specifically, each specimen was analyzed for characterization of vascular changes in the retina and choroid, including the presence of ectatic blood vessels, hyalinization of vascular walls, and presence of neovascularization. Location of choroidal vasculopathy was recorded as intratumoral or extratumoral. Other features recorded were presence of fibrosis, inflammatory infiltrates, and atrophy of the retina and/or the choroid. All information was placed on a secured, password-protected, encrypted database.

Treatment

Small and medium melanomas were generally treated with radiation (65–85 Gy to a prescription point) and enucleation for large melanomas. Radiation therapy was administered using two different techniques: proton beam (done elsewhere) or iodine-125 brachytherapy.

Histopathologic evaluation

The histology slides from the 26 cases were evaluated by a board-certified pathologist who had special training in ocular pathology (D. R. S.). The ocular pathologist was not aware of the prior history of any patient aside from the fact that the patient had uveal melanoma and had plaque brachytherapy. D. R. S. was asked to evaluate the eye for evidence of vascular changes in the retina and choroid.

Statistical analysis

Total number of cases were determined and percentages of the total number of cases, depending upon the numerator and denominator, were then assessed.

Results

Patient characteristics

A total of 101 included patients with uveal melanoma that underwent enucleation that were seen at the Mayo Clinic from June 2007 to June 2017 were identified (▶ **Table 1**).

Of the 101 eyes, 26 (26%) had received radiation therapy and were enucleated, so they were available for pathologic evaluation. Of these 26 eyes, 18 (69%) had clinical or pathologic evidence of radiation-induced vasculopathy. There was a slight predominance of female patients: 10 patients were female (56%) and 8 patients were male (44%), with a mean age of 67.2 years.

Radiation Outcomes

Clinical findings

The average dose of radiation where the radiation dose was known was 83.3 Gy. The average time from treatment to enucleation was 7.2 years (▶ **Table 2**). Nine patients had vitreous hemorrhage at the time of enucleation. When visualization to the fundus was present, nine patients had evidence of radiation retinopathy and, in five patients, large dilated choroidal vasculature was clinically evident.

Histopathological findings (▶ **Table 2**)

A histopathologic review was conducted with emphasis on the choroidal vascular changes within the tumor and in the choroid at the base of the treated tumor. Eighteen of the 26 eyes that were enucleated demonstrated evidence of radiation vasculopathy. Of the 18 eyes, 10/18 (55%) had radiation retinopathy and 16/18 (89%) had radiation choroidal vasculopathy. One patient had a phthisical eye, and the choroid could not be evaluated because the characteristics of the vasculature could not be determined. This patient was also the only patient that had radiation administered via proton beam elsewhere. Nine cases had vitreous hemorrhage (50%), all cases had radiation retinopathy, and 8/9 (89%) had radiation choroidopathy.

Of the 16 cases with radiation choroidal vasculopathy, 3/16 (19%) had only intratumoral radiation choroidal vasculopathy,

▶ **Table 2** Patient findings.

				Location of vasculopathy		Location of vasculopathy		Histopathologic findings			Rad dose (Gy)	Time to Enucleation
								Vasculopathy type		Other		
Patient #	Sex	Age	Vitreous hemorrhage	Retina	Choroid	Intratumoral	Extratumoral	Ectatic	Hyalinization			
1	M	59			+	+		+		Scarring	Unknown	7
2	F	83	+	+	+		+		+		85 Gy	1
3	F	30	+	+	+	+		+	+	Scarring	85 Gy	2
4	M	65			+	+		+	+	Scarring	85 Gy	8
5	M	62			+					Scarring	85 Gy	3
6	F	62			+					Choroidal Inflammation	85 Gy	1
7	F	77	+	+	+	+		+			Unknown	14
8	F	48	+	+						Subretinal Hemorrhage	65 Gy	0
9	F	67		+						Phthisis	Unknown	18
10	M	57	+	+	+	+		+			85 Gy	1
11	M	68	+	+	+	+		+	+		85 Gy	3
12	F	80			+	+	+	+	+	Choroidal Inflammation	Unknown	7
13	M	76	+	+	+	+	+	+	+		85 Gy	9
14	F	81			+	+		+	+	Choroidal Inflammation	85 Gy	3
15	F	83			+		+	+	+		Unknown	10
16	F	73	+	+	+	+		+	+	Choroidal Inflammation	85 Gy	4
17	M	54	+	+	+	+	+	+	+		Unknown	9
18	M	85			+		+		+		Unknown	30

3/16 (19%) only had extratumoral radiation choroidal vasculopathy, and, thus, 10/16 (32%) had both intratumoral and extratumoral radiation choroidal vasculopathy. In the patients with radiation choroidal vasculopathy, 2/16 (13%) had hyalinization of the choroidal vessels (▶ **Fig. 1 a**). Another 3/16 (19%) cases with radiation choroidal vasculopathy had ectatic vessels (▶ **Fig. 1 b**). The other 11/16 (68%) had evidence of both hyalinization of the choroidal vessels as well as ectatic vessels in the choroid. Polypoidal choroidal vasculopathy, choroidal neovascularization, and retinal choroidal anastomoses (RAP-type lesions) were seen in 12 of the 16 eyes (75%) (▶ **Figs. 1 c** and **d**).

During our analysis, certain histologic features became evident. Hyalinization or thickening of the vascular wall was a common early feature seen on histology (▶ **Fig. 1 a**). Next, the presence of ectatic or thin-walled vessels appeared as the severity of presentation progressed (▶ **Fig. 1 b**). The next stage of severity appeared to be with the formation of choroidal polyps as well as choroidal neovascularization. The size of the polyps varied from subtle polypoidal dilatation to large polypoidal complexes (▶ **Fig. 1 c**). It was sometimes difficult to distinguish polypoidal vessels from choroidal neovascularization. The most severe cases had vitreous hemorrhage and polyps or neovascularization in the choroid.

Currently, a histological grading system for radiation-associated choroidal vasculopathy has not been proposed. It is important for a grading system to be available as we learn more about the pathogenesis of this process. It will be important to organize this data for future research (▶ **Table 3**). Grade 1 radiation choroidal vasculopathy is the presence of hyalinization of the choroidal vessels (▶ **Fig. 1 a**). Grade 2 radiation choroidal vasculopathy is the development of ectatic or thin-walled vessels (▶ **Fig. 1 b**). Grade 3 is the presence of polyps or choroidal neovascularization (▶ **Fig. 1 c** and **d**). Grade 4 is the presence of vitreous and/or subretinal hemorrhage in the presence of Grade 3 vessels and no retinal neovascularization to account for the vitreous hemorrhage.

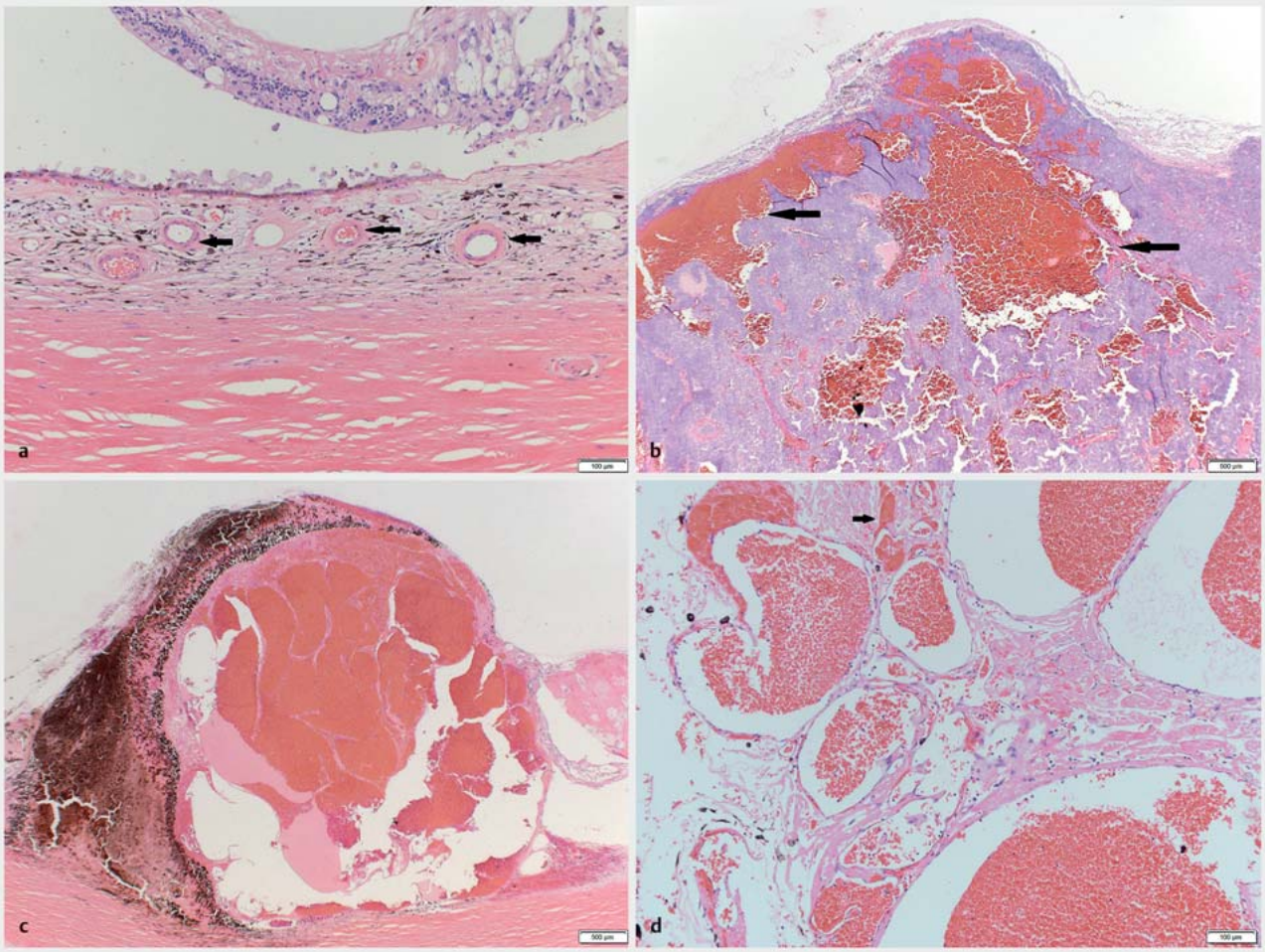

▶ **Fig. 1** **a** Hyalinization. Histological section shows marked hyalinization of vascular walls in the choroidal vessels (arrows), subretinal accumulation of histiocytes, and reactive changes in the overlying retina (hematoxylin-eosin stain; original magnification × 100). **b** Ectatic vessels. Low-power view of the choroidal melanoma demonstrates dilated intratumoral vessels focally coalescing to form hemorrhagic lakes (arrows). The overlying retina shows marked atrophy (hematoxylin-eosin stain; original magnification × 20). **c** Polyps. Low-power view of the choroidal mass with markedly dilated intratumoral, resulting in an elevated, polypoid mass (hematoxylin-eosin stain; original magnification × 20). **d** Ectatic vessels and neovascularization. High-power view shows ectatic choroidal vessels and areas of neovascularization (arrow) (hematoxylin-eosin stain; original magnification × 200).

Discussion

The incidence of radiation retinopathy has been extensively reviewed in the literature, with rates generally ranging from 10 to 63% [3, 4, 9], with proliferative changes reported to develop in 7% of eyes within 10 years after plaque therapy [10]. Reviewing the literature and their own institution's experiences treating radiation retinopathy, Wen and McCannel noted that anti-VEGF and intraocular steroids had an effect on macular edema, but its use for visual recovery over time was limited [9]. In contrast, Bascom Palmer's review of over 5000 injections for radiation retinopathy (54.2%) demonstrated stability or improvement of vision [11, 12].

Avery et al. previously studied histopathologic characteristics of patients from the COMS treated with iodine-125 versus radiation-naïve tumors. Noted findings included inflammation, fibrosis, vascular changes within the tumor, and damage to the retinal vasculature, which was consistent with our findings [4]. In contrast to our study, we also noted changes to the choroidal vasculature that localized to intratumoral and extratumoral locations. Spaide et al. conducted a retrospective imaging review of 193 patients who underwent radiation treatment for subfoveal choroidal neovascularization. Spaide first described choroidal vascular dilatations or "blebs" in 19 patients outside the border of previous CNV [6]. This description is similar to the ectatic choroidal vascular changes seen histologically in our study. Additionally, Peiretti et al. and Midena et al. noted, with indocyanine green angiography chorioretinal anastomosis, atypical dilated choroidal vessels and choriocapillaris drop out, respectively [5, 13]. A comparable histopathologic study by Egbert et al. looked at 17 eyes enucleated after radiation treatment for retinoblastoma. Their study found radiation-induced abnormalities to the posterior ciliary arteries but did not identify radiation-induced choroidal

▶ **Table 3** Choroidal vasculopathy grading system.

Grade	Hyalinization	Ectatic vessels	Polyps/neovascularization	Vitreous hemorrhage	Figure
0	–	–	–	–	
1	+	–	–	–	▶ **Fig. 1 a**
2	+	+	–	–	▶ **Fig. 1 b**
3	+	+	+	–	▶ **Fig. 1 c**
4	±	±	±	+	

changes [14]. The myointimal proliferation significantly constricted the posterior ciliary vessels and, in some cases, caused complete occlusion [14]. This suggests that posterior ciliary vessels, just like retinal vessels, are radiosensitive. Radiation-induced ischemia to the choroid from posterior ciliary artery occlusion, as well as free radical damage to the choroid, would cause a multifactorial effect on the choroidal vasculature.

There are two studies in the literature that have evaluated indocyanine green angiography of the choroidal vasculature after radiation, which suggested that there is not only vascular closure but also dilation of existing vessels, leakage of the vessels near the site of radiation, and possible choroidal neovascularization [15, 16]. Finally, another prior histopathologic study of cases treated with plaque brachytherapy discussed that some cases had hyalinization of vessels, dilation of some vessels, and intratumoral as well as subretinal hemorrhages, but the evaluation was not as specifically directed to evaluating the choroidal vasculature as this study; but the fact that some cases had similar findings suggests that the findings that we have described have been seen by others by ICG as well as by histology [17].

Our study is limited by being a retrospective study, but it was especially designed to evaluate the choroidal vasculature. Additionally, we have graded the response of the radiation choroidopathy but cannot state that it actually conforms to stages since we could not prospectively follow the cases. Regardless, the study does conform to the little that is known about radiation choroidopathy in the literature and adds that choroidopathy is an important aspect of radiation effects to the eye [4–6, 13–17].

Even with intravitreal anti-VEGF treatment, proliferative radiation-induced retinopathy can still be difficult to treat and sometimes recalcitrant to anti-VEGF therapy. Our study shows that, like polypoidal choroidal vasculopathy, radiation-induced choroidal vasculopathy has similar histologic findings, which may explain why anti-VEGF treatments can be unsuccessful.

Conclusion

Our histopathologic analysis demonstrated choroidal vasculopathy to be a common histologic feature associated with the late effects of radiation exposure. Although the presence of these choroidal changes has been previously recognized by ICG angiography [5, 6, 15, 16], histologic analysis of these findings has not been well described. Currently, a histologic grading system for radiation-associated choroidal vasculopathy does not exist. The role of radiation choroidopathy, in the subsequent visual loss following radiotherapy and the role of anti-VEGF therapy to treat it, needs to be recognized and distinguished from radiation retinopathy. As we try to determine the cause and treatment, a grading system is needed. Therefore, we would like to propose the following three grades: Grade 1 radiation choroidal vasculopathy is the presence of hyalinization of the choroidal vessels; Grade 2 radiation choroidal vasculopathy is the development of ectatic or thin-walled vessels; Grade 3 is the presence of polyps or choroidal neovascularization; and Grade 4 is the presence of a vitreous and/or subretinal hemorrhage in the setting of Grade 3 vessels and no retinal neovascularization to account for the vitreous hemorrhage.

Acknowledgements

Ms. Dee Chase for her work in editing the manuscript. Statement of Ethics: Institutional Review Board approval was obtained for this retrospective study, and research was conducted ethically in accordance with the World Medical Association Declaration of Helsinki. Disclosure Statement: Jose S. Pulido, M.D. has stock interest in Lagen Laboratories, which makes iPSC-retinal pigment epithelial cells for in vitro use and is not relevant to this study. Funding Resources: Supported in part by Mayo Clinic donations by the Deshong Family and the Paul Family. Author Contributions: Jose S. Pulido, M.D. developed the idea and helped with the writing, editing, and evaluation of data. Diva R. Salomão, M.D. helped with the writing and editing, and evaluation of data. Sean Platt, M.D. helped with the writing and editing, and evaluation of data.

Conflict of Interest

See above otherwise no other conflicts of interests.

References

[1] [Anonymous]. Accuracy of diagnosis of choroidal melanomas in the Collaborative Ocular Melanoma Study. COMS report no. 1. Arch Ophthalmol 1990; 108: 1268–1273

[2] Diener-West M, Earle JD, Fine SL et al. The COMS randomized trial of iodine 125 brachytherapy for choroidal melanoma, III: initial mortality findings. COMS Report No. 18. Arch Ophthalmol 2001; 119: 969–982

[3] Gündüz K, Shields CL, Shields JA et al. Radiation retinopathy following plaque radiotherapy for posterior uveal melanoma. Arch Ophthalmol 1999; 117: 609–614

[4] Avery RB, Diener-West M, Reynolds SM et al. Histopathologic characteristics of choroidal melanoma in eyes enucleated after iodine 125 brachytherapy in the collaborative ocular melanoma study. Arch Ophthalmol 2008; 126: 207–212. doi:10.1001/archophthalmol.2007.50

[5] Peiretti E, Slakter JS, Wu S et al. Late effect of external eye irradiation on choroidal circulation. Eur J Ophthalmol 2006; 16: 637–640

[6] Spaide RF, Borodoker N, Shah V. Atypical choroidal neovascularization in radiation retinopathy. Am J Ophthalmol 2002; 133: 709–711

[7] Pang CE, Freund KB. Intravitreal polypoidal choroidal vasculopathy in radiation retinopathy. Ophthalmic Surg Lasers Imaging Retina 2014; 45: 585–588. doi:10.3928/23258160-20141008-04

[8] Archer DB, Amoaku WM, Gardiner TA. Radiation retinopathy – clinical, histopathological, ultrastructural and experimental correlations. Eye (Lond) 1991; 5 (Pt 2): 239–251. doi:10.1038/eye.1991.39

[9] Wen JC, McCannel TA. Treatment of radiation retinopathy following plaque brachytherapy for choroidal melanoma. Curr Opin Ophthalmol 2009; 20: 200–204. doi:10.1097/ICU.0b013e328329b62d

[10] Bianciotto C, Shields CL, Pirondini C et al. Proliferative radiation retinopathy after plaque radiotherapy for uveal melanoma. Ophthalmology 2010; 117: 1005–1012. doi:10.1016/j.ophtha.2009.10.015

[11] Cavalcante LL, Cavalcante ML, Murray TG et al. Intravitreal injection analysis at the Bascom Palmer Eye Institute: evaluation of clinical indications for the treatment and incidence rates of endophthalmitis. Clin Ophthalmol 2010; 4: 519–524

[12] Houston S 3rd, Murray TG, Pina Y et al. Pharmacotherapy for radiation retinopathy. Retina Today 2010; November/December: 62–66

[13] Midena E, Segato T, Valenti M et al. The effect of external eye irradiation on choroidal circulation. Ophthalmology 1996; 103: 1651–1660

[14] Egbert PR, Fajardo LF, Donaldson SS et al. Posterior ocular abnormalities after irradiation for retinoblastoma: a histopathological study. Br J Ophthalmol 1980; 64: 660–665

[15] Amoaku WM, Lafaut B, Sallet G et al. Radiation choroidal vasculopathy: an indocyanine green angiography study. Eye (Lond) 1995; 9 (Pt 6): 738–744. doi:10.1038/eye.1995.187

[16] Takahashi K, Kishi S, Muraoka K et al. Radiation choroidopathy with remodeling of the choroidal venous system. Am J Ophthalmol 1998; 125: 367–373. doi:10.1016/s0002-9394(99)80148-2

[17] MacFaul PA, Morgan G. Histopathological changes in malignant melanomas of the choroid after cobalt plaque therapy. Br J Ophthalmol 1977; 61: 221–228. doi:10.1136/bjo.61.3.221