



Examining the Hand in the Video Consultation

Die Untersuchung der Hand in der Videosprechstunde

Authors

Kristian Welle¹, Stefan Täger², Roslind Karolina Hackenberg², Alexander Markowetz³, Frank Alexander Schildberg¹ , Christof Burger¹, Dieter Christian Wirtz¹, Tom Jansen¹, Koroush Kabir¹ 

Affiliations

- 1 Department of Orthopaedics and Trauma Surgery, Bonn University Medical Centre, Germany
- 2 Department of Orthopaedics and Trauma Surgery, Section of Hand and Plastic-Reconstructive Trauma Surgery, Bonn University Medical Centre, Germany
- 3 Department of Mathematics and Computer Science, Philipps University Marburg, Germany

Key words

telemedicine, video consultation, hand, examination, COVID-19

Schlüsselwörter

Telemedizin, Videosprechstunde, Hand, Untersuchung, COVID-19

published online 21.01.2021

Bibliography

Z Orthop Unfall 2021; 159: 202–207

DOI 10.1055/a-1304-3593

ISSN 1864-6697

© 2021. Thieme. All rights reserved.

Georg Thieme Verlag KG, Rüdigerstraße 14, 70469 Stuttgart, Germany

Correspondence

PD Dr. med. Koroush Kabir
Department of Orthopaedics and Trauma Surgery,
Bonn University Medical Centre
Venusberg-Campus 1, 53105 Bonn, Germany
koroushkabir@yahoo.com



Supplementary material is available under
<https://doi.org/10.1055/a-1304-3593>

ABSTRACT

Background Video consultations could support patient care in hand surgery during social distancing in the COVID-19 era. According to the literature, images of hand and fingers can support telediagnosis in hand emergencies. We present this feasibility study on online video consultation in hand surgery.

Methods A structured examination was designed to query the medical history and examine motor skills, sensitivity, strength and function tests of the hand. Thirty examinations on both hands were carried out by online video consultation, then in direct contact and compared with each other.

Results With 4560 evaluated range of movement of the hand and finger joints, there was a high correlation between the measurement methods of $R = 0.995$ ($p < 0.0001$, confidence interval 0.9946–0.9954). In the video-based examination, 84.6% of the measured values showed a deviation of less than 5° compared to the direct examination, 92.8% less than 10° deviation. Good accordance was also found in the patient's medical history. An estimating examination of sensitivity, function and strength during video examination is feasible with simple auxiliary aids. Deficits are evident in the detection of scars, in function tests and the absence of haptic findings.

Conclusion Online video consultation allows hand examination with sufficient documentation of hand and finger movements (range of motion) and proper evaluation of symptoms. It cannot replace direct examination but complement patient care in hand surgery even beyond the current COVID-19 pandemic.

ZUSAMMENFASSUNG

Hintergrund Videosprechstunden können bei Social Distancing in der COVID-19-Pandemie die Patientenversorgung unterstützen. Während zur Einholung handchirurgischer Fach- und Zweitmeinungen über Bildbefunde eine gute Literaturlage vorliegt, fehlt diese für die Videosprechstunde. Dies soll mit der vorliegenden Machbarkeitsstudie zur handchirurgischen Befunderhebung per Video nachgeholt werden.

Methoden Ein strukturierter Untersuchungsbogen wurde entworfen zur Abfrage der Anamnese und Untersuchung von Motorik, Sensibilität, Kraft sowie spezifischer Funktionstests an der Hand. 30 Untersuchungen an jeweils beiden Händen wurden per Videosprechstunde und nachfolgend in direktem Kontakt durchgeführt und miteinander verglichen.

Ergebnisse Bei 4560 Bewegungsumfängen an der Hand zeigte sich eine hohe Korrelation zwischen den Messmethoden von $R = 0,995$ ($p < 0,0001$, Konfidenzintervall 0,9946–0,9954). Dabei zeigten bei der videobasierten Untersuchung 84,6% der Messwerte eine Abweichung von weniger als 5° im Vergleich mit der direkten Untersuchung, 92,8% weniger als 10° Abweichung. Eine gute Übereinstimmung zeigte sich auch bei

der Anamnese. Die orientierende Untersuchung von Sensibilität, Funktion und Kraft ist mit einfachen Hilfsmitteln gut möglich in der Videosprechstunde. Defizite zeigen sich bei der Erkennung von Narben, bei differenzierten Funktionstests sowie durch das Fehlen haptischer Befunde.

Schlussfolgerung Die Untersuchung der Hand in der Videosprechstunde erlaubt eine sehr gute Untersuchung des Bewe-

gungsumfanges an den Gelenken der Hand, die Aufnahme der Beschwerden und eine Eingrenzung der Befunde. Sie kann die traditionelle Fachsprechstunde mit direktem Kontakt nicht vollständig ersetzen, stellt jedoch eine sinnvolle Ergänzung dar und besitzt eine Berechtigung über die aktuelle COVID-19-Pandemie hinaus.

Introduction

As part of the COVID 19 pandemic with its imposed lockdown, scheduled clinics in all departments were cancelled and patients rescheduled to later dates. Telemedicine offers patients the opportunity to interact and consult with experts. Examination of the hands is an obvious choice, since both extremities can be “offered to the camera” quite readily. It has already been demonstrated in recent years that telemedicine may be used to obtain expert opinions [1]. In rural and sparsely populated areas in particular, this allows for sophisticated medicine [2]; its utilisation there can also help reduce the number of patients transferred with hand injuries [3]. Virtual telemedicine visits can also contribute to post-operative follow-up [4]. Until now, however, telemedicine has focused on transmitting and assessing findings. Electronically transmitted radiographs [5], as well as the acquisition and transmission of smartphone images of the hand, facilitate reliable treatment and follow-up [6]. Technical progress, with its ubiquitous access to computers, tablets and fast internet, makes it possible to conduct virtual hand surgery clinics without any problems [7]. The quality of real-time images and videos offers outstanding possibilities for examination and treatment in hand surgery in the era of COVID-19 and beyond.

Virtual clinics permit direct interaction between physician and patient even without physical contact. Medical questions and instructions during the interview and examination can be directly realised and observed. Despite the increasing use of telemedicine procedures, to our knowledge there is no scientific data available to date comparing the full examination of the hand in virtual clinics with the traditional doctor-patient interaction.

This study aims to compare the virtual hand surgery clinic with a conventional hand surgery clinic.

Material and Methods

Patient population and data collection

30 examinations of 60 hands were performed twice in succession: first, as part of a virtual clinic with physical separation of physician and patient (VC), and then by in-person contact (IPC) with the same physician. 5 unilateral pathologies of the hand (Dupuytren contracture II° D V, trigger finger D IV, subcapital metacarpal fracture D V, scaphoid pseudarthrosis, and de Quervain disease) were selected and assessed by 6 senior physicians in the Department of Orthopaedics and Trauma Surgery of a German university medical centre.

These virtual clinics used the same setup as for the regular virtual clinic sessions in the department itself. For both the patient and physician, this included a computer with a 23-inch screen, HD webcam, built-in microphone and audio output (HP EliteDesk 800 G1, HP EliteDisplay E232, CA, USA; Logitech C920 CA, USA). Audio and video transmission was in real time, with both physician and patient facing a split-screen allowing them to see themselves and the person they were talking to at all times. The examiner also had the option of taking screenshots (Snipping Tool, Microsoft, WA, USA) and measuring angles by drawing auxiliary lines.

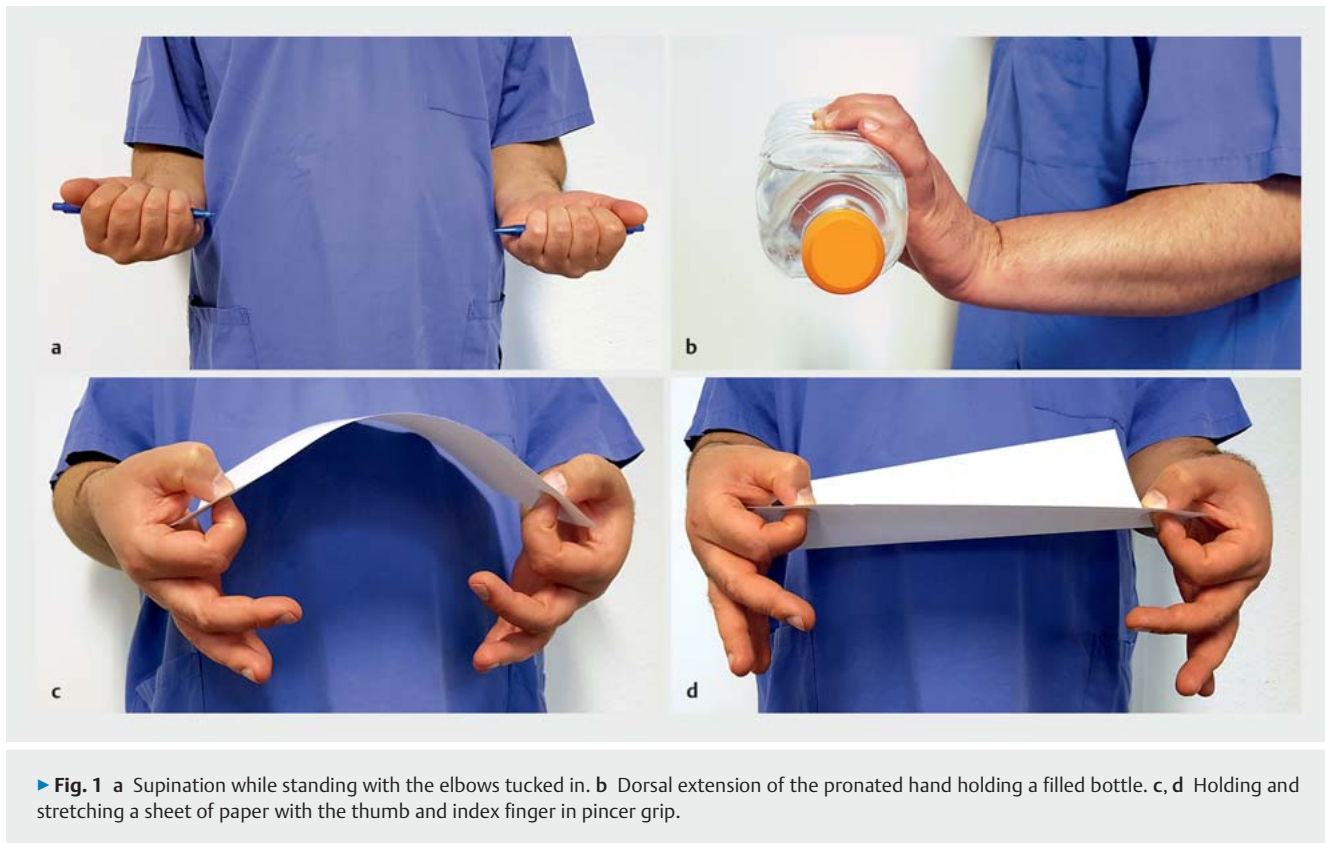
The examination took place in a room in the department without the support of relatives or medical staff. In order to be able to assess the feasibility without interfering examiner dependency, both examinations were performed by the same physician.

All examinations were undertaken after obtaining detailed informed consent. The trial was approved in advance by the institutional review board responsible for our department (IRB #163/20).

Examination structure

The initial examination was first conducted by virtual clinic (VC), followed by a traditional in-person contact with the same examiner (IPC). In order to structure the examination and documentation of the findings, a systematic questionnaire and examination form was developed and used in all examinations (Appendix 1). It included selected questions on medical history, sketches of the identified findings, and documentation of the range of motion of the joints. In addition, selected questions were asked for the examination of strength, for motor function and nerve tests, as well as for examination findings in common disorders. For the quick documentation of normal findings, preset reference values could be check-marked.

The medical history of the hand was obtained directly during the virtual examination. For the inspection, documentation of the range of motion and the subsequent examination process, the examiner performed the required movements and manipulations in front of the camera with direct control and adjustment of patient behaviour. In the virtual clinic a thin-walled 1.5 l PET bottle, 3/4-full, was used to check the strength as well as motion under load. Akin to intrinsic muscle testing, a sheet of paper was used to examine the pincer, key pinch and power grips as well as the finger function. The neurologic status was checked by assessing motion sequences; pressure points were assessed to rule out nerve compression syndromes, and the correct technique was checked in the virtual image. Common disorders were assessed separately through typical pain locations, function and stress tests. At the end, the diagnosis and recommended course of action were documented.



In the following traditional examination (IPC), the examination form was followed in the same fashion. The examiner also had a goniometer to measure the range of motion.

Examination workflow (VC)

Each examination started with the patient's medical history and the description of his/her symptoms. Active questions concerned the presence and timing of symptoms, previous accidents or increased strain on the hands, pain intensity (VAS) and other complaints, e.g. related to elbows or cervical spine. The symptomatic areas of the hands, demonstrated upon request, were marked on hand-drawn sketches. By presenting both hands to the camera, they were inspected for swelling; erythema; haematoma; atrophy/hypertrophy; scars; and deformities. Findings were completed by active questioning.

The patients palpated their hands themselves as instructed and demonstrated by the examiner. The examiner inquired about pain, hyperthermia and sensitivity with differentiation from dysaesthesia and anaesthesia. These findings were also incorporated into the manual sketches of the hands.

Further examination of the function was performed by a motion sequence demonstrated by the examiner. Starting with the demonstration of pronation and supination while standing with the elbows tucked in (► Fig. 1 a), and continuing in a sitting position with dorsal extension and palmar flexion as well as ulnar/radial abduction in the wrist, the range of motion of the thumb and finger joints were also documented for both hands.

In addition to the depicted measurement points, the examination form offered space for documenting the range of motion as well as for check-marking preset reference values.

Strength was tested with the help of a partially filled plastic bottle. Dorsal extension with pronated wrist (► Fig. 1 b), palmar flexion with supinated wrist, rapid pronation-supination, and strong squeezing of the bottle had to be performed while holding the filled bottle and with the elbow flexed. In the latter test under full power, the thin-walled bottle should exhibit deformation and/or deformation noise. The degree of strength was classified as strong (3 – performance without any problems), difficult (2 – performance with some problems), weak (1 – motion only without bottle) and not possible (0).

Motor function tests were performed with the thumb-fingertip contact and the following grip types: pincer; key pinch; power; and spherical. Differences in strength between the pincer and key pinch grips of both hands were checked by jerking a sheet of paper between both thumbs and index fingers (► Fig. 1 c and d). The power grip was checked by opening or closing the bottle, the spherical grip by holding the bottle cap in the hollow of the hand.

The examination process also included global neurologic tests. The radial nerve was assessed by extending the wrist and fingers with the elbow flexed, while the deep branch of the radial nerve was evaluated by powerful, rapid supination with the filled bottle. The median nerve was assessed by fist closure, palmar flexion of hand and fingers, and by opposing the thumb with the ring finger and little finger, while the ulnar nerve was evaluated by fist closure. In addition, the median and ulnar nerves were examined by

flexion of the supinated hand loaded with the filled bottle and checked with the Ochsner test (median nerve) and intrinsic muscle test (ulnar nerve), the latter by holding a sheet of paper between the ring and little fingers.

Palpation was performed according to the symptoms as a selective pain provocation test with imitation of the motions and pressure points demonstrated by the examiner. Triggered pain and abnormal motion patterns were regarded as pathological. The pronator teres syndrome (a) was assessed by powerful pronation with strong compression of the forearm by the other hand, the ulnar canal (b) by strong pressure with the thumb of one hand on the ulnar wrist flexor crease of the other hand. The carpal tunnel (c) was assessed by a (short) Phalen manoeuvre and the Tinel sign, the cubital tunnel (d) by local pressure. Other examinations included pain on vigorous fist closure, tenderness when putting pressure on the flat hand resting on the table and palmar tenderness above the wrist medially and radially for scapholunate dissociation (e) and scaphoid-centred pathologies (f). Other guided tests included tenderness above the thumb saddle joint and when the thumb was compressed and rotated as a guided grind test for carpometacarpal osteoarthritis (g); tenderness over the first extensor compartment and a positive guided Finkelstein test for de Quervain disease (h); tenderness over the A1 pulley with provoked pain on focal pressure and extension of the affected finger in trigger finger/A1 pulley stenosis (i); limited extension despite support with the unaffected hand and palmar scarring in Dupuytren contracture (j); pain, swelling and laxity in the metacarpophalangeal (MCP) joint of the thumb in ulnar collateral ligament rupture/skier's thumb (k); pain and swelling with plump joint contour in osteoarthritis (l); synovitis of the MCP joints with ulnar deviation of the fingers; extension deficit and swan neck or buttonhole deformity; as well as pain and possible malalignment in fractures of fingers (m); metacarpals (n); carpals (o); or distal radius (p).

Analysis

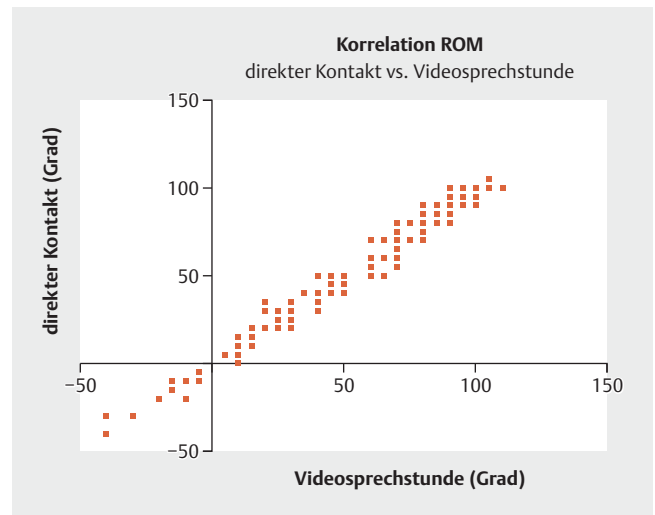
The examination was analysed and the graphs were created with Graphpad Prism (v8.4.2, Graphpad Software LLC, CA, USA). Range of motion statistics for the measurements by virtual clinic (VC), in-person contact (IPC) and for the difference were descriptive with mean value; median; standard deviation and error; and confidence level. The degree of agreement was determined by Spearman correlation and the significance level defined as $p < 0.05$. Descriptive and qualitative analysis was chosen for the sketches and the strength, function and provocation tests.

Results

A total of 4560 individual range of motion measurements were obtained in 30 examinations of both hands, each via virtual and in-person clinic.

The examination techniques demonstrated a significant ($p < 0.0001$) and high correlation ($R = 0.995$, confidence interval 0.9946 to 0.9954) (► Fig. 2).

In the virtual examination 84.6% of the measurements deviated by less than 5° compared to the in-person examination, with 92.8% deviating by less than 10° (► Fig. 3).



► Fig. 2 Correlation between hand range of motion measurements obtained by VC and IPC.

When documenting the medical history, pain intensity and location, the findings obtained during the virtual examination were identical to those in the in-person examination (30 of 30 examinations). Differences in the inspection of the hands were noted when looking at scars. While scars were noted in 18 IPC hand examinations, scars were identified in 8 (44.5%) VC hand examinations, with only 2 of those (11.1%) identifying all scars.

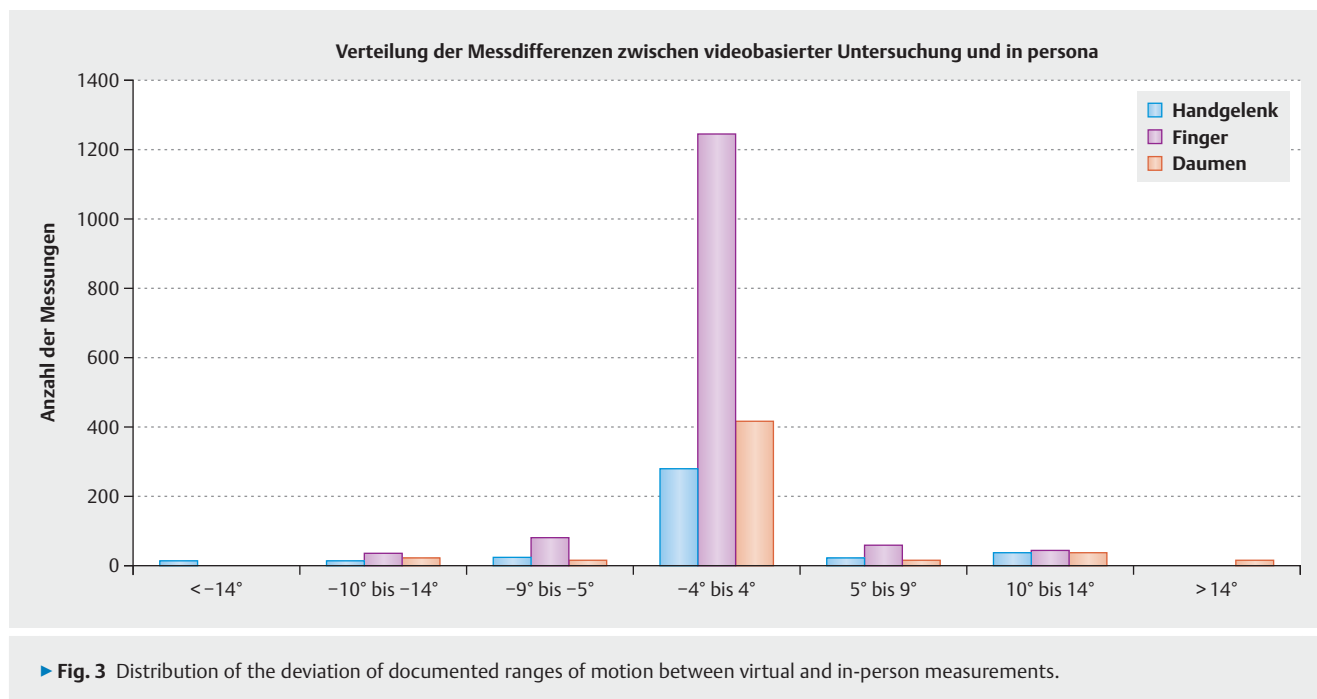
There were no unilateral sensitivity disorders and muscle changes (atrophy/hypertrophy) in the hands examined, and thus none were documented.

The demonstrated motor function tests as well as the provocation tests specified by the examination form also showed agreement with corresponding documentation in both examination modalities. More detailed examinations, such as for strength with classification according to Janda, and also more differentiated provocation tests were not feasible in the video visit with the tools provided.

The unilateral pathologies with their disease-specific findings of limited finger extension and scarring of the skin in Dupuytren contracture (j); snapping extension of the ring finger with tenderness over the A1 pulley (i); pain, swelling and restricted range of motion in subcapital metacarpal fracture (n); pain when leaning on the hand in previous scaphoid fracture (f); as well as tenderness over the extensor tendon sheath and a positive Finkelstein test in de Quervain disease (h); were identified in all cases and diagnosed in both the virtual and in-person examination.

Discussion

The introduction of virtual clinics in hand surgery during the COVID 19 pandemic lockdown was imperative for non-contact patient care. The benefits of obtaining expert or second opinion via telemedicine consultations have already been confirmed [8] and the feasibility of conducting these as part of orthopaedic clinics has been demonstrated [9]. Smartphone photographs can measure finger position and mobility with the same accuracy as go-



niometers [7]. Up to now, it had been unclear whether hand surgery patients could also be adequately assessed, diagnosed and managed via virtual clinics. This feasibility trial addressed the first part of this challenge – the examination, assessment and clinical diagnosis.

The goal was to clarify whether the findings obtained during both the virtual clinic and in-person examinations were identical. In this respect, an approach with identical examiners for each constellation of findings was chosen. In order to prevent changes in the findings over time, the virtual and in-person examinations were conducted without any time in between. One source of bias is the fact that findings from the first examination are still clearly present. Assuming that the virtual clinic would be inferior to in-person examination, the virtual clinic was therefore conducted first, followed by the in-person examination. The missing change of examiner between virtual clinic and in-person examination also represents a source of error in terms of interrater reliability, which was only mitigated by having 6 different examiners for each clinical entity. According to the authors, the listed limitations do not significantly reduce the impact of this study, which was designed to identify and assess opportunities and problem areas.

In order to compare both types of examination in an orderly manner, a structured protocol with hand surgery examinations was created. Besides the medical history, these included in particular the inspection of both hands; measurement of the range of motion of all joints in the hand; assessment of motor and sensory function; as well as the manual examination or, in the case of VC, the guided examination by the patients themselves

Transmission of the medical history and description of the complaints was not limited by any technical factors. It should be noted, however, that only findings of the hand were documented. Although patient habitus and behaviour are also automatically as-

essed on-screen, it cannot be ruled out that significant findings of the other extremities may be overlooked.

In terms of inspection, on the other hand, the virtual clinic and in-person examinations differed markedly. Without palpation, adequate assessment of many parameters, such as skin moisture, turgor and heat distribution, was lacking due to the nature of this modality. As part of the queried and tangible parameters, too, small skin changes such as older scars were hard to identify. While the retractions in Dupuytren' contracture were certainly be seen on-screen, not all older scars and skin efflorescences were identified.

Higher levels of accuracy can be achieved through active enquiry. It is possible that higher camera resolution (better than the HD resolution used by us) may improve results. Good lighting and a neutral background, typically the patient's outer clothing, is also helpful.

For the clinical conditions studied in this trial, the incomplete identification of the scars did not impact on the diagnosis. Nonetheless, this limitation should not be underestimated, as existing scars should be taken into account, e.g., when choosing the site of incision and thus also when obtaining informed consent for surgical measures. As a result of this trial, in addition to sole observation patients should be asked for information on scars and skin changes.

Range of motion measurements of the hand and fingers, which are important in hand surgery, demonstrated a high degree of agreement between virtual and in-person examinations. While Scott et al. (2019) [10] found valid results for visual range of motion assessment in the hand, which, however, depended on the examiner and were therefore prone to errors, and Smergliuolo et al. (2016) [11] also reported difficulties, particularly when measuring pronation and supination on-screen, Zhao et al. (2019) [7]

demonstrated that measuring finger position and mobility with a smartphone can be on par with goniometer measurements.

Our results revealed a high correlation between the range of motion measurements obtained in the virtual and in-person examinations. In particular, structured examination of both hands revealed even small differences between them. When examining pronation and supination, the results presented here were quite comparable only after standardisation of the measurement protocol in the preliminary examinations. To measure pronation and supination, the participants had to stand up, tuck in the elbow and keep it flexed at 90°. With the camera on top of the monitor screen, the hands are well within the field of vision and the position of the elbow joint can be checked. When measuring extension and flexion in the wrist, valid measurement results were obtained only after having gained experience in the preliminary examination. For the Phalen and reverse Phalen manoeuvre the examiner demonstrated the correct motions and asked the patient to keep both forearms in the correct position without rotation in the visual axis. Here, too, this will reveal even small differences on contra-lateral comparison. In general it can be said that patients almost “automatically” adjust their hand position to that demonstrated by the examiner. This allows correct and rapid examinations in a smooth sequence and problem-free “correction” of the demonstrated joint positions. In terms of rapid assessment, the option of quickly check-marking the reference values for the joint in question has proved particularly useful. However, the considerable time saved could entail the risk of misinterpretation through implied reference values. There was no apparent error on comparison in this trial; however, since the examiner used the same form for the in-person examination as well, a “two-sided” error cannot be ruled out. The high correlation may also be affected by the fact that in both types of examination joint mobility was usually noted in steps of 5° and 10°.

Documentation of motor skills and strength also revealed good agreement between the examination forms. Since both examinations were undertaken with the same tools, no significant difference was expected. However, the result is marred by a lack of Janda strength classification. While other authors [12] advocate the use of different size household items, such as milk cartons and wine bottles, our trial did not find these to be practical. However, we do favour the use of a single PET bottle, as this tends to provide a general assessment of the presence of vigorous motions, restrictions and pareses. But the case number in the examination selected here was too small for adequate statistical analysis.

The virtual examination also revealed good feasibility when conducting the function and provocation tests. The findings characteristic of the respective clinical disorders presented here were thus identified regularly and analogously in both examination modalities. The fact that contra-lateral comparison with the unaffected hand was available proved beneficial. Here too, however, further research is needed to provide statistical confirmation of the results.

Conclusions

In the virtual examination as part of telemedicine, medical history, location of the complaints, and range of motion of all joints of the hand can be documented with high correlation with the traditional examination in person. To date, small skin lesions and scars in particular cannot be adequately diagnosed by inspection. Strength testing with simple tools, as well as function and provocation tests, can be reproduced well as an initial examination. Virtual hand surgery clinics require further study. They will not replace the traditional in-person expert clinic, but offer the potential for future applications beyond the era of COVID-19.

Remark

K. Welle and S. Täger contributed equally to this project and should be considered as co-lead authors. T. Jansen and K. Kabir contributed equally to this project and should be considered as co-last authors. K. Welle and K. Kabir are the corresponding authors.

Conflict of Interest

The authors declare that they have no conflict of interest.

References

- [1] Abou Al Tout Y, Taleb C, Kosayer M et al. [Telemedicine and hand injuries: a feasibility study]. *Ann Chir Plast Esthet* 2010; 55: 8–13
- [2] Clemmer TP. The role of medical informatics in telemedicine. *J Med Syst* 1995; 19: 47–58
- [3] Tripod M, Tait M, Bracey J et al. The Use of Telemedicine Decreases Unnecessary Hand Trauma Transfers. *Hand (N Y)* 2020; 15: 422–427. doi:10.1177/1558944718810877
- [4] Grandizio LC, Foster BK, Klena JC. Telemedicine in Hand and Upper-Extremity Surgery. *J Hand Surg Am* 2020; 45: 239–242
- [5] Ferrero A, Garavaglia G, Gehri R et al. Analysis of the inter- and intra-observer agreement in radiographic evaluation of wrist fractures using the multimedia messaging service. *Hand (N Y)* 2011; 6: 384–389
- [6] Fenelon C, Murphy EP, Galbraith JG et al. Telesurveillance: Exploring the Use of Mobile Phone Imaging in the Follow-Up of Orthopedic Patients with Hand Trauma. *Telemed J E Health* 2019; 25: 1244–1249
- [7] Zhao JZ, Blazar PE, Mora AN et al. Range of Motion Measurements of the Fingers Via Smartphone Photography. *Hand (N Y)* 2020; 15: 679–685. doi:10.1177/1558944718820955
- [8] Paik AM, Granick MS, Scott S. Plastic surgery telehealth consultation expedites Emergency Department treatment. *J Telemed Telecare* 2017; 23: 321–327
- [9] Buvik A, Bugge E, Knutsen G et al. Quality of care for remote orthopaedic consultations using telemedicine: a randomised controlled trial. *BMC Health Serv Res* 2016; 16: 483
- [10] Scott KL, Skotak CM, Renfree KJ. Remote Assessment of Wrist Range of Motion: Inter- and Intra-Observer Agreement of Provider Estimation and Direct Measurement With Photographs and Tracings. *J Hand Surg Am* 2019; 44: 954–965
- [11] Smeragliuolo AH, Hill NJ, Disla L et al. Validation of the Leap Motion Controller using marked motion capture technology. *J Biomech* 2016; 49: 1742–1750
- [12] Tanaka MJ, Oh LS, Martin SD et al. Telemedicine in the Era of COVID-19: The Virtual Orthopaedic Examination. *J Bone Joint Surg Am* 2020; 102: e57. doi:10.2106/JBJS.20.00609