

Ovarian Vein Thrombosis: A Narrative Review

Nicoletta Riva^{1,2} Jean Calleja-Agius¹

¹ Department of Anatomy, Faculty of Medicine and Surgery, University of Malta, Msida, Malta

² Department of Pathology, Faculty of Medicine and Surgery, University of Malta, Msida, Malta

Address for correspondence Nicoletta Riva, MD, PhD, Department of Pathology, Faculty of Medicine and Surgery, University of Malta, Msida, MSD 2080, Malta
(e-mail: nico.riva@hotmail.it; nicoleтта.riva@um.edu.mt).

Hamostaseologie 2021;41:257–266.

Abstract

Ovarian vein thrombosis (OVT) is a rare type of venous thromboembolism. The most common risk factors for OVT include pregnancy, oral contraceptives, malignancies, recent surgery, and pelvic infections; however, in 4 to 16% of cases, it can be classified as idiopathic. Most of the available information regards pregnancy-related OVT, which has been reported to complicate 0.01 to 0.18% of pregnancies and to peak around 2 to 6 days after delivery or miscarriage/abortion. The right ovarian vein is more frequently involved (70–80% of cases). Clinical features of OVT include abdominal pain and tenderness, fever, and gastrointestinal symptoms. The most typical finding is the presence of a palpable abdominal mass, although reported in only 46% of cases. OVT can be the cause of puerperal fever in approximately a third of women. Ultrasound Doppler is the first-line imaging, because of its safety, low cost, and wide availability. However, the ovarian veins are difficult to visualize in the presence of bowel meteorism or obesity. Thus, computed tomography or magnetic resonance imaging is often required to confirm the presence and extension of the thrombosis. In oncological patients, OVT is often an incidental finding at abdominal imaging. Mortality related to OVT is nowadays low due to the combination treatment of parenteral broad-spectrum antibiotics (until at least 48 hours after fever resolution) and anticoagulation (low-molecular-weight heparin, vitamin K antagonists, or direct oral anticoagulants). Anticoagulant treatment duration of 3 to 6 months has been recommended for postpartum OVT, while no anticoagulation has been suggested for incidentally detected cancer-associated OVT.

Keywords

- ▶ anticoagulants
- ▶ ovary
- ▶ venous thrombosis

Introduction

Ovarian vein thrombosis (OVT) is a type of unusual-site venous thromboembolism (VTE) involving the female gonadal veins. The ovarian veins originate in the pelvis from the ovarian venous plexus, which in turn communicates with the uterine venous plexus in the broad ligament of the uterus.^{1,2} They ascend into the abdominal cavity anterior to the psoas muscle and cross the ureters at the level of the third/fourth lumbar vertebra.³ The right ovar-

ian vein is a direct tributary of the inferior vena cava with an oblique angle of drainage, while the left ovarian vein drains into the left renal vein with a straight angle,⁴ as shown in **Fig. 1**.

The aim of this narrative review is to summarize the latest evidence on OVT. To identify the available literature, we searched MEDLINE through PubMed up to April 21, 2020, using the following keywords: (“ovarian vein thrombosis”) OR (“ovarian thrombosis”) OR (“ovarian venous thrombosis”) OR (“ovarian vein” AND “thrombosis”).

received

June 6, 2020

accepted after revision

November 6, 2020

© 2020. Thieme. All rights reserved.
Georg Thieme Verlag KG,
Rüdigerstraße 14,
70469 Stuttgart, Germany

DOI <https://doi.org/10.1055/a-1306-4327>.
ISSN 0720-9355.

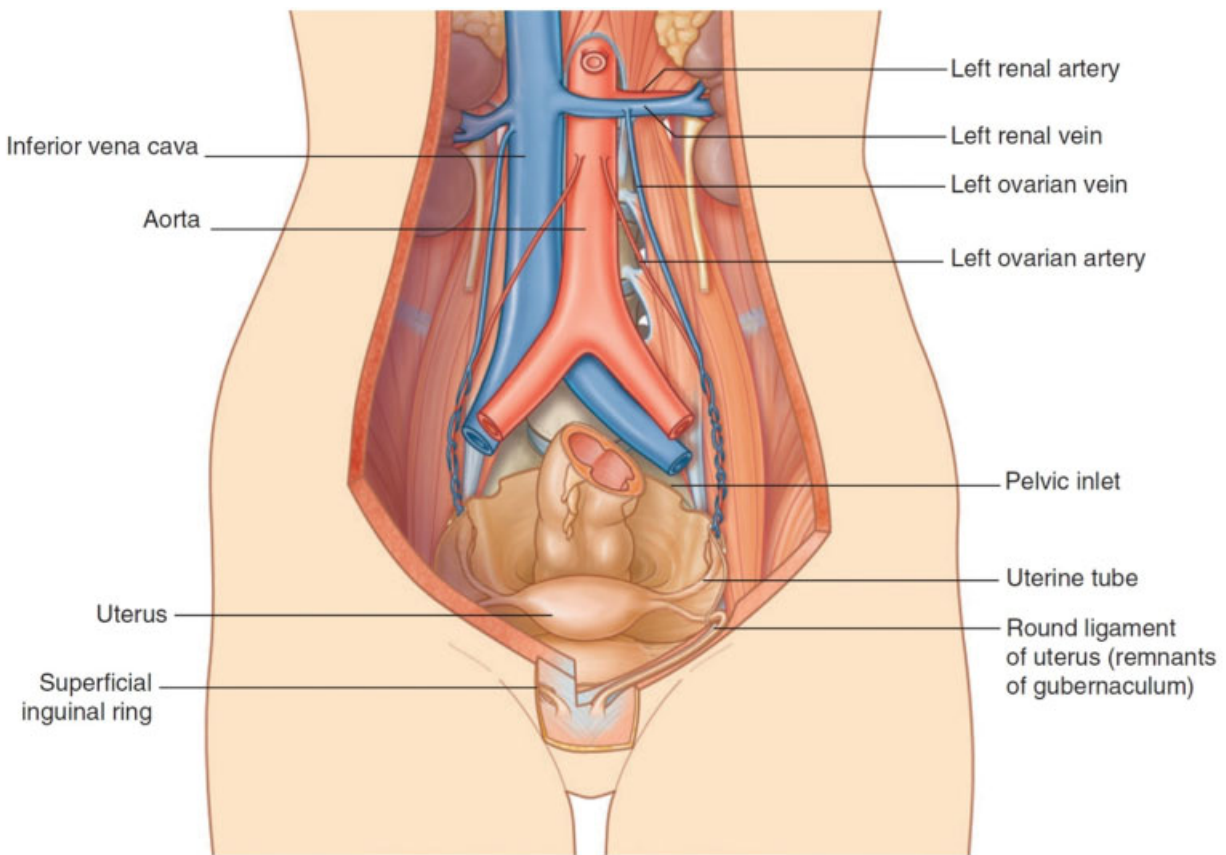


Fig. 1 Course of the ovarian veins in the female pelvis and abdomen. [This figure was published in Drake RL, Vogl AW, Mitchell AWM. Gray's Anatomy for Students, 4th edition, Chapter 4: Abdomen, page 266; Copyright © Elsevier (2020).] [rerif]

Epidemiology

OVT is a rare condition, which is around 60 times less common than lower limb deep vein thrombosis (DVT).⁵ However, it has been more frequently detected in recent years due to the widespread use of radiological imaging and its technical improvement.⁵

Most of the available information regards pregnancy-related OVT. Epidemiological data on other type of OVT are scarce, as well as precise estimates of its incidence and prevalence in the general population. OVT complicates approximately 0.01 to 0.18% of pregnancies^{6–8} and is more common after caesarean delivery than vaginal delivery.⁹ In a prospective study performed in the period 2004–2007, the incidence of OVT was 0.02% after vaginal delivery, 0.1% after caesarean section, and 0.67% when caesarean delivery was performed for a twin pregnancy.¹⁰ Postpartum OVT occurs with a peak around 2 to 6 days after delivery or miscarriage/abortion, and in 90% of women arises within 10 days.^{8,11,12}

Pregnancy-related OVT is usually diagnosed in women in their early thirties,^{8,13} while the other types of OVT involve older females with mean age ranging from 40 to 60 years in different studies.^{5,8,13,14} Due to the anatomical difference in venous drainage, the right ovarian vein is more frequently involved (70–80% of cases); occasionally, the thrombosis can be bilateral (around 10% of cases).^{7,9}

Pathophysiology and Risk Factors

The most common risk factors for OVT are pregnancy, estrogen-containing hormone treatment, malignancy, recent surgery, and pelvic infections, although with variable prevalence in different studies (–Table 1).

Pregnancy is a condition that predisposes to the development of VTE by acting on all the elements of the Virchow's triad, which forms the pathophysiological basis of venous thrombosis: hypercoagulability, venous stasis, and endothelial injury.¹⁵ There are several hemostatic changes in pregnancy leading to hypercoagulability, such as increased levels of procoagulant factors (e.g., fibrinogen; factors VII, VIII, and X; and von Willebrand factor), decreased levels of natural anticoagulants (e.g., reduced protein S activity and increased activated protein C resistance), and reduced fibrinolysis.^{16,17} Venous stasis can result from the increased blood flow in the ovarian veins during pregnancy (up to 60 times), associated with the vasodilatory effect of progesterone and the uterus compression on pelvic veins.¹⁸ The ovarian veins have minimal adventitial sheaths, which allow the increased capacity during pregnancy, but at the same time favor collapsibility if there is an external compression.¹⁹ Furthermore, the absence of ovarian vein valves has been reported in 6 to 15% of women.¹⁸ Finally, endothelial injury can occur during childbirth (both vaginal delivery and caesarean section),²⁰ but

Table 1 Risk factors for ovarian vein thrombosis in recent studies

	Gakhal et al ²¹	Labropoulos et al ³⁸	Mantha et al ¹⁴	Rottenstreich et al ⁶	Assal et al ¹³	Lenz et al ⁵	Covut et al ⁶⁶
Study design and population	Retrospective study of patients with OVT at a single center	Prospective study of patients with symptomatic OVT treated with anticoagulation, at 3 centers	Retrospective study of patients with OVT after surgical debulking for ovarian cancer at a single center	Retrospective study of patients with OVT at 3 centers	Retrospective study of patients with OVT at a single center	Case-control study of patients with OVT at a single center (controls were age-/sex-matched patients with DVT)	Retrospective study of patients with OVT treated with anticoagulation and with available follow-up imaging, at a single center
Timeframe	2003–2010	9-year period	2001–2010	2000–2015	2004–2014	1990–2015	2012–2018
No. of patients with OVT	26	23	41	74	223	219	36
Risk factors for OVT							
Pregnancy/puerperium	12%	39%	NR	81%	9%	12%	11%
Estrogen hormone treatment	NR	NR	NR	NR	NR	18%	6%
Malignancy	27%	26%	100%	1%	60%	44%	44%
Surgery	23%	NR	100%	45%	70%	26%	33%
Infections	4%	NR	NR	32%	NR	10%	NR
Trauma	NR	17%	NR	3%	NR	2%	NR
Recent hospitalization	NR	NR	NR	NR	NR	23%	NR
Inflammatory disease	4%	4%	NR	NR	NR	8%	17%
Thrombophilia	NR	9%	NR	24%	0%	14%	8%
Idiopathic OVT	12%	4%	0%	16%	NR	16%	8%

Abbreviations: DVT, deep vein thrombosis; NR, not reported; OVT, ovarian vein thrombosis.

also as a result of infections from the uterus (e.g., endometritis).²¹

Several anatomic and physiologic factors can explain the predominance of right OVT in pregnancy-related OVT: the right ovarian vein is frequently compressed at the pelvic brim by the physiological dextrorotation of the uterus during pregnancy²²; the longer length of the right ovarian vein, compared with the left, can more commonly result in valve incompetence²³; and the fact that the blood flow into the dilated ovarian veins decreases immediately after delivery.¹⁹ Furthermore, antegrade blood flow has been shown from the right ovarian vein into the inferior vena cava (which can favor thrombus extension),^{8,21} while retrograde flow has been reported from the left ovarian vein into the internal iliac vein (which can predispose to the formation of ovarian varicoceles and pelvic congestion syndrome).^{18,24}

Other hormonal factors have also been associated with the development of OVT, such as oral contraceptives and estrogen replacement therapy.^{5,25}

Malignancies associated with the development of OVT include mainly genitourinary cancers (such as ovarian or uterine tumors), followed by gastrointestinal cancers.^{5,13} Breast, lung, or hematologic cancers are less commonly reported.⁵ A study comparing risk factors between women with OVT and age-matched controls with lower extremity DVT found that cancer was twice more common in the first patient group (44% of OVT vs. 21% of DVT, $p < 0.01$).⁵

Cancer can also act on all three elements of the Virchow's triad.²⁶ The hypercoagulable state derives from the activation of coagulation (e.g., release of procoagulant tissue factor or microparticles by tumor cells; acquired protein C resistance) which can also lead to the development of disseminated intravascular coagulation.²⁷ Venous stasis can be due to compression of blood vessels by locally advanced tumors, while endothelial injury can result from vascular invasion by the growing tumor.²⁶ Concomitant factors, such as immobilization, chemotherapy, central venous catheters, and surgery, also contribute to the development of thrombosis.²⁷

OVT can be secondary to gynecologic or other pelvic surgery. For instance, it was described in 26% of patients undergoing debulking for ovarian cancer.¹⁴ OVT after unilateral salpingo-oophorectomy commonly occurred on the same side of the oophorectomy.¹³ In another study, OVT was an incidental finding in up to 80% of women undergoing abdominal surgery (total hysterectomy with bilateral salpingo-oophorectomy and retroperitoneal nodal dissection) for different gynecologic malignancies (ovarian, cervical, and endometrial cancer).²⁸ OVT can also occur after laparoscopic surgery, particularly in women with endometriosis and/or fibroids.^{29–31} Fibroids are likely to contribute to pressure, leading to stasis of blood flow, and endometriosis is responsible for an increase in a generalized pelvic inflammation.

Cases of OVT have also been reported in women with inflammatory disorders (e.g., inflammatory bowel diseases, appendicitis, diverticulitis, and pelvic inflammatory disease)²⁰ or thrombophilia (e.g., antiphospholipid syndrome, prothrombin G20210A or factor V Leiden mutations, and natural anticoagulant deficiency).^{5,8,10,32–34}

Since pelvic infection is another risk factor, OVT has also been described among septic pelvic thrombophlebitis.^{9,35} Pelvic infections (such as endometritis or chorioamnionitis) can be caused by Streptococci, Enterobacteriaceae, or anaerobes, and more frequently occur after caesarean delivery or other pelvic surgery.³⁶ However, in septic thrombophlebitis, blood cultures are typically negative and the causative microorganism can be identified in only 20 to 30 of cases.^{7,37}

Finally, 4 to 16% of OVT have no causative factor and these forms are classified as idiopathic OVT.^{5,8}

Clinical Features

The most common symptom of OVT is lower quadrant abdominal pain, usually on the side of the thrombosed vein.^{8,38} The pain may radiate to the flank, upper abdomen, or the groin.²² Acute abdominal tenderness can be noticed on physical examination. The most typical finding, although reported in only 46% of cases,⁷ is a palpable cord-like abdominal mass, extending from the ovary to the paracolic gutter and corresponding to the thrombosed ovarian vein.^{20,22} Nonspecific symptoms such as nausea, vomiting, anorexia, malaise, and ileus are reported, but they are usually mild.⁸

Patients with septic pelvic thrombophlebitis can manifest the typical triad of fever, pelvic pain, and palpable abdominal mass.^{39,40} Fever is usually spiking and associated with chills.³⁷

The presence of OVT has been evidenced in more than half of women with puerperal pelvic thrombophlebitis.⁴¹ Patients with OVT show earlier symptoms compared with those with thrombosis of the iliofemoral veins or inferior vena cava (the onset of symptoms is usually within 1 week in OVT vs. more than 2 weeks in the other thrombosis).⁴¹ Furthermore, septic pelvic thrombophlebitis is one of the causes of puerperal fever and OVT has been reported in approximately a third of women with puerperal fever.⁴²

In a multicenter study including 74 women with OVT of various etiology, 89% had acute onset, 7% had chronic symptoms, and 4% were asymptomatic.⁸ Asymptomatic OVT is common in oncological patients, in whom it might be an incidental finding on computed tomographic (CT) scans performed during follow-up.^{28,43} For instance, in the study by Yassa and Ryst, asymptomatic OVT was detected in 80% of patients undergoing cancer surgery.²⁸ Furthermore, there are some reports of incidental OVT after delivery. Two Canadian studies using magnetic resonance (MR) venography found asymptomatic postpartum thrombosis in pelvic veins (ovarian and/or iliac veins) in 30% of women at low VTE risk following vaginal delivery⁴⁴ and in 46% of women at moderate-high VTE risk following caesarean section.⁴⁵

Diagnosis

Diagnosis of OVT can be obtained using ultrasound (US) Doppler, CT, or MR. However, there is no definite consensus regarding the gold standard test, as only a few studies specifically evaluated sensitivity and specificity.^{42,46–48}

US Doppler is usually the first-line imaging, due to its safety, low cost, and wide availability. It can also be performed at the patient's bedside with the use of portable instruments. However, US is an operator-dependent imaging and can often be inconclusive, due to the presence of abdominal meteorism or obesity which interfere with the visualization of the ovarian veins.^{39,49} In a study evaluating its accuracy in 70 women after vaginal delivery, visualization of both ovarian veins was possible in 78.6%, one ovarian vein only in 17.1% and none in 4.3% of cases.⁵⁰ Thrombosis of the ovarian vein at US appears as an anechoic/hypoechoic mass located superiorly to the ovary and anteriorly to the psoas muscle.^{22,51} The thrombus can sometimes be seen as an intraluminal mass extending from the ovarian veins into the inferior vena cava or the renal vein. US Doppler shows decreased or absent flow in the ovarian vein, depending on whether the occlusion is partial or complete.^{49,52} In a systematic review, sensitivity of US has been reported in the range 50 to 100% and specificity in the range 41 to 99%.⁵³

CT scan (contrast-enhanced CT or CT venography) can better identify the presence and the extension of the thrombosis and is nowadays the reference imaging.^{39,49} However, CT involves the use of ionizing radiations and iodinated contrast medium, and possible contraindications include pregnancy, renal insufficiency, and previous contrast allergy. Typical findings of OVT on contrast-enhanced CT comprise dilation of the ovarian vein, enhancement of the vascular wall, and the presence of a low-density intraluminal filling defect (the Zerhouni criteria).^{11,49,54} The superior extension of the thrombus might be difficult to define precisely with CT scan due to the mixing effect between enhanced and non-enhanced blood at the level of the renal veins, which can give a false-positive image of filling defect in the inferior vena cava.⁴⁹ Sensitivity of CT has been reported to be 77 to 100% and specificity to be 62 to 99%.⁵³

MR does not use ionizing radiation or iodinated contrast medium; however, disadvantages include longer execution time, higher costs, and nonavailability for immediate use. Unenhanced MR can allow the direct visualization of the thrombus. In fact, the iron contained in the methaemoglobin molecules in the hypoxic erythrocytes entrapped into the thrombus has paramagnetic properties, thus acting as an endogenous contrast medium.^{55,56} On T1-weighted images, the thrombus can show low signal intensity (if acute) or high signal intensity (if subacute), while on T2-weighted images the thrombus can appear as an intermediate-high signal intensity at the center, surrounded by a low-intensity peripheral rim.^{21,49,56} The main characteristic of OVT on contrast-enhanced MR or MR venography is the lack of flow in the ovarian vein, which is usually associated with vein enlargement and wall thickening.^{21,39,49} Sensitivity of MR has been reported to be 92 to 100% and specificity approximately 100%⁵³; thus, MR is indicated when CT scan is inconclusive and the suspicion of OVT persists.^{39,49} However, the role of MR venography was recently questioned by two studies assessing the presence of pelvic vein thrombosis during postpartum and suggesting that some filling defects might be normal findings after vaginal or caesarean delivery.^{44,45}

Treatment

Treatment of OVT includes a combination of antibiotics and anticoagulation. According to the guidelines of the Canadian Society of Obstetricians and Gynaecologists addressing pregnancy-related VTE, parenteral broad-spectrum antibiotics should be commenced as soon as the diagnosis of OVT is confirmed and administered for at least 48 hours after fever resolution, considering longer duration in septicemic patients.⁵⁷ Furthermore, anticoagulation at therapeutic dose for 1 to 3 months is suggested.⁵⁷ The guidelines of the British Committee for Standards in Haematology recommend an anticoagulant treatment duration of 3 to 6 months for women with postpartum OVT and suggest no treatment for incidentally detected isolated OVT in cancer patients.⁵⁸

Broad-spectrum antibiotics are crucial if there is a concomitant infection.⁵³ For instance, in the study by Rottenstreich et al, 52.7% of women with OVT of various etiology received antibiotic therapy and patients with pregnancy-related OVT were more likely to receive antibiotics than those with non-pregnancy-related OVT (60 vs. 21.4%, $p = 0.007$).⁸

It is nowadays recognized that anticoagulation plays an important role in OVT^{53,57,59}; however, this concept has been debated for several years. There is only one randomized controlled trial, published in 1999, that evaluated the efficacy of heparin in OVT.⁹ In this study, 14 women with puerperal septic pelvic thrombophlebitis and involvement of the ovarian vein were randomized to antibiotic treatment alone ($n = 8$) or with the addition of intravenous unfractionated heparin ($n = 6$). There was no difference between the two groups in the mean duration of fever (140 vs. 134 hours, $p = 0.84$) or in the length of hospitalization (10.6 vs. 11.3 days, $p = n.s.$).⁹ There were no recurrent thrombotic events during the 3-month follow-up; however, the small sample size precluded the possibility to significantly assess differences in VTE recurrence.

The proportion of anticoagulated patients in the different studies was highly variable, ranging from 12 to 99% in unselected cohorts of OVT patients.^{5,8,13} Lenz et al described a cohort of 219 women with OVT assessed at the Mayo Clinic in the years 1990–2015, and found that they were less frequently anticoagulated than 220 age-matched women with leg DVT (54 vs. 98%, respectively, $p < 0.01$).⁵

Anticoagulation follows the principles of the management of usual-site VTE. In the study by Assal et al, 17 women with isolated OVT received parenteral anticoagulation in the acute phase, with either low-molecular-weight heparin (LMWH; $n = 13$) or unfractionated heparin ($n = 4$), and the majority of them (64.7%) were subsequently switched to vitamin K antagonists (VKAs).¹³ Conversely, in the study by Mantha et al, five women with cancer-associated OVT were treated with parenteral anticoagulation only,¹⁴ in line with guidelines for the treatment of cancer-associated DVT or pulmonary embolism (PE).⁶⁰ In the study by Salomon et al, 12 women with postpartum OVT received enoxaparin at therapeutic dose (1 mg/kg twice daily) for 2 weeks, followed by half-dose (1 mg/kg daily) for 3 months.¹⁰

Table 2 Case reports of women with ovarian vein thrombosis treated with the direct oral anticoagulants

Author	Age	Site OVT	Risk factors	Anticoagulant	Other treatment	Follow-up	Efficacy or safety outcomes
Cook et al ⁶⁷	30	Left OVT (extension into left renal vein)	Thrombophilia (factor V Leiden homozygosity) Combined oral contraceptive pill	Rivaroxaban 15 mg BID for 3 wk, followed by 20 mg OD indefinitely	Local thrombolysis (tPA) Angioplasty of the renal vein Unfractionated heparin for ~48 h	6 mo	Complete vessel recanalization No clinical events
Naoum et al ⁶⁸	36	Right OVT (extension into inferior vena cava)	Caesarean delivery Hysterectomy Obesity	Rivaroxaban 20 mg OD for 6 mo	Tinzaparin for a week	6 mo	Complete vessel recanalization No clinical events
Azhar et al ⁶⁹	30	Left OVT	Vaginal delivery Chorioamnionitis	Apixaban (no further details)	Antibiotics Enoxaparin for 3 d	NR	NR

Abbreviations: BID, twice daily; NR, not reported; OD, once daily; OVT, ovarian vein thrombosis; tPA, tissue plasminogen activator.

The novel direct oral anticoagulants (DOACs) were not specifically evaluated in patients with OVT, as unusual-site VTE was excluded from the large phase III randomized controlled trials evaluating their efficacy and safety in DVT and PE.^{61–64} However, small case series and case reports suggest that the DOACs are sometimes prescribed in this population. For instance, 5% of treated women in the study by Lenz et al received a direct factor Xa inhibitor,⁵ while the study by Janczak et al addressing the treatment of unusual-site VTE included eight patients with OVT treated with one of the DOACs.⁶⁵ Covut et al reported a retrospective cohort study of 36 women with OVT receiving different anticoagulant treatments: DOACs ($n = 10$), VKAs ($n = 11$), or LMWH ($n = 15$).⁶⁶ Although the timing of follow-up imaging was variable in the three groups, partial or complete recanalization occurred in 70% of women receiving DOACs, 55% of those receiving warfarin and 93% of those receiving enoxaparin.⁶⁶ However, given the lack of randomization, these results should be interpreted with caution and would need further confirmation in future studies. The published case reports^{67–69} on the treatment of OVT with the DOACs are summarized in **Table 2**. There is an ongoing collaborative registry on the use of the DOACs in unusual VTE, including OVT (www.clinicaltrials.gov registration NCT03778502).

Taken together, these data suggest that the anticoagulant treatment of OVT could be started with parenteral anticoagulation and the majority of patients could continue with oral anticoagulants. However, the VKAs cross the placenta and carry risks of fetal bleeding and teratogenicity; thus, they should be avoided during pregnancy (especially during the first and third trimesters), but they can be used during breastfeeding.⁷⁰ The DOACs cross the placenta and are also excreted into breast milk; thus, they are contraindicated both during pregnancy and breastfeeding.⁷¹ LMWH remains the drug of choice antenatally²⁴ and in cancer-associated OVT.

Anticoagulant treatment duration was variable in the different studies. The study by Lenz et al showed that

treatment duration in OVT was significantly shorter than lower extremities DVT (median: 3.0 vs. 5.7 months, $p = 0.02$).⁵ Furthermore, the study by Rottenreich et al evidenced a tendency toward shorter duration in women with pregnancy-related OVT compared with those with non-pregnancy-related OVT (3 vs. 6 months, $p = 0.1$).⁸ Expert opinions suggest a definite anticoagulant treatment duration of 3 months for symptomatic postpartum OVT.^{53,59} For non-pregnancy-related OVT, some authors⁶⁷ suggest to follow the general guidelines for the treatment of usual-site VTE⁶⁰ and prescribe anticoagulation for 3 months in patients with transient risk factors (e.g., infection, surgery) and longer duration in patients with persistent risk factors (e.g., cancer, severe thrombophilia). The best treatment strategies for asymptomatic isolated OVT are still debated, including the option of no anticoagulant treatment.⁵³

There are only a few studies reporting the risk of bleeding of OVT patients. Lenz et al reported similar rates of major bleeding between patients with OVT (2.1, 95% CI: 0.2–7.4, per 100 patient-years) and patients with DVT (2.3, 95% CI: 0.9–4.7, per 100 patient-years); however, only 54% of OVT patients received anticoagulation.⁵ In the study by Covut et al, the 1-year cumulative incidence of major bleeding was 0% in 10 women with OVT receiving DOACs, 13% in 11 women receiving VKA, and 9% in 15 women receiving LMWH.⁶⁶ However, the small sample size and the observational design limit the generalizability of these results (e.g., possible unbalanced baseline characteristics).

There are a few reports regarding the use of thrombolytic drugs (e.g., alteplase, urokinase).^{51,72} However, due to the associated high risk of bleeding, they should be reserved for selected cases of women with massive thrombosis. Retrieval inferior vena cava filters are indicated only when there are absolute contraindications to the anticoagulant treatment (e.g., active bleeding, undelayable surgery).^{22,24} Surgical treatments (e.g., ovarian vein excision or ligation) are rarely performed nowadays.⁷³

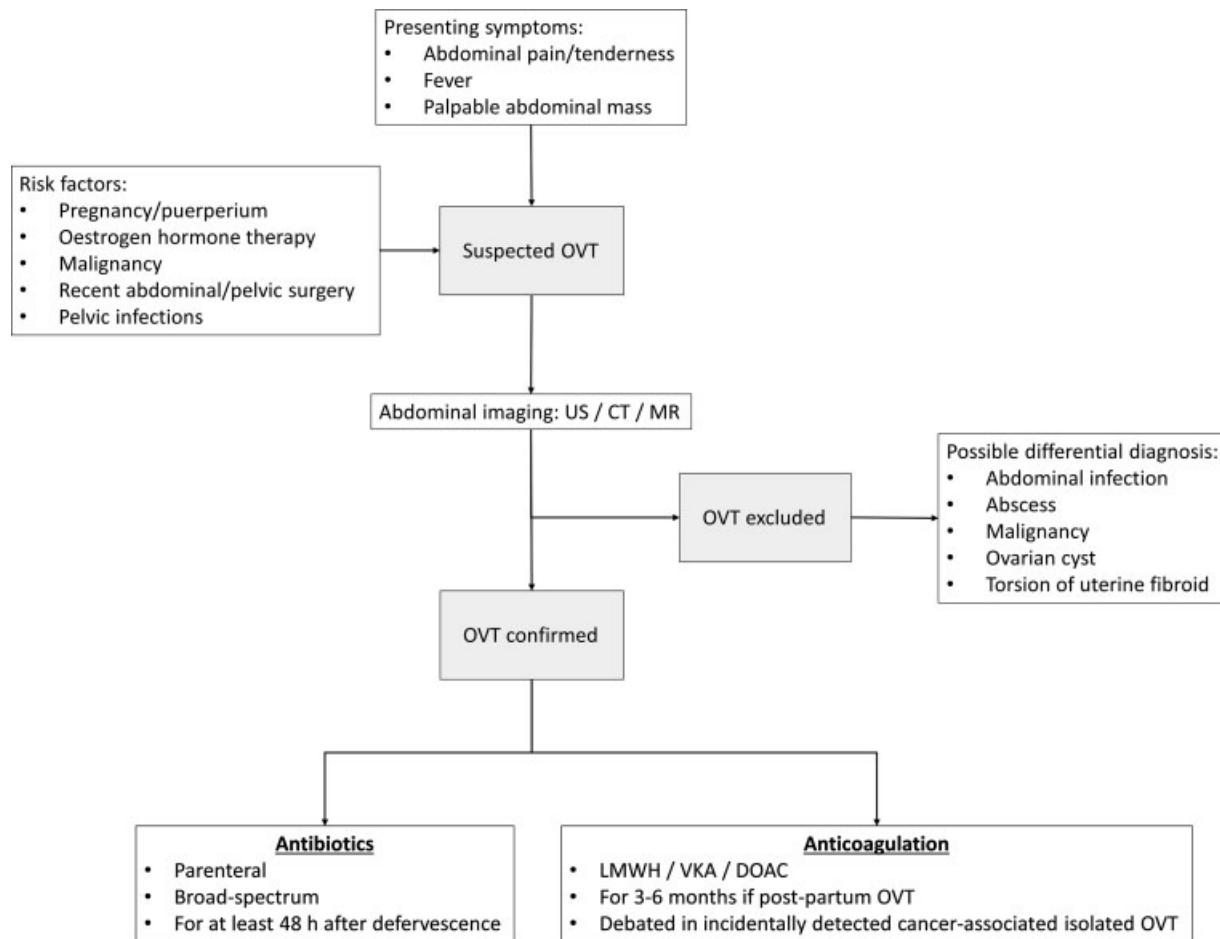


Fig. 2 Proposed approach to patients with suspected ovarian vein thrombosis. CT, computed tomography; DOAC, direct oral anticoagulant; LMWH, low-molecular-weight heparin; MR, magnetic resonance; OVT, ovarian vein thrombosis; US, ultrasound; VKA, vitamin K antagonist.

Prognosis

Possible complications described in patients with OVT include thrombus progression into the inferior vena cava (for right OVT) or into the left renal vein (for left OVT), PE, pelvic congestion syndrome, and recurrent VTE.^{5,13,14,38}

In approximately a quarter of patients, the thrombosis might have already extended into other veins at the time of diagnosis.⁸ A study evaluating 26 women with OVT reported extension into the left renal vein in 12% and into the inferior vena cava in 15%.²¹

Coexistence of PE was found in approximately 10% of women with OVT.^{5,8,38} It has been reported that PE is less common in OVT than lower limb DVT (being present in 6 vs. 16%, respectively, at the time of OVT diagnosis, $p = 0.001$).⁵ However, the presence of an acute PE during puerperium without any evidence of DVT in the lower limbs should raise the suspicion of OVT and prompt appropriate investigations.²¹

In the study by Labropoulos et al, 4 (17.4%) out of 23 women with symptomatic OVT developed recurrent VTE during a median follow-up of 2.3 years.³⁸ Pelvic congestion syndrome occurred in three (13.0%) patients, while mortality in four (17.4%) patients and was mainly due to underlying malignancy.³⁸

In the large cohort study by Assal et al, 22 (9.9%) out of 223 patients with OVT experienced recurrent VTE (18 episodes of DVT and 4 PE) during a median follow-up of 2.3 years.¹³ Overall survival was lower in patients with recurrent VTE compared with those without recurrent events ($p = 0.001$). The subanalysis considering only 199 patients with isolated OVT showed a nonsignificant trend toward lower recurrence rate in anticoagulated patients compared with women who did not receive anticoagulation (5.9 vs. 9.9%, respectively, $p = 0.59$).¹³

The large study by Lenz et al, including 219 consecutive women with OVT, reported VTE recurrence rates of 6.1% at 1-year and 14.3% at 5-year follow-up.⁵ There was no difference in the rates of recurrent VTE between patients with OVT and age-matched women with lower extremities DVT (2.3 vs. 1.8 patient-years, $p = 0.49$), despite only 54% of OVT patients were anticoagulated.⁵ However, while in the DVT group, recurrent thrombotic events were located mainly in usual venous sites (e.g., DVT, PE, inferior vena cava thrombosis), in patients with OVT several unusual venous sites were also involved (e.g., renal vein, portal vein, contralateral ovarian vein).⁵ No VTE recurrences were reported in patients with pregnancy-related or infection-related OVT.⁷⁴ The survival of both OVT and DVT women was decreased when compared with the general population.⁵ A previous study had reported

higher 5-year mortality rate in OVT versus DVT patients (43 vs. 20%, $p = 0.08$), mainly due to underlying malignancies.²⁵

The study by Mantha et al, which enrolled oncological patients undergoing debulking surgery for ovarian cancer, showed that the incidence of VTE at 1-year follow-up was not significantly different between women who developed OVT and women who did not developed OVT (17.1 vs. 15.3%, respectively, $p = 0.78$).¹⁴ One-year survival rate was also similar in the two groups (95.1 vs. 93.2%, $p = 0.84$).¹⁴

Rare complications of OVT include ovarian infarction with potential influence on fertility,²⁴ and obstruction of the right ureter which can lead to hydronephrosis and renal failure.^{75,76}

Septic pelvic thrombophlebitis can also evolve into septic shock or septic emboli, which have high mortality rate.³⁵ However, with the use of antibiotics and anticoagulants, mortality due to OVT is nowadays less than 5%.^{22,75}

Conclusion

OVT is a rare disorder which has been described mainly during postpartum, after pelvic surgery or in women with gynecological malignancies. Clinical features of OVT include abdominal pain and tenderness, palpable abdominal mass, and fever, combined with nonspecific gastrointestinal symptoms. Since OVT is one of the causes of puerperal fever, it should be suspected in women with pelvic abdominal pain and fever within a week after delivery, especially if they had a caesarean section.

US Doppler is usually the first-line imaging, as it can be easily performed for the evaluation of abdominal pain or puerperal fever. However, CT or MR is suggested to confirm the presence and extension of OVT, because US can often be inconclusive. In women with non-pregnancy-related OVT, abdominal imaging can also serve as screening for a local occult cancer. There is no consensus regarding laboratory tests for thrombophilia, given the rarity of thrombophilia-related OVT.

Mortality is nowadays low, due to a treatment combination of parenteral broad-spectrum antibiotics and anticoagulation. Anticoagulant treatment duration of 3 to 6 months has been recommended for postpartum OVT, while no anticoagulation has been suggested for incidentally detected cancer-associated OVT. Evidence is lacking on the optimal management of other types of OVT. An algorithm to approach patients with suspected OVT is proposed in **Fig. 2**.

Conflict of Interest

The authors declare that they have no conflict of interest.

References

- Drake RL, Vogl AW, Mitchell AWM. Gray's Anatomy for Students, 4th ed. Canada: Elsevier; 2020
- Karaosmanoglu D, Karcaaltincaba M, Karcaaltincaba D, Akata D, Ozmen M. MDCT of the ovarian vein: normal anatomy and pathology. *AJR Am J Roentgenol* 2009;192(01):295–299
- Bhutta HY, Walsh SR, Tang TY, Walsh CA, Clarke JM. Ovarian vein syndrome: a review. *Int J Surg* 2009;7(06):516–520
- Gupta R, Gupta A, Aggarwal N. Variations of gonadal veins: embryological prospective and clinical significance. *J Clin Diagn Res* 2015;9(02):AC08–AC10
- Lenz CJ, Wysokinski WE, Henkin S, et al. Ovarian vein thrombosis: incidence of recurrent venous thromboembolism and survival. *Obstet Gynecol* 2017;130(05):1127–1135
- Brown TK, Munsick RA. Puerperal ovarian vein thrombophlebitis: a syndrome. *Am J Obstet Gynecol* 1971;109(02):263–273
- Dunnihoo DR, Gallaspy JW, Wise RB, Otterson WN. Postpartum ovarian vein thrombophlebitis: a review. *Obstet Gynecol Surv* 1991;46(07):415–427
- Rottenstreich A, Da'as N, Kleinstern G, Spectre G, Amsalem H, Kalish Y. Pregnancy and non-pregnancy related ovarian vein thrombosis: clinical course and outcome. *Thromb Res* 2016;146:84–88
- Brown CE, Stettler RW, Twickler D, Cunningham FG. Puerperal septic pelvic thrombophlebitis: incidence and response to heparin therapy. *Am J Obstet Gynecol* 1999;181(01):143–148
- Salomon O, Dulitzky M, Apter S. New observations in postpartum ovarian vein thrombosis: experience of single center. *Blood Coagul Fibrinolysis* 2010;21(01):16–19
- Klima DA, Snyder TE. Postpartum ovarian vein thrombosis. *Obstet Gynecol* 2008;111(2, Pt 1):431–435
- Aguilar S, Cunha V, Martins L, Colaço J, Nunes F, Kayryakova M. Ovarian vein thrombosis: a case report. *Int J Med Rev Case Rep* 2019;3(08):494–498
- Assal A, Kaner JD, Danda N, Cohen HW, Billett HH. Risk factors and prognosis of ovarian vein thrombosis. *Blood Coagul Fibrinolysis* 2017;28(06):468–474
- Mantha S, Sarasohn D, Ma W, et al. Ovarian vein thrombosis after debulking surgery for ovarian cancer: epidemiology and clinical significance. *Am J Obstet Gynecol* 2015;213(02):208.e1–208.e4
- Virchow R. Thrombose und embolie. *Gefässentzündung und septische infektion. Gesammelte Abhandlungen zur wissenschaftlichen Medicin Frankfurt am Main: Von Meidinger & Sohn; 1856:219–732*
- Villani M, Ageno W, Grandone E, Dentali F. The prevention and treatment of venous thromboembolism in pregnancy. *Expert Rev Cardiovasc Ther* 2017;15(05):397–402
- Brenner B. Haemostatic changes in pregnancy. *Thromb Res* 2004;114(5-6):409–414
- Osman MW, Nikolopoulos I, Jayaprakasan K, Raine-Fenning N. Pelvic congestion syndrome. *Obstet Gynaecol* 2013;15:151–157
- Rooholamini SA, Au AH, Hansen GC, et al. Imaging of pregnancy-related complications. *Radiographics* 1993;13(04):753–770
- Virmani V, Kaza R, Sadaf A, Fasih N, Fraser-Hill M. Ultrasound, computed tomography, and magnetic resonance imaging of ovarian vein thrombosis in obstetrical and nonobstetrical patients. *Can Assoc Radiol J* 2012;63(02):109–118
- Gakhil MS, Levy HM, Spina M, Wrigley C. Ovarian vein thrombosis: analysis of patient age, etiology, and side of involvement. *Del Med J* 2013;85(02):45–50, quiz 59
- Kominiarek MA, Hibbard JU. Postpartum ovarian vein thrombosis: an update. *Obstet Gynecol Surv* 2006;61(05):337–342
- Durham JD, Machan L. Pelvic congestion syndrome. *Semin Intervent Radiol* 2013;30(04):372–380
- Dougan C, Phillips R, Harley I, Benson G, Anbazhagan A. Postpartum ovarian vein thrombosis. *Obstet Gynaecol* 2016;18:291–299
- Wysokinska EM, Hodge D, McBane RD II. Ovarian vein thrombosis: incidence of recurrent venous thromboembolism and survival. *Thromb Haemost* 2006;96(02):126–131
- Rickles FR, Falanga A. Activation of clotting factors in cancer. *Cancer Treat Res* 2009;148:31–41
- Falanga A, Marchetti M, Vignoli A. Coagulation and cancer: biological and clinical aspects. *J Thromb Haemost* 2013;11(02):223–233
- Yassa NA, Ryst E. Ovarian vein thrombosis: a common incidental finding in patients who have undergone total abdominal

- hysterectomy and bilateral salpingo-oophorectomy with retroperitoneal lymph node dissection. *AJR Am J Roentgenol* 1999;172(01):45–47
- 29 Gupta A, Gupta N, Blankstein J, Trester R. Ovarian vein thrombosis as a complication of laparoscopic surgery. *Case Rep Obstet Gynecol* 2015;2015:682941
 - 30 Tanaka Y, Kato H, Hosoi A, Isobe M, Koyama S, Shiki Y. Ovarian vein thrombosis following total laparoscopic hysterectomy. *Asian J Endosc Surg* 2012;5(04):179–182
 - 31 Al-Achmar SN, Stavrou S, Protopapas A, Drakakis P, Siemou P, Chatzipapas I. Ovarian vein thrombosis after total laparoscopic hysterectomy with unilateral adnexectomy: a case report. *Int J Surg Case Rep* 2017;41:1–4
 - 32 Drozdinsky G, Hadar E, Shmueli A, Gabbay-Benziv R, Shiber S. Obstetric antiphospholipid syndrome and long term arterial thrombosis risk. *J Thromb Thrombolysis* 2017;44(03):371–375
 - 33 André M, Delèveaux I, Amoura Z, et al. Ovarian vein thrombosis in the antiphospholipid syndrome. *Arthritis Rheum* 2004;50(01):183–186
 - 34 Salomon O, Apter S, Shaham D, et al. Risk factors associated with postpartum ovarian vein thrombosis. *Thromb Haemost* 1999;82(03):1015–1019
 - 35 Valerio L, Riva N. Head, neck and abdominopelvic septic thrombophlebitis: current evidence and challenges in diagnosis and treatment. *Hamostaseologie* 2020;40(03):301–310
 - 36 Dotters-Katz SK, Smid MC, Grace MR, Thompson JL, Heine RP, Manuck T. Risk factors for postpartum septic pelvic thrombophlebitis: a multicenter cohort. *Am J Perinatol* 2017;34(11):1148–1151
 - 37 Garcia J, Aboujaoude R, Apuzzio J, Alvarez JR. Septic pelvic thrombophlebitis: diagnosis and management. *Infect Dis Obstet Gynecol* 2006;2006:15614
 - 38 Labropoulos N, Malgor RD, Comito M, Gasparis AP, Pappas PJ, Tassiopoulos AK. The natural history and treatment outcomes of symptomatic ovarian vein thrombosis. *J Vasc Surg Venous Lymphat Disord* 2015;3(01):42–47
 - 39 Sinha D, Yasmin H, Samra JS. Postpartum inferior vena cava and ovarian vein thrombosis—a case report and literature review. *J Obstet Gynaecol* 2005;25(03):312–313
 - 40 Akinbiyi AA, Nguyen R, Katz M. Postpartum ovarian vein thrombosis: two cases and review of literature. *Case Rep Med* 2009;2009:101367
 - 41 Brown CE, Lowe TW, Cunningham FG, Weinreb JC. Puerperal pelvic thrombophlebitis: impact on diagnosis and treatment using x-ray computed tomography and magnetic resonance imaging. *Obstet Gynecol* 1986;68(06):789–794
 - 42 Kubik-Huch RA, Hebisch G, Huch R, Hilfiker P, Debatin JF, Krestin GP. Role of duplex color Doppler ultrasound, computed tomography, and MR angiography in the diagnosis of septic puerperal ovarian vein thrombosis. *Abdom Imaging* 1999;24(01):85–91
 - 43 Jacoby WT, Cohan RH, Baker ME, Leder RA, Nadel SN, Dunnick NR. Ovarian vein thrombosis in oncology patients: CT detection and clinical significance. *AJR Am J Roentgenol* 1990;155(02):291–294
 - 44 Khalil H, Avruch L, Olivier A, Walker M, Rodger M. The natural history of pelvic vein thrombosis on magnetic resonance venography after vaginal delivery. *Am J Obstet Gynecol* 2012;206(04):356.e1–356.e4
 - 45 Rodger MA, Avruch LI, Howley HE, Olivier A, Walker MC. Pelvic magnetic resonance venography reveals high rate of pelvic vein thrombosis after cesarean section. *Am J Obstet Gynecol* 2006;194(02):436–437
 - 46 Giraud JR, Poulain P, Renaud-Giono A, et al. Diagnosis of postpartum ovarian vein thrombophlebitis by color Doppler ultrasonography: about 10 cases. *Acta Obstet Gynecol Scand* 1997;76(08):773–778
 - 47 Hadas-Halpern I, Patlas M, Fisher D. Postpartum ovarian vein thrombophlebitis: sonographic diagnosis. *Abdom Imaging* 2002;27(01):93–95
 - 48 Twickler DM, Setiawan AT, Evans RS, et al. Imaging of puerperal septic thrombophlebitis: prospective comparison of MR imaging, CT, and sonography. *AJR Am J Roentgenol* 1997;169(04):1039–1043
 - 49 Sharma P, Abdi S. Ovarian vein thrombosis. *Clin Radiol* 2012;67(09):893–898
 - 50 Smith MD, Felker RE, Emerson DS, Livingston JC, Egerman RS. Sonographic visualization of ovarian veins during the puerperium: an assessment of efficacy. *Am J Obstet Gynecol* 2002;186(05):893–895
 - 51 Lee EH, Im CY, Kim JW. Ultrasound diagnosis of postpartum ovarian vein thrombosis: case report. *Ultrasound Obstet Gynecol* 2001;18(04):384–386
 - 52 Savader SJ, Otero RR, Savader BL. Puerperal ovarian vein thrombosis: evaluation with CT, US, and MR imaging. *Radiology* 1988;167(03):637–639
 - 53 Bannow BTS, Skeith L. Diagnosis and management of postpartum ovarian vein thrombosis. *Hematology (Am Soc Hematol Educ Program)* 2017;2017(01):168–171
 - 54 Vandermeer FQ, Wong-You-Cheong JJ. Imaging of acute pelvic pain. *Clin Obstet Gynecol* 2009;52(01):2–20
 - 55 Kelly J, Hunt BJ, Moody A. Images in cardiovascular medicine. Deep vein thrombosis demonstrated by magnetic resonance direct thrombus imaging. *Circulation* 2003;107(16):2165
 - 56 Bilgin M, Sevket O, Yildiz S, Sharifov R, Kocakoc E. Imaging of postpartum ovarian vein thrombosis. *Case Rep Obstet Gynecol* 2012;2012:134603
 - 57 Chan WS, Rey E, Kent NE, et al;VTE in Pregnancy Guideline Working Group Society of Obstetricians and Gynecologists of Canada. Venous thromboembolism and antithrombotic therapy in pregnancy. *J Obstet Gynaecol Can* 2014;36(06):527–553
 - 58 Tait C, Baglin T, Watson H, et al;British Committee for Standards in Haematology. Guidelines on the investigation and management of venous thrombosis at unusual sites. *Br J Haematol* 2012;159(01):28–38
 - 59 Abbattista M, Capecci M, Martinelli I. Treatment of unusual thrombotic manifestations. *Blood* 2020;135(05):326–334
 - 60 Kearon C, Akl EA, Ornelas J, et al. Antithrombotic therapy for VTE disease: CHEST guideline and expert panel report. *Chest* 2016;149(02):315–352
 - 61 Bauersachs R, Berkowitz SD, Brenner B, et al;EINSTEIN Investigators. Oral rivaroxaban for symptomatic venous thromboembolism. *N Engl J Med* 2010;363(26):2499–2510
 - 62 Agnelli G, Buller HR, Cohen A, et al;AMPLIFY Investigators. Oral apixaban for the treatment of acute venous thromboembolism. *N Engl J Med* 2013;369(09):799–808
 - 63 Schulman S, Kearon C, Kakkar AK, et al;RE-COVER Study Group. Dabigatran versus warfarin in the treatment of acute venous thromboembolism. *N Engl J Med* 2009;361(24):2342–2352
 - 64 Büller HR, Décousus H, Grosso MA, et al;Hokusai-VTE Investigators. Edoxaban versus warfarin for the treatment of symptomatic venous thromboembolism. *N Engl J Med* 2013;369(15):1406–1415
 - 65 Janczak DT, Mimier MK, McBane RD, et al. Rivaroxaban and apixaban for initial treatment of acute venous thromboembolism of atypical location. *Mayo Clin Proc* 2018;93(01):40–47
 - 66 Covut F, Kewan T, Perez O, et al. Direct oral anticoagulants versus warfarin and enoxaparin in ovarian vein thrombosis. *Am J Ther* 2019; (epub ahead of print). Doi: 10.1097/MJT.0000000000001084
 - 67 Cook RM, Rondina MT, Horton DJ. Rivaroxaban for the long-term treatment of spontaneous ovarian vein thrombosis caused by factor V Leiden homozygosity. *Ann Pharmacother* 2014;48(08):1055–1060
 - 68 Naoum J, Mohsen A, Daher J, Eid T. Novel management of ovarian vein thrombosis: a case report. *Saudi Pharm J* 2018;26(05):608–610
 - 69 Azhar E, Nguyen T, Waheed A. Left ovarian vein thrombosis presenting as acute postpartum pyelonephritis. *Cureus* 2020;12(02):e6854

- 70 Bates SM, Greer IA, Middeldorp S, Veenstra DL, Prabulos AM, Vandvik PO. VTE, thrombophilia, antithrombotic therapy, and pregnancy: Antithrombotic Therapy and Prevention of Thrombosis, 9th ed: American College of Chest Physicians Evidence-Based Clinical Practice Guidelines. *Chest* 2012;141(2, Suppl):e691S–e736S
- 71 Cohen H, Arachchilage DR, Middeldorp S, Beyer-Westendorf J, Abdul-Kadir R. Management of direct oral anticoagulants in women of childbearing potential: guidance from the SSC of the ISTH. *J Thromb Haemost* 2016;14(08):1673–1676
- 72 Acharya G, Singh K, Hansen JB, Kumar S, Maltau JM. Catheter-directed thrombolysis for the management of postpartum deep venous thrombosis. *Acta Obstet Gynecol Scand* 2005;84(02):155–158
- 73 Josey WE, Staggers SR Jr. Heparin therapy in septic pelvic thrombophlebitis: a study of 46 cases. *Am J Obstet Gynecol* 1974;120(02):228–233
- 74 Lenz CJ, Wysokinski WE, McBane RD. In reply. *Obstet Gynecol* 2018;131(04):741–742
- 75 Al-toma A, Heggelman BG, Kramer MH. Postpartum ovarian vein thrombosis: report of a case and review of literature. *Neth J Med* 2003;61(10):334–336
- 76 Kolluru A, Lattupalli R, Kanwar M, Behera D, Kamalakannan D, Beeai MK. Postpartum ovarian vein thrombosis presenting as ureteral obstruction. *BMJ Case Rep* 2010;2010:bcr0320102863