

# Gastric metaplasia of the duodenal mucosa in Crohn's disease: novel histological and endoscopic findings



## Authors

Go Ikezono<sup>1</sup>, Kenshi Yao<sup>1</sup>, Kentaro Imamura<sup>1</sup>, Takao Kanemitsu<sup>1</sup>, Masaki Miyaoka<sup>1</sup>, Akikazu Hirano<sup>1</sup>, Kazuhiro Takeda<sup>1</sup>, Takashi Hisabe<sup>1</sup>, Toshiharu Ueki<sup>1</sup>, Hiroshi Tanabe<sup>2</sup>, Atsuko Ota<sup>2</sup>, Seiji Haraoka<sup>2</sup>, Akinori Iwashita<sup>2</sup>

## Institutions

- 1 Department of Endoscopy, Fukuoka University Chikushi Hospital
- 2 Department of Pathology, Fukuoka, University Chikushi Hospital

submitted 1.7.2020

accepted after revision 8.10.2020

## Bibliography

Endoscopy International Open 2021; 09: E181–E189

DOI 10.1055/a-1313-7239

ISSN 2364-3722

© 2021. The Author(s).

This is an open access article published by Thieme under the terms of the Creative Commons Attribution-NonDerivative-NonCommercial License, permitting copying and reproduction so long as the original work is given appropriate credit. Contents may not be used for commercial purposes, or adapted, remixed, transformed or built upon. (<https://creativecommons.org/licenses/by-nc-nd/4.0/>)

Georg Thieme Verlag KG, Rüdigerstraße 14,  
70469 Stuttgart, Germany

## Corresponding author

Kenshi Yao, MD, PhD, Department of Endoscopy, Fukuoka University Chikushi Hospital, Zokumyoin, Chikushino City, Fukuoka 818-8502, Japan  
Fax: +81-(0)92-929-2630  
yao@fukuoka-u.ac.jp

## ABSTRACT

**Background and study aims** Upper gastrointestinal endoscopy and biopsy are useful for differential diagnosis of Crohn's disease (CD) of the large intestine and ulcerative colitis (UC). We aimed to identify novel histopathological and endoscopic findings in the upper gastrointestinal tract in patients with CD who did not have *Helicobacter pylori* infection.

**Patients and methods** Upper gastrointestinal endoscopy was performed on patients with CD and UC. Mucosal lesions detected were subsequently observed using magnifying endoscopy with narrow-band imaging (M-NBI), following which biopsy was performed. When no mucosal lesion was detected on conventional endoscopy, M-NBI and biopsy were performed on four sites: the gastric body, gastric antrum, duodenal bulb, and second portion of the duodenum.

**Results** The prevalences of gastric metaplasia (GM) were 48% (24/50) and 16% (8/50) in the CD and UC groups, showing a significant difference ( $P=0.001$ ). In 23 of 24 patients with histologically proven GM in the CD group, mucosal lesions were detected using conventional white-light imaging (C-WLI). In 22 of 24 patients with histologically proven GM in the CD group, disappearance of normal villous structure and the presence of curved marginal crypt epithelium were noted using magnifying endoscopic findings characteristic of GM (M-GM). A combination of C-WLI and M-NBI yielded a significantly increased specificity ( $P=0.004$ ) and accuracy ( $P=0.039$ ).

**Conclusions** The prevalence of GM in the duodenal mucosa was significantly higher in patients with CD than in controls. The identified endoscopic findings may be useful as novel indicators for the histological diagnosis of GM in the duodenum.

## Introduction

Chronic inflammatory bowel diseases are broadly classified into Crohn's disease (CD) and ulcerative colitis (UC). CD is characterized by upper gastrointestinal lesions [1–4]. In addition, the characteristic histological findings of CD have been reported to include noncaseating epithelioid granulomas [5] and the pres-

ence of focally enhanced gastritis in the gastric mucosa without *Helicobacter pylori* (HP) infection [6]. These characteristic endoscopic and histological findings of the upper gastrointestinal mucosa in CD are useful in the differential diagnosis of CD of the large intestine and UC [1–4]. However, the detection rate for noncaseating epithelioid granuloma based on histological examination of biopsy specimens collected during upper gas-

trointestinal endoscopy has been decreasing in recent years according to our recent experience. In our experience of evaluating the histopathological findings of endoscopically biopsied specimens from the gastroduodenal mucosa of patients with CD, we have frequently detected gastric metaplasia (GM) in the duodenum and intestinal metaplasia in the stomach. Further, a previous study has reported that GM in the duodenum is one of the characteristic histological findings of CD, distinguishing it from Behçet's disease [7]. However, whether these histologic findings can serve as markers for differentiating CD from UC has not yet been investigated. Thus, it may be meaningful to identify novel histological and endoscopic indicators that could serve as useful novel markers for the differential diagnosis of CD and UC. We designed and conducted a study to identify the characteristic histopathological findings in the upper gastrointestinal tract and the characteristic endoscopic findings in the upper gastrointestinal mucosa in patients with CD who do not have HP infection.

## Patients and methods

In this retrospective study, we enrolled 50 consecutive patients with CD who underwent upper gastrointestinal endoscopy with a magnifying endoscope in the Department of Gastroenterology, Fukuoka University Chikushi Hospital, between April 2018 and March 2020. Consecutive 50 Patients with UC during the same period were included as controls.

### Inclusion criteria

Inclusion criteria were as follows: 1. Use of upper gastrointestinal endoscopy with a magnifying endoscope for diagnosing CD or UC; 2. Absence of HP infection, defined as presence of endoscopic findings characteristic of an HP-uninfected stomach [8, 9], absence of a history of HP eradication, and negative results on at least two diagnostic tests for HP infection (HP immunoglobulin G antibody test, urea breath test, stool antigen test, rapid urease test, culture of biopsy specimens, and microscopy of biopsy specimens); 3. Eastern Cooperative Oncology Group performance status score of 0 or 1 [10].

### Exclusion criteria

Exclusion criteria were as follows: An indication of endoscopy for diagnosing an upper gastrointestinal hemorrhage, post-operative stomach or reconstruction of a gastric tube, presence of a serious underlying disease, presence of concurrent psychiatric diseases or symptoms that would make participation in the study difficult, participation deemed inappropriate by the principal investigator or sub-investigators.

### Endoscopic procedures and biopsy

A specialist in Gastrointestinal Endoscopy certified by the Japanese Gastroenterological Endoscopy Society or an equally qualified endoscopist with more than 10 years of experience in endoscopy performed the procedures.

In this study, endoscopy was performed as follows. First, conventional white-light imaging (C-WLI) was performed to determine the presence or absence of mucosal lesions. When

C-WLI revealed mucosal lesions, M-NBI was performed, and target biopsies at the observation sites were performed. When no mucosal lesion was detected, magnifying endoscopy with narrow-band imaging (M-NBI) and biopsy of the gastric body, gastric antrum, duodenal bulb, and second portion of the duodenum were randomly performed.

### Histopathological assessment

Biopsy specimens were fixed in 20% formalin and embedded in paraffin. Sections of the specimens were stained with hematoxylin and eosin (HE) and Alcian blue-periodic acid Schiff (AB-PAS) stain. We examined histopathological characteristics in these stained specimens.

### Histopathological definition of gastric metaplasia in the duodenum

Replacement of the absorptive epithelium of the small intestine with the gastric crypt epithelium on HE staining was used to define GM. In addition, intense staining of the entire cells and reddish-purple staining of the mucosal epithelium replaced with the gastric crypt epithelium on AB-PAS staining were performed to confirm GM [11, 12]. Ectopic gastric mucosa associated with proper gastric glands were not used to define GM in this study.

### Histopathological definition of intestinal metaplasia in the stomach

Intestinal metaplasia was defined as the presence of goblet cells in the gastric epithelium on HE staining, which were stained blue with the AB-PAS stain.

### Review of endoscopic findings

An independent endoscopist who was unaware of the patients' histopathological findings reviewed the endoscopic findings (C-WLI and M-NBI). In this study, endoscopic findings of C-WLI were classified by color (red, normal, and pale) and morphology (protruded, flat, depressed). As for the endoscopic M-NBI findings, the anatomical findings visualized by M-NBI were analyzed.

### Endpoints

The primary endpoint involved the characteristic histopathological findings of the upper gastrointestinal tract in patients with CD who did not have HP infection. The secondary endpoints included the following: Prevalence of mucosal lesions and characteristic endoscopic findings; prevalence of mucosal lesions exhibiting GM; magnifying endoscopic findings characteristic of gastric metaplasia (M-GM); diagnostic performances (sensitivity, specificity, and accuracy) of C-WLI and C-WLI+M-NBI in the detection of GM; prevalence of GM in the duodenum according to the presence or absence of a bamboo joint-like appearance and duodenal notch; and prevalence of histologically proven GM and M-GM by the type of CD.

► **Table 1** Patient characteristics.

	Crohn's disease (n=50)	Ulcerative colitis (n=50)	P value
Age (years) (mean ± SD)	37.8 ± 15.0	41.9 ± 16.1	0.189 <sup>1</sup>
Sex (male/female)	33/17	28/22	0.412 <sup>2</sup>
Disease duration (month) (mean ± SD)	144.3 ± 135.4	98.9 ± 112.2	0.071 <sup>1</sup>

SD, standard deviation.  
<sup>1</sup> Student's *t*-test  
<sup>2</sup> Fisher's exact test

► **Table 2** Histological findings in the duodenal mucosa.

	Crohn's disease (n=50)	Ulcerative colitis (n=50)	P value
Gastric metaplasia	24 (48%)	8 (16%)	0.001
Noncaseating granuloma	1 (2%)	0 (0%)	n.s.
No specific findings	25 (50%)	42 (84%)	n.s.

n.s., not significant; Fisher's exact test.

## Interobserver and intraobserver agreement

Endoscopic images taken by C-WLI and M-NBI of 50 patients with CD and 50 patients with UC were obtained to test interobserver agreement. The images were arranged in random order. First, to determine interobserver agreement, two independent endoscopists with 14 (K. I.) and 10 years (G. I.) of experience in gastric endoscopy were asked to review all images and determine whether each image showed the presence or absence of mucosal lesions (C-WLI) and M-GM (M-NBI) [13]. To determine intraobserver agreement, the first endoscopist was asked to review all the images 2 weeks later and to determine whether each image showed the presence or absence of mucosal lesions and M-GM [13].

## Statistical analysis

Comparisons between the two groups were performed using Fisher's exact test, McNemar's test, and Bonferroni correction, while a comparison of mean values between the groups was performed using an unpaired Student's *t*-test.  $P < 0.05$  was considered to indicate statistical significance in all tests. Kappa values were calculated for interobserver and intraobserver agreement. Agreement was classified as excellent for  $\geq 0.8$ ; good for  $< 0.8$  to  $\geq 0.6$ ; moderate for  $< 0.6$  to  $\geq 0.4$ ; and fair for  $< 0.4$ . SPSS version 21 J for Windows (SPSS, Chicago, Illinois, United States).

## Ethical considerations

This study was conducted in accordance with the 1964 Declaration of Helsinki and its subsequent amendments. Written informed consent was obtained from each patient. Personal information listed in the medical records or obtained through questionnaire surveys, including data on informed consent, was managed in a database such that individual data were anonymized. This study was approved by the institutional

review board of Fukuoka University Chikushi Hospital (C20-01-006).

## Results

There were no significant differences in age, sex, or medical history between the CD and UC groups (► **Table 1**). In the CD group, based on the Crohn's Disease Activity Index, the disease activity level was assessed as inactive in 34 patients, active in 15, and severe in one; the distribution of the disease type was as follows: the small and large intestines in 33 patients, small intestine in eight, and large intestine in nine. In the UC group, based on the Sutherland Index, the disease activity was assessed as mild in 28 patients, moderate in 20, and severe in two; the distribution of the disease type was as follows: the pancolitis type in 37 patients, left colitis type in 10, and proctitis type in three.

## Primary endpoint

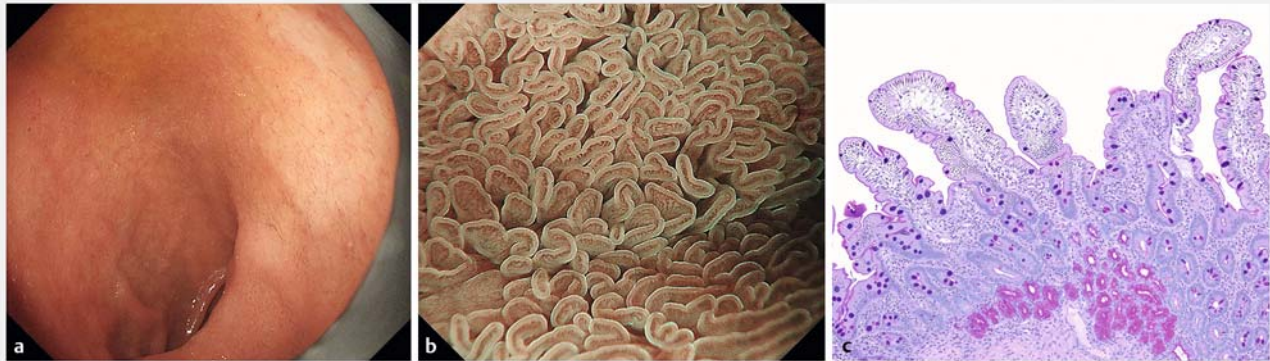
On histological examination of the biopsy specimens collected from duodenal mucosae, GM was detected in 48% of patients (24/50) in the CD group and 16% of patients (8/50) in the UC group; a significant difference was observed ( $P = 0.001$ ) (► **Table 2**). In addition, noncaseating granulomas in the duodenum were detected only in 2% of patients (1/50) in the CD group.

On histological examination of the biopsy specimens collected from HP-negative gastric mucosae, intestinal metaplasia was detected in 8% of patients (4/50) in the CD group and 6% of those (3/50) in the UC group; the difference was not significant ( $P = 1.000$ ) (► **Table 3**). Focally enhanced gastritis was detected in 18% of patients (9/50) in the CD group but was not detected in the UC group (► **Table 3**). In addition, noncaseating granulomas in the stomach were detected only in one (2%) of 50 patients in the CD group (► **Table 3**).

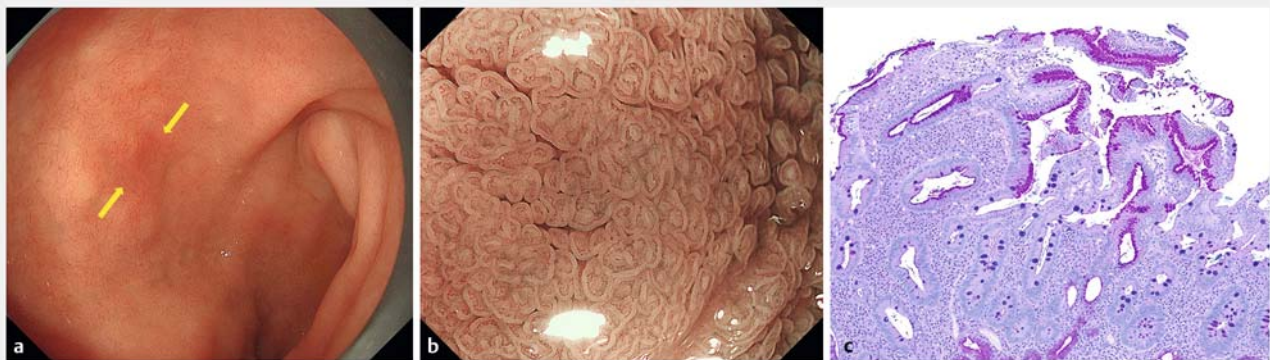
► **Table 3** Histological findings in gastric mucosa.

	Crohn's disease (n=50)	Ulcerative colitis (n=50)	P value
Intestinal metaplasia	4 (8%)	3 (6%)	n.s.
Focally enhanced gastritis	9 (18%)	0 (0%)	<0.001
Noncaseating granuloma	1 (2%)	0 (0%)	n.s.
No specific findings	36 (72%)	47 (94%)	n.s.

n.s., not significant; Fisher's exact test.



► **Fig. 1** Endoscopic and histopathological findings of a normal duodenum. **a** Duodenal bulb: normal mucosa. **b** Magnifying endoscopy with narrow-band imaging at the same site. The normal villous structure is preserved. **c** Histopathological findings of the same site. Alcian blue-periodic acid Schiff staining showing normal duodenal mucosa.



► **Fig. 2** Endoscopic and histopathological findings of the duodenum with mucosal lesions. **a** Conventional white-light imaging. Red flat lesions are observed in the duodenal bulb (arrow). **b** Magnifying endoscopy with narrow-band imaging at the same site. The villous structure is disappeared, and the marginal crypt epithelium appears curved shape. **c** Histopathological findings of the same site. Alcian blue-periodic acid Schiff staining; the mucosal epithelium replaced with the gastric crypt epithelium is stained reddish-purple.

## Secondary endpoints

Examples of C-WLI, M-NBI, and corresponding histological findings of the normal duodenal mucosa and the duodenal mucosa with GM are shown in ► **Fig. 1** and ► **Fig. 2**, respectively. When the duodenal endoscopic findings on C-WLI were examined, mucosal lesions were detected in 66% of patients (33/50) in the CD group and 36% of those (18/50) in the UC group; a significant difference was observed ( $P < 0.001$ ) (► **Table 4**). Based

on the endoscopic findings on C-WLI, the most commonly observed lesion color was red, and the most commonly detected morphological types were the flat and depressed types (► **Table 4**). In addition, the presence of GM was histologically confirmed in 72.2% of the biopsy specimens collected from the flat and depressed lesions.



► **Table 4** Conventional endoscopic findings in the duodenal mucosa.

Crohn's disease (n = 50)			Ulcerative colitis (n = 50)			P value
With mucosal lesions		33	With mucosal lesions		18	<0.001
Duodenum 1 <sup>st</sup> part	Duodenum 2 <sup>nd</sup> part		Duodenum 1 <sup>st</sup> part	Duodenum 2 <sup>nd</sup> part		
Red, flat/depressed	No findings	11	Red, flat/depressed	No findings	9	
Red, flat/depressed	Red, flat/depressed	7	Red, flat/depressed	Red, flat/depressed	3	
Red, protruding	Normal, depressed	1	Red, flat/depressed	White granular	1	
Red, protruding	No findings	1	Normal, protruding	No findings	2	
Normal, protruding	No findings	5	Rough mucosa	Rough mucosa	1	
Normal, protruding	Red, flat/depressed	1	No findings	Red, flat/depressed	1	
Pale, depressed	No findings	1	No findings	Normal, depressed	1	
Beaded mucosa	Normal, depressed	1				
No findings	Red, flat/depressed	3				
No findings	Normal, depressed	2				
Without mucosal lesions		17	Without mucosal lesions		32	

Fisher's exact test.

► **Table 5** Prevalence of gastric metaplasia in the duodenum according to presence or absence of a bamboo joint-like appearance (n = 50).

		Gastric metaplasia		P value
		Positive	Negative	
Bamboo-joint-like appearance	Positive (n = 25)	11 (22%)	14 (28%)	n.s.
	Negative (n = 25)	13 (26%)	12 (24%)	

n.s., not significant; Fisher's exact test.

We found no significant difference in the frequency of GM between patients with and without a bamboo joint-like appearance or duodenal notch on C-WLI (► **Table 5**).

Duodenal mucosal lesions were endoscopically identified in 23 of 24 patients with histologically proven GM in the duodenum. The prevalence rates of GM were significantly different between the patients with and without mucosal lesions ( $P < 0.001$ ) (► **Table 6**). When the presence of mucosal lesions on C-WLI was used as an indicator of CD, C-WLI had a sensitivity of 95.8%, a specificity of 61.5%, and an accuracy of 78.0% for diagnosing GM (► **Table 6**).

A detailed review of M-NBI findings revealed that the characteristic features of GM were the disappearance of normal villous structure in the duodenal mucosa and the presence of curve-shaped marginal crypt epithelium (MCE) at the site of the disappearance of the normal villous structure. These two features were termed magnifying endoscopic findings characteristic of gastric metaplasia (M-GM). In 22 of 24 patients with histologically proven GM in the duodenum, M-NBI showed findings characteristic of M-GM. The prevalence of GM was significantly higher in patients with M-GM findings than in those without them ( $P < 0.001$ ) (► **Table 7**). The following types of GM were

noted: 26% (13/50), small- and large-intestine type, 10% (5/50) were small-intestine type; and 12% (6/50), large-intestine type (► **Table 8**). Meanwhile, the following types of M-GM were observed: 24% (12/50), small- and large-intestine type; 10% (5/50), small-intestine type; and 12% (6/50), large-intestine type (► **Table 9**).

When the presence of M-GM findings on M-NBI was used as an indicator of CD, M-NBI had a sensitivity of 91.6%, a specificity of 96.2%, and an accuracy of 94.0% for diagnosing GM (► **Table 10**). When M-NBI was performed in combination with C-WLI, significant increases were observed in the specificity and accuracy. M-NBI was found to have an additive effect. (► **Table 11**).

The diagnostic concordance rate between the two endoscopists for the presence of mucosal lesions on C-WLI was 83/100 (83%), with a kappa coefficient of 0.68 (moderate). The diagnostic concordance rate between the two endoscopists for the presence of M-GM on M-NBI was 94/100 (94%), with a kappa coefficient of 0.84 (excellent). The intra-observer concordance rate of G. I. for the presence of mucosal lesions on C-WLI for CD and UC was 93/100 (93%), with a kappa coefficient of 0.86 (excellent). The intraobserver concordance rate of G.I.

► **Table 6** Prevalence of gastric metaplasia in the duodenum according to presence or absence of a duodenal notch (n = 50)

		Gastric metaplasia		P value
		Positive	Negative	
Duodenal notch	Positive (n = 6)	3 (6%)	3 (6%)	n.s.
	Negative (n = 44)	21 (42%)	23 (46%)	

n.s., not significant; Fisher's exact test.

► **Table 7** Prevalence of gastric metaplasia in the duodenum of patients with Crohn's disease according to presence or absence of mucosal lesions detected by conventional white-light imaging.

		Gastric metaplasia		P value
		Positive	Negative	
Mucosal lesion	Positive (n = 33)	23 (46%)	10 (20%)	<0.001
	Negative (n = 17)	1 (2%)	16 (32%)	

Fisher's exact test.

► **Table 8** Prevalence of gastric metaplasia in the duodenum of patients with Crohn's disease according to presence or absence of magnifying endoscopic findings characteristic of gastric metaplasia on magnifying endoscopy with narrow-band imaging (n = 50).

		Gastric metaplasia		P value
		Positive	Negative	
M-GM	Positive (n = 23)	22 (44%)	1 (2%)	<0.001
	Negative (n = 27)	2 (4%)	25 (50%)	

M-GM, magnifying endoscopic finding characteristic of gastric metaplasia; Fisher's exact test.

► **Table 9** Prevalence of gastric metaplasia by type of Crohn's disease (n = 50)

		Gastric metaplasia		P value
		Positive	Negative	
Small and large intestine		13 (26%)	20 (40%)	n.s.
Small intestine		5 (10%)	3 (6%)	
Large intestine		6 (12%)	3 (6%)	

n.s., not significant; Fisher's exact test.

for the presence of M-GM on M-NBI for CD was 49/50 (98%), with a kappa coefficient of 0.96 (excellent).

## Discussion

In this study, the prevalence of GM of the duodenal mucosa was significantly higher in patients with CD who did not have HP infection than in control patients with UC. In this study, we histologically examined biopsy specimens collected from the gastric and duodenal mucosae of patients with CD who did not have HP infection and revealed that GM was often detected in the duodenum of patients with CD.

Metaplasia is a condition in which persistent mucous membrane disorders, such as chronic inflammation, induce the differentiation of already differentiated tissues into those with different properties. HP infection is generally reported to be a factor that causes GM of the duodenal mucosa [14]. To the best of our knowledge, to date, no study has identified the presence of GM in the duodenal mucosa of patients with chronic inflammatory bowel diseases, including CD, based on histological findings. For the first time, this study revealed that GM occurs commonly in the duodenal mucosa of patients with CD who do not have HP infection, suggesting that the occurrence of GM in the duodenum may be a novel specific histopathological marker of CD. When our patients' endoscopic findings were exam-

► **Table 10** Prevalence of M-GM by type of Crohn's disease (n = 50).

	M-GM		P value
	Positive	Negative	
Small and large intestine	12 (24%)	21 (42%)	n.s.
Small intestine	5 (10%)	3 (6%)	
Large intestine	6 (12%)	3 (6%)	

M-GM, magnifying endoscopic finding characteristic for gastric metaplasia; n.s., not significant; Fisher's exact test

► **Table 11** Diagnostic performance of endoscopy in the diagnosis of gastric metaplasia in the duodenum of patients with Crohn's disease.

	C-WLI (95% CI)	C-WLI+M-NBI (95% CI)	P value
Sensitivity	95.8 (90.1–99.9)	91.6 (83.5–99.1)	n.s.
Specificity	61.5 (50.0–76.4)	96.2 (90.9–99.9)	0.004
Accuracy	78.0 (66.5–89.5)	94.0 (93.6–94.4)	0.039

C-WLI, conventional endoscopy with white-light imaging; M-NBI, magnifying endoscopy with narrow-band imaging; n.s., not significant; McNemar's test.

ined, the prevalence of mucosal lesions was significantly higher in the CD group than in the UC group ( $P < 0.001$ ). As a bamboo-joint-like appearance and duodenal notch have been reported to be characteristic C-WLI findings of CD [1–4], we also investigated their relationships with the presence of GM. However, there was no correlation between the presence of a bamboo-joint-like appearance or duodenal notch and GM in the duodenum.

Next, the morphology of the lesions was examined on endoscopic images. In general, many endoscopic images of GM show protrusion [15].

In this study, GM was detected in 72.2% of the biopsy specimens collected from flat and depressed lesions. One of the reasons for this is that although GM owing to HP infection is an inflammatory condition that predominantly affects the mucosal epithelium in the superficial layer, CD is characterized by patchy transmural inflammation. When the inflammation affects the superficial layer, lesions may appear as focal flat lesions [5]. We also examined M-NBI findings and found that mucosa with histologically proven GM was characterized based on the findings of villous structure loss and the presence of arc-like structures in the MCE (M-GM). These microscopic focal M-GM findings may reflect noncontinuous patchy lesions of chronic inflammation in the mucosa that are caused by CD.

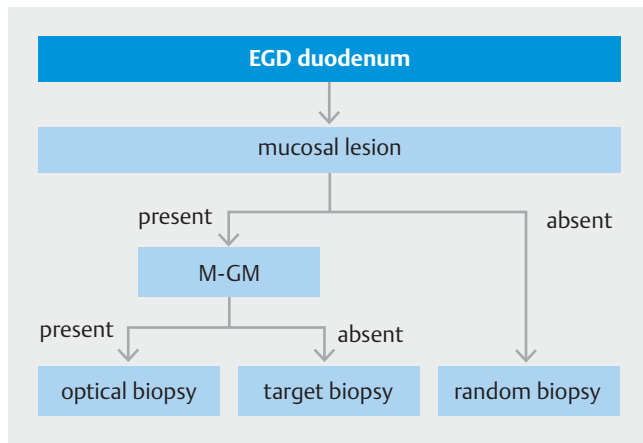
When M-NBI was performed together with C-WLI, significant increases were observed in specificity and accuracy. M-NBI was found to have an additive effect on C-WLI, and M-NBI showed a high diagnostic performance in terms of sensitivity, specificity, and accuracy. The use of M-NBI could have enabled the accurate and efficient diagnosis of GM in the duodenal mucosa. When we closely reexamined the histological findings of two patients with false-negative results on M-NBI, the area of GM in the biopsied tissues was very small. Therefore, we considered that M-GM findings could have been undetectable on magni-

fied endoscopy. Furthermore, we closely reexamined the M-NBI findings of patients with false-positive results and confirmed that the M-GM findings were certainly detectable. In other words, we assumed that the false-positive results were attributable to a sampling error because biopsy specimens were not accurately collected from the observation sites.

The interobserver concordance rate was calculated. The diagnostic concordance rate for mucosal lesions on C-WLI was 83.0% (kappa coefficient 0.68 [moderate]), whereas the diagnostic concordance rate for M-GM on M-NBI for CD was 94.0% (kappa coefficient 0.84 [excellent]). Accordingly, when mucosal lesions are detected on C-WLI, the presence of M-GM, confirmed by M-NBI, could be more reliable marker than that by C-WLI for characterizing the detected lesion.

Based on the current study results, we propose a provisional strategy for the histological diagnosis of GM in the duodenum of Patients with CD who do not have HP infection (► **Fig. 3**). If the detection of mucosal lesions in the duodenum using C-WLI is followed by the detection of M-GM findings using M-NBI in the same sites, a combination of C-WLI and M-NBI can be regarded as optical biopsy, in which GM is diagnosed based on endoscopic findings alone with a high diagnostic performance. When M-NBI reveals a lack of M-GM findings, target biopsy of the mucosal lesions detected using C-WLI should be performed because the incidence of GM is higher in sites with mucosal lesions than in those without mucosal lesions. In the absence of mucosal lesions, random biopsy should be performed. The usefulness of this provisional strategy needs to be verified in a future prospective study. The histological findings of the presence of GM and the characteristic endoscopic findings of GM in the duodenum of HP-uninfected CD patient has not been described in previously published papers.

In the histopathological examination of biopsy specimens collected from the gastrointestinal mucosa (the stomach, duo-



► **Fig. 3** Provisional strategy for a more efficient histological diagnosis of gastric metaplasia in the duodenum. EGD, esophagogastroduodenoscopy; M-GM, magnifying endoscopic finding characteristic of gastric metaplasia.

denum, small intestine, and large intestine) of patients with CD during endoscopy, the presence of a noncaseating epithelioid granuloma is a characteristic finding. The detection rate of this finding by biopsy has been reported to range from approximately 26% to 67% [16, 17]. However, we recently observed a decline in the detection rate of noncaseating epithelioid granulomas. In fact, as demonstrated in this study, the prevalence rate of noncaseating epithelioid granulomas was only 2% and 2% in the stomach and duodenum, respectively.

In this study, we also performed histological and endoscopic examinations of patients' gastric mucosa. Intestinal metaplasia was detected in HP-uninfected gastric mucosae; however, its prevalence did not differ significantly between patients with CD and UC (► **Table 3**). Although intestinal metaplasia is associated with HP infection [18, 19], to our knowledge, this study is the first to demonstrate that intestinal metaplasia occurs even in HP-uninfected gastric mucosae. Half of the gastric mucosal lesions exhibiting intestinal metaplasia appeared as red, patchy, shallow depressed lesions on C-WLI and were characterized by light blue crests on M-NBI. Furthermore, focally enhanced gastritis was histopathologically detected only in patients with CD. When the endoscopic findings of the sites showing histologically proven focally enhanced gastritis were reviewed, no characteristic endoscopic findings were identified.

At our hospital, upper gastrointestinal endoscopy, including that used for screening malignant tumors, is always performed with an endoscopic system using NBI and an optical magnifying endoscope [20]. Furthermore, after informed consent is obtained from patients with chronic inflammatory bowel disease, upper gastrointestinal endoscopy is performed according to the procedure used in this study. These clinical background characteristics allowed for the conduct of this retrospective study.

One of the limitations is that healthy controls were not included to our study. In addition, owing to the retrospective nature of this study, our results need to be verified in a future multicenter prospective study including healthy subjects.

## Conclusion

In conclusion, histologically proven GM of the duodenal mucosa was observed more commonly in patients with CD who did not have HP infection than in patients with UC. The identified endoscopic findings may be useful as novel indicators for the histological diagnosis of GM in the duodenum.

## Competing interests

The authors declare that they have no conflict of interest.

## References

- [1] Yao T, Iwashita A. Upper gastrointestinal involvements of Crohn's disease. *Stomach Intest (Tokyo)* 1983; 18: 1323–1334 (in Japanese, with English abstract)
- [2] Yokota K, Saito Y, Einami K et al. bamboo joint-like appearance of the gastric body and cardia: possible association with Crohn's disease. *Gastrointest Endosc* 1997; 46: 268–272
- [3] Sakatani A, Fujiya M, Kashima S et al. Upper-gastrointestinal Lesions in Patients with Inflammatory Bowel Diseases. *Stomach Intest (Tokyo)* 2013; 48: 636–644 (in Japanese, with English abstract)
- [4] Yoshiki N, Kentaro M, Mikihiro F et al. The endoscopic findings of the upper gastrointestinal tract in patients with Crohn's disease. *Clin J Gastroenterol* 2017; 10: 289–296
- [5] Iwashita A, Yamada Y, Yao T et al. Pathology for Crohn's disease. *Stomach Intest (Tokyo)* 1997; 32: 365–376 (in Japanese, with English abstract)
- [6] Oberhuber G. Focally enhanced gastritis: A frequent type gastritis in patients with Crohn's disease. *Gastroenterology* 1997; 112: 698–706
- [7] Akemoto Y, Sakuraba H, Tanaka M et al. Gastric focal neutrophil infiltration and wide duodenal gastric foveolar metaplasia are histologic discriminative markers for Crohn's disease and Behcet's disease. *Digestion* 2019; 100: 210–219
- [8] Kimura K, Takemoto T. An endoscopic recognition of the atrophic border and its significance in chronic gastritis. *Endoscopy* 1969; 1: 87–97
- [9] Saskaki N, Momma K, Egawa N et al. The influence of *Helicobacter pylori* infection on the progression of gastric mucosal atrophy and occurrence of gastric cancer. *Eur J Gastroenterol Hepatol (Suppl I)* 1995: S59–62
- [10] Oken MM, Creec RH et al. Toxicity and response criteria Of The Eastern Cooperative Oncology Group. *Am J Clin Oncol* 1982; 5: 649–655
- [11] Gormally SM, Kierce BM, Daly LE et al. Gastric metaplasia and duodenal ulcer disease in children infected by *Helicobacter pylori*. *Gut* 1996; 38: 513–517
- [12] Voutilanen M, Juhola M, Farkkila M et al. Gastric metaplasia and chronic inflammation at the duodenal bulb mucosa. *DigestLiver Dis* 2003; 35: 94–98
- [13] Landis JR, Koch GG. The measurement of observer agreement for categorical data. *Biometrics* 1977; 33: 159–174
- [14] Shirai T. The pathogenetic role of gastric metaplasia and *Helicobacter Pylori* duodenal ulcer. *Gastroenterol Endosc* 1991; 33: 2177–2182 (in Japanese, with English abstract)
- [15] Nakai H, koizumi I, Saionnji K. Relation to the background gastric mucosa and *Helicobacter pylori* infections. *Gastroenterol Endosc* 1995; 37: 529–539 (in Japanese, with English abstract)



- [16] De Matos V, Russo PA, Cohen AB et al. Frequency and clinical correlations of granulomas in children with Crohn's disease. *J Pediatr Gastroenterol Nutr* 2008; 46: 392–398
- [17] Rubio CA, Orrego A, Nesi G et al. Frequency of epithelioid granulomas in colonoscopic biopsy specimens from paediatric and adult patients with Crohn's colitis. *J Clin Pathol* 2007; 60: 1268–1272
- [18] Mutoh H, Hakamata Y, Sato K et al. Conversion of gastric mucosa to intestinal metaplasia in Cdx2-expressing transgenic mice. *Biochem Biophys Res Commun* 2002; 294: 470–479
- [19] Rita AB, Alex B. Intestinal metaplasia: A premalignant lesion involved in gastric carcinogenesis. *J Gastroenterol Hepatol* 2009; 24: 193–201
- [20] Yao K, Doyama H, Gotoda T et al. Diagnostic performance and limitations of magnifying narrow-band imaging in screening endoscopy of early gastric cancer: a prospective multicenter feasibility study. *Gastric Cancer* 2014; 17: 669–679