

# Applicability of Magnetic Resonance Imaging for Bone Age Estimation in the Context of Medical Issues

## Einsatz der MRT zur Knochenalterbestimmung im Rahmen medizinischer Fragestellungen

### Authors

Vera Diete<sup>1</sup>, Martin Wabitsch<sup>2</sup>, Christian Denzer<sup>2</sup>, Horst Jäger<sup>3</sup>, Elke Hauth<sup>3</sup>, Meinrad Beer<sup>1</sup>, Daniel Vogele<sup>1</sup>

### Affiliations

- 1 Department for Diagnostic and Interventional Radiology, University Ulm Medical Centre, Ulm, Germany
- 2 Division of Pediatric Endocrinology and Diabetes, University Ulm Medical Centre, Ulm, Germany
- 3 Radiologische Praxis, Ulm, Germany

### Key words

bone age estimation, medical issues, greulich and pyle, hand MRI, imaging technique

received 29.06.2020

accepted 01.11.2020

published online 17.12.2020

### Bibliography

Fortschr Röntgenstr 2021; 193: 692–700

DOI 10.1055/a-1313-7664

ISSN 1438-9029

© 2020, Thieme. All rights reserved.

Georg Thieme Verlag KG, Rüdigerstraße 14, 70469 Stuttgart, Germany

### Correspondence

Dr. Daniel Vogele

Department of Diagnostic and Interventional Radiology, University Ulm Medical Centre, Albert-Einstein-Allee 23, 89081 Ulm, Germany

Tel.: +49/7 31/6 10 04

daniel.vogele@uniklinik-ulm.de

### ABSTRACT

**Objective** The determination of bone age is a method for analyzing biological age and structural maturity. Bone age estimation is predominantly used in the context of medical issues, for example in endocrine diseases or growth disturbance. As a rule, conventional X-ray images of the left wrist and hand are used for this purpose. The aim of the present study is to investigate the extent to which MRI can be used as a radiation-free alternative for bone age assessment.

**Methods** In 50 patients, 19 females and 31 males, in addition to conventional left wrist and hand radiographs, MRI was performed with T1-VIBE (n = 50) and T1-TSE (n = 34). The average age was 11.87 years (5.08 to 17.50 years). Bone age

assessment was performed by two experienced investigators blinded for chronological age according to the most widely used standard of Greulich and Pyle. This method relies on a subjective comparison of hand radiographs with gender-specific reference images from Caucasian children and adolescents. In addition to interobserver and intraobserver variability, the correlation between conventional radiographs and MRI was determined using the Pearson correlation coefficient.

**Results** Between the bone age determined from the MRI data and the results of the conventional X-ray images, a very good correlation was found for both T1-VIBE with  $r = 0.986$  and T1-TSE with  $r = 0.982$ . Gender differences did not arise. The match for the interobserver variability was very good:  $r = 0.985$  (CR),  $0.966$  (T1-VIBE) and  $0.971$  (T1-TSE) as well as the match for the intraobserver variability for investigator A (CR = 0.994, T1-VIBE = 0.995, T1-TSE = 0.998) and for investigator B (CR = 0.994, T1-VIBE = 0.993, T1-TSE = 0.994).

**Conclusion** The present study shows that MRI of the left wrist and hand can be used as a possible radiation-free alternative to conventional X-ray imaging for bone age estimation in the context of medical issues.

### Key points:

- MRI and X-ray show a very good correlation for bone age determination in medical issues.
- With short examination times, T1 VIBE shows slight advantages over T1 TSE.
- Both investigators show high intra- and interobserver variability.

### Citation Format

- Diete V, Wabitsch M, Denzer C et al. Applicability of Magnetic Resonance Imaging for Bone Age Estimation in the Context of Medical Issues. *Fortschr Röntgenstr* 2021; 193: 692–700

### ZUSAMMENFASSUNG

**Ziel** Die Bestimmung des Knochenalters ist ein Verfahren zur Ermittlung des biologischen Alters und der strukturellen Reife. Überwiegend zum Einsatz kommt die Knochenalterbestimmung im Rahmen medizinischer Fragestellungen, z. B. bei endokrinologischen Erkrankungen oder Wachstumsstörungen. In der Regel werden hierzu konventionelle Röntgenaufnahmen der linken Hand verwendet. In der vorliegenden

Studie soll untersucht werden, inwieweit die MRT als strahlungsfreie Alternative zur Knochenalterbestimmung angewendet werden kann.

**Material und Methoden** Bei 50 Patienten (19 weiblich und 31 männlich) wurde zusätzlich zu den konventionellen Röntgenaufnahmen der linken Hand eine MRT mit einer T1-VIBE (n = 50) und einer T1-TSE (n = 34) durchgeführt. Das chronologische Durchschnittsalter lag bei 11,87 Jahren (5,08–17,50 Jahre). Die Knochenalterbestimmung erfolgte verblindet durch 2 erfahrene Untersucher (A und B) gemäß dem am weitesten verbreiteten Standard nach Greulich und Pyle. Die Korrelation zwischen den konventionellen Röntgenaufnahmen und den MRT-Untersuchungen wurde mit dem Korrelationskoeffizienten nach Pearson bestimmt. Zusätzlich erfolgte eine Analyse der Inter- und Intraobserver-Variabilität.

**Ergebnisse** Zwischen dem aus den MRT-Bilddaten bestimmten Knochenalter und den Ergebnissen der konventionellen

Röntgenaufnahmen zeigte sich eine sehr gute Korrelation sowohl für die T1-VIBE mit  $r = 0,986$  als auch für die T1-TSE mit  $r = 0,982$ . Geschlechtsabhängige Unterschiede ergaben sich nicht. Die Übereinstimmung bei der Interobserver-Variabilität war mit  $r = 0,985$  (CR),  $0,966$  (T1-VIBE) und  $0,971$  (T1-TSE) ebenso wie die Intraobserver-Variabilität für Untersucher A (CR =  $0,994$ , T1-VIBE =  $0,995$ , T1-TSE =  $0,998$ ) beziehungsweise Untersucher B (CR =  $0,994$ , T1-VIBE =  $0,993$ , T1-TSE =  $0,994$ ) sehr gut.

**Schlussfolgerung** Die vorliegende Studie zeigt, dass die MRT der linken Hand zur Knochenalterbestimmung im Rahmen medizinischer Fragestellungen als mögliche strahlungsfreie Alternative zu den konventionellen Röntgenaufnahmen verwendet werden kann.

## Introduction

The determination of skeletal age has been an important aspect of diagnosis in endocrinology and pediatrics for decades. The close connection between biological maturation processes and skeletal development, which can be used to determine the biological age of children and adolescents, is used here [1, 2]. Indications for determining skeletal age include the determination of mature body size in small and tall children and diagnosis and follow-up of hormone treatments in endocrine diseases and in adolescents with premature or delayed puberty (pubertas praecox/tarda) [3, 4].

The method according to Greulich and Pyle [GP] is the most commonly used method for determining bone age. In a survey published in 2016, 97% of surveyed radiologists used the GP atlas for bone age determination in the age group between 3 and 18 years [5]. This atlas which includes reference images for various age groups for girls and boys was published in 1959 [6]. According to the GP method, a conventional X-ray image of the left hand and the wrist is acquired and compared to the gender-specific reference images in the atlas. The GP atlas with its reference images can still be used today to determine bone age [7]. In 1962, Tanner and Whitehouse (TW) published another method for determining skeletal age based on conventional X-rays. The revised versions (TW2 and TW3) are still used today [8]. In the TW method the maturity of various bones in the hand and the wrist are categorized according to stages. Using a point system, the skeletal age is then calculated from the stages [9]. Studies comparing the GP method and the TW2 method concluded that the GP method is more suitable for clinical practice due to the shorter application time [10].

In medical issues, follow-up, for example in the case of hormonal therapy, is often performed. Even if the dose for an individual X-ray image is low, higher cumulative doses can occur over time. Due to the overall higher sensitivity of pediatric tissue to radiation, ionizing radiation must be used on a restrictive basis [11]. Ultrasound and MRI have been examined in most studies as possi-

ble alternatives without the use of ionizing radiation [12–15]. Since there is no separate MRI atlas with reference images, the authors used the method according to GP or TW.

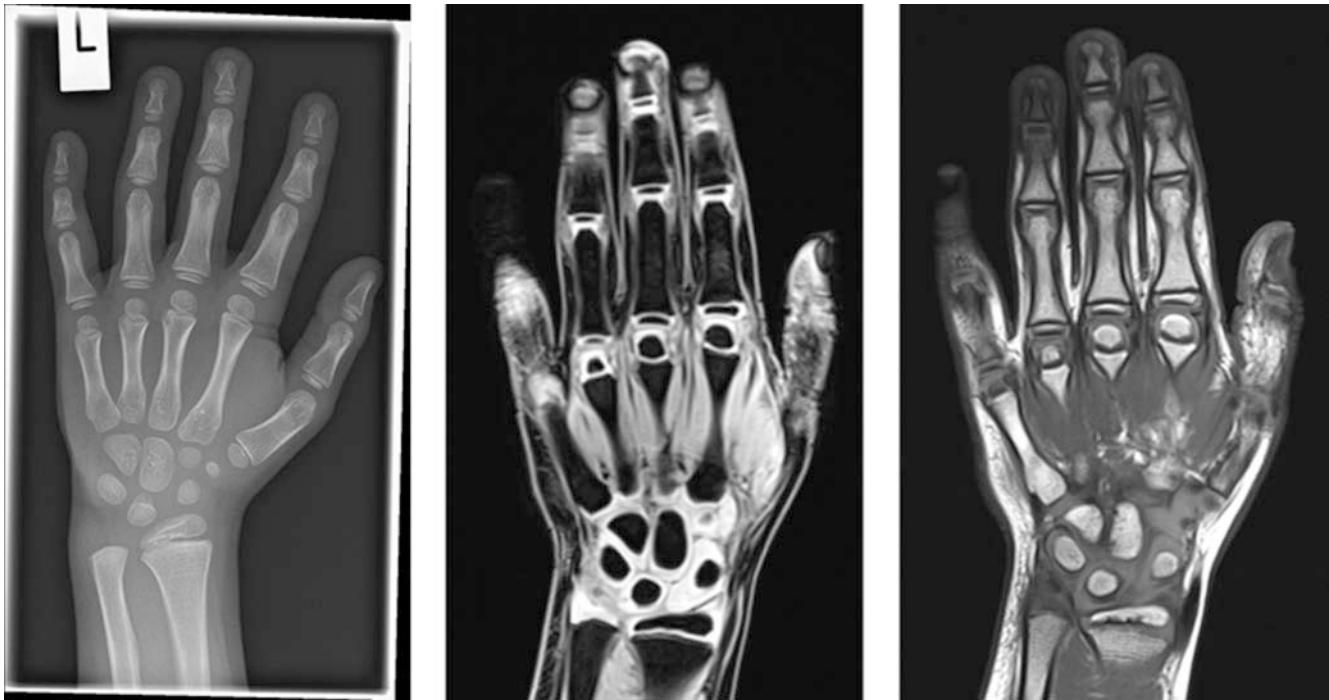The goal of the present prospective study is to examine whether MRI is a suitable alternative to conventional X-ray images for determining bone age using the GP method in medical issues. The bone ages determined with each method were compared. Moreover, the goal of the study is to examine whether relevant advantages and disadvantages of various MRI sequences can be identified and whether there are differences regarding the time requirement for evaluation.

## Materials and Methods

The study was approved by the local ethics committee (no. 351/16). The parents of the patients were provided with information about the study both verbally and in writing and gave their informed consent.

### Patients

50 children and adolescents with growth and/or development disorders, e. g. as a result of endocrine disease, were included in the study. Written informed consent from the parents was required for participation. The exclusion criteria were prior surgeries or prior fractures of the hand or wrist, upper extremity implants, and general (relative) contraindications to MRI, e. g. claustrophobia. 19 female and 31 male children with an age range of 5.08 years to 17.50 years were examined. The average chronological age at the time of examination was 11.87 years. No child needed sedation to undergo MRI examination. Prior to the examination, the children and adolescents as well as their parents received a precise explanation of the examination procedure and any questions were answered.



► **Fig. 1** Pictures of a 7-year, 9-month-old male subject. Conventional X-ray, T1-weighted VIBE and T1-weighted TSE. VIBE = Volumetric Interpolated Breathhold Examination, TSE = Turbo-Spin-Echo.

## Imaging

A conventional X-ray image of the left hand was used to determine the bone age of patients during diagnosis/follow-up. An MRI examination was also performed on the same day (► **Fig. 1, 2**).

The X-ray images of the left hand were acquired on one plane in anterior-posterior projection (a. p.) on a digital X-ray device (Samsung Electronics GC 70, Samsung Healthcare, Seoul, South Korea) (tube voltage 50 kV, tube current 1 mAs). MRI examinations were performed on a 3-Tesla scanner (Magnetom Skyra, Siemens Healthcare, Erlangen, Germany). The examination was performed in a prone position with the arm extended. The left hand was positioned in a 16-channel hand coil (hand/wrist 16, Siemens Healthcare, Erlangen, Germany). One T1-weighted turbo-spin echo sequence (TSE) and one T1-weighted volumetric interpolated breathhold examination sequence (VIBE) were acquired. The sequence parameters are shown in ► **Table 1**.

A coronal T1 VIBE sequence was acquired in all 50 children and adolescents and a coronal T1 TSE sequence was additionally acquired in 34 participants. The image material was archived in a picture-archiving and communication system (PACS) (IMPAX EE R20, Agfa Healthcare, Mortsel, Belgium) for evaluation.

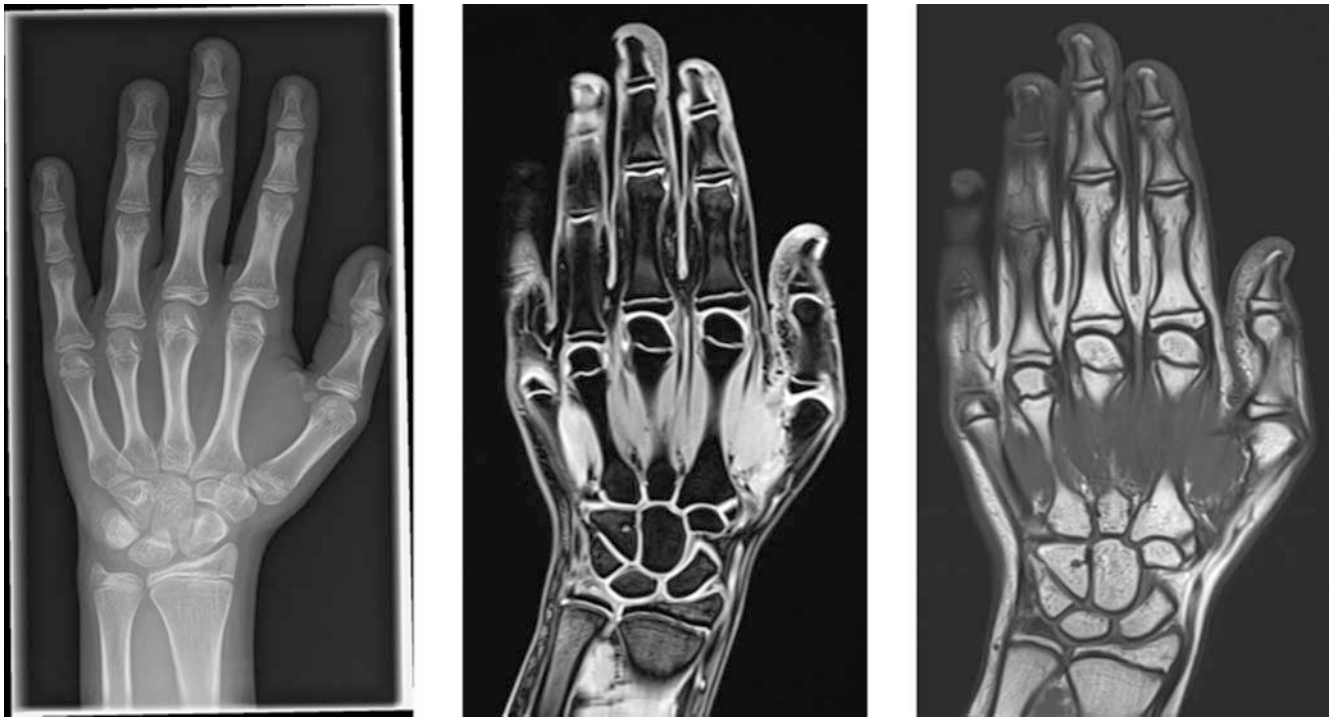## Bone age determination

The method according to Greulich and Pyle was used to determine skeletal age [6]. The image material was compared to the corresponding male or female standardized reference images from the GP atlas. The skeletal age of the children and adolescents was determined in four regions (regions of interest (ROIs)): The

distal forearm, the carpals, the metacarpals, and the phalanges. The shape and size of the ossification centers and the degree of ossification of the epiphyseal plates were analyzed. The mean of the results from the four ROIs was defined as the calculated bone age. The images shown in the GP atlas are conventional X-ray images of the left hand. There is no corresponding atlas for MRI images. Therefore, the MRI images used in the study were evaluated using the GP atlas based on the described ROI method. The carpo-graphs and MRI examinations were evaluated with an interval of 2 weeks. The various MRI sequences were also evaluated with an interval of 2 weeks.

## Statistics

The data were evaluated using IBM SPSS Statistics 24 (IBM Corporation, Armonk, NY). The acquired data were checked for normal distribution using the Shapiro-Wilk test. The correlations between the results of various modalities were tested using Pearson correlation coefficients. The interrater variability was calculated using the Spearman rank correlation coefficients. The interrater variability was also calculated using the Pearson correlation coefficients. The results were shown with the help of scatter plots. A line of origin and an adjustment line were drawn. Bland-Altman plots were used to compare the methods to one another and for graphic representation of the interrater variability (Altman and Bland, 1983). The mean difference between the results and the limits of agreement (LoA), defined as 1.96 times the positive and negative standard deviation (SD), were plotted as reference lines.



► **Fig. 2** Pictures of a 12-year, 11-month-old female subject. Conventional X-ray, T1-weighted VIBE and T1-weighted TSE. VIBE = Volumetric Interpolated Breathhold Examination, TSE = Turbo-Spin-Echo.

► **Table 1** Sequence parameters for the MRI acquisition protocols.

	T1-VIBE	T1-TSE
matrix	512 × 384	512 × 384
voxel size	0.4 × 0.4 × 0.9 mm	0.4 × 0.4 × 2.0 mm
field of view (FOV)	200 mm	200 mm
slice thickness	0.9 mm	2.0 mm
repetition time (TR)	14 ms	450 ms
echo time (TE)	5.94 ms	13 ms
flip angle	15°	180°
fat saturation	Spectral	None
Acquisition time	2:45 min	3:48 min

## Results

The children and adolescents were divided into five age groups with an increment of three years. Most participants (n = 41) were between the ages of 9.5 and 15.49 years. ► **Table 2** shows the absolute and relative distribution.

### Comparison of skeletal age determined using conventional carpalogram versus MRI

After no significant differences between the two observers were seen (see interrater variability), the results of the comparison of the skeletal age calculated using conventional carpalogram versus

MRI were averaged. The Pearson correlation coefficient was 0.986 for T1 VIBE and 0.982 for T1 TSE (► **Fig. 3A, B**). In addition, the average of the results from both sequences was correlated to the average of the conventional carpalograms. The Pearson correlation coefficient was 0.987 (► **Fig. 3C**).

The average difference between the skeletal age determined using conventional carpalogram and the skeletal age calculated using T1 VIBE was 0.51 years with a standard deviation of 0.492 years. On average, the skeletal age was estimated to be older using T1 VIBE than conventional carpalogram. The average difference between the skeletal age determined using conventional carpalogram and the skeletal age calculated using T1 TSE was 0.18 years with a standard deviation of 0.566 years. Younger children were estimated to be older in the case of T1 TSE, and the skeletal age of older children was estimated to be older when using conventional carpalogram. The results for conventional carpalogram versus T1 VIBE and T1 TSE, respectively, are shown as a Bland-Altman plot (► **Fig. 4A, B**). The results of the two observers were averaged for this purpose. In the case of T1 VIBE, 95% of values were within the LoA, which corresponds to a sufficiently symmetrical distribution (► **Fig. 4A**). In the case of T1 TSE, all values were within the LoA (► **Fig. 4B**).

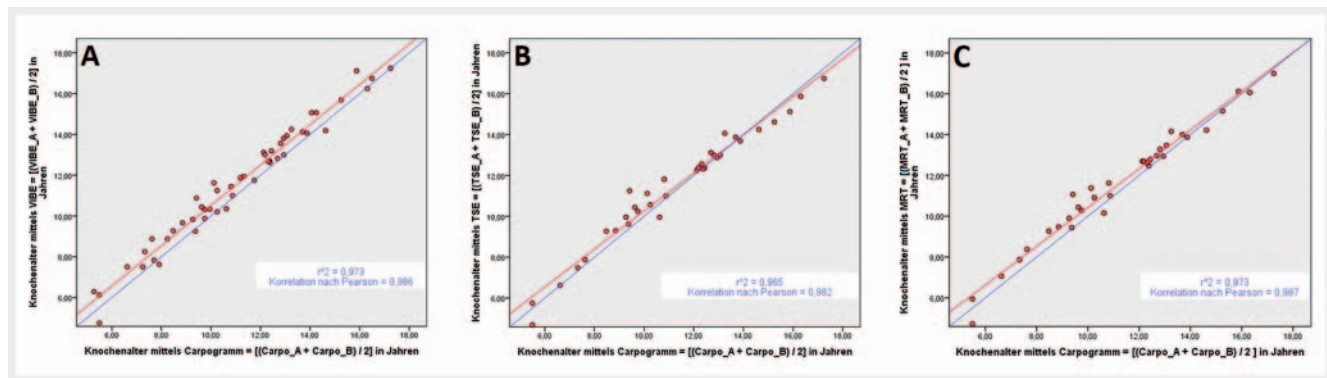
### Interrater variability

The skeletal ages determined both observers were compared using the Spearman rank correlation coefficient. The interrater correlation is significant with a Spearman-Rho of 0.985 for the 50 carpalograms, 0.966 for T1 VIBE and 0.971 for T1 TSE at a level of 0.01.

► **Table 2** Distribution of children and adolescents by age group.

		frequency	percentage	valid percentage	cumulative percentage
valid	1	2	4.0	4.0	4.0
	2	4	8.0	8.0	12.0
	3	22	44.0	44.0	56.0
	4	19	38.0	38.0	94.0
	5	3	6.0	6.0	100.0
	total	50	100.0	100.0	

age groups: 1 = 4–6.49 years; 2 = 6.5–9.49 years; 3 = 9.5–12.49 years; 4 = 12.5–15.49 years; 5 = 15.5–18.5 years



► **Fig. 3** Comparison of the average calculated skeletal age using conventional carpalogram versus MRI T1 VIBE **A**, conventional X-ray versus MRI T1 TSE **B**, and conventional carpalogram versus average of MRI sequences **C**. The results were averaged for observers A and B, respectively. A line of origin is shown in blue. For points above the line of origin, the calculated skeletal age by MRI exceeds the calculated skeletal age by conventional X-ray. An adjustment line (red) illustrates the trend of the values.

The interrater variability was shown with the help of a Bland-Altman plot (► **Fig. 5**). The percentage of values within the LoA was 92% for conventional carpalograms (► **Fig. 5A**), 98% for T1 VIBE (► **Fig. 5B**) and 91% for T1 TSE (► **Fig. 5C**). Sufficiently symmetrical distribution was seen in all plots.

### Interrater variability

After four weeks, each observer reevaluated ten examinations (conventional carpalograms, T1 VIBE, and T1 TSE). The datasets were processed in an anonymized and blinded manner. The observers were blinded to the chronological age and the skeletal age calculated in the first evaluation. Attention was paid to uniform distribution according to age and gender. The observers assessed the children and adolescents in the second evaluation on average to be 0.04 years (observer A) and 0.11 years (observer B) younger.

For observer A, there was a total intrarater Pearson correlation of 0.995. Categorized by examination type, an interrater correlation with a Pearson correlation coefficient of 0.994 was seen for conventional carpalograms, 0.995 for T1 VIBE and 0.998 for T1 TSE. For observer B, there was a total intrarater Pearson correlation of 0.988. Categorized by examination type, an interrater correlation with a Pearson correlation coefficient of 0.994 was

seen for conventional carpalograms, 0.993 for T1 VIBE and 0.994 for T1 TSE. All correlations are significant with a level of 0.01.

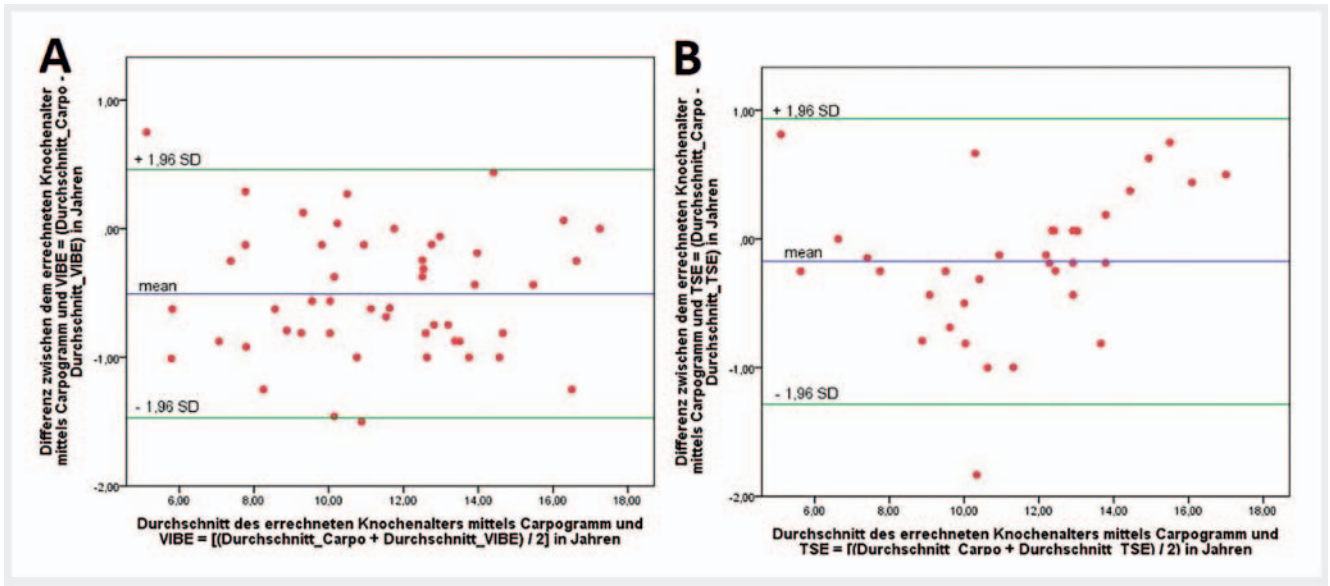
### Time requirement

#### Examination time

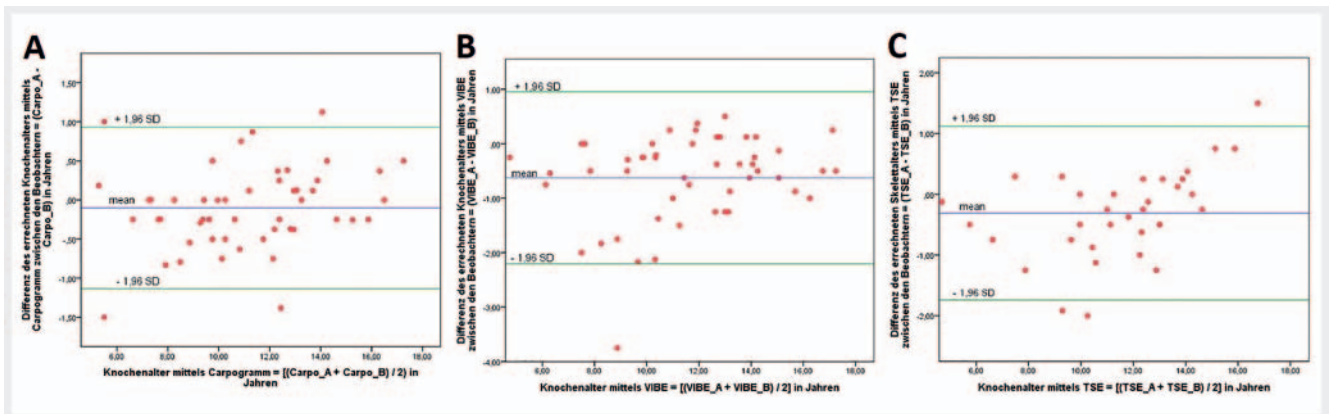
The average examination time for a conventional carpalogram including informed consent discussion with the children/adolescents and their parents, positioning, image acquisition, and post-processing was approximately 3 minutes. The MRI examination, also including informed consent discussion, positioning, image acquisition, and post-processing, took approximately 15 minutes.

#### Evaluation time

For both observers, the time needed to determine bone age for 15 evaluations (conventional carpalograms, T1 VIBE, and T1 TSE) was measured. The average time requirement for the evaluation of a conventional carpalogram was 147 seconds for observer A and 127 seconds for observer B. The maximum time requirement was 191 seconds for observer A and 174 seconds for observer B. The average time requirement for the evaluation of an MRI sequence was 205 seconds for observer A and 163 seconds for observer B. The maximum time requirement was 252 seconds for observer A



► **Fig. 4** Bland-Altman plot for method comparison of skeletal age determination using conventional X-ray and MRI T1 VIBE **A** as well as conventional X-ray and T1 TSE **B**. Comparison of the difference between the results obtained by the two methods with the average of the results obtained by the two methods. Results averaged for both observers. The mean difference between the results (mean = -0.5010 years and -0.0858 years, respectively) and the Limits of Agreement (LoA) were plotted up and down as 1.96 times the standard deviation (SD = 0.474 years and 0.497 years, respectively). 95 % **A** and 100 % **B** of the values are within the LoA. Distribution of the data is sufficiently symmetrical over all sections.



► **Fig. 5** Bland-Altman plot to show interrater variability, conventional X-ray **A**, T1 VIBE **B**, and T1 TSE **C**. Dependence of the difference between the calculated skeletal ages by observers A and B on the average of the calculated skeletal ages by observers A and B. As auxiliary lines, the mean difference between the estimates of the two observers (mean = -0,311 years **A**, -0,101 years **B** und -0,626 years **C**) and the limits of agreement (LoA) were plotted up and down as 1.96 times the standard deviation (SD = 0,729 years **A**, 0,527 years **B** und 0,806 years **C**). 95 % of the values are within the LoA. Distribution of the data is sufficiently symmetrical over all sections. Interrater correlation with a Spearman rank correlation coefficient of 0.985 **A**, 0.966 **B**, and 0.971 **C** significant at the level of 0.01.

and 215 seconds for observer B. The minimum time requirement was 162 seconds for observer A and 135 seconds for observer B. Thus, the difference between the average time requirements is 58 seconds for observer A and 36 seconds for observer B.

## Discussion

To avoid the use of X-ray and CT examinations to determine bone age, alternative methods were used in some studies. In this con-

nection, ultrasound and MRI of the medial clavicular epiphysis as well as MRI of the knee joint were studied [16–20]. Nonetheless, MRI of the hand was used as the alternative method of bone age diagnosis in most studies [21–23]. Hojreh et al. (patients n = 10, test subjects n = 50) and Urschler et al. (patients n = 18) examined the extent to which MRI in direct comparison to conventional carpo-grams can be used to determine bone age for medical issues [12, 24].

## Correlation between conventional carpograms and MRI

In the present study, the comparison of MRI with conventional carpogram was analyzed for the first time on the basis of a greater number of cases ( $n = 50$ ). There was a very good correlation regarding the determined bone age between conventional carpograms and MRI (T1 TSE: 0.976; T1 VIBE: 0.975). On average, the age of the children and adolescents was overestimated in the case of both MRI sequences compared to the conventional carpograms. The average difference was slightly higher for T1 VIBE (0.51 years) than for T1 TSE (0.18 years). All age groups were estimated to be older with T1 VIBE while older children were estimated to be slightly younger with T1 TSE. The difference between the two MRI sequences may be due to the difference in the appearance of bony structures. 95% of the values for T1 VIBE and 100% of the values for T1 TSE were within the 95% confidence interval.

In their study including 18 patients with growth disorders, Urschler et al. also achieved a highly significant correlation (0.98) between the skeletal age calculated using T1 VIBE and the one calculated using conventional carpograms. The skeletal age calculated using T1 VIBE was less than the one calculated using conventional carpograms with an average difference of -0.25 years [12]. In the study by Hojreh et al., bone age was estimated higher with T1 VIBE by one examiner with an average difference of 0.175 years, with only minimal differences being seen for a second examiner (0.05) [24].

As already discussed by Urschler et al., one possible explanation for the differences in bone age determination between the two modalities could be the two-dimensional representation particularly of the growth plates in conventional carpograms compared to the non-overlapping three-dimensional representation in the case of MRI. The additional MRI visualization of cartilaginous and soft-tissue structures could have a further influence even if this was not directly taken into consideration in the GP method [12].

## Interrater and intrarater variability

The reproducibility of this good correlation was seen in the analysis of the interrater variability. Very good interrater variability was seen for carpograms (0.985) as well as for T1 VIBE (0.966) and T1 TSE (0.971). The percentage of values within the 95% confidence interval was 93% for conventional carpograms, 98% for T1 VIBE and 95% for T1 TSE. It should be noted that the conventional GP method with selection of the most suitable standard was used in most studies and more exact agreement between different observers is seen compared to the ROI method used in the present study. Nonetheless, the present results are to be considered equally good to very good compared to the interrater correlations of other studies [21, 22, 24].

There were also very good correlations regarding intrarater variability both for observer A ( $r = 0.995$ ) and observer B ( $r = 0.988$ ). There were also no relevant differences in the categorization according to different methods. The results showed that bone age determination using conventional carpogram as well as MRI can be reliably reproduced in repeated evaluations and between different examiners.

## Differences among sequences

The present study also examined whether advantages or disadvantages can be identified in the evaluation using T1 VIBE and T1 TSE. According to the currently available studies, T1 VIBE should be used even if the sequences have comparable results [25]. Urschler et al. acquired three MRI sequences in their subjects: T1-weighted 3D VIBE, T1-weighted SE, and T2-weighted GRE. Due to the better visualization of the epiphyseal structures, the authors chose to use T1 VIBE for the determination of skeletal age [12]. Hojreh et al. acquired three different sequences (T1-weighted TIRM, T1-weighted 3D VIBE WE, and T1-weighted SE) and had them evaluated by two radiologists regarding quality and suitability for skeletal age determination. The authors chose T1 VIBE, with the better contrast enhancement of cartilaginous components compared to other sequences being a particular advantage [24].

However, the benefit of additional information regarding the development of cartilaginous structures in the determination of skeletal age using the atlas from Greulich and Pyle is questionable. Cartilaginous structures cannot be visualized on the conventional carpograms that serve as reference images in the atlas. As a result, the additional information must be independently interpreted by the observers and theoretically integrated into the course of development. In the long term, the introduction of an atlas based on MRI sequences would address this limitation. In particular, in such an atlas, the carpals could be observed starting with early cartilaginous development and integrated into the evaluation [23].

## Examination time

It takes significantly less time to perform a conventional carpogram than an MRI examination. This fact must also be considered with regard to the compensation situation. The restriction to the acquisition of one sequence and future further developments with shorter acquisition times could decrease the difference regarding examination time between the two modalities.

## Evaluation time

According to Horter et al., the average time requirement for the evaluation of a conventional X-ray image according to Greulich and Pyle is 46.7 seconds with a standard deviation of 15.2 seconds [10]. On average, observer A needed 147 seconds to evaluate a conventional carpogram and observer B required 127 seconds. However, the ROI method was used in the present study, while Horter et al. used the most suitable reference image in the GP method. This fact could explain the difference in evaluation time. With an average time requirement of 205 seconds (observer A) and 163 seconds (observer B), the evaluation of an MRI sequence takes more time than the evaluation of a conventional X-ray image. The time required for evaluation varies between the observers. The difference regarding the average time requirement is 58 seconds for observer A and 36 seconds for observer B. The additional time needed for the evaluation of an MRI image can be explained by the number of different slices.

## Outlook

Systems with artificial intelligence (AI) were used in some studies to evaluate conventional carpograms for determining bone age. These had good results compared to the established methods according to GP and TW [26–28]. Initial studies have already addressed the use of AI systems for bone age determination based on MRI of the left hand or the knee joint [29–31]. The reduction of MRI acquisition times was also already examined in initial studies [32, 33], resulting in promising approaches for future studies.

## Limitations

The present study is a monocentric study. A multicentric study with a larger number of cases is needed to confirm the results. In addition, the ethnicity of the included patients was not analyzed. This aspect should also be taken into consideration in subsequent studies.

## Conclusion

MRI is a reliable method for determining skeletal age without the use of ionizing radiation. The results can be reproduced with a high degree of accuracy at different points in time and by different observers. The GP atlas can be used to evaluate MRI images. However, a new atlas based on MRI reference images should be developed in order to take into account the additional information provided by the visualization of cartilaginous structures on MRI. Both sequences (T1 VIBE and T1 TSE) yielded comparably good results. The more definitive visualization of cartilaginous structures on T1 VIBE is advantageous particularly with regard to an MRI-based atlas.

### CLINICAL RELEVANCE

- MRI is a reliable method for determining bone age.
- T1 VIBE and T1 TSE provide comparable results with slight advantages for T1 VIBE.
- The results can be reproduced with a high degree of accuracy at different points in time and by different observers.

## Conflict of Interest

The authors declare that they have no conflict of interest.

## References

- [1] Ontell FK, Ivanovic M, Ablin DS et al. Bone age in children of diverse ethnicity. *Am J Roentgenol American journal of roentgenology* 1996; 167: 1395–1398. doi:10.2214/ajr.167.6.8956565
- [2] Szemraj A, Wojtaszek-Slominska A, Racka-Pilszak B. Is the cervical vertebral maturation (CVM) method effective enough to replace the hand-wrist maturation (HWM) method in determining skeletal maturation? – A systematic review. *European journal of radiology* 2018; 102: 125–128. doi:10.1016/j.ejrad.2018.03.012
- [3] Martin DD, Wit JM, Hochberg Z et al. The use of bone age in clinical practice – part 1. *Horm Res Paediatr* 2011; 76: 1–9. doi:10.1159/000329372
- [4] Martin DD, Wit JM, Hochberg Z et al. The use of bone age in clinical practice – part 2. *Horm Res Paediatr* 2011; 76: 10–16. doi:10.1159/000329374
- [5] Breen MA, Tsai A, Stamm A et al. Bone age assessment practices in infants and older children among Society for Pediatric Radiology members. *Pediatr Radiol* 2016; 46: 1269–1274. doi:10.1007/s00247-016-3618-7
- [6] Greulich W, Pyle S. *Radiographic atlas of skeletal development of the hand and wrist*. Stanford University Press. 1959
- [7] Chaumoitre K, Saliba-Serre B, Adalian P et al. Forensic use of the Greulich and Pyle atlas: prediction intervals and relevance. *Eur Radiol* 2017; 27: 1032–1043. doi:10.1007/s00330-016-4466-4
- [8] Maggio A, Flavel A, Hart R et al. Skeletal age estimation in a contemporary Western Australian population using the Tanner-Whitehouse method. *Forensic Sci Int* 2016; 263: e1–e8. doi:10.1016/j.forsciint.2016.03.042
- [9] Alshamrani K, Offiah AC. Applicability of two commonly used bone age assessment methods to twenty-first century UK children. *Eur Radiol* 2020; 30: 504–513. doi:10.1007/s00330-019-06300-x
- [10] Horter MJ, Friesen S, Wacker S et al. [Determination of skeletal age: comparison of the methods of Greulich and Pyle and Tanner and Whitehouse]. *Orthopade* 2012; 41: 966–976. doi:10.1007/s00132-012-1983-y
- [11] Alzen G, Benz-Bohm G. Radiation protection in pediatric radiology. *Deutsches Arzteblatt international* 2011; 108: 407–414. doi:10.3238/arztebl.2011.0407
- [12] Urschler M, Krauskopf A, Widek T et al. Applicability of Greulich-Pyle and Tanner-Whitehouse grading methods to MRI when assessing hand bone age in forensic age estimation: A pilot study. *Forensic Sci Int* 2016; 266: 281–288. doi:10.1016/j.forsciint.2016.06.016
- [13] Schmidt S, Schiborr M, Pfeiffer H et al. Age dependence of epiphyseal ossification of the distal radius in ultrasound diagnostics. *Int J Legal Med* 2013; 127: 831–838. doi:10.1007/s00414-013-0871-2
- [14] Mentzel HJ, Vilser C, Eulenstein M et al. Assessment of skeletal age at the wrist in children with a new ultrasound device. *Pediatr Radiol* 2005; 35: 429–433. doi:10.1007/s00247-004-1385-3
- [15] George J, Nagendran J, Azmi K. Comparison study of growth plate fusion using MRI versus plain radiographs as used in age determination for exclusion of overaged football players. *Br J Sports Med* 2012; 46: 273–278. doi:10.1136/bjsm.2010.074948
- [16] Schmidt S, Ottow C, Pfeiffer H et al. Magnetic resonance imaging-based evaluation of ossification of the medial clavicular epiphysis in forensic age assessment. *Int J Legal Med* 2017; 131: 1665–1673. doi:10.1007/s00414-017-1676-5
- [17] Benito M, Munoz A, Beltran I et al. Assessment of adulthood in the living Spanish population based on ossification of the medial clavicle epiphysis using ultrasound methods. *Forensic Sci Int* 2018; 284: 161–166. doi:10.1016/j.forsciint.2018.01.007
- [18] Ottow C, Schulz R, Pfeiffer H et al. Forensic age estimation by magnetic resonance imaging of the knee: the definite relevance in bony fusion of the distal femoral- and the proximal tibial epiphyses using closest-to-bone T1 TSE sequence. *Eur Radiol* 2017; 27: 5041–5048. doi:10.1007/s00330-017-4880-2
- [19] Schmidt S, Henke CA, Wittschieber D et al. Optimising magnetic resonance imaging-based evaluation of the ossification of the medial clavicular epiphysis: a multi-centre study. *Int J Legal Med* 2016; 130: 1615–1621. doi:10.1007/s00414-016-1442-0
- [20] Schulz R, Schiborr M, Pfeiffer H et al. Sonographic assessment of the ossification of the medial clavicular epiphysis in 616 individuals. *Forensic Sci Med Pathol* 2013; 9: 351–357. doi:10.1007/s12024-013-9440-8



- [21] Terada Y, Kono S, Tamada D et al. Skeletal age assessment in children using an open compact MRI system. *Magn Reson Med* 2013; 69: 1697–1702. doi:10.1002/mrm.24439
- [22] Serinelli S, Panebianco V, Martino M et al. Accuracy of MRI skeletal age estimation for subjects 12–19. Potential use for subjects of unknown age. *Int J Legal Med* 2015; 129: 609–617. doi:10.1007/s00414-015-1161-y
- [23] Tomei E, Sartori A, Nissman D et al. Value of MRI of the hand and the wrist in evaluation of bone age: preliminary results. *J Magn Reson Imaging* 2014; 39: 1198–1205. doi:10.1002/jmri.24286
- [24] Hojreh A, Gamper J, Schmook MT et al. Hand MRI and the Greulich-Pyle atlas in skeletal age estimation in adolescents. *Skeletal Radiol* 2018; 47: 963–971. doi:10.1007/s00256-017-2867-3
- [25] De Tobel J, Hillewig E, de Haas MB et al. Forensic age estimation based on T1 SE and VIBE wrist MRI: do a one-fits-all staging technique and age estimation model apply? *Eur Radiol* 2019; 29: 2924–2935. doi:10.1007/s00330-018-5944-7
- [26] Thodberg HH, van Rijn RR, Jenni OG et al. Automated determination of bone age from hand X-rays at the end of puberty and its applicability for age estimation. *Int J Legal Med* 2017; 131: 771–780. doi:10.1007/s00414-016-1471-8
- [27] Booz C, Yel I, Wichmann JL et al. Artificial intelligence in bone age assessment: accuracy and efficiency of a novel fully automated algorithm compared to the Greulich-Pyle method. *Eur Radiol Exp* 2020; 4: 6 doi:10.1186/s41747-019-0139-9
- [28] Nusken E, Imschinetzki D, Nusken KD et al. Automated Greulich-Pyle bone age determination in children with chronic kidney disease. *Pediatr Nephrol* 2015; 30: 1173–1179
- [29] Stern D, Ebner T, Bischof H et al. Fully automatic bone age estimation from left hand MR images. *Med Image Comput Comput Assist Interv* 2014; 17: 220–227. doi:10.1007/978-3-319-10470-6\_28
- [30] Urschler M, Grassegger S, Stern D. What automated age estimation of hand and wrist MRI data tells us about skeletal maturation in male adolescents. *Ann Hum Biol* 2015; 42: 358–367. doi:10.3109/03014460.2015.1043945
- [31] Prove PL, Jopp-van Well E, Stanczus B et al. Automated segmentation of the knee for age assessment in 3D MR images using convolutional neural networks. *Int J Legal Med* 2019; 133: 1191–1205. doi:10.1007/s00414-018-1953-y
- [32] Neumayer B, Lesch A, Thaler F et al. The four-minute approach revisited: accelerating MRI-based multi-factorial age estimation. *Int J Legal Med* 2020; 134: 1475–1485. doi:10.1007/s00414-019-02231-w
- [33] Neumayer B, Schloegl M, Payer C et al. Reducing acquisition time for MRI-based forensic age estimation. *Sci Rep* 2018; 8: 2063 doi:10.1038/s41598-018-20475-1