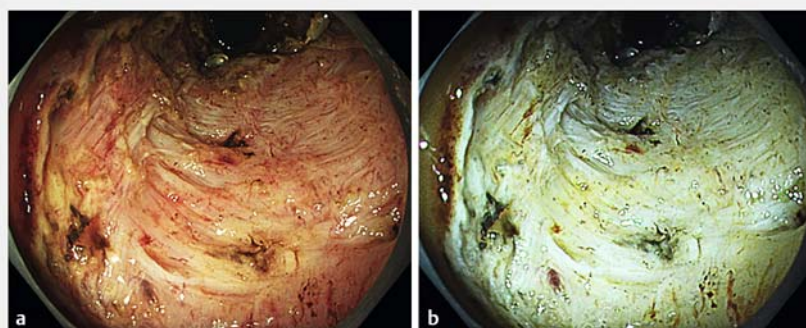


Red dichromatic imaging helps in detecting exposed blood vessels in gastric ulcer induced by endoscopic submucosal dissection

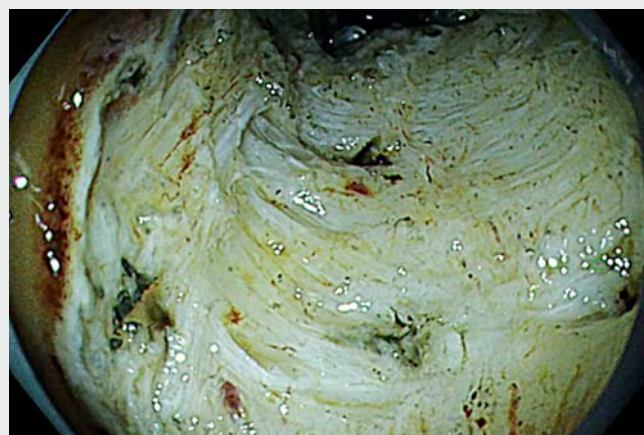Delayed bleeding is one of the postoperative complications of gastric endoscopic submucosal dissection (ESD) [1]. The clipping of exposed blood vessels after ESD completion is effective in preventing delayed bleeding [2,3]. However, the exposed blood vessels are sometimes difficult to detect. Herein we report the effectiveness of a novel image-enhanced endoscopic technology called red dichromatic imaging (or dual red imaging) for detecting exposed blood vessels and preventing delayed bleeding after gastric ESD.

A 61-year-old man had a 25-mm 0-IIc lesion located in the middle gastric body. We performed ESD using esophago-gastroduodenoscopy (GIF-H290T with EVIS X1 video system; Olympus Medical Systems, Tokyo, Japan). After completion of ESD, the scope was changed to a GIF-EZ1500, and the ESD-induced ulcer was observed (► **Fig. 1 a**, ► **Video 1**). We switched the white light imaging to red dichromatic imaging and the exposed blood vessels were more clearly visualized (► **Fig. 1 b**, ► **Video 1**). A blood vessel penetrating the muscle layer was covered with submucosal fibrous and fatty tissue, as observed by white light (► **Fig. 2 a**). This blood vessel could be identified more clearly than the surrounding tissue using red dichromatic imaging (► **Fig. 2 b**). We were able to easily detect the exposed blood vessels using red dichromatic imaging and then perform clipping (HX-610-090S; Olympus Medical Systems) (► **Fig. 3**). The patient was discharged without delayed bleeding.

Red dichromatic imaging is a novel image-enhanced endoscopic technology using three wavelengths (540 nm, 600 nm, and 630 nm). Its effectiveness for detecting bleeding vessels has been previously reported [4]. In this case, submucosal fibrous tissue, fatty tissue, and the muscle layer were identified as a whiter collar using red dichromatic ima-



► **Fig. 1** Endoscopic submucosal dissection (ESD)-induced ulcer. **a** Observed using white light. **b** Observed using red dichromatic imaging.



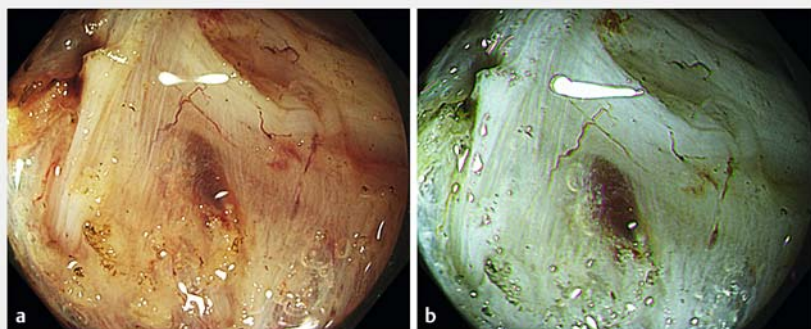
► **Video 1** The observation of the exposed blood vessels in a gastric ulcer induced by endoscopic submucosal dissection using red dichromatic imaging.

ging rather than white light. Red dichromatic imaging helped gain a clear endoscopic view during colorectal ESD with submucosal fatty tissue [5]. We were able to easily detect the exposed blood vessels using red dichromatic imaging because the color difference between the exposed blood vessels and surrounding tissue was clear.

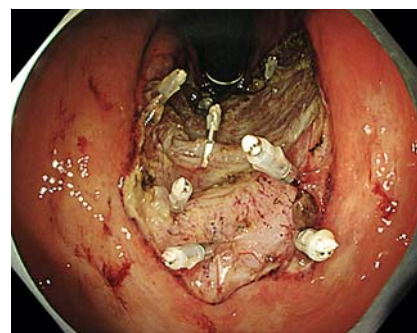
Endoscopy_UCTN_Code_TTT_1AO_2AB

Competing interests

The authors declare that they have no conflict of interest.



► **Fig. 2** **a** The blood vessel penetrating the muscle layer was covered with submucosal and fatty tissue, as observed by white light. **b** The blood vessel could be identified more clearly than the surrounding tissue using red dichromatic imaging.



► **Fig. 3** Endoscopic submucosal dissection-induced ulcer after clipping.

The authors

Shuichi Miyamoto^{1,2}, Ryo Sugiura¹, Satoshi Abiko¹, Kazuteru Hatanaka¹, Yoshiya Yamamoto¹, Hirohito Naruse¹, Naoya Sakamoto²

- 1 Department of Gastroenterology and Hepatology, Hakodate Municipal Hospital, Hakodate, Japan
- 2 Department of Gastroenterology and Hepatology, Hokkaido University Faculty of Medicine and Graduate School of Medicine, Sapporo, Japan

Corresponding author

Shuichi Miyamoto, MD

Department of Gastroenterology and Hepatology, Hakodate Municipal Hospital, 1-10-1, Minato-cho, Hakodate, 041-8680, Japan
shuichi0210miyamoto@yahoo.co.jp

References

- [1] Yamamoto S, Uedo N, Ishihara R et al. Endoscopic submucosal dissection for early gastric cancer performed by supervised residents: assessment of feasibility and learning curve. *Endoscopy* 2009; 41: 923–928
- [2] Azumi M, Takeuchi M, Koseki Y et al. Correction to: The search, coagulation, and clipping (SCC) method prevents delayed bleeding after gastric endoscopic submucosal dissection. *Gastric Cancer* 2019; 22: 576
- [3] Mukai S, Cho S, Nakamura S et al. Postprocedural combined treatment using the coagulation plus artery-selective clipping (2C) method for the prevention of delayed bleeding after ESD. *Surg Endosc* 2013; 27: 1292–1301
- [4] Fujimoto A, Saito Y, Abe S et al. Haemostasis treatment using dual red imaging during endoscopic submucosal dissection: a multi-centre, open-label, randomised controlled trial. *BMJ Open Gastroenterol* 2019; 6: e000275
- [5] Tanaka H, Oka S, Tanaka S et al. Dual red imaging maintains clear visibility during colorectal endoscopic submucosal dissection. *Dig Dis Sci* 2019; 64: 224–231

Bibliography

Endoscopy 2021; 53: E403–E404

DOI 10.1055/a-1314-9714

ISSN 0013-726X

published online 17.12.2020

© 2020. Thieme. All rights reserved.

Georg Thieme Verlag KG, Rüdigerstraße 14, 70469 Stuttgart, Germany

ENDOSCOPY E-VIDEOS

<https://eref.thieme.de/e-videos>



Endoscopy E-Videos is a free access online section, reporting on interesting cases and new techniques in gastroenterological endoscopy. All papers include a high quality video and all contributions are freely accessible online.

This section has its own submission website at

<https://mc.manuscriptcentral.com/e-videos>