Subscapularis Tendon Tears – Usefulness of Written MRI Reports for Guiding Patient Referral to Shoulder Specialists

Versorgungsforschung zur Verlässlichkeit radiologischer Befunde in der MRT-Diagnostik von Subscapularisläsionen

Authors
Robert Lenz[1], Jörn Kircher[2], Knut Schwalba[2], Marc-André Weber[3], Thomas Tischer[1]

Affiliations
1 Orthopedics, University Medicine Rostock, Germany
2 Shoulder and Elbow Surgery, ATOS Klinik Fleetinsel Hamburg, Germany
3 Institute of Diagnostic and Interventional Radiology, University Medicine Rostock, Germany

Key words
subscapularis tear, MRI, sensitivity, healthcare research

received 20.04.2020
accepted 16.11.2020
published online 21.01.2021

Bibliography
Fortschr Röntgenstr 2021; 193: 797–803
DOI 10.1055/a-1328-3142
ISSN 1438-9029

Georg Thieme Verlag KG, Rüdigerstraße 14, 70469 Stuttgart, Germany

Correspondence
Dr. Robert Lenz
Orthopedics, Universitätsmedizin Rostock, Doberaner Str. 142, 18057 Rostock, Germany
Tel.: +49/3 81/4 94 93 53
robert.lenz@med.uni-rostock.de

ZUSAMMENFASSUNG

Hintergrund Risse der Rotatorenmanschette sind einer der häufigsten Gründe für Schulterschmerzen. In der Mehrzahl der Fälle stellen sich die Patienten zunächst bei nicht spezialisierten Ärzten (meist beim Hausarzt) vor. Insbesondere Subscapularissehnenrupturen sind jedoch schwer zu diagnostizieren, sodass eine adäquate Therapie oft verzögert wird. Insbesondere der Hausarzt oder nichtspezialisierte Orthopäden benötigen eine verlässliche MRT-Befundung, um eine rechtzeitige Überweisung der Patienten an Schulterspezialisten zu ermöglichen. Daher war es Ziel dieser Studie, die Wertigkeit des schriftlichen MRT-Berichts anhand arthroskopisch nachgewiesener Subscapularissehnenrupturen zu untersuchen.

Methoden In diese retrospektive Studie wurden 97 Patienten (Durchschnittsalter 62,4 Jahre, 63 Männer) eingeschlossen. Zwischen April 2013 und Januar 2015 erhielten sie eine arthroskopische Subscapularissehnenrekonstruktion durch 2 erfahrene Schulterchirurgen. Alle Patienten hatten Standard-MRT-Scans (≥ 1,5 Tesla) innerhalb von 4–164 Tagen (durchschnittlich 57,4 Tage) vor ihren arthroskopischen Eingriffen.

Ergebnisse und Schlussfolgerung Durch Arthroskopie verifizierte Subscapularissehnenrupturen wurden im schriftlichen Bericht der präoperativen MRT-Scans nur in 37 von 97 Fällen korrekt identifiziert. Dies führte zu einer insgesamt geringen Sensitivität von 38,1 %. Korrekt beschriebene Läsionen wurden wie folgt gefunden: Fox/Romeo I 29,4 % (5/17 Patienten), Fox/Romeo II 20 % (7/35 Patienten), Fox/Romeo III 46,7 % (14/30 Patienten) und Fox/Romeo IV 73,3 % (11/15 Patienten). Im Gegensatz dazu wurden gleichzeitige Supraspinatussehnenrupturen in 88,2 % (60/68 Fälle, Sensitivität 88,2 %, Spezifität 96,5 %) korrekt identifiziert. Präoperative schriftliche MRT-Berichte einer heterogenen Gruppe von 39 überwiegend nicht muskuloskelettal spezialisierten radiologischen Zentren beschreiben Subscapularissehnenrupturen nicht zuverlässig. Damit gelten sie als unzureichend, um Patienten spezialisierten Zentren zuzuführen. Diese Studie zeigt, im Vergleich zu anderen Verletzungen der Rotatorenmanschette, Schwierigkeiten in der korrekten Befundung von Subscapularissehnenverletzungen auf. Diese ist allerdings notwendig, um die Patienten einer rechtzeitigen Therapie zuzuführen. Es ist anzunehmen, dass eine Befundung durch muskuloskelettal spezialisierte Radiologen häufiger zu korrekten Befunden führen würde.

Kernaussagen:
- Subscapularissehnenrupturen sind im Standard-Schulter-MRT schwer zu diagnostizieren.
- Schriftliche MRT-Berichte nicht muskuloskelettal spezialisierter Radiologen sind insbesondere bei kleineren Läsionen nicht zuverlässig.
- Für zielgerichtete Zuweisung zu Schulterspezialisten ist eine zuverlässige Befundung erforderlich (spezialisierte muskuloskelettale Radiologen).

ABSTRACT

Introduction Rotator cuff tears are one of the most common reasons for shoulder pain, and patients often present initially to general practitioners. However, subscapularis tears are especially difficult to diagnose and hence adequate therapy is often delayed. General practitioners or non-specialist orthopedic surgeons need reliable MRI findings to allow timely referral of patients to shoulder specialists. The purpose of this study was to determine the validity of the written MRI report of patients with arthroscopically proven subscapularis tendon tears.

Method In this retrospective study, 97 patients (mean age 62.4 ± 10 years, 63 men) who underwent arthroscopic subscapularis repair between April 2013 and January 2015 by two experienced shoulder surgeons and who underwent a preoperative 1.5 T MRI study were included. All of these patients had high-field strength (i. e., ≥ 1.5 T) standard MRI scans performed within 4–164 (mean 57.4 ± 38.4) days before their arthroscopic procedures.

Results and Conclusion Subscapularis tendon tears, verified by arthroscopy, were correctly identified in only 37 of 97 cases in the written report of the preoperative MRI. This resulted in an overall low sensitivity of 38.1 %. Correctly predicted lesions were as follows: Fox and Romeo I 29.4 % (5/17 patients), Fox and Romeo II 20 % (7/35 patients), Fox and Romeo III 46.7 % (14/30 patients) and Fox and Romeo IV 73.3 % (11/15 patients). In contrast, concurrent supraspinatus tendon tears were identified correctly in 88.2 % of patients (60/68 cases, sensitivity 88.2 %, specificity 96.5 %). Preoperative written radiology reports provided by a heterogeneous group of 39 presumably non-MSK-specialized radiologic centers do not reliably detect subscapularis tendon tears and are not sufficient for guiding patients to specialist centers. Compared to other rotator cuff injuries, this study shows difficulties in the correct diagnosis of subscapular tendon injuries. However, this is necessary to provide patients with timely therapy. It can be assumed that MRI review by musculoskeletal-specialized radiologists would more often than not lead to the correct diagnosis.

Key Points:

- Subscapularis tendon ruptures are difficult to diagnose on standard shoulder MRI.
- Written MRI reports from non-musculoskeletal-specialized radiologists are not reliable, especially for smaller lesions.
- Reliable findings are required for referral allocation to shoulder specialists (specialized musculoskeletal radiologists).

Citation Format

- Lenz R, Kircher J, Schwalba K et al. Subscapularis Tendon Tears – Usefulness of Written MRI Reports for Guiding Patient Referral to Shoulder Specialists. Fortschr Röntgenstr 2021; 193: 797–803

Introduction

In the German healthcare system, patients with shoulder problems often present initially to a general practitioner or general orthopedic doctor with no special training regarding the shoulder. Subscapularis (SSC) tendon tears are especially difficult to diagnose for non-specialized doctors and are often missed early on, leading to a delay in therapy [1]. Therefore, the written report from the radiologist is very important in terms of referring patients to specialist shoulder surgeons. This is of even greater importance since SSC tendon tears have been found to be present more often, with newer studies reporting a prevalence between 27 % and 30 % in all shoulder arthroscopies and between 49 % and 59 % in arthroscopic rotator cuff surgery [2–4].

An overlooked SSC lesion shows a tendency for early retraction with progression to muscle atrophy and fatty degeneration that makes a delayed refixation less likely to be successful [5, 6]. The loss of the strongest internal rotator at the front and the loss of the force coupled with the infraspinatus (ISP) tendon are commonly believed to be catastrophic for shoulder function and the long-term prognosis [5, 7]. Salvage procedures, such as pectoralis major transfer (PMT) and anterior latissimus dorsi (ALTD) transfer, are less likely to restore shoulder function and have a higher risk for complication and failure of treatment. This underlines the importance of a correct diagnosis in the first instance.

The aim of this study was to assess the usefulness of the written radiological report provided to our center by a heterogeneous group of 39 general radiologic centers (37 without dedicated musculoskeletal-specialized radiologists (i. e., certificates indicating a level of competence in musculoskeletal radiology) as a tool for patient guidance and decision making regarding SSC tendon tears.

Materials and Methods

This retrospective study (Ethics Committee Approval is granted with number A 2013–0160) includes 103 patients who underwent shoulder arthroscopy between April 2013 and January 2015 with intraoperative confirmation of SSC tendon tears in two centers by two experienced consultant orthopedic surgeons (each with over 10 years of experience in shoulder surgery). Tear size was intraoperatively classified according to Fox and Romeo (▶ **Table 1**) [8] and additional lesions were noted. The intraoperative findings were then correlated to the written radiological report. Exclusion criteria were time from magnetic resonance imaging (MRI) to surgery of more than 180 days (five patients), missing written report (one case), and previous surgery on the examined shoulder. A total of 97 patients were included for analysis. The mean age was 62.4 years (range 39 to 81), with 63 men and 34 women. The right side was affected in 58 cases (56 %). All patients had conventional MRI scans performed at a mean of 57.4 days (range 4–164) before arthroscopic surgery. The written MRI reports by the radiologists were assessed with respect to SSC,

▶ **Table 1** Comparison of the sensitivity of MRI-positive SSC lesions depending on the size of the defect in accordance with the Fox and Romeo classification. Type I 1: partial thickness tear; type 2: complete tear of upper 25 % of tendon; type 3: complete tear of upper 50 % of tendon; and type 4: complete rupture of tendon.

▶ **Tab. 1** Vergleich der Sensitivität von MRT-positiven SSC-Läsionen in Abhängigkeit von der Größe des Defekts gemäß der Fox- und Romeo-Klassifikation. Typ 1: partieller Dickenriss; Typ 2: vollständiger Riss der oberen 25 % der Sehne; Typ 3: vollständiger Riss der oberen 50 % der Sehne; Typ 4: vollständiger Sehnenriss.

	Fox/Romeo I	Fox/Romeo II	Fox/Romeo III	Fox/Romeo IV
arthroscopy (n = 97)	17	35	30	15
MRI-positive SSC lesion (n = 37)	5	7	14	11
sensitivity	5/17 (29.4 %)	7/35 (20 %)	14/30 (46.7 %)	11/15 (73.3 %)

supraspinatus (SSP)/ISP tendon tears, and biceps tendon pathology and correlated to the intraoperative findings. Calculation of the sensitivity for each type of lesion was performed.

MRI

Every included patient had a high-field strength (i. e., ≥ 1.5 T) standard MRI scan that fulfilled the criteria established by the German Radiological Society (https://www.ag-bvb.drg.de/de-DE/3644/protokollempfehlungen/). No patient received contrast-enhanced arthrography, but in 14 MRIs, intravenous contrast medium was applied. The examinations were performed in an outpatient setting in different locations (39 radiological institutions) in northern Germany. Three of them were associated with a communal hospital. The rest were either private centers or part of a radiology network. Only two of them had certificates of musculoskeletal specialization (DGMSR) listed in their reports or on their homepages. We analyzed the written radiologic report of each patient and evaluated the interpretation of the SSC and SSP tendons by the radiologist (i. e., complete and partial tears versus intact tendon). There was no influence on the particular MRI protocols of each radiologist. All of the MRI scans where a protocol was transmitted included T2-weighted coronal oblique, axial, and sagittal oblique films and T1-weighted sagittal oblique films.

Arthroscopy

The arthroscopic examination was standardized by an inspection of the glenohumeral joint via the posterior approach. The structural integrity and stability of the long biceps tendon from its origin to the intertubercular course was checked. Inspection of the joint cartilage and the labrum was followed by examination of the rotator cuff tendons. The SSC tendon was tested by watching its movement during rotation. Visualization was enhanced with a posterior lever push maneuver [7, 8]. A (partially) bare lesser tuberosity is indicative of tearing. In cases of disturbing tissue (i. e., scar or synovitis), careful debridement was performed in order not to miss hidden lesions. SSC tendon tears were measured and then classified by the same protocol using the Fox and Romeo classification [8].

The biceps pulley was described as damaged or intact. Thus, the co-incidence of pulley lesions and SSC tendon tears could be determined. In addition, supraspinatus, ISP, and biceps tendon lesions (partial and complete tears), as well as labrum lesions, were recorded during arthroscopy (▶ **Fig. 1**).

A tenotomy or tenodesis of the long biceps tendon was usually performed prior to SSC therapy, depending on the age and functional demands of the patient. Afterwards, arthroscopic repair of the SSC tendon was performed with one or two suture anchors, depending on rupture size and preferred surgical technique. Additional rotator cuff tears were addressed depending on their size and tear configuration.

Statistical analysis

Microsoft Excel (Microsoft, Redmond, Washington, USA) was used for data collection. Continuous variables are presented as means, standard deviations (SDs), maximums and minimums. Categorical variables are presented as percentages. The ANOVA test for linear regression was used to calculate correlations. Statistical significance was set to a p-value of < 0.05. Data was analyzed using SPSS statistics software version 23.0 (IBM, New York, USA).

Results

Arthroscopic findings

SSC tendon tears (n = 97) were classified according to the classification by Fox and Romeo (▶ **Table 1**): I, 17 patients (17.5 %); II, 35 patients (36.1 %); III, 30 patients (30.1 %); and IV, 15 patients (15.5 %). Isolated SSC tendon tears were present in 24 cases (24.7 %). Additional tears of the ISP or SSP tendon were observed in 73 cases (75.3 %). SSP tendon partial or full-thickness tears were present in 68/97 patients (70.1 %). ISP partial or full-thickness tendon tears were present in 22/97 patients (22.7 %) (no isolated ISP tendon tears). The long head of the biceps (LHB) and pulley systems showed a normal structure in only 6/97 cases (6.2 %). We detected isolated pulley lesions in 39/97 cases (40.2 %) and combined with dislocation of the LHB tendon (LHBT) in 13/97 cases (13.4 %). Other LHBT lesions (54.6 %) included complete or partially torn LHB tendons or tendinitis of the tendon. Among the sizes of the torn SSC tendons, there was a rising co-incidence of pathologies of the LHBT (▶ **Table 2**).

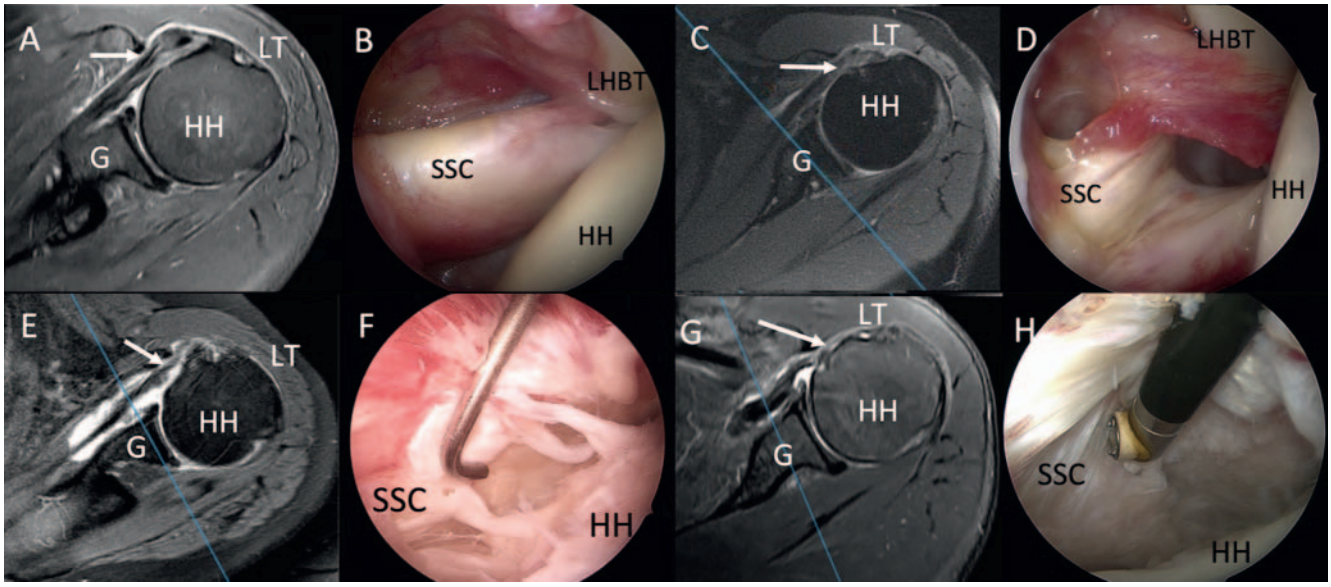

▶ **Fig. 1** Corresponding MRI (unenhanced proton density fat saturated sequences in axial orientation) and intraoperative findings of SSC tears with different defect sizes. **A** Axial MRI view of a right shoulder with a luxation of the long head of the biceps tendon and a partial tear of the subscapularis tendon (arrow) without relevant detachment of the lesser tuberosity (LT). **B** Standard posterior viewing portal with 30° arthroscope showing a partial lesion (Fox/Romeo I). **C** Axial MRI view of a right shoulder demonstrating a focal area of fluid signal intensity of the superior subscapularis tendon attachment at the lower tuberosity (LT) (arrow) consistent with a partial thickness tear. **D** Standard posterior viewing portal with 30° arthroscope showing a partial lesion (Fox/Romeo II). **E** Axial MRI view of a right shoulder with a subtotal tear of the subscapularis tendon. **F** Standard posterior viewing portal with 30° arthroscope showing a subtotal lesion (Fox/Romeo III). **G** Axial MRI view of a right shoulder with a full-thickness tear of the subscapularis tendon (arrow) and ruptured long head of biceps tendon. **H** Standard posterior viewing portal with 30° arthroscope confirming the complete lesion of the SSC (Fox/Romeo IV). (MR images were mirrored for better orientation), (SSC = subscapularis tendon; LHBT = long head of the biceps tendon; HH = humeral head; G = glenoid).

▶ **Abb. 1** Korrespondierende MRT (nichtverstärkte protonendichte fettsaturierte Sequenzen in axialer Orientierung) und intraoperative Befunde von SSC-Rissen mit unterschiedlichen Defektgrößen. **A** Axiale MRT-Ansicht einer rechten Schulter mit einer Luxation der langen Bizepssehne und einer Teilruptur der Subscapularissehne (Pfeil) ohne relevante Ablösung des Tuberculum minus (LT). **B** Standard-Betrachtungsportal von posterior mit 30°-Arthroskop, das eine partielle SSC-Läsion zeigt (Fox/Romeo I). **C** Axiale MRT-Ansicht einer rechten Schulter, die ein fokales Flüssigkeitssignal des oberen Subscapularissehnenansatzes am unteren Tubeculum minus (LT) (Pfeil) zeigt, übereinstimmend mit einer Partialruptur. **D** Standard-Portal von posterior mit 30°-Arthroskop, das eine partielle SSC-Läsion zeigt (Fox/Romeo II). **E** Axiale MRT-Ansicht einer rechten Schulter mit einem subtotalen Riss der Subscapularissehne. **F** Standard-Betrachtungsportal von posterior mit 30°-Arthroskop, das eine subtotale Läsion zeigt (Fox/Romeo III). **G** Axiale MRT-Ansicht einer rechten Schulter mit einer kompletten Ruptur der Subscapularissehne (Pfeil) und rupturierter langer Bizepssehne. **H** Standard-Portal von posterior mit 30°-Arthroskop zur Bestätigung der vollständigen Läsion des SSC (Fox/Romeo IV). Die MRT-Bilder wurden zur besseren Orientierung gespiegelt. SSC = Subscapularissehne; LHBT = lange Bizepssehne; HH = Humeruskopf; G = Glenoid.

▶ **Table 2** Correlation of LHBT pathology with the size of the subscapularis tears in accordance with the Fox and Romeo classification.

▶ **Tab. 2** Korrelation der Pathologie der langen Bicepssehne mit der Größe der Subskapularissehnenrisse nach der Fox- und Romeo-Klassifikation.

	Fox 1	Fox 2	Fox 3	Fox 4
pulley lesion	2/17 (11.8 %)	18/35 (51.4 %)	12/30 (40 %)	7/15 (46.7 %)
LHBT dislocation	1/17 (5.9 %)	0/35 (0 %)	9/30 (30 %)	3/15 (20 %)
LHBT partial lesion	5/17 (29.4 %)	8/35 (22.8 %)	10/30 (33.3 %)	3/15 (20 %)
LHBT complete lesion	4/17 (23.5 %)	2/35 (5.7 %)	6/30 (20 %)	5/15 (33.3 %)
LHBT tendinitis	2/17 (11.7 %)	6/35 (17.1 %)	1/30 (3.3 %)	1/15 (6.6 %)

▶ **Table 3** Comparison of MRI and arthroscopic findings in diagnosing supraspinatus tears.

▶ **Tab. 3** Vergleich von MRT und arthroskopischen Befunden hinsichtlich der Diagnose von Supraspinatussehnenrissen.

		ASK		
	supraspinatus	**tear**	**no tear**	**total**
MRI	tear	60 (61.8 %)	1 (1 %)	61 (62.8 %)
	no tear	8 (8.2 %)	28 (28.7 %)	36 (37.1 %)
	total	68 (70.1 %)	29 (29.9 %)	97 (100 %)

MRI

We collected MRI findings from 39 different radiological centers. On average, 2.3 patients were examined by one center (range 1–21). For two centers, a certificate concerning subspecialization in musculoskeletal imaging could be identified. In 89 cases, the MRI protocols were transmitted. Intravenous administration of contrast medium was performed 14 times. Arthrographies were not used.

In order to obtain an indication of the precision of the examination results depending on the clinical question submitted by the requester, the clinical information was divided into the five following groups (double counting possible): suspected SSC tendon tear (3/97), suspected SSP tendon tear 14(97), general rotator cuff lesion (46/97), disorders of the biceps tendon (8/49), and trauma (14/97). The tear was identified correctly by the radiologist in only 1 of 3 received suspected lesions of the SSC tendon. Due to the very heterogeneous information provided by the referring physician, we did not see any statistical significance with regard to a correlation with the accuracy of the findings.

Preoperatively written MRI reports showed a frequency of SSC lesions of 37 of 97 for SSP and of 61 of 97 for SSP/ISP. The correlation with the intraoperative findings resulted in an overall low sensitivity of 38.1 % for the correct diagnosis of an SSC tendon tear confirmed by arthroscopy. With increasing size of the SSC tendon tear, the sensitivity increased (Fox and Romeo I 29.4 %, II 20 %, III 46.7 % and IV 73.3 %). In contrast, the radiologists classified SSP and SSP/ISP tendon tears more often correctly. From 68 arthroscopically proven tears, 60 tears were correctly identified in the written report, which creates an overall sensitivity of 88.2 %. Only 1 of 29 MRI reports was false-positive, which results in a specificity of 96.5 % (▶ **Table 3**).

When comparing the mean intervals between MRI and surgical treatment, a small difference was found depending on the size of the defect but without statistical significance. (Fox and Romeo I: 73.16 d vs. 48.25 d, II: 60.75 d vs. 49.14 d, III: 60.9 d vs. 45.8 d, and IV: 52.8 d vs. 51.2 d (not detected vs. detected)).

Discussion

The main finding of our study is the overall low sensitivity of the written MRI reports for detecting SSC lesions, with a strong tendency to underdiagnose these lesions. Delayed or missed treatment, especially of larger lesions, has detrimental effects on the patient's chances to restore normal shoulder function (as explained above), as well as an additional impact in terms of sick leave and treatment costs for the social system [5]. Clinical diagnosis of an SSC lesion is also difficult [9, 10], highlighting the need for experienced MRI examinations of patients with SSC tendon tears to get the correct diagnosis and timely further therapy.

MRI is the imaging modality of choice for the diagnosis of rotator cuff lesions. Nevertheless, MRI does not always provide appropriate preoperative information, especially in the case of tears involving less than half the cephalad-to-caudal width of the tendon originating in the articulating face [11]. Garavaglia et al. also showed a clearly elevated frequency of arthroscopically determined SSC lesions compared with the radiological report [12]. They showed a sensitivity of 37 % for MRI-documented SSC tendon tears, compared to 38 % in our study. However, all 37 patients with preoperative MRI scans that were interpreted by the radiologists as positive for SSC tendon tears were confirmed to be positive by arthroscopy. This resulted in a sensitivity of 38.1 % and a specificity of 100 %. This is comparable with other studies concerning the value of preoperative MRI in the diagnosis of SSC tendon tears. For example, Adams et al. conducted a retrospective study of patients undergoing shoulder arthroscopy in correlation with preoperative MRI examinations (90 patients). They defined an SSC tendon tear when at least 20 % of the craniocaudal length of the tendon insertion was involved. Their results showed both 100 % specificity and positive predictive value, as well as a sensitivity of 36 %, negative predictive value of 62 %, and an accuracy of 69 %. Larger tears (at least 50 % of the craniocaudal length) were more likely to be seen on MRI than smaller tears (< 50 %) [9]. Foad and Wijdicks evaluated SSC tendon tears using MRI and MR arthrography and reported relatively low sensitivities of 40 % and 36 %, respectively, which were not different between these two techniques, and concluded that there was no advantage for arthrography in the diagnosis of SSC tendon tears [13]. Other authors showed an accuracy of up to 84 % with the use of MRI arthrography. However, it is more expensive and requires intra-articular injection [14].

Our data support the assumption that cranial partial ruptures are especially overlooked with the standard MRI protocols. This low sensitivity arises because lesions of the superior part of the SSC tendon insertion are visualized obliquely on transverse MR images and in parallel on oblique sagittal MR images, which leads to distortion from the partial-volume effect. Most SSC tendon tears start as disinsertion of the superior border of the tendon

and extend inferiorly [15]. This might be the reason for the higher rates for accuracy reported by Ryu et al. using a sagittal oblique technique, with a sensitivity, specificity, and accuracy of SSC tendon tear detection of 0.72, 0.77, and 0.75, respectively, for the radiologists [16]. Additionally, radial slice magnetic resonance images reached sensitivity values of 94.7 % and a specificity of 82.4 % and were promoted as useful for diagnosing these lesions. In particular, the sensitivity for tears in the superior part of the SSC tendon is higher than that of conventional methods [17]. In our study collective, none of the mentioned special sequences were used according to the transmission of the study protocols in the written report. Concerning the tear size, we could demonstrate an increasing sensitivity with increasing tear size (type III 46.7 % and type IV 73.3 %). This underlines the fact that larger and full-thickness tears of the SSC tendon were more frequently detected, which was comparable to other studies [9, 18, 19]. However, still some Fox and Romeo IV lesions were missed. Therefore, we also looked specifically at the time from MRI to arthroscopic diagnosis, and we found no difference between correctly diagnosed and missed Fox and Romeo IV SSC lesions. Moreover, the time from MRI to clinical confirmation and scheduling of an operation was generally short (< 2 months) for these lesions.

Additionally, concurrent pathology of the LHBT can be assessed on axial MRI views. SSC tendon tears are associated with partial rupture or displacement of the biceps from the bicipital groove due to the frequent disruption of the coracohumeral ligament attachment on the humerus at the medial aspect of the bicipital groove ("Pulley lesion") [20, 21]. Therefore, newer studies promote the position of the LHBT in the intertubercular sulcus or lesions of the pulley system as signs associated with SSC tendon tears, which probably can increase the accuracy of detecting SSC tendon tears [22, 23]. The integrity or disintegrity of the LHBT as a marker for severity of a torn SSC tendon is emphasized by our results. However, as Shi et al. mentioned, the diagnostic value of a subluxated LHBT in axial MRI scans lies primarily in its negative predictive value. They pronounced, if there is no subluxation, it is unlikely that a full-thickness tear of the SSC tendon is present. In our study, there were also high rates of LHBT lesions. A subluxation often could not be determined due to older tears with complete retraction of the biceps tendon. Thus, surgeons should be cautious about relying on static biceps subluxation as a primary diagnostic tool for predicting SSC tendon tears [22]. Here, clinical data regarding positive pain symptoms of the LHBT could direct the focus accordingly. In our study, the referring physician noted an indication of biceps pain with a comparatively low frequency (n = 8) compared to the long biceps tendons treated during arthroscopy (n = 79). Thus, arthroscopy remains the gold standard for identifying SSC tendon tears and LHBT co-pathologies [24].

In contrast to the low sensitivity of MRI reports for SSC lesions, the correct diagnosis of SSP lesions in 60 cases was much better and acceptable. A meta-analysis of de Jesus et al. emphasizes the relatively high sensitivity (88 %) of MRI in diagnosing SSP tendon tears without any significant differences between MR arthrography, conventional MRI, and ultrasound regarding full- and partial-thickness tears [25]. There are several studies concerning the accuracy for the detection of rotator cuff lesions, with little attention to abnormalities of the SSC tendon [25–27].

For the future, further improvement of MRI techniques is needed. New protocols or supporting MR series may be helpful to accentuate the ability to also detect small SSC tendon tears and to be more concise with intraoperative findings. It appears important to develop better diagnostic tools and agreement on classification systems for SSC pathology that are universal, as well as easy to manage and reproducible. The main goal of this study is to highlight the importance of specialized shoulder expertise in the diagnosis of rotator cuff lesions, especially SSC lesions, which is often underrepresented in a changing medical landscape. In addition, one may conclude that, with the initiatives of several radiological societies to certify the expertise in musculoskeletal radiology, the diagnostic performance may be better when MRI reports are obtained by a group of radiologists with certified expertise in musculoskeletal radiology. However, since this was not the initial goal of our study and only two radiological centers were identified with musculoskeletal specialization, we cannot prove this with our data. This should be demonstrated in another study.

Study limitations

We are aware that some variables may affect the results since MRI investigations were performed by different outpatient radiologists with varying levels of experience in musculoskeletal imaging and differing imaging protocols. The time interval (in days) from MRI scan to arthroscopic surgery was limited to 180 days. Progression of the tendon lesion is conceivable with a longer interval between MRI and surgical treatment. However, a comparison of the median intervals between detected and undetected ruptures shows a statistically insignificant difference. Thus, the time elapsed between MRI and arthroscopic treatment is not sufficient to explain the low sensitivity. Further limitations are the retrospective cohort study design, with a potential for overreporting bias. Including a large number of different reporting outpatient radiologists (39 radiologic institutions) is a further limitation, because of varying experience and skill levels in the interpretation of MRIs. However, this reflects the current practice in the German health care system and other systems worldwide and thus represents the real clinical quality of care for our patients outside a dedicated musculoskeletal center where every patient received imaging and therapy within this center.

Conclusion

Preoperative MRI and interpretation by a heterogeneous group of general (presumably non-MSK-specialized) radiologic centers do not reliably detect SSC tendon tears and are not sufficient for guiding patients to specialist centers, especially in the case of partial-thickness tears. However, larger and full-thickness SSC tendon tears were also overlooked. Often technical difficulties are the explanation. Therefore, the radiologist's report alone cannot be used as the main tool in terms of patient referral. This study punctuates the need for the experienced examination of patients with SSC tendon tears by radiologists to get the correct diagnosis and timely further therapy. Future studies must show the extent to which specialization in musculoskeletal imaging leads to improved findings.

Conflict of Interest

The authors declare that they have no conflict of interest.

References

[1] Cofield RH, Parvizi J, Hoffmeyer PJ et al. Surgical repair of chronic rotator cuff tears. A prospective long-term study. J Bone Joint Surg Am 2001; 83-A: 71–77

[2] Arai R, Sugaya H, Mochizuki T et al. Subscapularis tendon tear: an anatomic and clinical investigation. Arthroscopy 2008; 24: 997–1004. doi:10.1016/j.arthro.2008.04.076

[3] Lafosse L, Jost B, Reiland Y et al. Structural integrity and clinical outcomes after arthroscopic repair of isolated subscapularis tears. J Bone Joint Surg Am 2007; 89: 1184–1193. doi:10.2106/jbjs.f.00007

[4] Barth JR, Burkhart SS, De Beer JF. The bear-hug test: a new and sensitive test for diagnosing a subscapularis tear. Arthroscopy 2006; 22: 1076–1084. doi:10.1016/j.arthro.2006.05.005

[5] Bartl C, Salzmann GM, Seppel G et al. Subscapularis function and structural integrity after arthroscopic repair of isolated subscapularis tears. Am J Sports Med 2011; 39: 1255–1262. doi:10.1177/0363546510396317

[6] Bartl C, Scheibel M, Magosch P et al. Open repair of isolated traumatic subscapularis tendon tears. Am J Sports Med 2011; 39: 490–496. doi:10.1177/0363546510388166

[7] Burkhart SS, Brady PC. Arthroscopic subscapularis repair: surgical tips and pearls A to Z. Arthroscopy 2006; 22: 1014–1027. doi:10.1016/j.arthro.2006.07.020

[8] Fox JA, Noerdlinger MA, Romeo AA. Arthroscopic subscapularis repair. Tech Shoulder Elb Surg 2003; 4: 154–168

[9] Adams CR, Schoolfield JD, Burkhart SS. Accuracy of preoperative magnetic resonance imaging in predicting a subscapularis tendon tear based on arthroscopy. Arthroscopy 2010; 26: 1427–1433. doi:10.1016/j.arthro.2010.02.028

[10] Adams CR, Brady PC, Koo SS et al. A systematic approach for diagnosing subscapularis tendon tears with preoperative magnetic resonance imaging scans. Arthroscopy 2012; 28: 1592–1600. doi:10.1016/j.arthro.2012.04.142

[11] Lo IK, Burkhart SS. The etiology and assessment of subscapularis tendon tears: a case for subcoracoid impingement, the roller-wringer effect, and TUFF lesions of the subscapularis. Arthroscopy 2003; 19: 1142–1150. doi:10.1016/j.arthro.2003.10.024

[12] Garavaglia G, Ufenast H, Taverna E. The frequency of subscapularis tears in arthroscopic rotator cuff repairs: a retrospective study comparing magnetic resonance imaging and arthroscopic findings. Int J Shoulder Surg 2011; 5: 90–94. doi:10.4103/0973-6042.91000

[13] Foad A, Wijdicks CA. The accuracy of magnetic resonance imaging and magnetic resonance arthrogram versus arthroscopy in the diagnosis of subscapularis tendon injury. Arthroscopy 2012; 28: 636–641. doi:10.1016/j.arthro.2011.10.006

[14] Jung JY, Jee WH, Chun CW et al. Diagnostic performance of MR arthrography with anterior trans-subscapularis versus posterior injection approach for subscapularis tendon tears at 3.0T. Eur Radiol 2017; 27: 1303–1311. doi:10.1007/s00330-016-4467-3

[15] Sakurai G, Ozaki J, Tomita Y et al. Incomplete tears of the subscapularis tendon associated with tears of the supraspinatus tendon: cadaveric and clinical studies. J Shoulder Elbow Surg 1998; 7: 510–515

[16] Ryu HY, Song SY, Yoo JC et al. Accuracy of sagittal oblique view in preoperative indirect magnetic resonance arthrography for diagnosis of tears involving the upper third of the subscapularis tendon. J Shoulder Elbow Surg 2016; 25: 1944–1953. doi:10.1016/j.jse.2016.02.038

[17] Furukawa R, Morihara T, Arai Y et al. Diagnostic accuracy of magnetic resonance imaging for subscapularis tendon tears using radial-slice magnetic resonance images. J Shoulder Elbow Surg 2014; 23: e283–e290. doi:10.1016/j.jse.2014.03.011

[18] Lin L, Yan H, Xiao J et al. The diagnostic value of magnetic resonance imaging for different types of subscapularis lesions. Knee Surg Sports Traumatol Arthrosc 2016; 24: 2252–2258. doi:10.1007/s00167-014-3335-4

[19] Malavolta EA, Assunção JH, Guglielmetti CL et al. Accuracy of preoperative MRI in the diagnosis of subscapularis tears. Arch Orthop Trauma Surg 2016; 136: 1425–1430. doi:10.1007/s00402-016-2507-8

[20] Walch G, Nové-Josserand L, Boileau P et al. Subluxations and dislocations of the tendon of the long head of the biceps. J Shoulder Elbow Surg 1998; 7: 100–108

[21] Urita A, Funakoshi T, Amano T et al. Predictive factors of long head of the biceps tendon disorders-the bicipital groove morphology and subscapularis tendon tear. J Shoulder Elbow Surg 2016; 25: 384–389. doi:10.1016/j.jse.2015.12.015

[22] Shi LL, Mullen MG, Freehill MT et al. Accuracy of long head of the biceps subluxation as a predictor for subscapularis tears. Arthroscopy 2015; 31: 615–619. doi:10.1016/j.arthro.2014.11.034

[23] Naimark M, Zhang AL, Leon I et al. Clinical, radiographic, and surgical presentation of subscapularis tendon tears: a retrospective analysis of 139 patients. Arthroscopy 2016; 32: 747–752. doi:10.1016/j.arthro.2015.11.019

[24] Smucny M, Shin EC, Zhang AL et al. Poor agreement on classification and treatment of subscapularis tendon tears. Arthroscopy 2016; 32: 246–251, e241. doi:10.1016/j.arthro.2015.08.006

[25] de Jesus JO, Parker L, Frangos AJ et al. Accuracy of MRI, MR arthrography, and ultrasound in the diagnosis of rotator cuff tears: a meta-analysis. Am J Roentgenol 2009; 192: 1701–1707. doi:10.2214/ajr.08.1241

[26] Waldt S, Bruegel M, Mueller D et al. Rotator cuff tears: assessment with MR arthrography in 275 patients with arthroscopic correlation. Eur Radiol 2007; 17: 491–498. doi:10.1007/s00330-006-0370-7

[27] Pfirrmann CW, Zanetti M, Weishaupt D et al. Subscapularis tendon tears: detection and grading at MR arthrography. Radiology 1999; 213: 709–714. doi:10.1148/radiology.213.3.r99dc03709