

Gadolinium-based contrast agents: What we learned from acute adverse events, nephrogenic systemic fibrosis and brain retention

Gadolinium-haltige Kontrastmittel nach anaphylaktoiden Reaktionen, nephrogener systemischer Fibrose und Hirnretention – was haben wir gelernt?

Authors

Tobias Bäuerle, Marc Saake, Michael Uder

Affiliation

Institute of Radiology, University Medical Center, Erlangen, Germany

Key words

gadolinium-based contrast agents, acute adverse events, nephrogenic systemic fibrosis, gadolinium retention

received 22.07.2020

accepted 24.11.2020

published online 21.12.2020

Bibliography

Fortschr Röntgenstr 2021; 193: 1010–1018

DOI 10.1055/a-1328-3177

ISSN 1438-9029

© 2020, Thieme. All rights reserved.

Georg Thieme Verlag KG, Rüdigerstraße 14, 70469 Stuttgart, Germany

Correspondence

Prof. Tobias Bäuerle

Institute of Radiology, University Medical Center, Maximiliansplatz 3, 91054 Erlangen, Germany

Tel.: +49/91 31/8 52 33 43

Fax: +49/91 31/8 53 60 68

tobias.baeyerle@uk-erlangen.de

ABSTRACT

Background Radiologists have been administering gadolinium-based contrast agents (GBCA) in magnetic resonance imaging for several decades, so that there is abundant experience with these agents regarding allergic-like reactions, nephrogenic systemic fibrosis (NSF) and gadolinium retention in the brain.

Methods This review is based on a selective literature search and reflects the current state of research on acute adverse effects of GBCA, NSF and brain retention of gadolinium.

Results Due to the frequent use of GBCA, data on adverse effects of these compounds are available in large collectives. Allergic-like reactions occurred rarely, whereas severe acute reactions were very rarely observed. Systemic changes in NSF also occur very rarely, although measures to avoid NSF resul-

ted in a significantly reduced incidence of NSF. Due to gadolinium retention in the body after administration of linear MR contrast agents, only macrocyclic preparations are currently used with few exceptions. Clear clinical correlates of gadolinium retention in the brain could not be identified so far. Although the clinical added value of GBCA is undisputed, individual risks associated with the injection of GBCA should be identified and the use of non-contrast enhanced MR techniques should be considered. Alternative contrast agents such as iron oxide nanoparticles are not clinically approved, but are currently undergoing clinical trials.

Conclusion GBCA have a very good risk profile with a low rate of adverse effects or systemic manifestations such as NSF. Gadolinium retention in the brain can be minimized by the use of macrocyclic GBCA, although clear clinical correlates due to gadolinium retention in the brain following administration of linear GBCA could not be identified yet.

Key Points:

- Acute adverse effects are predominantly mild/moderate, rarely severe reactions occur.
- International guidelines resulted in significant reduction of nephrogenic systemic fibrosis.
- Application of macrocyclic contrast agents minimizes gadolinium retention in the brain.

Citation Format

- Bäuerle T, Saake M, Uder M. Gadolinium-based contrast agents: What we learned from acute adverse events, nephrogenic systemic fibrosis and brain retention. Fortschr Röntgenstr 2021; 193: 1010–1018

ZUSAMMENFASSUNG

Hintergrund Radiologen verabreichen Gadolinium-haltige Kontrastmittel (GBCA) in der Magnetresonanztomografie seit mehreren Jahrzehnten, sodass umfangreiche Erfahrung mit diesen Präparaten bezüglich anaphylaktoider Reaktionen, nephrogener systemischer Fibrose (NSF) und Retentionen von Gadolinium im Gehirn besteht.

Methode Diese Übersichtsarbeit basiert auf einer selektiven Literaturrecherche und gibt den aktuellen Forschungsstand bezüglich akuter unerwünschter Wirkungen, NSF und Hirnre-

tentionen von Gadolinium nach Verabreichung von GBCA wieder.

Ergebnisse Aufgrund der häufigen Verwendung von GBCA liegen Daten über unerwünschte Wirkungen dieser Verbindungen in großen Kollektiven vor. Anaphylaktoide Reaktionen traten dabei selten auf, wobei schwere akute Reaktionen sehr selten zu beachten waren. Zu den systemischen Veränderungen der NSF kommt es ebenfalls sehr selten, wobei Maßnahmen zur Vermeidung der NSF in einer signifikant reduzierten Inzidenz der NSF resultierten. Aufgrund der Gadolinium-Retention im Körper nach Verabreichung von linearen MR-Kontrastmitteln werden derzeit mit wenigen Ausnahmen nur noch makrozyklische Präparate eingesetzt. Eindeutige klinische Korrelate von Gadolinium-Retentionen im Gehirn

konnten bislang nicht identifiziert werden. Obwohl der klinische Mehrwert von GBCA unbestritten ist, sollten individuelle Risiken in Verbindung mit der Injektion von GBCA ermittelt und der Einsatz nativer MR-Techniken erwogen werden. Alternative Kontrastmittel, wie beispielsweise Eisenoxid-Nanopartikel, sind nicht klinisch zugelassen, befinden sich aber aktuell in klinischer Prüfung.

Schlussfolgerung Gadolinium-haltige Kontrastmittel weisen ein sehr gutes Risikoprofil auf mit einer geringen Rate unerwünschter Wirkungen. Lineare GBCA führen zu Gadolinium-Retentionen im Gehirn, klinische Korrelate sind jedoch nicht gesichert. Durch die Verwendung von makrozyklischen Kontrastmitteln lässt sich die Gadolinium-Retention im Gehirn minimieren.

Introduction

For decades gadolinium-based contrast agents (GBCA) have been used in magnetic resonance imaging in which the contained gadolinium cation (Gd^{3+}) shortens the T1 relaxation time of protons due to its paramagnetic behavior. Since gadolinium is a toxic heavy metal, it can only be injected into humans when bound in a chemical complex. A distinction is made between GBCA with a linear chelator (linear contrast agent) and GBCA with a macrocyclic chelator (macrocyclic contrast agent; ► **Table 1**). The stability of the complexation of gadolinium with linear contrast agents is significantly lower than that with macrocyclic agents [1, 2]. GBCAs currently play a central role in diagnostic imaging to increase soft tissue contrast in MRI, characterize pathological structures and detect vascularization and perfusion in tissues.

As with every active ingredient used in medicine, desirable and undesirable effects are also known with gadolinium-based contrast agents [3]. Since the approval of gadopentetate (Magnevist) in 1988, immediate-type adverse effects in the sense of an anaphylactoid reaction have been known. Linear preparations (gadobenate, gadodiamide, gadoversetamide, gadofosveset, gadoxetate; ► **Table 1**) and macrocycles (gadobutrol, gadoteridol and gadoterate/gadoteric acid; ► **Table 1**) approved in subsequent years showed comparable rates of adverse effects [4].

In connection with the administration of GBCAs, Grobner and colleagues in 2006 first reported a symptom complex of nephrogenic systemic fibrosis with diffuse fibrotic or scleroderma-like changes of the skin and internal organs due to the activation of fibroblasts and cytokines by gadolinium [5]. The retention of gadolinium in the brain after multiple administrations of GBCAs was described in a publication by Kanda et al. in 2014 when they reported T1 hyperintensity in the dentate nucleus and globus pallidus after multiple administrations of linear contrast agents [6].

Radiologists therefore can look back on decades of experience with intravenous administration of GBCAs. The following is a summary of recent studies based on a literature review of immediate adverse effects, nephrogenic systemic fibrosis and gadolinium retention in the brain.

Undesired Immediate Reactions

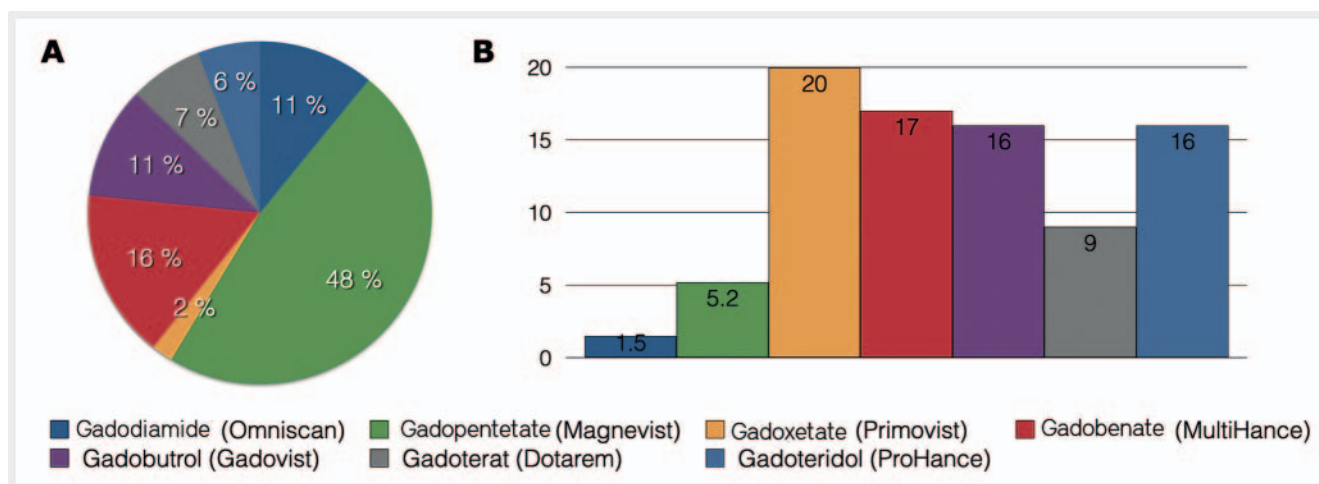
Although GBCAs have excellent tolerability and a low risk profile, there may be immediate adverse effects [7, 8]. A distinction should be made between allergoid or anaphylactoid (allergy-like reactions) and physiological reactions. Anaphylactoid reactions such as urticaria, itching and edema manifest themselves similarly to allergies, but a specific antibody-antigen interaction cannot always be detected [9]. There is usually no correlation between dose or concentration and reaction. The treatment of anaphylactoid reactions is similar to that of allergic reactions [10]. In contrast, physiological reactions such as nausea or vomiting are often dose- or concentration-dependent and are usually based on direct chemotoxicity, osmotoxicity or molecular interaction with activators. On the whole, undesired immediate reactions are classified according to severity: mild (nausea, minor vomiting, mild urticaria, itching), moderate (violent vomiting, clearly visible urticaria, bronchospasm, facial/laryngeal edema, vasovagal syncope) and severe (hypotensive shock, respiratory arrest, cardiac arrest, cerebral seizure) [11].

Immediate adverse effects usually occur within an hour after intravenous administration of GBCA [12]. Since these events are rare, it is difficult to find clear differences between the individual preparations and to describe risk factors that influence the occurrence of undesirable effects. Due to the high number of GBCA doses administered intravenously so far, single-center studies or meta-analyses have been published in recent years which integrate a large number of contrast media and applications.

In a meta-analysis, Behzadi et al. included 9 studies in which anaphylactoid responses to GBCA in 716 978 injections met the inclusion and exclusion criteria [13]. The total rate of allergic reactions was 9.2/10 000 administrations, with 0.5/10 000 injections classified as severe acute effects. Of these reactions, 539/662 (81 %) were mild, 86/662 (13 %) moderate, and 37/662 (6 %) were severe. The severe reactions resulted in two deaths attributed to the administration of gadobenate and gadobutrol, a rate of 2.7/1000 000 applications. Of all included GBCA applications, gadodiamide showed the lowest rate of reaction at 1.5/10 000 administrations, which was significantly below that of macrocyclic contrast

► **Table 1** Characteristics of gadolinium-based contrast agents.

drug	trade name	molecular structure	ionic/non-ionic
Gadobutrol	Gadovist	cyclical	non-ionic
Gadoteridol	ProHance	cyclical	non-ionic
Gadoterate	Dotarem	cyclical	ionic
Gadobenate	MultiHance	linear	ionic
Gadopentetate	Magenevist	linear	ionic
Gadodiamide	Omniscan	linear	non-ionic
Gadoversetamide	Optimark	linear	non-ionic
Gadofosveset	Vasovist	linear	ionic
Gadoxetate	Primovist	linear	ionic



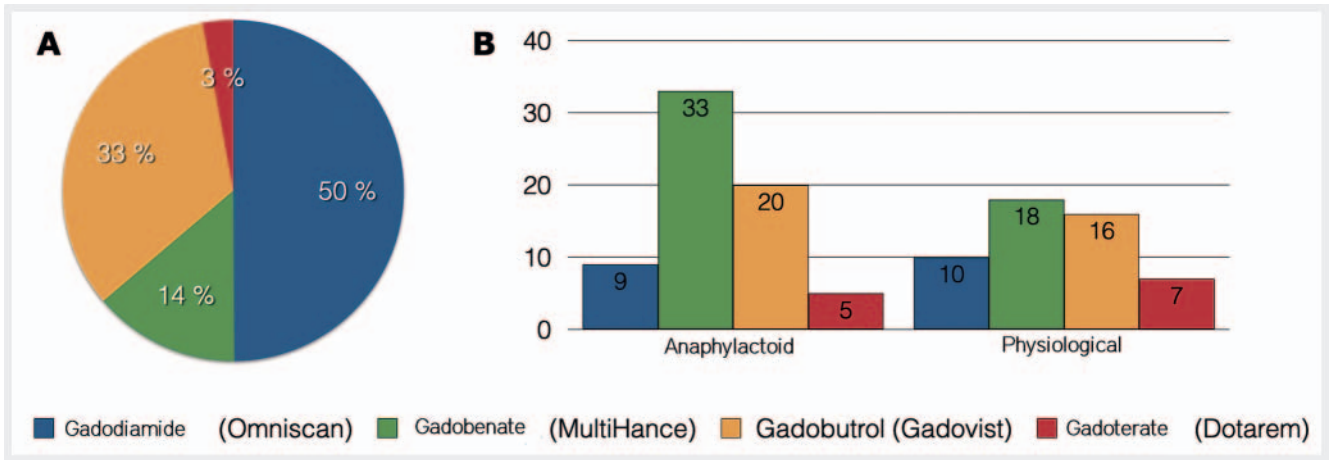
► **Fig. 1** Meta-analysis by Behzadi et al (Radiology 2018). **A** Proportion of GBCA in the meta-analysis and **B** number of anaphylactoid reactions of GBCA per 10 000 injections. Investigated substances: Gadodiamide (Omniscan), gadopentetate (Magnevist), gadoxetate (Eovist, Primovist), gadobenate (MultiHance), gadobutrol (Gadovist), gadoterate meglumine (Dotarem), gadoteridol (Prohance) and gadofosveset (Vasovist, 797 injections, not shown).

agents such as gadoteridol (16/10 000 applications), gadobutrol (16/10 000 applications) and gadoterate (9/10 000 applications, ► **Fig. 1**).

In comparison among GBCA classes, non-ionic linear GBCAs (1.5/10 000 injections) showed fewer anaphylactoid reactions than ionic linear GBCAs and non-ionic macrocyclic GBCA (8.3 and 16/10 000 injections, respectively). Ionic linear GBCAs with a tendency to protein binding (gadoxetate, gadofosveset and gadobenate) were more frequently associated with anaphylactoid reactions compared to ionic linear preparations without protein binding (gadopentetate; 17 versus 5.2/10 000 injections). Furthermore, linear GBCAs without protein binding induced fewer allergoid reactions than macrocyclic contrast media without protein binding (4.4 versus 14/10 000 applications) [13]. Overall, the GBCA ionic, protein-binding and macrocyclic characteristics were linked to a higher rate of undesirable effects. However, this conclusion was criticized by Raynaud and colleagues, since the study by Behzadi et al. only included non-ionic macrocyclic GBCAs [14].

In further studies, the frequency of adverse effects caused by ionic macrocyclic gadoterate was largely identical to that of gadodiamide [15] and significantly lower than that of gadopentetate, gadobenate and gadobutrol [3, 16, 17].

A single-center study by McDonald et al. included 158 100 patients representing 281 945 GBCA injections to investigate anaphylactoid and physiological adverse effects of the drugs gadodiamide (140 645 injections), gadobutrol (94 109 injections), gadobenate (39 138 injections) and gadoterate (8053 injections) (► **Fig. 2A**) [18]. In a multivariate analysis, gadobenate or gadobutrol showed higher rates of adverse allergic effects compared to gadodiamide (gadobenate OR 3.9, gadobutrol OR 2.3) or gadoterate (gadobenate OR 4.8; gadobutrol OR 2.8). Physiological acute effects were higher after injection of gadoterate (OR 7.7), gadobenate (OR 1.8) and gadobutrol (OR 1.6) than after gadodiamide. In the monocentric study there were 6 severe allergoid reactions requiring hospitalization (anaphylactoid reactions: mild 62%, moderate 36%, severe 2%). Severe physiological reactions were



► **Fig. 2** Monocentric study by McDonald et al (Radiology 2019). **A** Proportion of GBCA in the monocentric study and **B** number of adverse reactions (anaphylactoid and physiological) of GBCA per 10 000 injections. Substances studied: Gadodiamide (Omniscan), gadobenate (MultiHance), gadobutrol (Gadovist) and gadoterate meglumine (Dotarem).

not observed (mild 88 %, moderate 12 %). For comparison with the above meta-analysis, ► **Fig. 2B** shows the rates of anaphylactoid and physiological reactions per 10 000 injections.

In a European study of 72 839 patients who received a cardiac MRI, 260 patients reported adverse acute reactions (0.36 %), with only 24 (0.03 %) classified as severe [19]. Allergoid reactions were more frequent than physiological ones (71 % versus 29 %). In addition, there was a correlation between stressors (adenosine or regadenoson) administered during cardiac MRI and GBCAs, as patients without stress testing showed an acute reaction significantly less frequently than those after stress testing (0.22 % versus 0.75 %).

As noted above, immediate adverse effects are rare or very rare events. In this respect, disproportionate comparisons – even in extensive meta-analyses – can lead to conclusions of limited validity.

Nephrogenic Systemic Fibrosis

Nephrogenic systemic fibrosis (NSF) is a systemic disease characterized by fibrotic skin and organ changes in patients with chronic kidney disease (stage 4/5) or acute renal failure. Such systemic changes were already described in 2000, and in 2006 these manifestations were linked to the administration of linear GBCAs [5] [20]. Pathophysiologically, the release of the gadolinium ion from a linear or macrocyclic bond leads to an activation of local and circulating fibroblasts and the expression of fibronectin, which leads to fibrosis of skin and other tissues (the CD34- and alpha-SMA-mediated local and systemic activation of fibroblasts is summarized in [21]). The relevance of renal function prior to administration of contrast agents containing Gd. has been described by the German Federal Institute for Drugs and Medical Devices (BfArM), the European Medical Agency (EMA), US Food and Drug Administration (FDA) and other organizations. If the eGFR is below 30 mL/min/1.73 m², GBCAs may only be administered to a limited extent or those with an increased NSF risk must

be avoided (► **Table 2, 3**). The different release rates of gadolinium ions from the respective contrast agents result in their classification into different risk groups as shown in ► **Table 2**. Here it should be explicitly mentioned again that medium- and low-risk contrast agents (► **Table 2**) may be administered independently of renal function according to the specifications of the German Federal Institute for Drugs and Medical Devices and the EMA, but in the case of eGFR < 30 mL/min/1.73 m², repeated administration within 7 days should be avoided (► **Table 3**).

A meta-analysis by Attari and colleagues included 693 patients from 173 articles with biopsy-confirmed NSF [22]. With respect to gender of NSF patients, the ratio was nearly balanced (women 46 %; men 54 %), with the majority of patients receiving dialysis at the time of exposure to GBCAs (82 %) or with renal failure (acute, 20 %; chronic, 81 %). The onset of symptoms was reported in 177 patients and averaged 49 years of age (range 6–87 years). Cases of children under 6 years of age were not reported and only 7 patients over 80 years of age were diagnosed with NSF.

Exposure to GBCAs was reported in 529 patients with biopsy-confirmed NSF, with 307 patients (76 %) developing NSF after administration of gadodiamide, 49 (12 %) after gadopentetate, 6 (2 %) after gadoversetamide, 1 (0.2 %) after gadobutrol, 1 (0.2 %) after gadobenate (► **Fig. 3A**). After 2008, only 7 NSF cases were reported, significantly fewer than in previous years. With regard to symptoms, almost all patients developed skin changes (96 % skin plaques, 95 % skin thickening/hardening). In addition, 71 % of patients reported edema and movement restrictions. Internal organ involvement was present in 56 % of cases (► **Fig. 3B**). When patients were followed-up, recovery was observed in 4 % and improvement in 28 % of patients. A total of 110 patients (32 %) died, with only 4 deaths (1 %) reported in direct association with NSF. Thirty patients (9 %) reported worsening or severe limitations, and a total of 26 (7 %) were dependent on a walking aid or wheelchair as a result of NSF (► **Fig. 3C**).

Due to the small number of NSF patients and the lack of a control group, only limited conclusions can be drawn from these figures. For example, cases in children under the age of 6 or adults

► **Table 2** Classification of the Bundesinstituts für Arzneimittel und Medizinprodukte (German Federal Institute for Drugs and Medical Devices) regarding the risk of developing nephrogenic systemic fibrosis (NSF) as of 09/07/2010.

high risk	Gadodiamide (Omniscan), Gadopentetate (Magnevist), Gadoversetamide (Optimark)
medium risk	Gadobenate (MultiHance), Gadoxetate (Primovist), Gadofosveset (Vasovist)
low risk	Gadoterate (Dotarem), Gadobutrol (Gadovist), Gadoteridol (ProHance)

► **Table 3** Administration of GBCA according to the main information of the Bundesinstituts für Arzneimittel und Medizinprodukte (German Federal Institute for Drugs and Medical Devices) and the European Medicinal Agency as of 09/07/2010 Indication of the eGFR in mL/min/1.73 m².

	risk		
	high	medium	low
renal insufficiency confirmation	must	should	should
eGFR < 30	contraindication	low dose, not repeated within the following 7 days	
eGFR 30–59	low dose, not repeated within the following 7 days	no limitation	
breast feeding	discontinue breast feeding (24 h)	physician and mother decide	

over 87 cannot be ruled out [23]; likewise, the individual risk of falling ill with NSF cannot be derived from the generated figures. Overall, however, it must be noted that the measures taken succeeded in almost completely eliminating NSF after 2008, in particular GFR screening for impaired kidney function. Nevertheless, we should not forget that the overall risk of NSF is very low, even with reduced renal function. On the other hand, there is a significant diagnostic benefit of a contrast-enhanced MRI for a given indication. Studies on the disadvantages caused by not administering GBCAs are currently not available.

Gadolinium Retention in the Brain

In 2014 Kanda et al. first reported on the retention of gadolinium in the brain with the discovery of T1 hyperintensity in the globus pallidus and dentate nucleus after multiple administrations of the GBCAs gadodiamide and gadopentetate [6]. The following year Radbruch et al. reported that these signal alterations in the globus pallidus and dentate nucleus could not be detected after several injections of gadobutrol [24]. Several studies have shown that T1w hyperintense signaling occurs in these core regions after administration of linear contrast agents (e. g., gadopentetate,

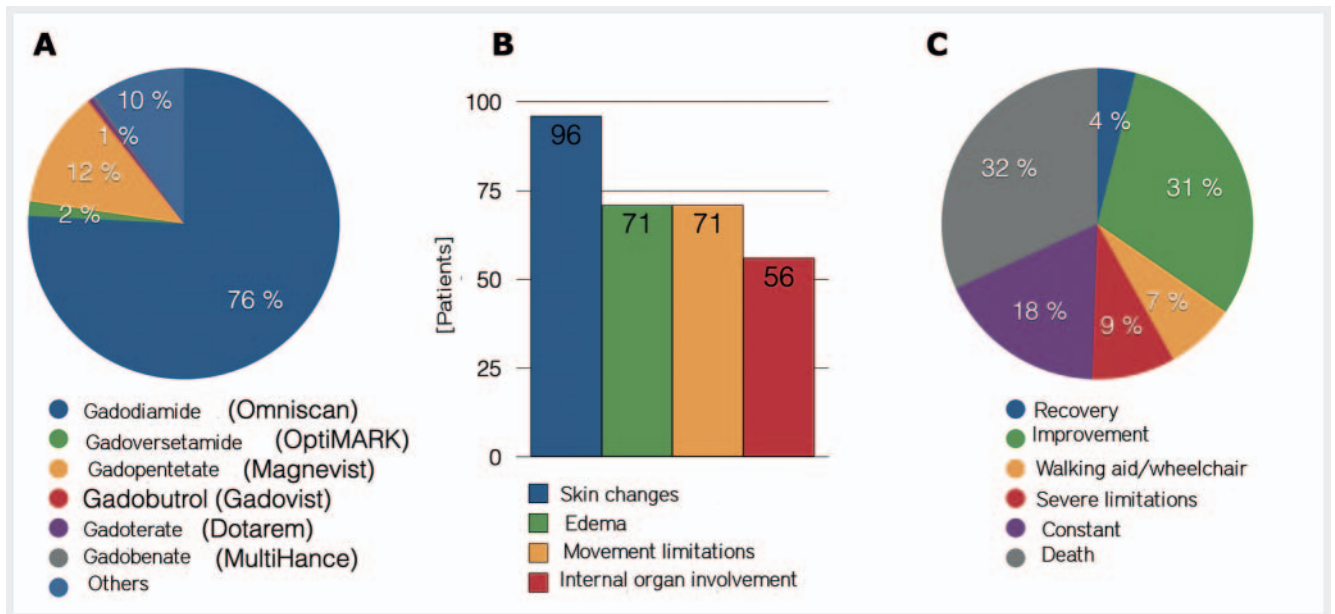
gadobenate and gadodiamide), but not after application of macrocyclic agents (such as gadobutrol, gadoteridol and gadoterate) [25]. Even after 20 or more administrations of gadoterate/gadobutrol in a cohort of glioma patients, no T1 signal alterations were detected in the dentate nucleus [26].

Correspondingly, using mass spectroscopic analysis in the brains of deceased patients after at least 4 injections of gadodiamide, McDonald measured the tissue concentration of gadolinium in the pons (median 0.3 µg Gd/g tissue; range 0.1–0.6), thalamus (median 0.5 µg Gd/g tissue; range 0.2–1.6), globus pallidus (median 1.7 µg Gd/g tissue; range 0.6–4.4) and dentate nucleus (median 6.6 µg Gd/g tissue; range 1.6–18.6); however, the measured T1 signal intensity did not correlate with the absolute tissue concentration of gadolinium [27]. In a comparison of tissue concentrations of gadolinium in the brain of different preparations determined by mass spectroscopy, Murata and colleagues succeeded in demonstrating that linear contrast media caused significantly higher gadolinium tissue concentrations in the globus pallidus than macrocycles [28]. In addition to gadolinium retention in the above-mentioned core areas, the cerebral cortex is also affected, since gadolinium was also detected by mass spectroscopy after multiple applications of linear contrast agents [29].

In addition to determination of gadolinium concentrations *ex vivo*, the focus was on MR measurement techniques for the standardized determination of gadolinium retention *in vivo* [30, 31]. In the majority of the studies the signal intensities were measured in T1-weighted sequences and related (ratio of nucleus dentatus to pons and globus pallidus to thalamus). In recent years, absolute measurements of T1 relaxation times have also been used in mapping techniques. This has the advantage that no reference tissues (especially thalamus and pons) have to be included because, as shown in the above-mentioned Murata study, they contain gadolinium themselves and are therefore only conditionally suitable as divisors [28].

In a retrospective study, Kang et al. found significantly decreased T1 relaxation times of the globus pallidus after multiple injections of gadobutrol, with T1 relaxation time independent of the number of gadobutrol injections [32]. In contrast, Deike-Hoffmann et al. in a retrospective analysis reported that after multiple administrations of gadobutrol there was no change in the T1 relaxation time, neither in globus pallidus nor in other core regions [33]. In a prospective study with 220 individuals who did not show brain pathologies on MRI, there was a significant reduction in T1 relaxation times in the globus pallidus after multiple gadobutrol doses, analogous to the above-mentioned study by Kang et al., where the number of gadobutrol doses correlated inversely with the T1 relaxation time, as a possible correlate to Gd retention in this core region [34]. Corresponding to these results Choi et al. reports in a recent paper on Quantitative Susceptibility Mapping (QSM) in the globus pallidus after multiple administrations of gadobutrol, whereby the magnetic susceptibility in this core correlated with the number of gadobutrol injections [35]. A visual correlation of shortened T1 relaxation times or magnetic susceptibility after gadobutrol was not detectable in the T1-weighted image of patients in these studies [34, 35].

The reason for the visual detection of retained gadolinium on native MRI images of the brain after repeated administration of



► **Fig. 3** Meta-analysis in patients with nephrogenic systemic fibrosis (NSF) by Attari et al (Radiology 2019). **A** Contrast medium used (405 patients): gadodiamide (Omniscan), gadoversetamide (OptiMARK), gadopentetate (Magnevist), gadobutrol (Gadovist), gadoterate meglumine (Dotarem), gadobenate (MultiHance) and others. **B** Clinical manifestations (418 patients). **C** Clinical manifestation over the course of the disease (341 patients). Illustrations simplified according to Attari et al. Radiology 2019.

linear but not macrocyclic contrast agents is mainly due to the chemical compound in which the gadolinium is present [36, 37]. Frenzel and colleagues state that gadolinium is either in a soluble, small-molecule form (e. g. as intact GBCA), in a soluble form bound to macromolecules, or in a non-soluble form [38]. The last two forms appear to be responsible for the retention of gadolinium. After gadolinium has been dissolved out of the linear GBCA, it binds to macromolecules [38]; due to their high relaxivity, these macromolecular compounds are responsible for the hyperintensity on T1-weighted images [39].

These findings of gadolinium retention in the brain give rise to many questions currently under investigation; these deal with how gadolinium gains access to diseased and above all healthy brain tissue, and how gadolinium exits the brain tissue [40]. Obviously, perivascular spaces, such as periarterial and pial-gial pathways (the so-called glymphatic system), play an essential role [41]. With regard to elimination, complexed gadolinium in intact GBCA appears to leave the brain more easily in order to be excreted afterwards than what is released from the chelator [42].

In addition to the retention of gadolinium in the brain, other organs in which gadolinium is retained or deposited are currently in focus, such as bones, skin and the nervous system [43–45]. The depositing of gadolinium in other organs was described well before brain retention, e. g. in the skin by the pathogenesis of NSF, but also in bone [46, 47]. The absolute concentrations of gadolinium were significantly higher in skin and bone than in the brain [48]. In animal experiments, higher gadolinium concentrations were also determined in peripheral nerves and the spinal cord than in the brain after administration of linear GBCAs; the measured gadolinium after injection of macrocycles was found to be lower overall in these locations [49]. In another animal study by

Radbruch et al., it was possible to describe indications of GBCA-induced neuropathy, especially after the application of linear GBCA [50].

The body of studies is limited with respect to clinical correlates of gadolinium retention in the brain. Patients with multiple sclerosis demonstrated changes in information processing and reduced speech flow after administration of linear and macrocyclic contrast agents [51]. However, a study of a cohort of patients without known cerebral pathology demonstrated no neurological correlates using neurological or neurocognitive analyses and functional MRI [52]; the study included patients with Crohn's disease and control persons who had received 4 or more injections of gadodiamide. Likewise, no clear connection between gadolinium retention and clinical or neurological correlates has been found in other studies [53–56].

Contrary to the current study situation, diffuse symptoms were reported in individual cases after administration of GBCA, which was referred to as Gadolinium Deposition Disease (GDD) [57, 58]. Affected patients report multilocal pain, predominantly cerebral and osseous; symptoms overlap with the described complaints of NSF, as in the case of skin thickening [58]. Intravenously administered calcium or zinc trisodium pentetate has been proposed as a possible therapy for GDD, with reports of increased gadolinium concentration in the urine as an indication of trapped retained gadolinium. Since there is no clear scientific proof of the existence of GDD, a warning is issued against the uncritical use of chelation therapy, as possible adverse effects of this procedure could occur [59]. This opinion is shared by the German Federal Institute for Drugs and Medical Devices, which does not recognize GDD as a disease entity and therefore does not recommend therapeutic intervention (<https://www.bfarm.de/SharedDocs/Risikoin>

formationen/Pharmakovigilanz/DE/RV_STP/g-I/gadolinium-kern spin-neu.html).

Alternative Techniques

Alternative intravenous MR contrast agents without gadolinium are currently not approved for routine imaging. Due to the superparamagnetic properties of iron, particulate iron compounds have been used in magnetic resonance imaging for over 20 years. In 2003, Weissleder's research group reported on the use of iron oxide nanoparticles for the diagnosis of lymph node metastases in patients with prostate carcinoma, which, however, required a two-stage examination every 24 hours [60]. Due to the uptake of iron oxide nanoparticles in non-tumor-infected lymph node tissue and the resulting signal drop, metastases in lymph nodes in the absence of signal drop could be detected with high sensitivity using this technique. In current studies, iron supplements such as ferumoxytol are used in the MRI, which is off-label use, as this drug has only been approved in the USA and Europe for the treatment of iron deficiency anemia. In a multicenter study on the use of ferumoxytol in MRI, it was recently reported that the compound was well tolerated and thus attested to a good safety profile. In the study, 3215 patients received a total of 4240 ferumoxytol injections (1–11 mg/kg), with 83 adverse effects (1.9%) reported, of which 75 were mild and 8 moderate [61]. With regard to indication, this contrast agent is particularly suitable for vascular imaging, since ferumoxytol remains primarily intravascular for up to 15 hours after administration, is absorbed by macrophages from one day after injection and is transferred to the body's iron store starting 15 days after injection.

Due to improved native imaging techniques, such as diffusion-weighted imaging, it has been possible in recent years to dispense with intravenous administration of contrast agents in many indications without making diagnostic compromises. For example, contrast medium-free techniques for abdominal MRI are increasingly being used in children, or techniques such as arterial spin labeling (ASL), time of flight (TOF), susceptibility-weighted imaging (SWI), phase contrast imaging or MR spectroscopy are increasingly being propagated in neuroradiology [62, 63].

Conclusions

What have we radiologists learned from our previous experience with gadolinium-based products? Quite a lot. Above all, with GBCA preparations for non-invasive MR imaging, contrast agents are available with an excellent risk profile with a very low frequency of undesirable effects. With an incidence of severe allergic reactions is less than 1 per 10 000 injections, we have excellent preparations at our disposal. In addition, undesired reactions can be treated sufficiently by keeping emergency drugs and measures on hand. On the other hand, we have learned that with proper management, such as implementation of guidelines for the use of GBCAs by national and international institutes such as the Federal Institute for Drugs and Medical Devices in Germany, NSF could almost be eliminated. Finally, the presence of gadolinium retention in the brain is also being discussed less and less critically.

This was achieved by largely dispensing with linear contrast agents and recognizing that macrocyclic preparations only lead to minimal retention in the brain. The debate on gadolinium retention was also calmed by the fact that to date no clear clinical correlation of this retention has been demonstrated, even after multiple administrations of linear contrast agents.

In view of the great clinical added value of contrast agents containing gadolinium, their use is still undoubtedly justified. Nevertheless, it is the responsibility of the radiologist to check the indication of contrast agent administration individually and to consider whether a comparable statement can be made using native MR techniques such as diffusion-weighted imaging. An equivalent substitution of GBCAs by other preparations is currently not possible. An alternative in some areas – e. g. in MR angiography by iron oxide nanoparticles – is currently being tested.

Conflict of Interest

The authors declare that they have no conflict of interest.

References

- [1] Frenzel T, Lengsfeld P, Schirmer H et al. Stability of gadolinium-based magnetic resonance imaging contrast agents in human serum at 37 degrees C. *Invest Radiol* 2008; 43: 817–828. doi:10.1097/RLI.0b013e3181852171
- [2] Idee JM, Port M, Robic C et al. Role of thermodynamic and kinetic parameters in gadolinium chelate stability. *J Magn Reson Imaging* 2009; 30: 1249–1258. doi:10.1002/jmri.21967
- [3] Matsumura T, Hayakawa M, Shimada F et al. Safety of gadopentetate dimeglumine after 120 million administrations over 25 years of clinical use. *Magn Reson Med Sci* 2013; 12: 297–304. doi:10.2463/mrms.2013-0020
- [4] Ramalho M, Ramalho J. Gadolinium-Based Contrast Agents: Associated Adverse Reactions. *Magn Reson Imaging Clin N Am* 2017; 25: 755–764. doi:10.1016/j.mric.2017.06.006
- [5] Grobner T. Gadolinium – a specific trigger for the development of nephrogenic fibrosing dermopathy and nephrogenic systemic fibrosis? *Nephrol Dial Transplant* 2006; 21: 1104–1108. doi:10.1093/ndt/gfk062
- [6] Kanda T, Ishii K, Kawaguchi H et al. High signal intensity in the dentate nucleus and globus pallidus on unenhanced T1-weighted MR images: relationship with increasing cumulative dose of a gadolinium-based contrast material. *Radiology* 2014; 270: 834–841. doi:10.1148/radiol.13131669
- [7] Costello JR, Kalb B, Martin DR. Incidence and Risk Factors for Gadolinium-Based Contrast Agent Immediate Reactions. *Top Magn Reson Imaging* 2016; 25: 257–263. doi:10.1097/RMR.000000000000109
- [8] Fok JS, Smith WB. Hypersensitivity reactions to gadolinium-based contrast agents. *Curr Opin Allergy Clin Immunol* 2017; 17: 241–246. doi:10.1097/ACI.0000000000000371
- [9] Tasker F, Fleming H, McNeill G et al. Contrast media and cutaneous reactions. Part 2: Delayed hypersensitivity reactions to iodinated contrast media. *Clin Exp Dermatol* 2019; 44: 844–860. doi:10.1111/ced.13991
- [10] Dillman JR, Trout AT, Davenport MS. Allergic-like contrast media reaction management in children. *Pediatr Radiol* 2018; 48: 1688–1694. doi:10.1007/s00247-018-4241-6
- [11] Radiology ESofU. *ESUR Guidelines on Contrast Agents* 2020.
- [12] Radiology ACo. *ACR Manual on contrast media* 2020.

- [13] Behzadi AH, Zhao Y, Farooq Z et al. Immediate Allergic Reactions to Gadolinium-based Contrast Agents: A Systematic Review and Meta-Analysis. *Radiology* 2018; 286: 471–482. doi:10.1148/radiol.2017162740
- [14] Raynaud JS, Darmon-Kern E, Lancelot E et al. Immediate Allergic Reactions to Gadolinium-based Contrast Agents. *Radiology* 2018; 286: 1094–1095. doi:10.1148/radiol.2018172414
- [15] de Kerviler E, Maravilla K, Meder JF et al. Adverse Reactions to Gadoterate Meglumine: Review of Over 25 Years of Clinical Use and More Than 50 Million Doses. *Invest Radiol* 2016; 51: 544–551. doi:10.1097/RLI.0000000000000276
- [16] Endrikat J, Vogtlaender K, Dohanish S et al. Safety of Gadobutrol: Results From 42 Clinical Phase II to IV Studies and Postmarketing Surveillance After 29 Million Applications. *Invest Radiol* 2016; 51: 537–543. doi:10.1097/RLI.0000000000000270
- [17] Shellock FG, Parker JR, Venetianer C et al. Safety of gadobenate dimeglumine (MultiHance): Summary of findings from clinical studies and postmarketing surveillance. *Invest Radiol* 2006; 41: 500–509. doi:10.1097/01.rli.0000209661.99225.c2
- [18] McDonald JS, Hunt CH, Kolbe AB et al. Acute Adverse Events Following Gadolinium-based Contrast Agent Administration: A Single-Center Retrospective Study of 281 945 Injections. *Radiology* 2019; 292: 620–627. doi:10.1148/radiol.2019182834
- [19] Uhlig J, Lucke C, Vliegenthart R et al. Acute adverse events in cardiac MR imaging with gadolinium-based contrast agents: results from the European Society of Cardiovascular Radiology (ESCR) MRCT Registry in 72839 patients. *Eur Radiol* 2019; 29: 3686–3695. doi:10.1007/s00330-019-06171-2
- [20] Cowper SE, Robin HS, Steinberg SM et al. Scleromyxoedema-like cutaneous diseases in renal-dialysis patients. *Lancet* 2000; 356: 1000–1001. doi:10.1016/S0140-6736(00)02694-5
- [21] Wagner B, Drel V, Gorin Y. Pathophysiology of gadolinium-associated systemic fibrosis. *Am J Physiol Renal Physiol* 2016; 311: F1–F11. doi:10.1152/ajprenal.00166.2016
- [22] Attari H, Cao Y, Elmholt TR et al. A Systematic Review of 639 Patients with Biopsy-confirmed Nephrogenic Systemic Fibrosis. *Radiology* 2019; 292: 376–386. doi:10.1148/radiol.2019182916
- [23] Davenport MS. Virtual Elimination of Nephrogenic Systemic Fibrosis: A Medical Success Story with a Small Asterisk. *Radiology* 2019; 292: 387–389. doi:10.1148/radiol.2019191158
- [24] Radbruch A, Weberling LD, Kieslich PJ et al. Gadolinium retention in the dentate nucleus and globus pallidus is dependent on the class of contrast agent. *Radiology* 2015; 275: 783–791. doi:10.1148/radiol.2015150337
- [25] Kanda T, Matsuda M, Oba H et al. Gadolinium Deposition after Contrast-enhanced MR Imaging. *Radiology* 2015; 277: 924–925. doi:10.1148/radiol.2015150697
- [26] Radbruch A, Haase R, Kieslich PJ et al. No Signal Intensity Increase in the Dentate Nucleus on Unenhanced T1-weighted MR Images after More than 20 Serial Injections of Macrocyclic Gadolinium-based Contrast Agents. *Radiology* 2017; 282: 699–707. doi:10.1148/radiol.2016162241
- [27] McDonald RJ, McDonald JS, Kallmes DF et al. Intracranial Gadolinium Deposition after Contrast-enhanced MR Imaging. *Radiology* 2015; 275: 772–782. doi:10.1148/radiol.15150025
- [28] Murata N, Gonzalez-Cuyar LF, Murata K et al. Macrocyclic and Other Non-Group 1 Gadolinium Contrast Agents Deposit Low Levels of Gadolinium in Brain and Bone Tissue: Preliminary Results From 9 Patients With Normal Renal Function. *Invest Radiol* 2016; 51: 447–453. doi:10.1097/RLI.0000000000000252
- [29] Minaeva O, Hua N, Franz ES et al. Nonhomogeneous Gadolinium Retention in the Cerebral Cortex after Intravenous Administration of Gadolinium-based Contrast Agent in Rats and Humans. *Radiology* 2020; 294: 377–385. doi:10.1148/radiol.2019190461
- [30] Quattrocchi CC, Ramalho J, van der Molen AJ et al. Standardized assessment of the signal intensity increase on unenhanced T1-weighted images in the brain: the European Gadolinium Retention Evaluation Consortium (GREC) Task Force position statement. *Eur Radiol* 2019; 29: 3959–3967. doi:10.1007/s00330-018-5803-6
- [31] Saake M, Hepp T, Schmidle A et al. Influence of Artifact Corrections on MRI Signal Intensity Ratios for Assessment of Gadolinium Brain Retention. *Acad Radiol* 2020; 27: 744–749. doi:10.1016/j.acra.2019.07.013
- [32] Kang KM, Choi SH, Hwang M et al. T1 Shortening in the Globus Pallidus after Multiple Administrations of Gadobutrol: Assessment with a Multi-dynamic Multiecho Sequence. *Radiology* 2018; 287: 258–266. doi:10.1148/radiol.2017162852
- [33] Deike-Hofmann K, Reuter J, Haase R et al. No Changes in T1 Relaxometry After a Mean of 11 Administrations of Gadobutrol. *Invest Radiol* 2020; 55: 381–386. doi:10.1097/RLI.0000000000000650
- [34] Saake M, Schmidle A, Kopp M et al. MRI Brain Signal Intensity and Relaxation Times in Individuals with Prior Exposure to Gadobutrol. *Radiology* 2019; 290: 659–668. doi:10.1148/radiol.2018181927
- [35] Choi Y, Jang J, Kim J et al. MRI and Quantitative Magnetic Susceptibility Maps of the Brain after Serial Administrations of Gadobutrol: A Longitudinal Follow-up Study. *Radiology* 2020; 297: 143–150. doi:10.1148/radiol.2020192579
- [36] Gulani V, Calamante F, Shellock FG et al. Chelated or dechelated gadolinium deposition – Authors' reply. *Lancet Neurol* 2017; 16: 955–956. doi:10.1016/S1474-4422(17)30365-4
- [37] Gulani V, Calamante F, Shellock FG et al. Gadolinium deposition in the brain: summary of evidence and recommendations. *Lancet Neurol* 2017; 16: 564–570. doi:10.1016/S1474-4422(17)30158-8
- [38] Frenzel T, Apte C, Jost G et al. Quantification and Assessment of the Chemical Form of Residual Gadolinium in the Brain After Repeated Administration of Gadolinium-Based Contrast Agents: Comparative Study in Rats. *Invest Radiol* 2017; 52: 396–404. doi:10.1097/RLI.0000000000000352
- [39] Radbruch A, Roberts DR, Clement O et al. Chelated or dechelated gadolinium deposition. *Lancet Neurol* 2017; 16: 955. doi:10.1016/S1474-4422(17)30364-2
- [40] Rasschaert M, Weller RO, Schroeder JA et al. Retention of Gadolinium in Brain Parenchyma: Pathways for Speciation, Access, and Distribution. A Critical Review. *J Magn Reson Imaging* 2020. doi:10.1002/jmri.27124
- [41] McKnight CD, Rouleau RM, Donahue MJ et al. The Regulation of Cerebral Spinal Fluid Flow and Its Relevance to the Glymphatic System. *Curr Neurol Neurosci Rep* 2020; 20: 58. doi:10.1007/s11910-020-01077-9
- [42] Robert P, Fingerhut S, Factor C et al. One-year Retention of Gadolinium in the Brain: Comparison of Gadodiamide and Gadoterate Meglumine in a Rodent Model. *Radiology* 2018; 288: 424–433. doi:10.1148/radiol.2018172746
- [43] Lord ML, Chettle DR, Grafe JL et al. Observed Deposition of Gadolinium in Bone Using a New Noninvasive in Vivo Biomedical Device: Results of a Small Pilot Feasibility Study. *Radiology* 2018; 287: 96–103. doi:10.1148/radiol.2017171161
- [44] Radbruch A. The Gadolinium Deposition Debate and the Streetlight Effect: Should We Really Focus on the Brain? *Radiology* 2020; 297: 417–418. doi:10.1148/radiol.2020203143
- [45] Williams S. Open Letter to FDA, Radiologists & Researchers 2020.
- [46] Gibby WA, Gibby KA, Gibby WA. Comparison of Gd DTPA-BMA (Omniscan) versus Gd HP-DO3A (ProHance) retention in human bone tissue by inductively coupled plasma atomic emission spectroscopy. *Invest Radiol* 2004; 39: 138–142. doi:10.1097/01.rli.0000112789.57341.01
- [47] Tweedle MF, Wedeking P, Kumar K. Biodistribution of radiolabeled, formulated gadopentetate, gadoteridol, gadoterate, and gadodiamide

- in mice and rats. *Invest Radiol* 1995; 30: 372–380. doi:10.1097/00004424-199506000-00008
- [48] Fretellier N, Granottier A, Rasschaert M et al. Does Age Interfere With Gadolinium Toxicity and Presence in Brain and Bone Tissues?: A Comparative Gadoterate Versus Gadodiamide Study in Juvenile and Adult Rats. *Invest Radiol* 2019; 54: 61–71. doi:10.1097/RLI.0000000000000517
- [49] Alkhunizi SM, Fakhoury M, Abou-Kheir W et al. Gadolinium Retention in the Central and Peripheral Nervous System: Implications for Pain, Cognition, and Neurogenesis. *Radiology* 2020; 297: 407–416. doi:10.1148/radiol.2020192645
- [50] Radbruch A, Richter H, Bucker P et al. Is Small Fiber Neuropathy Induced by Gadolinium-Based Contrast Agents? *Invest Radiol* 2020; 55: 473–480. doi:10.1097/RLI.0000000000000677
- [51] Forslin Y, Martola J, Bergendal A et al. Gadolinium Retention in the Brain: An MRI Relaxometry Study of Linear and Macrocyclic Gadolinium-Based Contrast Agents in Multiple Sclerosis. *AJNR Am J Neuroradiol* 2019; 40: 1265–1273. doi:10.3174/ajnr.A6112
- [52] Mallio CA, Piervincenzi C, Gianolio E et al. Absence of dentate nucleus resting-state functional connectivity changes in nonneurological patients with gadolinium-related hyperintensity on T1-weighted images. *J Magn Reson Imaging* 2019; 50: 445–455. doi:10.1002/jmri.26669
- [53] Chehabeddine L, Al Saleh T, Baalbaki M et al. Cumulative administrations of gadolinium-based contrast agents: risks of accumulation and toxicity of linear vs macrocyclic agents. *Crit Rev Toxicol* 2019; 49: 262–279. doi:10.1080/10408444.2019.1592109
- [54] Mallio CA, Piervincenzi C, Carducci F et al. Within-network brain connectivity in Crohn's disease patients with gadolinium deposition in the cerebellum. *Neuroradiology* 2020; 62: 833–841. doi:10.1007/s00234-020-02415-x
- [55] McDonald JS, McDonald RJ. MR Imaging Safety Considerations of Gadolinium-Based Contrast Agents: Gadolinium Retention and Nephrogenic Systemic Fibrosis. *Magn Reson Imaging Clin N Am* 2020; 28: 497–507. doi:10.1016/j.mric.2020.06.001
- [56] Smith TE, Steven A, Bagert BA. Gadolinium Deposition in Neurology Clinical Practice. *Ochsner J* 2019; 19: 17–25. doi:10.31486/toj.18.0111
- [57] Ramalho J, Ramalho M, Jay M et al. Gadolinium toxicity and treatment. *Magn Reson Imaging* 2016; 34: 1394–1398. doi:10.1016/j.mri.2016.09.005
- [58] Semelka RC, Ramalho J, Vakharia A et al. Gadolinium deposition disease: Initial description of a disease that has been around for a while. *Magn Reson Imaging* 2016; 34: 1383–1390. doi:10.1016/j.mri.2016.07.016
- [59] Layne KA, Wood DM, Dargan PI. Gadolinium-based contrast agents – what is the evidence for 'gadolinium deposition disease' and the use of chelation therapy? *Clin Toxicol (Phila)* 2020; 58: 151–160. doi:10.1080/15563650.2019.1681442
- [60] Harisinghani MG, Barentsz J, Hahn PF et al. Noninvasive detection of clinically occult lymph-node metastases in prostate cancer. *N Engl J Med* 2003; 348: 2491–2499. doi:10.1056/NEJMoa022749
- [61] Nguyen KL, Yoshida T, Kathuria-Prakash N et al. Multicenter Safety and Practice for Off-Label Diagnostic Use of Ferumoxytol in MRI. *Radiology* 2019; 293: 554–564. doi:10.1148/radiol.2019190477
- [62] Anderson MA, Harrington SG, Kozak BM et al. Strategies to Reduce the Use of Gadolinium-Based Contrast Agents for Abdominal MRI in Children. *Am J Roentgenol* 2020; 214: 1054–1064. doi:10.2214/Am J Roentgenol.19.22232
- [63] Falk Delgado A, Van Westen D, Nilsson M et al. Diagnostic value of alternative techniques to gadolinium-based contrast agents in MR neuroimaging—a comprehensive overview. *Insights Imaging* 2019; 10: 84. doi:10.1186/s13244-019-0771-1