

# Thrombotic Thrombocytopenic Purpura: When Basic Science Meets Clinical Research

Gaëlle Bécel<sup>1,2,\*</sup> Sylvia Faict<sup>1,2,\*</sup> Adrien Picod<sup>1,2</sup> Raïda Bouzid<sup>1</sup> Agnès Veyradier<sup>1,3,4</sup> Paul Coppo<sup>1,2,5</sup>

<sup>1</sup> Centre de Référence des MicroAngiopathies Thrombotiques, Paris, France

<sup>2</sup> Service d'hématologie, Hôpital Saint-Antoine, AP-HP – Sorbonne Université, Paris, France

<sup>3</sup> Service d'Hématologie Biologique, Groupe Hospitalier Saint-Louis-Lariboisière, AP-HP, Paris, France

<sup>4</sup> Université Paris-Diderot, Paris, France

<sup>5</sup> Centre de Recherche des Cordeliers, INSERM, Sorbonne Université, USPC, Université Paris Descartes, Paris, France

**Address for correspondence** Professor Paul Coppo, Centre de Référence des Microangiopathies Thrombotiques ([www.cnr-mat.fr](http://www.cnr-mat.fr)), Service d'hématologie, Hôpital Saint-Antoine, 184 Rue du Faubourg Saint-Antoine, Paris, 75012, France (e-mail: [paul.coppo@aphp.fr](mailto:paul.coppo@aphp.fr)).

Hamostaseologie 2021;41:283–293.

## Abstract

### Keywords

- ▶ plasma exchange
- ▶ thrombotic thrombocytopenic purpura
- ▶ thrombotic microangiopathy
- ▶ rituximab
- ▶ caplacizumab
- ▶ ADAMTS13

The therapeutic landscape of thrombotic thrombocytopenic purpura (TTP) is rapidly changing with the recent availability of new targeted therapies. This progressive shift from empiricism to pathophysiology-based treatments reflects an intensive interaction between the continuous findings in the field of basic science and an efficient collaborative clinical research and represents a convincing example of the strength of translational medicine. Despite the rarity of TTP, national and international efforts could circumvent this limitation and shed light on the epidemiology, clinical presentation, prognosis, and long-term outcome of this disease. Importantly, they also provided high-quality results and practice changing studies for the benefit of patients. We report here the most recent therapeutic findings that allowed progressively improving the prognostic of TTP, both at the acute phase and through long-term outcome.

## Introduction

Thrombotic thrombocytopenic purpura (TTP) is a life-threatening disease characterized by a severe deficiency in *A Disintegrin And Metalloprotease with ThromboSpondin type 1 repeats, 13th member* (ADAMTS13), the von Willebrand factor (vWF)-cleaving protease. This deficiency leads to the accumulation of ultra-large vWF multimers both on the endothelial cells surface and into the circulation. By binding to platelets, these ultra-large vWF multimers prompt the formation of platelet-rich occlusive microthrombi in the microcirculation which subsequently cause ischemic organ dysfunction. The most affected organs are the central nervous system, the heart, and the digestive tract, but virtually all organs might be involved. A consumptive throm-

bocytopenia reflects microthrombi formation, whereas microangiopathic hemolytic anemia is related to red blood cells fragmentation on microthrombi, with increased shear stress in the microcirculation that maintains and amplifies these features. Accordingly, fragmented red blood cells, or schistocytes, are observed on patients' blood smear. Additionally, elevated serum lactate dehydrogenase (LDH) levels reflect hemolysis but primarily multivisceral ischemia. The disease affects mostly adults with a female predominance (sex ratio  $\approx 3/1$ ) and a maximum incidence between 30 and 50 years. TTP is a rare disease, with a prevalence of approximately 13 cases per million people and an incidence of approximately 1 to 2 new cases per million people.<sup>1</sup> However, a history of immune-mediated TTP (iTTP) exposes survivors to more comorbidities during long-term follow-up, including autoimmune diseases, hypertension, and major

\* Both the authors equally contributed to this work.

received

June 18, 2020

accepted after revision

December 7, 2020

© 2021. Thieme. All rights reserved.

Georg Thieme Verlag KG,

Rüdigerstraße 14,

70469 Stuttgart, Germany

DOI <https://doi.org/10.1055/a-1332-3066>.

10.1055/a-1332-3066.

ISSN 0720-9355.

depression, which could at least in part account for the shortened life expectancy reported in this population.<sup>2-4</sup> The first TTP episode usually occurs during adulthood (~90% of all TTP cases) or less frequently in childhood (~10% of all TTP cases).<sup>1,5,6</sup> TTP is a severe, potentially fatal disease if left untreated. However, an early recognition of the diagnosis and an adapted treatment now allow achieving remission rates of 90%.<sup>7</sup> Following the acute phase, TTP is associated with relapses when ADAMTS13 activity remains persistently undetectable.<sup>8</sup>

TTP management has long been centered on the replenishment of the deficient ADAMTS13, either by the sole administration of donor's plasma in the congenital form of the disease (cTTP), or by the combined extracorporeal removal of patient plasma and its replacement by donor's plasma, now referred to as therapeutic plasma exchange (TPE) in the iTTP. In the latter, corticosteroids were then empirically added to the standard treatment. Yet, the recent development of therapies targeting the pathophysiological mechanisms of the disease, that is, autoantibodies production or interaction between platelets and vWF multimers, might change the therapeutic landscape of TTP in the next few years. The purpose of this narrative review is to expose these recent advances in TTP management and to detail how such therapies are translating into standard of care and transform the historical, TPE-centered therapy of TTP for the benefit of patients.

## The Milestones of TTP Pathophysiology

The first TTP case was described by Moschcowitz in 1924 in a 16-year-old girl who suddenly developed weakness, pain, pallor, fever, and petechiae. Few days later, she developed neurological disorders (hemiparesis and paralysis), became comatose, and died. The autopsy analyzed the heart, the kidney, the spleen, and the liver (but not the brain) and reported the presence of disseminated hyaline thrombi in the microcirculation.<sup>9</sup> In 1982, Moake et al demonstrated that TTP patients exhibited ultra-large VWF multimers hyperadhesive to platelets in plasma, suggesting the role of VWF in TTP pathophysiology and a deficient factor in plasma.<sup>10</sup> In 1998, the deficient factor was described as a protease cleaving vWF and preventing the accumulation of proaggregant ultra-large multimers, and the antibodies responsible for the inhibition of this enzyme were identified as a cause for iTTP.<sup>11,12</sup> It took some more years for this protease to be isolated<sup>13</sup> and identified as ADAMTS13.<sup>14</sup> Lastly, a genetic deficiency resulting of biallelic mutations of *ADAMTS13* gene accounted for cTTP.<sup>14</sup> The rationale of plasmapheresis was then fully understood: first and foremost, TPE achieves ADAMTS13 supplementation without risking fluid overload and subsequent complications as well as removal of ultra-large vWF multimers and autoantibodies, although these last mechanisms might be of lesser importance in clinical efficacy.

ADAMTS13 specifically cleaves highly adhesive high-molecular-weight vWF multimers (>20,000 kDa) into lower, less adhesive, molecular-weight multimers. This process

occurs in the microcirculation, where high shear stress conditions expose VWF to a conformational change, from a globular to an elongated conformation making the binding sites for GpIb $\alpha$  and ADAMTS13 available. Hepatic stellate cells, podocytes and renal tubular epithelial cells, platelets, and endothelial cells produce an active ADAMTS13 protein. The N-terminal region of ADAMTS13 comprises a metalloprotease domain, a disintegrin-like domain, a first thrombospondin type 1 repeat (TSP1), and Cys-rich and spacer domains; the C-terminal region of ADAMTS13 comprises seven additional TSP1 repeats and two CUB domains.<sup>5</sup>

Autoantibodies directed to ADAMTS13 in iTTP are polyclonal. They have a neutralizing action inhibiting the catalytic activity of ADAMTS13 or a non-neutralizing action, thanks to a complexation of ADAMTS13 and an acceleration of its clearance. IgG1 and IgG4 are the most frequent IgG subclasses. IgA and IgG1 are associated with an increased mortality rate, and IgG4 with a higher risk of relapse.<sup>15</sup> More recently, it was shown that the interaction between the C-terminal (CUB) domain of ADAMTS13 and the spacer domain induces a folded conformation of ADAMTS13. This CUB-spacer domain interaction is relieved by interaction of ADAMTS13 with the C-terminal domains of VWF or by the addition of anti-CUB antibodies in vitro, resulting in the conformational activation of ADAMTS13. ADAMTS13 switches from a folded conformation to an open conformation. The spacer-CUB interaction is abrogated when ADAMTS13 is conformationally activated. The activation of ADAMTS13 reveals a cryptic epitope in the spacer domain, when the protease adopts an unfolded conformation, representing the autoantigenic core for anti-ADAMTS13 autoantibodies in iTTP. The exposure of cryptic epitopes in the spacer domain of ADAMTS13 is thus important in the pathophysiology of iTTP. Anti-spacer domain antibodies were developed in vitro and recognize a cryptic epitope in ADAMTS13. Recently, Roose and collaborators developed an original ELISA to distinguish the conformation of ADAMTS13 (folded vs. open).<sup>16</sup> They demonstrated that an open conformation of ADAMTS13 is a hallmark of acute iTTP and that ADAMTS13 adopts a folded conformation during remission.<sup>16</sup> Interestingly, this group could show that anti-ADAMTS13 autoantibodies can induce a change in the conformation of ADAMTS13 and thus the exposure of cryptic epitopes in its spacer domain. ADAMTS13 conformation could therefore be a new tool for iTTP diagnosis and monitoring during follow-up.<sup>17,18</sup>

iTTP is due to a loss of self-tolerance of the immune system toward ADAMTS13, mainly related to the presence of anti-ADAMTS13 autoantibodies. Specific alleles in the human major histocompatibility complex (MHC) type II system have been identified as risk factors for iTTP. Studies conducted in adult and also in pediatric Caucasian patients led to the identification of the predisposing HLA class II loci DRB1\*11 and DQB1\*03 and the protective allele DRB1\*04.<sup>19-22</sup> HLA alleles significantly associated with iTTP in the Japanese population differ from those observed in the Caucasians.<sup>23</sup> Nevertheless, the HLA DR proteins encoded by DRB1\*11 and DRB1\*08:03 (main predisposing allele in the Japanese) are each able to bind to an ADAMTS13 peptide in the CUB2 domain, the sequence of which differs only by the shift of one amino acid.<sup>23</sup>

The example of cTTP clearly illustrates that ADAMTS13 deficiency is necessary but not sufficient to induce a perceptible disease.<sup>14</sup> Indeed, several conditions such as infection, inflammation, or pregnancy act as triggering factors by activating endothelial cells and thus increasing vWF production (infections, inflammation, tissue attrition, etc.).<sup>24</sup> The imbalance between high concentrations of ultra-large vWF multimers and the low cleaving activity of ADAMTS13 either inherited or acquired then leads to the disease.

### Clinical Presentation: Do Not Miss the Diagnosis

Data obtained from large series of patients allowed a better understanding of the clinical spectrum of TTP. cTTP might be observed in children and pregnant women, whereas iTTP is more common during adulthood. In this last situation, an underlying condition such as a pregnancy, a history of HIV infection, connective tissue disease or cancer, or the use of antiplatelet agents is identified in 50% of iTTP cases<sup>1</sup> and need to be identified for appropriate management.

Patients usually present with mild fever (30–50% of cases) and symptoms related to organs dysfunction. Neurologic symptoms are observed in more than 50% of patients and range from headache to coma through transient and/or migratory focal deficiency, stupor, and seizure. Cardiac involvement includes infarction, congestive heart failure, arrhythmias, cardiogenic shock, and sudden cardiac arrest. Importantly, an elevated serum troponin level upon presentation is a common event (observed in up to 60% of patients) and represents an independent predictor of death, treatment refractoriness, and subsequent acute myocardial infarction.<sup>25</sup> Life-threatening hemorrhage related to severe thrombocytopenia might occur. Renal involvement is mild with typically a serum creatinine level <200 µmol/L (2.27 mg/dL). Microangiopathic hemolytic anemia and peripheral thrombocytopenia are constant clinical features of TTP. Thrombocytopenia is profound, with a platelet count usually <30 G/L. The direct antiglobulin test is negative. However, in 10% of cases, schistocytes may be rare, and the direct antiglobulin test slightly positive, which may lead to *confound* TTP with autoimmune cytopenias, thereby exposing patients to a delayed diagnosis. Therefore, a low schistocyte count and a positive direct antiglobulin test should not systematically rule out TTP, especially when associated with organ failure.<sup>26</sup>

With the increasing availability of effective treatments, rapid diagnosis of TTP by sensitive criteria is mandatory, and this urgency led to a decrease in the stringency of the diagnostic criteria in the clinical trial that documented the effectiveness of TPE. Consequently, the association of microangiopathic hemolytic anemia with peripheral thrombocytopenia should be enough to strongly suggest a diagnosis of TTP, before organ failure occurs.<sup>27</sup>

Although the identification of severe (activity <10%) autoimmune-mediated ADAMTS13 deficiency is required to document the diagnosis of iTTP, results of ADAMTS13 activity measurements are rarely available in emergency situations. Moreover, commercial kits may provide discrep-

ant results in 12% of cases.<sup>28</sup> Until assays are able to provide accurate ADAMTS13 activity within some hours, clinical scores for rapid prediction of individuals with severe ADAMTS13 deficiency will continue to have an important role in diagnosis.<sup>6</sup> Two scores (the French score and more recently the PLASMIC score),<sup>29,30</sup> derived from standard parameters easily available on presentation, offer a comparable and reliable way to identify patients with severe ADAMTS13 deficiency. Both scores use absence of an associated condition (e.g., cancer, transplant, and disseminated intravascular coagulation), severe thrombocytopenia (< 30 G/L), and mild renal involvement (serum creatinine level <2.0 or 2.27 mg/dL) as criteria for identifying patients with probable TTP (–Table 1). It is likely that platelet count and serum creatinine level are the most useful and reliable values to predict severe ADAMTS13 deficiency. These scores are not aimed at redefining TTP diagnostic criteria, which are based on severe ADAMTS13 deficiency, but they can help rapidly identify patients who are most likely to have iTTP and therefore most likely to benefit from emergency treatment including TPE.

**Table 1** Comparison of the two clinical scores (French score and PLASMIC score) predicting severe ADAMTS13 deficiency

	French score	PLASMIC score
Platelet count	< 30 G/L (+1)	< 30 G/L (+1)
Serum creatinine level	< 2.25 mg/dL (+1)	< 2.0 mg/dL (+1)
Hemolysis Indirect bilirubin > 2 mg/dL Or reticulocyte count > 2.5% Or undetectable haptoglobin	<sup>a</sup>	+1
No active cancer in previous year	<sup>a</sup>	+1
No history of solid organ or SCT	<sup>a</sup>	+1
INR < 1.5	<sup>a</sup>	+1
MCV < 90 fl <sup>b</sup>	–	+1
Prediction of severe ADAMTS13 deficiency (activity <10%) <sup>c</sup>	0: 2% 1: 85% 2: 94%	0–4: 0–4% 5: 5–24% 6–7: 62–82%

Abbreviations: INR, international normalized ratio; MCV, red blood cell means corpuscular volume (a surrogate for red cell fragmentation); SCT, stem cell transplantation.

Note: Each item is associated with one point (+1).

Source: Adapted from Coppo et al.<sup>46</sup>

<sup>a</sup>The French score considered patients with a TMA syndrome (which includes hemolysis with schistocytes in the definition) and assumes that there is no history of or clinical evidence for associated cancer, transplantation, or DIC; so these items are intrinsic to the score.

<sup>b</sup>MCV was not incorporated in the French score.

<sup>c</sup>Results correspond to those of the derivation cohort and those of the validation by (French score) the bootstrap resampling technique (internal validation),<sup>(29,30)</sup> or (PLASMIC score) different samples of patients from the same institution (internal validation) or from a different institution (external validation).<sup>29,30</sup>

## Historical Treatment

TPE still remains the centerpiece of iTTP treatment (Category I, Grade 1A).<sup>31,32</sup> Its effectiveness was suggested by the mention of transfusion exchange techniques as early as the description of the disease by Moschowitz in 1924.<sup>9</sup> Several variants of transfusion exchange have subsequently been used and, remarkably, only the techniques including plasma infusion proved efficacy.<sup>33–36</sup> This important clinical observation had two important consequences: first, it led to the conclusion that a deficient factor was provided by plasma (which paved the way for the identification of ADAMTS13); second, it defined TPE as the reference treatment of iTTP for decades. The superior efficacy of TPE compared with the sole infusion of plasma in early studies probably relies on the difference in volume (three times higher for TPE) and therefore on the quantity of ADAMTS13 infused.<sup>32</sup>

In the specific context of iTTP, the clinical benefit of TPE could result from three actions: the removal of autoantibodies directed against ADAMTS13; the removal of ultra-large vWF multimers; and most importantly, the supplementation in ADAMTS13 without risking fluid overload. TPE needs to be started as soon as possible because any delay worsens the prognosis.<sup>37,38</sup> TPE can be performed either using centrifugation or filtration depending on team's experience and/or availability of the corresponding device. Centrifugation plasmapheresis is the historical modality and consists in the centrifugation of whole blood to separate plasma from platelets, white blood cells, and erythrocytes. This technique requires one (discontinuous flow) or two (continuous flow) peripheral venous accesses depending on the device used and allows only low blood flow rates (50–80 mL/min). Anticoagulation is most often performed by using citrate-dextrose solution, which is almost completely eliminated along with plasma. It is common to start the treatment by exchanging 1.5 times the estimated plasma volume and then reducing the exchanged volume to 1.0 times. The replacement fluid should be plasma only since other fluids do not bring ADAMTS13. Various preparations of plasma have been tested based on the rationale of varying content in vWF multimers, while ADAMTS13 activity remains constant.<sup>39</sup> To date, there is no clearly demonstrated superiority between quarantine fresh frozen plasma, amotosalen-inactivated plasma, and solvent-detergent inactivated plasma. Of note, methylene blue photo-inactivated plasma was associated with more TPE sessions versus fresh frozen plasma to achieve durable remission<sup>40–42</sup>; moreover, its use has been discontinued in several countries as side effects were more prevalent. In patients who do not improve with standard treatment, twice-daily TPE has been reported as an available salvage strategy.<sup>43,44</sup> TPE should be continued until remission, as defined by platelet recovery (platelet count > 150 G/L for more than 48 hours), LDH decrease, and clinical improvement.<sup>45</sup> Historically, TPE used to be tapered over several weeks to prevent (and/or to control more rapidly) an exacerbation of the disease after cessation. However, the increasing use of concomitant immunosuppressive strategies as well as the use of caplacizumab should allow interrupting TPE abruptly without any detrimental conse-

**Table 2** Complications of TPE for iTTP

<b>Catheter-related complications</b>
Catheter-related bleeding
- Hemothorax
- Retroperitoneal hemorrhage
- Insertion-site hemorrhage
Catheter-related thrombosis
Catheter-related local or systemic infection
Catheter dysfunction
<b>TPE procedure-related complications</b>
Hypotension
Arrhythmia
Hypocalcemia
Hypokalemia
Filter clotting (filtration)
Reactions to plasma
- Anaphylaxis
- Serum sickness
- Transfusion-related acute lung injury

Abbreviations: iTTP, immune-mediated thrombotic thrombocytopenic purpura; TPE, therapeutic plasma exchange.

Source: Adapted from Nguyen et al.<sup>47</sup>

quence. The accurate monitoring of ADAMTS13 activity provides confidence in this attitude when a recovery of ADAMTS13 activity is observed (at least >20% activity). Conversely, a persistently suppressed (i.e., < 10%) ADAMTS13 activity, although it does not necessarily preclude TPE cessation—especially under the coverage of anti-vWF therapy, should plead for an optimization of immunosuppression.<sup>46</sup>

In addition to disease-driven complications, patients are exposed to complications, directly resulting from TPE and related to vascular access and to the volume of the extracorporeal circuit and/or the replacement fluid (→Table 2). It is noteworthy that the frequency of TPE-related complications decreases over time as a result of both experience of teams and the progressive decrease in the number of TPE sessions.<sup>47</sup>

Historically, and despite the lack of strong clinical evidence, corticosteroids have been empirically administered to achieve this goal.<sup>31</sup> Corticosteroids are usually used at doses of 1 to 1.5 mg/kg/day of prednisone or equivalent, although higher doses might be of interest. In a multicentric randomized open-label trial, 60 patients were randomized to receive either methylprednisolone 1 or 10 mg/kg/day for 3 days, followed by 2.5 mg/kg/day in addition to TPE. After 23 days of treatment, a significant reduction in the proportion of patients refractory to therapy was noted in the high-dose group (23.4 vs. 53.4, respectively,  $p = 0.03$ ).<sup>48</sup>

## Recent Therapeutic Advances in TTP Management

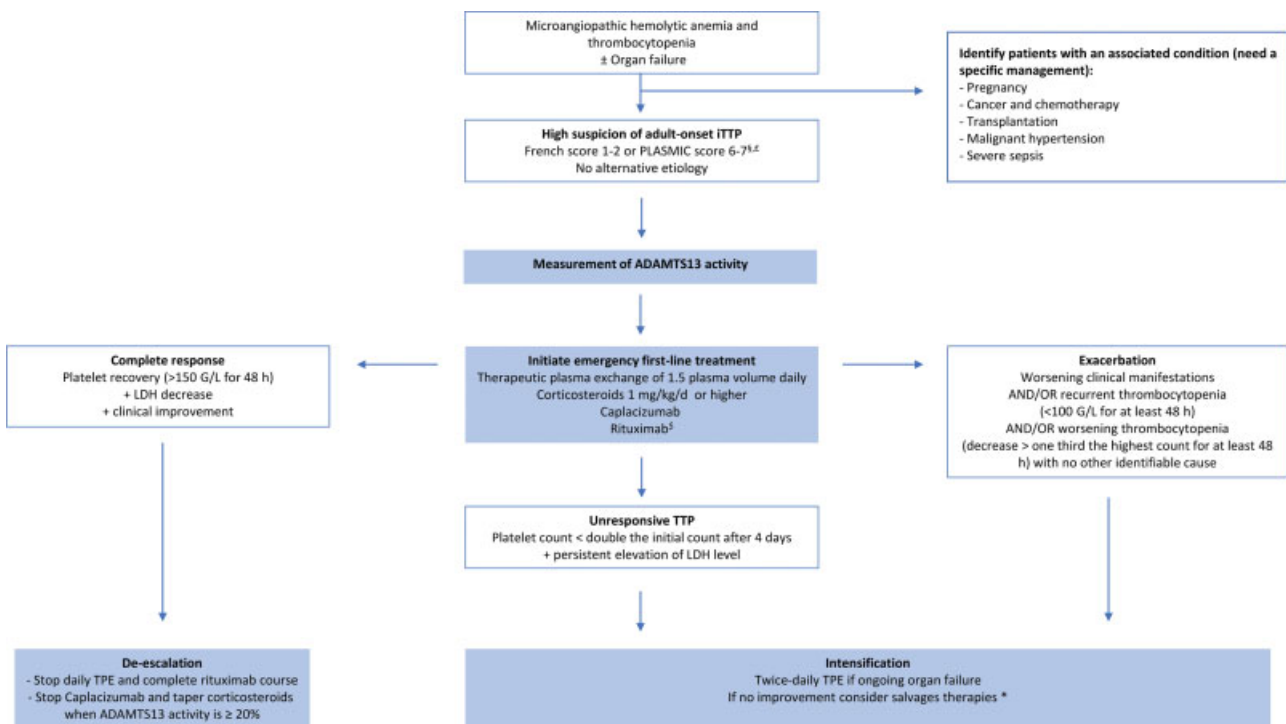
### Immunomodulation with Rituximab at the Acute Phase

The success of rituximab in the treatment of various autoimmune conditions such as idiopathic thrombocytopenic purpura and autoimmune hemolytic anemia prompted its evaluation in iTTP, first for patients with a suboptimal response to treatment (i.e., patients experiencing an exacerbation or a refractory disease). In these reports, rituximab used as a

salvage therapy resulted in higher remission rates (82–100%) with faster responses to treatment and consequently fewer slow responders.<sup>49,50</sup> Interestingly, despite an often more severe initial presentation, patients who received rituximab experienced fewer 2-year relapses that occurred later in accordance with a prolonged immunosuppression. Given these encouraging results, a randomized trial was initiated by the Transfusion Medicine/Hemostasis Clinical Trials Network to evaluate the efficacy of systematic administration of rituximab as part of the frontline management of iTTP.<sup>51</sup> Unfortunately, because of a very low rate of inclusion, this study was prematurely terminated and the only evidence available comes from an open-label trial from the South East England TTP study group.<sup>52</sup> In this study, the early ( $\leq 3$  days from admission) administration of rituximab in addition to a standard therapeutic regimen including TPE and corticosteroids resulted in a high response rate with fewer relapses. Additionally, there was a trend toward a shorter duration of TPE therapy for rituximab-treated patients when compared with historical controls. Interestingly, a subsequent study from the same group compared the outcome of patients who received rituximab early ( $\leq 3$  days, most of these patients

having been included in the aforementioned trial) versus late ( $> 3$  days) and confirmed the benefit of an early administration with regard to the time to remission (median, 12 vs. 20 days, respectively,  $p < 0.001$ ), the number of TPE procedures (median, 16 vs. 24, respectively,  $p = 0.03$ ), and the length of hospital stay (median, 16 vs. 23 days, respectively,  $p = 0.01$ ).<sup>53</sup>

Following this line of thought, frontline adjuvant rituximab should now be administered to all patients to achieve rapid, efficient, and durable immunosuppression and prevent short-term relapses (→ Fig. 1).<sup>46</sup> Furthermore, it appears that rituximab is well tolerated, with no increase in the overall infections rate.<sup>49,50,52</sup> Moreover, this strategy could be cost-effective by saving a full cumbersome management in case of relapse.<sup>54</sup> However, the optimal dose and timing of rituximab infusions remain to be determined. Indeed, most studies used a 4-week regimen of once-weekly 375 mg/m<sup>2</sup> infusion. A more intensive regimen has been evaluated considering the fact that a substantial amount of rituximab was eliminated during TPE; however, kinetics of B-cell depletion in this work proved to be similar to previous studies.<sup>49</sup> Conversely, lower doses of rituximab (100 mg/week for 4 weeks or 375 mg/m<sup>2</sup> × 2 to 3 infusions) showed a similar efficacy.<sup>55,56</sup>



**Fig. 1** Current management of immune-mediated thrombotic thrombocytopenic purpura (adapted from Coppo et al<sup>46</sup>). Treatment with TPE and corticosteroids should be initiated as soon as the diagnosis is made or even suggested. Of utmost importance, to avoid a delay in the optimal management, TTP diagnosis should be suspected on the basis of clinical scores aimed at predicting a severe ADAMTS13 deficiency.<sup>29,30</sup> If the clinical probability of iTTP is high, the anti-vWF agent caplacizumab as well as frontline rituximab should also be associated with TPE and corticosteroids. Response to therapy should be assessed at least daily by repeated platelet count, LDH, and clinical assessment. Patients experiencing refractoriness after 4 days or an exacerbation of the disease should be intensified. There is no consensual recommendation; we propose the use of twice-daily TPE. \*For the more severe patients, pulses of cyclophosphamide, vincristine, cyclosporine, splenectomy, or bortezomib should be considered. <sup>5</sup>Details in →Table 1. <sup>4</sup>If the likelihood for ADAMTS13 activity <10% is intermediate (e.g., PLASMIC score = 5; →Table 1), we recommend empiric treatment for iTTP because of the potential harms of withholding or delaying treatment, particularly TPE. This salvage treatment should be subsequently completed with immunosuppressive strategies and caplacizumab only when/if severe ADAMTS13 deficiency is confirmed. <sup>5</sup>In our practice, if the clinical probability of iTTP diagnosis is intermediate (French score = 1), rituximab is started after severe ADAMTS13 deficiency is ascertained (whereas daily TPE, corticosteroids, and caplacizumab are started frontline). iTTP, immune-mediated thrombotic thrombocytopenic purpura; TPE, therapeutic plasma exchange.

This document was downloaded for personal use only. Unauthorized distribution is strictly prohibited.

### Prevention of Relapses with Rituximab

Each relapse exposes the patient to risk of death and to complications related to TPE or to intensive care unit hospitalization. Therefore, the prevention of relapse in TTP represents a major goal. As detailed earlier, the use of rituximab in the acute phase of the disease dramatically decreases the relapse rate at 1 year. However, beyond this period, anti-ADAMTS13 autoantibodies may recur along with peripheral B-cell reconstitution, exposing patients to risk of clinical relapse. These observations provided a rationale to evaluate the efficacy of rituximab in iTTP as preemptive therapy for patients in clinical remission, but with persistent or recurrent severe ADAMTS13 deficiency. In this context, rituximab remarkably reduces the incidence of TTP relapse by diminishing the production of anti-ADAMTS13 antibodies and rapidly restoring ADAMTS13 activity, which parallels peripheral B-cell depletion.<sup>17,57,58</sup> In our practice, we assess ADAMTS13 regularly during follow-up (typically every 3 months). After serial ADAMTS13 assessments have remained normal (>50%) durably (typically 3 years), measurements are spaced out to twice a year for 2 years and then yearly. When ADAMTS13 activity becomes undetectable (activity <10% or even <20%), a single infusion of rituximab 375 mg/m<sup>2</sup> is administered. In more than 80% of patients, ADAMTS13 activity post-rituximab is detectable or even normalizes (20% to >50%) as early as 4 to 6 weeks after infusion. However, in up to 50% of patients, ADAMTS13 recovery is transient and drops again with peripheral B-cell reconstitution, typically 12 months later. Consequently, further rituximab infusions may be required to maintain a detectable ADAMTS13 activity and prevent clinical relapse.<sup>17,58</sup> Patients with persistent severe (activity <10–20%) ADAMTS13 deficiency are exposed to a high risk of relapse, with a 7-year cumulative incidence of relapse of 74%.<sup>17</sup> Moreover, 10 to 15% of patients are primarily unresponsive to rituximab or experience refractoriness after an initial response. In these cases, a more intensive regimen inspired from those used in lymphoid malignancies and consisting of 4 to 6 weekly infusions and/or maintenance treatment (4 infusions/year for 2 years) may overcome rituximab refractoriness.<sup>59,60</sup> Recently, subcutaneous preemptive rituximab was shown to have similar efficacy than IV perfusion as a preemptive treatment for iTTP and could ease the management of these patients, notably when repeated administrations are needed, by decreasing the burden of care and improving patients' satisfaction. Therefore, subcutaneous rituximab could represent a new standard of care in the prevention of iTTP relapses.<sup>61</sup>

### Inhibiting the vWF/Platelets Axis with Caplacizumab

More recently, therapies targeting the interaction between platelets and vWF multimers have been developed with the aim to prevent the formation of microthrombi and subsequent microcirculation occlusion and ischemic organ damage. Caplacizumab (Cabliivi, Ablynx, a Sanofi Company), formerly known as ALX-0081 (intravenous administration) and ALX-0681 (subcutaneous administration), is a bivalent nanobody, that is, a humanized single-variable domain antibody derived from the homodimeric heavy-chain antibodies naturally occurring in camelids. This small format of 28 kDa offers several theoretical

advantages compared with classically manufactured antibodies: rapid distribution and rapid clearance to allow both a rapid onset of action and a limitation of potential toxicity; specific, high affinity, and irreversible binding to the target and direct action without Fc-mediated recruitment of cellular effectors or complement activation, preventing potential adverse effects. Caplacizumab targets the A1 domain of ultra-large vWF multimers and thus blocks its interaction and binding to the platelet glycoprotein Ib–IX–V receptor, which is the critical first step of platelet aggregation. The drug was first developed as an antithrombotic agent in the context of myocardial infarction, but greater interest has soon been paid to its therapeutic potential in TTP, and development for the first indication has since been discontinued. Indeed, in the absence of interaction between platelets and vWF, the formation of occlusive microthrombi can be prevented. In a preclinical baboon model of iTTP obtained by the administration of a neutralizing anti-ADAMTS13 antibody, the daily administration of caplacizumab allowed a rapid (<1 day) and profound inhibition of vWF activity as measured by ristocetin cofactor activity which recovered 7 days after treatment cessation (for a review, see the article by Poullin et al<sup>62</sup>). This inhibition of vWF activity translated into clinical efficacy with a rapid recovery of platelet count and a decrease in LDH level along with a trend toward the resolution of the microangiopathic hemolytic anemia in treated animals compared with untreated controls. However, at postmortem analysis, the proportion of occluded vessels did not differ between groups, suggesting that caplacizumab was not able to clear previously formed microthrombi.<sup>63</sup>

Preliminary data showed that effective, steady-state concentration was reached in humans following once-daily subcutaneous administration of caplacizumab 10 mg and this therapeutic schedule was then adopted for clinical trials with the addition of one intravenous dose prior to the first TPE, to achieve an immediate onset of action. So far, caplacizumab has been evaluated in two randomized controlled trials (→Table 3). In the phase II TITAN trial, the addition of caplacizumab to standard treatment and for 30 days after the last TPE resulted in a significant reduction in the time to response, defined as the time to confirmed normalization of the platelet count (median: 2.97 days, vs. 4.79 days in placebo).<sup>64</sup> Two deaths occurred in the placebo group versus none in patients treated with caplacizumab. However, relapses were more frequent in the caplacizumab group with seven patients relapsing within 10 days after caplacizumab had been stopped. In these seven patients, ADAMTS13 activity was persistently less than 10%. These results were then confirmed in a phase III randomized clinical trial.<sup>65</sup> Again, the addition of caplacizumab to standard treatment resulted in a significant reduction in the time to platelet count response (platelet count normalization rate: 1.55, 95% CI: 1.10–2.20,  $p < 0.01$ ). Additionally, there was a significant reduction in a composite secondary endpoint of iTTP-related death, recurrence of iTTP, or one or more major thromboembolic event during the study treatment period compared with placebo (12.5 vs. 49.3%, respectively,  $p < 0.0001$ ). Unlike for the phase II trial, investigators were encouraged to extend the blinded treatment for a maximum of 4 weeks along with optimization of the

**Table 3** First-line treatment with caplacizumab versus placebo in iTTP: data from TITAN and HERCULES randomized controlled trials

Reference	Number of patients: caplacizumab vs. placebo	Mean age (y) (range)	Female, N (%)	CR (%)	Recurrence <sup>a</sup> (%)	Exacerbation (%)	Relapse (%)	Mortality in the acute phase (%)	Mean TPE duration (d)
TITAN <sup>8</sup>	75 (36 vs. 39)	42 (19–72)	44 (59)	81 vs. 46	38.9 vs. 38.4	8.3 vs. 28.2	30.6 vs. 7.7 <sup>b</sup>	0 vs. 5.1	5.9 vs. 7.9
HERCULES <sup>9</sup>	145 (72 vs. 73)	46 (18–79)	100 (69)	NA	12.5 vs. 38.3	4.2 vs. 38.3	8.3 vs. 0 <sup>c</sup>	0 vs. 4.1	5.8 vs. 9.4

Abbreviations: CR, complete remission; iTTP, immune-mediated thrombotic thrombocytopenic purpura; TPE, therapeutic plasma exchange.

<sup>a</sup>Recurrence was defined as exacerbation and/or relapse.

<sup>b</sup>12 months of follow-up.

<sup>c</sup>2 months of follow-up.

immunosuppression regimen if there was evidence of an ongoing disease, that is, a persistently suppressed ADAMTS13 activity. This strategy translated into a reduced rate of iTTP recurrence (including exacerbation and relapse) in the caplacizumab group (12.5 vs. 38.4%, respectively,  $p < 0.001$ ). Lastly, when patients in the placebo group experiencing an exacerbation of the disease were crossed-over to received caplacizumab, a rapid and sustained response was systematically observed, further supporting the efficacy of caplacizumab.<sup>66</sup>

Two groups have recently reported their experience with the use of caplacizumab outside the context of a randomized controlled trial. These experiences differ in the strategy used. In the French cohort, caplacizumab was part of a frontline therapeutic strategy in association with TPE and immunosuppression with corticosteroids and frontline rituximab. This strategy resulted in a significantly lower incidence of a composite outcome of iTTP refractoriness or death within 30 day since diagnosis in the 90 patients treated with this “triplet regimen” as compared with historical controls treated with TPE and corticosteroids, with rituximab as salvage therapy (2.2 vs. 12%,  $p = 0.01$ ). Moreover, exacerbations in the triplet cohort were observed only in 3.4% of patients versus 44% in the historical cohort ( $p < 0.01$ ).<sup>67</sup> Conversely, in a German cohort where caplacizumab was administered frontline in only 58% of patients and as a salvage therapy in the others, 31.7% experienced a refractory disease, including one death.<sup>68</sup> Taken together, these real-life data confirm the efficacy of caplacizumab and suggest that the agent should be part of the frontline therapy, in accordance with the strategy evaluated in RCTs to prevent more systematically unfavorable outcomes.

Impressively, treatment with caplacizumab resulted in a substantial reduction in the burden of care, with a 38% relative reduction in the number of days of TPE compared with placebo (mean: 5.8 vs. 9.4 days, respectively) and a 41% relative reduction in the volume of plasma used. Moreover, the duration of hospitalization stay was shortened with a 65% relative reduction in the length of stay in the intensive care unit (ICU) (3.4 vs. 9.7 days, respectively) and a 31% relative reduction in the total number of days in hospital (9.9 vs. 14.4 days, respectively).<sup>65</sup> In the French cohort, patients in the caplacizumab-containing regimen received 50% fewer TPE sessions and 45% lower plasma volumes, while accordingly the number of days in hospital was 41% lower ( $p < 0.01$  all).<sup>67</sup>

In accordance with its mechanism of action, side effects associated with the use of caplacizumab in both studies were mainly represented by a greater occurrence of mucocutaneous bleeding such as epistaxis and gingival bleeding (–Table 4). However, these events were mild and rarely clinically significant, with no death attributable to treatment. Long-term efficacy and safety of caplacizumab is now being evaluated in all patients who completed the HERCULES trial in a phase IIIb prospective follow-up study (Post-HERCULES trial, NCT02878603). These positive results encouraged investigators to treat patients suffering from iTTP who cannot receive plasma or TPE, with the association of caplacizumab and immunosuppression, with successful results.<sup>69,70</sup> A perspective from such observations is to foresee TPE-free regimens.<sup>71</sup>

**Table 4** Adverse events in patients treated with caplacizumab versus placebo

Adverse event	TITAN Caplacizumab vs. placebo	HERCULES Caplacizumab vs. placebo
Bleeding	54.2 vs. 37.8	64.8 vs. 47.9
Gingival bleeding	14.3 vs. 5.4	18.3 vs. 1.4
Epistaxis	31.4 vs. 10.8	32.4 vs. 2.7
Hematuria	0 vs. 2.7	7.0 vs. 2.7
Catheter-site hemorrhage	NA	7.0 vs. 6.8
Subarachnoid hemorrhage	2.9 vs. 0	1.4 vs. 0
Headache	34.3 vs. 27	22.5 vs. 8.2
Pyrexia	17.1 vs. 16.2	14.1 vs. 8.2
Myalgia	20.0 vs. 2.7	NA
Urticaria	NA	16.9 vs. 6.8

Abbreviation: NA, not available.

Note: Data are provided as percent.

Source: Adapted from Peyvandi et al and Scully et al.<sup>64,65</sup>

Several salvage therapies have been addressed in refractory patients, including mainly cyclophosphamide, vincristine, cyclosporine, or splenectomy and more recently anti-plasma cell agents.<sup>46</sup> However, given the impressive efficacy of caplacizumab translating in a very few number of unfavorable outcomes, their role in the modern treatment strategy including TPE, corticosteroids, and rituximab and caplacizumab, needs to be revisited.

### The Next Step in TTP Management: The Recombinant Human ADAMTS13?

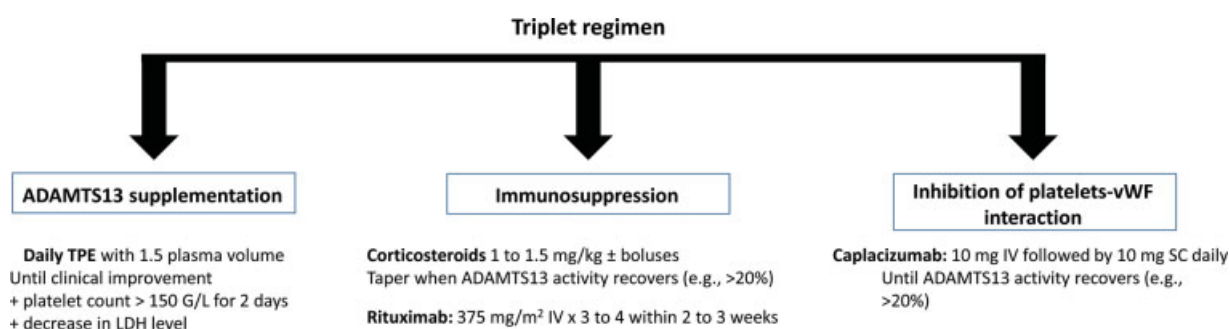
Another major therapeutic achievement in the field of TTP is the development of a recombinant human ADAMTS13 (rhADAMTS13) (BAX930, Baxalta, part of Shire). In a phase I study conducted in patients suffering from cTTP, the administration of rhADAMTS13 led to a dose-dependent detection of vWF-cleavage products as well as a trend toward LDH decrease and platelet count improvement. Additionally, administration of the recombinant enzyme was well tolerated,

and importantly, no patient developed detectable neutralizing anti-ADAMTS13 antibodies.<sup>72</sup> The half-life of the recombinant form of ADAMTS13 was comparable to this of the wild-type protein, that is, ~3 days. Of note, this half-life represents the lowest known clearance rates of proteases in circulating human plasma.<sup>73</sup> rhADAMTS13 is now being evaluated in cTTP in a phase 3 trial (NCT03393975). Additionally, it has been shown that rhADAMTS13 was able to restore vWF-cleaving activity when added to the plasma of iTTP patients with inhibitory autoantibodies, with a linear correlation between autoantibodies titer and required rhADAMTS13.<sup>74</sup> Furthermore, amino acid substitution in the spacer domain of ADAMTS13 results in several gain of function variants, some of which are being resistant to inhibition by autoantibodies from patients with iTTP and therefore could be of interest in the specific context of iTTP.<sup>72</sup> There is no doubt that the evaluation of a rhADAMTS13 will be the next major step in the search for the optimal iTTP therapeutic strategy. The success of such an approach would allow a fully targeted, plasma-free therapeutic strategy, devoid of TPE-related complications and associated costs.

### Perspectives: Future Directions

The therapeutic landscape of TTP is shifting toward more precision medicine and targeted therapies. A triplet regimen systematically associating ADAMTS13 supply through TPE, immunosuppression with corticosteroids and rituximab, and caplacizumab, by addressing the three components of iTTP pathophysiology (→Fig. 2), should further improve survival and long-term outcome in these patients.

Now that the therapeutic armamentarium allows remission in almost all cases of the once-fatal TTP, research should gradually shift to other horizons and three issues emerge particularly. First, the availability of agents able to alleviate the burden of care (caplacizumab, and soon rhADAMTS13) could lead to the suppression of the cumbersome management with TPE and outpatient or home treatment. This goal, however, should be addressed through formal clinical trials, with the need to assess the cost-effectiveness of such new strategy. Second, there is a need to further optimize the follow-up of patients once remission is achieved. In iTTP, it has already been shown that regular, lifetime monitoring of ADAMTS13 activity with preemptive administration of



**Fig. 2** The three axes of iTTP management in the acute phase. LDH, lactate dehydrogenase; TPE, therapeutic plasma exchange; vWF, von Willebrand factor.



rituximab can prevent the occurrence of a relapse. It is now necessary to define the ideal monitoring strategy as well as the schedule of rituximab administration and the best strategy to manage patients for whom the administration of rituximab would not be sufficient to restore detectable ADAMTS13 activity. Finally, future work should focus on whether newest therapeutic regimens can reduce the incidence of several comorbidities occurring during long-term follow-up, and prevent premature death. No doubt that the history of TTP treatment will require additional chapters to be written in the forthcoming years.

### Conflict of Interest

GB, SF and AP have no competing interest. AV is a member of the advisory board for Sanofi-Genzyme. PC is a member of the advisory board for Alexion, Octapharma, Shire, and Sanofi-Genzyme.

### References

- Mariotte E, Azoulay E, Galicier L, et al; French Reference Center for Thrombotic Microangiopathies. Epidemiology and pathophysiology of adulthood-onset thrombotic microangiopathy with severe ADAMTS13 deficiency (thrombotic thrombocytopenic purpura): a cross-sectional analysis of the French national registry for thrombotic microangiopathy. *Lancet Haematol* 2016;3(05):e237–e245
- Deford CC, Reese JA, Schwartz LH, et al. Multiple major morbidities and increased mortality during long-term follow-up after recovery from thrombotic thrombocytopenic purpura. *Blood* 2013;122(12):2023–2029, quiz 2142
- Roriz M, Landais M, Desprez J, et al; French Thrombotic Microangiopathies Reference Center. Risk factors for autoimmune diseases development after thrombotic thrombocytopenic purpura. *Medicine (Baltimore)* 2015;94(42):e1598
- Prevel R, Roubaud-Baudron C, Gourlain S, et al. Immune thrombotic thrombocytopenic purpura in older patients: prognosis and long-term survival. *Blood* 2019;134(24):2209–2217
- Kremer Hovinga JA, Coppo P, Lämmle B, Moake JL, Miyata T, Vanhoorelbeke K. Thrombotic thrombocytopenic purpura. *Nat Rev Dis Primers* 2017;3:17020
- Joly BS, Coppo P, Veyradier A. Thrombotic thrombocytopenic purpura. *Blood* 2017;129(21):2836–2846
- Kremer Hovinga JA, Vesely SK, Terrell DR, Lämmle B, George JN. Survival and relapse in patients with thrombotic thrombocytopenic purpura. *Blood* 2010;115(08):1500–1511, quiz 1662
- Peyvandi F, Lavoretano S, Palla R, et al. ADAMTS13 and anti-ADAMTS13 antibodies as markers for recurrence of acquired thrombotic thrombocytopenic purpura during remission. *Haematologica* 2008;93(02):232–239
- Moschowitz E. An acute febrile pleiochromic anemia with hyaline thrombosis of the terminal arterioles and capillaries: an undescribed disease. 1925. *Mt Sinai J Med* 2003;70(05):352–355
- Moake JL, Rudy CK, Troll JH, et al. Unusually large plasma factor VIII: von Willebrand factor multimers in chronic relapsing thrombotic thrombocytopenic purpura. *N Engl J Med* 1982;307(23):1432–1435
- Tsai HM, Lian EC. Antibodies to von Willebrand factor-cleaving protease in acute thrombotic thrombocytopenic purpura. *N Engl J Med* 1998;339(22):1585–1594
- Furlan M, Robles R, Solenthaler M, Lämmle B. Acquired deficiency of von Willebrand factor-cleaving protease in a patient with thrombotic thrombocytopenic purpura. *Blood* 1998;91(08):2839–2846
- Zheng X, Chung D, Takayama TK, Majerus EM, Sadler JE, Fujikawa K. Structure of von Willebrand factor-cleaving protease (ADAMTS13), a metalloprotease involved in thrombotic thrombocytopenic purpura. *J Biol Chem* 2001;276(44):41059–41063
- Levy GG, Nichols WC, Lian EC, et al. Mutations in a member of the ADAMTS gene family cause thrombotic thrombocytopenic purpura. *Nature* 2001;413(6855):488–494
- Ferrari S, Scheiflinger F, Rieger M, et al; French Clinical and Biological Network on Adult Thrombotic Microangiopathies. Prognostic value of anti-ADAMTS 13 antibody features (Ig isotype, titer, and inhibitory effect) in a cohort of 35 adult French patients undergoing a first episode of thrombotic microangiopathy with undetectable ADAMTS 13 activity. *Blood* 2007;109(07):2815–2822
- Roose E, Schelpe AS, Joly BS, et al. An open conformation of ADAMTS-13 is a hallmark of acute acquired thrombotic thrombocytopenic purpura. *J Thromb Haemost* 2018;16(02):378–388
- Jestin M, Benhamou Y, Schelpe AS, et al; French Thrombotic Microangiopathies Reference Center. Preemptive rituximab prevents long-term relapses in immune-mediated thrombotic thrombocytopenic purpura. *Blood* 2018;132(20):2143–2153
- Roose E, Schelpe AS, Tellier E, et al. Open ADAMTS13, induced by antibodies, is a biomarker for subclinical immune-mediated thrombotic thrombocytopenic purpura. *Blood* 2020;136(03):353–361
- Scully M, Brown J, Patel R, McDonald V, Brown CJ, Machin S. Human leukocyte antigen association in idiopathic thrombotic thrombocytopenic purpura: evidence for an immunogenetic link. *J Thromb Haemost* 2010;8(02):257–262
- Coppo P, Busson M, Veyradier A, et al; French Reference Centre For Thrombotic Microangiopathies. HLA-DRB1\*11: a strong risk factor for acquired severe ADAMTS13 deficiency-related idiopathic thrombotic thrombocytopenic purpura in Caucasians. *J Thromb Haemost* 2010;8(04):856–859
- John ML, Hitzler W, Scharer I. The role of human leukocyte antigens as predisposing and/or protective factors in patients with idiopathic thrombotic thrombocytopenic purpura. *Ann Hematol* 2012;91(04):507–510
- Joly BS, Loiseau P, Darmon M, et al. HLA-DRB1\*11 is a strong risk factor for acquired thrombotic thrombocytopenic purpura in children. *Haematologica* 2020;haematol.2019.241968
- Sakai K, Kuwana M, Tanaka H, et al. HLA loci predisposing to immune TTP in Japanese: potential role of the shared ADAMTS13 peptide bound to different HLA-DR. *Blood* 2020;135(26):2413–2419
- Zheng L, Abdelgawwad MS, Zhang D, et al. Histone-induced thrombotic thrombocytopenic purpura in *adamts13<sup>-/-</sup>* zebrafish depends on von Willebrand factor. *Haematologica* 2020;105(04):1107–1119
- Benhamou Y, Boelle PY, Baudin B, et al; Reference Center for Thrombotic Microangiopathies Experience of the French Thrombotic Microangiopathies Reference Center. Cardiac troponin-I on diagnosis predicts early death and refractoriness in acquired thrombotic thrombocytopenic purpura. *J Thromb Haemost* 2015;13(02):293–302
- Grall M, Azoulay E, Galicier L, et al. Thrombotic thrombocytopenic purpura misdiagnosed as autoimmune cytopenia: causes of diagnostic errors and consequence on outcome. Experience of the French thrombotic microangiopathies reference centre. *Am J Hematol* 2017;92(04):381–387
- Scully M, Cataland S, Coppo P, et al; International Working Group for Thrombotic Thrombocytopenic Purpura. Consensus on the standardization of terminology in thrombotic thrombocytopenic purpura and related thrombotic microangiopathies. *J Thromb Haemost* 2017;15(02):312–322
- Joly B, Stepanian A, Hajage D, et al. Evaluation of a chromogenic commercial assay using VWF-73 peptide for ADAMTS13 activity measurement. *Thromb Res* 2014;134(05):1074–1080

- 29 Bendapudi PK, Hurwitz S, Fry A, et al. Derivation and external validation of the PLASMIC score for rapid assessment of adults with thrombotic microangiopathies: a cohort study. *Lancet Haematol* 2017;4(04):e157–e164
- 30 Coppo P, Schwarzwinger M, Buffet M, et al; French Reference Center for Thrombotic Microangiopathies. Predictive features of severe acquired ADAMTS13 deficiency in idiopathic thrombotic microangiopathies: the French TMA reference center experience. *PLoS One* 2010;5(04):e10208
- 31 Bell WR, Braine HG, Ness PM, Kickler TS. Improved survival in thrombotic thrombocytopenic purpura-hemolytic uremic syndrome. Clinical experience in 108 patients. *N Engl J Med* 1991;325(06):398–403
- 32 Rock GA, Shumak KH, Buskard NA, et al; Canadian Apheresis Study Group. Comparison of plasma exchange with plasma infusion in the treatment of thrombotic thrombocytopenic purpura. *N Engl J Med* 1991;325(06):393–397
- 33 Rubinstein MA, Kagan BM, MacGillviray MH, Merliss R, Sacks H. Unusual remission in a case of thrombotic thrombocytopenic purpura syndrome following fresh blood exchange transfusions. *Ann Intern Med* 1959;51:1409–1419
- 34 Bukowski RM, King JW, Hewlett JS. Plasmapheresis in the treatment of thrombotic thrombocytopenic purpura. *Blood* 1977;50(03):413–417
- 35 Byrnes JJ, Khurana M. Treatment of thrombotic thrombocytopenic purpura with plasma. *N Engl J Med* 1977;297(25):1386–1389
- 36 Gottschall JL, Pisciotto AV, Darin J, Hussey CV, Aster RH. Thrombotic thrombocytopenic purpura: experience with whole blood exchange transfusion. *Semin Thromb Hemost* 1981;7(01):25–32
- 37 Pereira A, Mazzara R, Monteagudo J, et al. Thrombotic thrombocytopenic purpura/hemolytic uremic syndrome: a multivariate analysis of factors predicting the response to plasma exchange. *Ann Hematol* 1995;70(06):319–323
- 38 Sawler D, Parker A, Britto J, Goodyear MD, Sun HL. Time from suspected thrombotic thrombocytopenic purpura to initiation of plasma exchange and impact on survival: a 10-year provincial retrospective cohort study. *Thromb Res* 2020;193:53–59
- 39 Hacquard M, Lecompte T, Belcour B, et al. Evaluation of the hemostatic potential including thrombin generation of three different therapeutic pathogen-reduced plasmas. *Vox Sang* 2012;102(04):354–361
- 40 de la Rubia J, Arriaga F, Linares D, et al. Role of methylene blue-treated or fresh-frozen plasma in the response to plasma exchange in patients with thrombotic thrombocytopenic purpura. *Br J Haematol* 2001;114(03):721–723
- 41 Alvarez-Larrán A, Del Río J, Ramírez C, et al. Methylene blue-photoactivated plasma vs. fresh-frozen plasma as replacement fluid for plasma exchange in thrombotic thrombocytopenic purpura. *Vox Sang* 2004;86(04):246–251
- 42 del Río-Garma J, Alvarez-Larrán A, Martínez C, et al. Methylene blue-photoactivated plasma versus quarantine fresh frozen plasma in thrombotic thrombocytopenic purpura: a multicentric, prospective cohort study. *Br J Haematol* 2008;143(01):39–45
- 43 Nguyen L, Li X, Duvall D, Terrell DR, Vesely SK, George JN. Twice-daily plasma exchange for patients with refractory thrombotic thrombocytopenic purpura: the experience of the Oklahoma Registry, 1989 through 2006. *Transfusion* 2008;48(02):349–357
- 44 Soucemarianadin M, Benhamou Y, Delmas Y, et al. Twice-daily therapeutic plasma exchange-based salvage therapy in severe autoimmune thrombotic thrombocytopenic purpura: the French TMA Reference Center experience. *Eur J Haematol* 2016;97(02):183–191
- 45 Picod A, Provôt F, Coppo P. Therapeutic plasma exchange in thrombotic thrombocytopenic purpura. *Presse Med* 2019;48(11, Pt 2):319–327
- 46 Coppo P, Cuker A, George JN. Thrombotic thrombocytopenic purpura: toward targeted therapy and precision medicine. *Res Pract Thromb Haemost* 2018;3(01):26–37
- 47 Nguyen L, Terrell DR, Duvall D, Vesely SK, George JN. Complications of plasma exchange in patients treated for thrombotic thrombocytopenic purpura. IV. An additional study of 43 consecutive patients, 2005 to 2008. *Transfusion* 2009;49(02):392–394
- 48 Balduini CL, Gugliotta L, Luppi M, et al; Italian TTP Study Group. High versus standard dose methylprednisolone in the acute phase of idiopathic thrombotic thrombocytopenic purpura: a randomized study. *Ann Hematol* 2010;89(06):591–596
- 49 Froissart A, Buffet M, Veyradier A, et al; French Thrombotic Microangiopathies Reference Center Experience of the French Thrombotic Microangiopathies Reference Center. Efficacy and safety of first-line rituximab in severe, acquired thrombotic thrombocytopenic purpura with a suboptimal response to plasma exchange. *Crit Care Med* 2012;40(01):104–111
- 50 Scully M, Cohen H, Cavenagh J, et al. Remission in acute refractory and relapsing thrombotic thrombocytopenic purpura following rituximab is associated with a reduction in IgG antibodies to ADAMTS-13. *Br J Haematol* 2007;136(03):451–461
- 51 George JN, Woodson RD, Kiss JE, Kojouri K, Vesely SK. Rituximab therapy for thrombotic thrombocytopenic purpura: a proposed study of the Transfusion Medicine/Hemostasis Clinical Trials Network with a systematic review of rituximab therapy for immune-mediated disorders. *J Clin Apher* 2006;21(01):49–56
- 52 Scully M, McDonald V, Cavenagh J, et al. A phase 2 study of the safety and efficacy of rituximab with plasma exchange in acute acquired thrombotic thrombocytopenic purpura. *Blood* 2011;118(07):1746–1753
- 53 Westwood JP, Webster H, McGuckin S, McDonald V, Machin SJ, Scully M. Rituximab for thrombotic thrombocytopenic purpura: benefit of early administration during acute episodes and use of prophylaxis to prevent relapse. *J Thromb Haemost* 2013;11(03):481–490
- 54 Sadler JE. Pathophysiology of thrombotic thrombocytopenic purpura. *Blood* 2017;130(10):1181–1188
- 55 Benhamou Y, Pintaud G, Azoulay E, et al; French Reference Center for Thrombotic Microangiopathies. Efficacy of a rituximab regimen based on B cell depletion in thrombotic thrombocytopenic purpura with suboptimal response to standard treatment: Results of a phase II, multicenter noncomparative study. *Am J Hematol* 2016;91(12):1246–1251
- 56 Zwicker JI, Muia J, Dolatshahi L, et al; ART Investigators. Adjuvant low-dose rituximab and plasma exchange for acquired TTP. *Blood* 2019;134(13):1106–1109
- 57 Hie M, Gay J, Galicier L, et al. Preemptive rituximab infusions after remission efficiently prevent relapses in acquired thrombotic thrombocytopenic purpura: experience of the French Thrombotic Microangiopathies Reference Center. *Blood* 2014;124(02):204–210
- 58 Westwood JP, Thomas M, Alwan F, et al. Rituximab prophylaxis to prevent thrombotic thrombocytopenic purpura relapse: outcome and evaluation of dosing regimens. *Blood Adv* 2017;1(15):1159–1166
- 59 Saleem R, Rogers ZR, Neunert C, George JN. Maintenance rituximab for relapsing thrombotic thrombocytopenic purpura: a case report. *Transfusion* 2019;59(03):921–926
- 60 Ojeda-Urbe M, Federici L, Wolf M, Coppo P, Veyradier A. Successful long-term rituximab maintenance for a relapsing patient with idiopathic thrombotic thrombocytopenic purpura. *Transfusion* 2010;50(03):733–735
- 61 Delrue M, Baylatry MT, Joly AC, et al. Efficacy of subcutaneous preemptive rituximab in immune-mediated thrombotic thrombocytopenic purpura: experience from the first 12 cases. *Am J Hematol* 2020
- 62 Poullin P, Bornet C, Veyradier A, Coppo P. Caplacizumab to treat immune-mediated thrombotic thrombocytopenic purpura. *Drugs Today (Barc)* 2019;55(06):367–376

- 63 Callewaert F, Roodt J, Ulrichs H, et al. Evaluation of efficacy and safety of the anti-VWF nanobody ALX-0681 in a preclinical baboon model of acquired thrombotic thrombocytopenic purpura. *Blood* 2012;120(17):3603–3610
- 64 Peyvandi F, Scully M, Kremer Hovinga JA, et al;TITAN Investigators. Caplacizumab for acquired thrombotic thrombocytopenic purpura. *N Engl J Med* 2016;374(06):511–522
- 65 Scully M, Cataland SR, Peyvandi F, et al;HERCULES Investigators. Caplacizumab treatment for acquired thrombotic thrombocytopenic purpura. *N Engl J Med* 2019;380(04):335–346
- 66 Knoebl P, Cataland S, Peyvandi F, et al. Efficacy and safety of open-label caplacizumab in patients with exacerbations of acquired thrombotic thrombocytopenic purpura in the HERCULES study. *J Thromb Haemost* 2020;18(02):479–484
- 67 Coppo P, Bubenheim M, Azoulay E, et al. A regimen with caplacizumab, immunosuppression and plasma exchange prevents unfavorable outcomes in immune-mediated TTP. *Blood* 2020: blood.2020008021
- 68 Völker LA, Kaufeld J, Miesbach W, et al. Real-world data confirm the effectiveness of caplacizumab in acquired thrombotic thrombocytopenic purpura. *Blood Adv* 2020;4(13):3085–3092
- 69 Chander DP, Loch MM, Cataland SR, George JN. Caplacizumab therapy without plasma exchange for acquired thrombotic thrombocytopenic purpura. *N Engl J Med* 2019;381(01):92–94
- 70 Sukumar S, George JN, Cataland SR. Shared decision making, thrombotic thrombocytopenic purpura, and caplacizumab. *Am J Hematol* 2020
- 71 Völker LA, Brinkkoetter PT, Knöbl PN, et al. Treatment of acquired thrombotic thrombocytopenic purpura without plasma exchange in selected patients under caplacizumab. *J Thromb Haemost* 2020;18(11):3061–3066
- 72 Scully M, Knöbl P, Kentouche K, et al. Recombinant ADAMTS-13: first-in-human pharmacokinetics and safety in congenital thrombotic thrombocytopenic purpura. *Blood* 2017;130(19):2055–2063
- 73 Furlan M, Robles R, Morselli B, Sandoz P, Lämmle B. Recovery and half-life of von Willebrand factor-cleaving protease after plasma therapy in patients with thrombotic thrombocytopenic purpura. *Thromb Haemost* 1999;81(01):8–13
- 74 Plaimauer B, Kremer Hovinga JA, Juno C, et al. Recombinant ADAMTS13 normalizes von Willebrand factor-cleaving activity in plasma of acquired TTP patients by overriding inhibitory antibodies. *J Thromb Haemost* 2011;9(05):936–944