

# Ambulatory Use of Handheld Point-of-Care Ultrasound (HH-POCUS) in Rural Brandenburg – A Pilot Study

## Handheld-Ultraschall im Point-of-Care-Einsatz (HH-POCUS) in der ambulanten Versorgung in ländlichen Regionen Brandenburgs – eine Pilotstudie

### Authors

Hendra Lo<sup>1</sup>, Vilmar Frauendorf<sup>2</sup>, Sandra Wischke<sup>3</sup>, Christin Schimmath-Deutrich<sup>4</sup>, Markus Kersten<sup>5</sup>, Maria Nuernberg<sup>1</sup>, Dieter Nuernberg<sup>1, 6</sup>, Christian Jossen<sup>1</sup>

### Affiliations

- 1 Institute for Clinical Ultrasound, Brandenburg Medical School Theodor Fontane, Neuruppin, Germany
- 2 Gastroenterology, Ruppiner Kliniken, Neuruppin, Germany
- 3 Private Practice, Practice for Internal Medicine and Cardiology, Oberkramer, Germany
- 4 Private Practice, Practice for Internal Medicine, Neuruppin, Germany
- 5 Private Practice, Practice for General Medicine, Rheinsberg, Germany
- 6 Faculty of Health Sciences Brandenburg, Brandenburg Medical School Theodor Fontane, Neuruppin, Germany

### Key words

point of care, palliative medicine, management decision, outpatient care, handheld ultrasound devices

received 15.07.2020

accepted 11.01.2021

published online 24.02.2021

### Bibliography

Ultraschall in Med 2022; 43: 584–591

DOI 10.1055/a-1354-5958

ISSN 0172-4614

© 2021. Thieme. All rights reserved.

Georg Thieme Verlag KG, Rüdigerstraße 14, 70469 Stuttgart, Germany


### Correspondence

Prof. Dr. Dieter Nuernberg

Department of Gastroenterology, Brandenburg Medical School Theodor Fontane, Fehrbelliner Str. 38, 16816 Neuruppin, Germany

Tel.: +49/17 49 37 93 17

d.nuernberg@mhb-fontane.de

 Supplementary material is available under <https://doi.org/10.1055/a-1354-5958>

### ABSTRACT

**Purpose** This study aims to evaluate the use of handheld ultrasound devices (HHUS) for point-of-care ultrasound (POCUS) to improve outpatient care in rural Brandenburg.

**Materials and Methods** A group of general practitioners (n = 9), palliative care physicians (n = 6), emergency physicians (n = 4), and nurses from palliative care services (n = 5) participated in this study. Following a 3-hour workshop and 2 weeks of individual training, participants performed POCUS using HHUS (HH-POCUS). Indications, examination results, and resulting treatment changes (e. g., acute interventions, new medication) were documented in a standardized data entry form.

**Results** 19 physicians with different ultrasound experience and 5 palliative care nurses attended the workshop program and took part in the study. Three of the participating physicians were out of training in ultrasound and received prolonged supervision. Among 427 HH-POCUS examinations, the FAST scan and kidney scan were performed most often. Pain and dyspnea were the most common indications for HH-POCUS. Among the examinations performed by physicians (n = 311), ascites was the most common pathology (27% of cases). Using a simplified examination protocol, palliative care nurses diagnosed fluid collections, hydronephrosis and transurethral catheter position or urinary retention. In 80.4% of physician-performed cases, HH-POCUS made a valuable impact on patient management. HH-POCUS contributed to treatment decisions in 49.5% of cases, including a change of medication in 29.6% and performance of therapeutic interventions in 19.9%. Hospital admission or referral to an ambulatory specialist was initiated due to HH-POCUS findings in 17.7% of patients.

**Conclusion** HH-POCUS helped doctors in rural areas to optimize patient care through rapid on-site collection of therapeutically relevant findings. In addition, it was shown that specialized and motivated nurses can independently detect simple ultrasound findings and thus provide clinically relevant information to doctors.

## ZUSAMMENFASSUNG

**Ziel** In der Studie wird der Einsatz des Handheld-Ultraschalls (HHUS) in der ambulanten Point-of-Care (POCUS)-Versorgung in Brandenburg, einem Flächenland geringer Bevölkerungsdichte, evaluiert.

**Material und Methode** Hausärzte (n = 9), Palliativärzte (n = 6), Notärzte (n = 4) und Palliativpflegekräfte (n = 5) wurden eingeschlossen. Nach einem 3-stündigen Workshop und einem 2-wöchigen Individualtraining führten die Teilnehmer selbstständig ambulante POCUS-Untersuchungen mit HHUS-Geräten (HH-POCUS) durch. Indikationen, Befunde und resultierende Behandlungsänderungen (Akutintervention, Medikationsänderung) wurden in einem Erhebungsbogen dokumentiert.

**Ergebnisse** 19 Ärzte mit unterschiedlicher Ultraschallerfahrung und 5 Palliativpflegekräfte nahmen an Workshop und Studie teil. Unter 427 HH-POCUS-Untersuchungen waren FAST- und Nierensonografie die häufigsten. Die häufigsten Indikationen waren Schmerz und Luftnot. Bei den 311 ärztlichen Untersuchungen war Aszites die häufigste Pathologie (27%).

Unter Anwendung eines deutlich vereinfachten Untersuchungsprotokolls diagnostizierten Palliativpflegekräfte Flüssigkeitssammlungen, Harnstauung sowie die Position transurethraler Katheter bzw. Harnverhalt. In 80,4% der ärztlichen Fälle hatte HH-POCUS Einfluss auf das weitere Patientenmanagement. In 49,5% der Fälle trug HH-POCUS zur Therapieänderung bei, wobei es in 29,6% zur Medikationsänderung kam und in 19,9% eine therapeutische Intervention veranlasst wurde. Eine Krankenhauseinweisung oder Vorstellung in einer Spezialambulanz wurde aufgrund der HH-POCUS-Befunde bei 17,7% der Patienten veranlasst.

**Schlussfolgerungen** HH-POCUS half Ärzten in ländlichen Gebieten, die ambulante Betreuung durch rasche Vor-Ort-Erhebung therapeutisch relevanter Befunde zu optimieren. Darüber hinaus wurde gezeigt, dass spezialisierte und motivierte Pflegekräfte selbstständig einfache Ultraschallbefunde detektieren und so Ärzten klinisch relevante Informationen liefern können.

## Introduction

Demographic change, urbanization, and the shortage of physicians in rural areas of Germany imperil access to medical care, especially for the older population. Point-of-care ultrasonography (POCUS) is a safe and rapidly developing diagnostic technique now used by health care practitioners from almost all specialties. By increasing ultrasound (US) equipment portability, technological advancements have enabled health care practitioners to perform bedside and outpatient US, facilitating timely diagnosis and US-guided interventions [1].

While application of portable US devices in the emergency department (ED) and intensive care unit (ICU) is already established, its use in the ambulatory medicine setting is still emerging [2]. Given the relatively low cost of these systems, their mobility, and minimal maintenance requirements, they are among the most economical and practical imaging tools in developing countries and places with limited access to health care [3].

Hand-carried ultrasound devices are typically larger and require space, while handheld US (HHUS) systems can be used while holding the display unit and probe with either one or two hands (pocket-sized US). Like a stethoscope, HHUS can be integrated into a patient's physical examination and initial diagnosis, making it simpler to perform diagnostic US at the bedside than to move a patient to a specialist stationary unit or specialized practice ("EchoScopy") [4–6]. The spread of POCUS from hospital EDs to clinics and outpatient care is a challenge for the appropriate training of a significantly growing number of users [1].

In palliative care (PC), HH-POCUS is an ideal option for ambulatory patient care [7]. It gives the palliative care physician (PCP), the opportunity for immediate intervention, e. g., US-guided paracentesis or thoracocentesis. The patient experiences immediate relief, and hospitalization can be avoided in order to improve quality of life despite limited life expectancy.

Some authors reported successful application of HH-POCUS even by non-expert operators in bedside and outpatient settings after focused training [8–15]. Given the tremendous potential of EchoScopy imaging to enhance the diagnosis of many medical conditions and to guide individual patient care, little is known about existing procedures in outpatient care, such as the primary indications for the use of HH-POCUS and impacts on patient outcome.

This prospective observational study aims to evaluate the role of HH-POCUS in improving outpatient care in rural Brandenburg by analyzing its key indications, most common findings, and influence on further treatment.

## Materials and Methods

### Study Participants

The study participants were recruited successively starting in January 2018 among PCPs, general practitioners (GPs), and emergency physicians (EPs) in the northwest of the German state of Brandenburg. Of 96 physicians invited to participate in this study, 10 GPs, 8 PCPs, and 5 EPs attended our workshop, and 9 GPs, 6 PCPs, and 4 EPs were enrolled in the study as HH-POCUS examiners. All participating physicians provide home-visits and work at least partly in the out-of-hours care or pre-hospital emergency service. All 19 US examiners have acquired competency in US as part of their clinical training and 14 of them passed a basic and an advanced course of the German Society for Ultrasound in Medicine (DEGUM). 16 examiners reported that they regularly perform US examinations in their clinical practice, 7 of them > 800 examinations/year.

Considering the lack of GPs in rural regions of Brandenburg predicted for 2030 with distances of more than 30–50 kms to the nearest family practice or hospital, we also included specialia-

lized and very well-trained non-physician healthcare professionals who are not regularly authorized to perform ultrasound examinations in Germany. Therefore, palliative care nurses (PCNs) from 42 PC services of the Palliative Network Brandenburg Northwest were invited to participate in a 3-hour POCUS workshop in December 2018. 13 PCNs from five PC services providing specialized palliative home care service (SAPV: Spezialisierte Ambulante Palliativversorgung, specialized outpatient palliative care service) attended the workshop. Finally, 5 PCNs from 3 PC services participated and were enrolled in the study.

## Study design

In the 3-hour workshop, physicians and PCNs listened to lectures on HH-US application, followed by a hands-on POCUS training session supervised by an experienced instructor with a DEGUM level 2 or 3 certificate. After the workshop, the participants received the HH-US device. During two weeks of independent and accompanied training, the participants were accompanied by the instructor during patient examinations to ensure confident handling of HH-US devices. Three of the participants required additional training in US and received extended supervision.

In the application phase, after completion of each HH-POCUS examination, the participating physicians answered a structured questionnaire on the examination indication, the scope of the examination (type of scans, e. g., liver, lung, leg vessels), and the findings. In addition, the quality of the examination and its influence on clinical diagnosis and further management were to be assessed. Additional information and comments could be provided in free text (Appendix 1).

Taking into account the lack of formal ultrasound training, the indications for HH-POCUS were restricted and a simplified examination protocol was assigned for PCNs. In contrast to the physician's group, a standardized questionnaire was made including a FAST protocol to diagnose fluid in the abdominal, pericardial, and pleural cavity. In addition, examination of kidneys and bladder to detect urinary retention and assess the position of transurethral catheter was included (Appendix 2). These questions are often encountered by PCNs during their home care visits. The participating PCNs would inform the PCPs of their regional PC network of any suspected findings. A documented communication between PCNs and PCPs ensured that therapy-relevant information was not missed.

## Patient recruitment

With the exception of 2 patients with lower abdominal pain, all patients participating in the study were older than 18 years old. Patients of both sexes who received general, palliative, or emergency medical treatment were included. Informed consent was obtained from all patients.

## Equipment

Two Vscan Dual Probes and eight Vscan Extend Handheld Ultrasound systems (GE Medical Systems, Milwaukee, WI, USA) were used in this study. Both devices are equipped with a fixed broad-bandwidth phased array transducer (1.7–3.8 MHz) and a second broad-bandwidth linear array transducer (3.4–8.0 MHz).

## Statistical analysis

Data according to categories used in the questionnaire were collected and analyzed using Microsoft Excel 2016 (Microsoft Corp., Redmond, Washington, USA), and descriptive statistics were reported using number and proportion, where appropriate.

## Ethics and Financial Support

The Ethics Committee of the Brandenburg Medical School approved the study (E-01-20190829).

This study was funded by the Ministry of Culture & Science of the Federal State of Brandenburg as a research project of Health Campus Brandenburg, "digilog"-program, and as part of the "Vscan Extend Primary Care research project-DF#14915139857" (GE Healthcare, Munich, Germany).

## Results

During the study period from January 2018 to March 2020, study data of 371 patients and 447 HH-POCUS examinations were collected. Since only 7 patients were recruited from 4 EPs within 4 months due to bureaucratic hurdles, patient data from the EPs group was excluded from further analysis. Furthermore, 13 questionnaires were excluded due to inadequate patient information. Ultimately, 427 examinations with complete questionnaires from 364 patients (mean age 66 years, range: 12–100 years; 54% male) were analyzed, many of them including more than one type of US examination (e. g., liver scan and FAST scan) (► **Table 1**).

The image quality of physician-performed HH-POCUS examinations was rated by the examiners as "good" in 74.3% (231/311) and as "moderate" in 18.6% (58/311) of scans. For only 22/311 (7.1%) of examinations, the image quality was regarded as "insufficient". PCNs regarded the quality of obtained US images as "good" in 63.8% (74/116) of cases.

Both the GPs and PCPs found pain (40.4%) and dyspnea (24.3%) to be the most common reasons to perform HH-POCUS, followed by nausea/vomiting (9.4%) (► **Table 2**). Since some patients had multiple indications, 404 indications were listed in 311 questionnaires (188 from the GPs group and 123 from the PCPs group). In 9 questionnaires, there was no further description in the free text column regarding the "special reason" of the indication for performing HH-POCUS.

PCNs listed pain (27.8%), position control of transurethral catheter, or suspicion of urinary retention (21.2%), dyspnea (19.9%) and suspicion of ascites (12.6%) as the most common reasons to perform HH-POCUS (► **Table 3**).

The results of this study show a wide range of HH-POCUS applications. Participating physicians (GPs and PCPs) performed a total of 1276 different scans during 311 HH-POCUS examinations. FAST scan to rule out free fluid was the most common scan followed by kidney and liver scans (► **Table 4**). GPs most often scanned kidneys and livers followed by FAST scan, while PCPs were most interested in FAST scans followed by liver and kidney scans.

Ascites (27%), pleural effusions (14.1%), and solid liver lesions (11.5%) were the most common pathologies detected by partici-

► **Table 1** Patient data and number of HH-POCUS examinations included in the study.

examiners	number of patients	median patients age (years)	patients gender distribution	total number of HH-POCUS examinations
GPs (n = 9)	169	70	85 male 84 female	188
PCPs (n = 6)	79	61	40 male 39 female	123
all physicians (GPs and PCPs) (n = 15)	248	68	125 male 123 female	311
PCNs (n = 5)	116	64	72 male 44 female	116
All* (n = 20)	364	66	197 male 167 female	427

GPs: General Practitioners; PCPs: Palliative Care Physicians; PCNs: Palliative Care Nurses.  
\* grand total of examiners, patients, and examinations from all three groups.

► **Table 2** Indications to perform HH-POCUS scans in both groups of participating physicians (GPs and PCPs).

indication	Number of indications to perform HH-POCUS	%
pain	163	40.4%
dyspnea	98	24.3%
nausea/vomiting	38	9.4%
swollen extremities	20	5.0%
bladder voiding disorder	15	3.7%
monitoring after intervention	12	3.0%
fever	7	1.7%
jaundice	7	1.7%
obstipation	7	1.7%
swollen neck	5	1.2%
weakness	3	0.7%
ascites	3	0.7%
testicular swelling	2	0.5%
weight loss	2	0.5%
increase in abdominal circumference	2	0.5%
other*	11	2.7%
no description	9	2.2%
total	404	100%

\* Other: in this category rare indications were listed, e. g., shock, macrohematuria, cold hand, coughing, calcification in neck arteries, swelling of left thorax.

► **Table 3** Indications for performing HH-POCUS scans in the PCN group (due to multiple symptoms in some patients, a total of 151 indications were documented in 116 HH-POCUS examinations).

indication	number of indications to perform HH-POCUS	%
pain	42	27.8%
dyspnea	30	19.9%
ascites	19	12.6%
position control of the transurethral catheter	18	11.9%
nonspecific abdominal symptoms	15	9.9%
urinary retention	14	9.3%
fever	6	4.0%
flank pain	3	2.0%
monitoring after transurethral catheter removal	3	2.0%
edema	1	0.7%
total	151	100%

pating physicians with pleural effusions, hydronephrosis, ascites, gallstones, and bladder voiding disorder as the most common pathologies diagnosed by GPs. Ascites, liver lesions, and pleural effusions were the most common pathological findings diagnosed by PCPs (► **Fig. 1, 2**).

From a total of 116 patients examined by PCNs, abdominal free fluid (25.9%) and pleural effusions (25.0%) were detected the most, followed by hydronephrosis (21.6%) (► **Fig. 3**). The urinary

► **Table 4** HH-POCUS scans performed by both groups of participating physicians (GPs and PCPs). The term “scan” refers to one examination of an organ.

scan performed for	number of POCUS scans	%
FAST	180	14.1 %
kidney	169	13.2 %
liver	168	13.2 %
gallbladder	122	9.6 %
spleen	121	9.5 %
lung	104	8.2 %
pancreas	102	8.0 %
bladder	88	6.9 %
heart	63	4.9 %
abdominal aorta	61	4.8 %
inferior caval vein	52	4.1 %
extremities	38	3.0 %
jugular vein	6	0.5 %
testicles	2	0.2 %
total	1276	100.00 %

bladder was examined in 99 out of 116 patients, in 29 cases evaluating the position of a transurethral catheter.

The participating physicians reported that the clinical working diagnosis was confirmed in 82.3 % (256/311) by the HH-POCUS results and changed in 10.9 % (34/311) of cases. Participating doctors reported no additional diagnostic information of HH-POCUS only in a minority of cases (21/311; 6.8 %).

Physicians reported that performing HH-POCUS in outpatient care influenced further patient management in 250 of 311 cases (80.4 %). The majority of management decisions impacted by HH-POCUS were related to therapy: modification of medication plan (92/311 cases, 29.6 %) and initiation of interventions (62/311 cases, 19.9 %). Interventions included paracentesis (n = 50), thoracocentesis (n = 1), bladder catheterization (n = 4), and miscellaneous (n = 7) (► **Table 5**).

## Discussion

### Impact on Patient Care and Local Resources

The use of HH-POCUS in hospitals and particularly in EDs and ICUs has expanded rapidly in recent years [16], while its role in the outpatient care setting is not yet established [17]. To better examine the needs and potential advantages in different areas, we divided the participants into four groups consisting of PCPs, GPs, EPs, and PCNs. Despite the broad application of HH-POCUS in EDs [18–21], due to bureaucratic hurdles, EPs recruited only seven patients within four months and therefore were not included in the analysis.

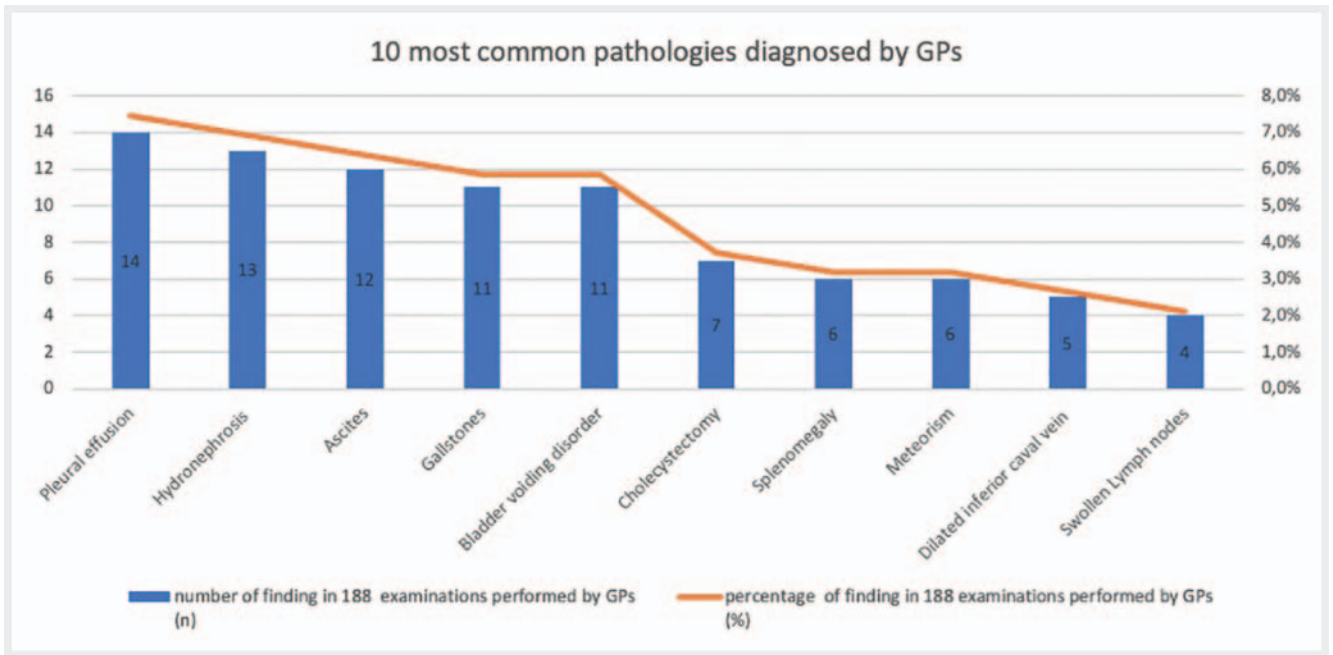
► **Table 5** Influence of HH-POCUS in the ambulatory setting on further patient management in 311 cases (GPs and PCPs groups).

medical management decisions	change in patient's management influenced by HH-POCUS findings	
	number of cases	%
<b>change of treatment</b>	<b>154</b>	<b>49.5</b>
change of medication	92	29.6
immediate intervention*	30	9.6
intervention during follow-up visits	32	10.3
<b>other management decisions</b>	<b>96</b>	<b>30.9</b>
hospital admission	32	10.3
referral to an ambulatory specialist	23	7.4
confirmation of treatment plan	14	4.5
not otherwise specified management decisions	27	8.7
<b>all management decisions</b>	<b>250</b>	<b>80.4</b>

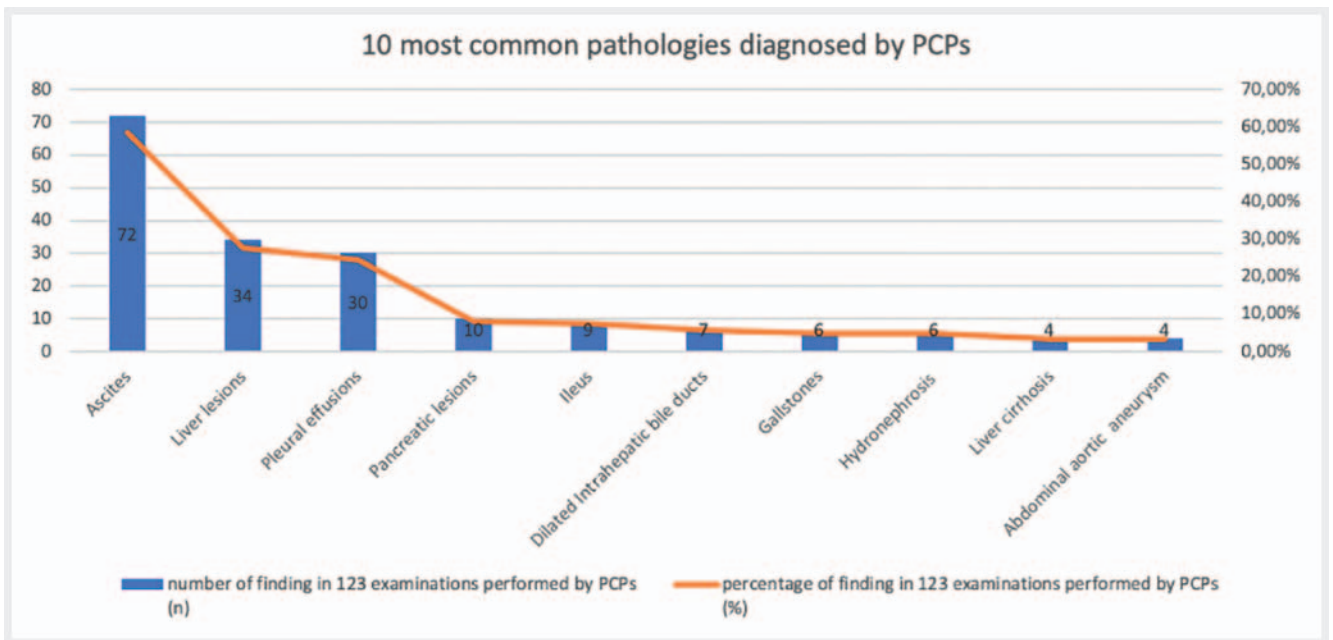
\* Therapeutic intervention was performed immediately after the HH-POCUS examination during the same ambulatory patient visit.

Presented data indicate widespread use of POCUS in an ambulatory setting and reflect the variety of medical tasks in outpatient care. The majority of questions to be answered using HH-POCUS in this study refer to the detection or exclusion of intraabdominal free fluid followed by kidney and liver scans, as pain, dyspnea, and nausea/vomiting were the most common symptoms. As shown in ► **Fig. 1, 2**, the spectrum of HH-POCUS findings collected by GPs was diverse and quantitatively broad, while ascites, solid liver lesions and pleural effusions together accounted for 75 % of the PCPs' top 10 findings. These differences in the spectrum of findings between the two groups of physicians can be explained by the fact that the GPs examined patients with a wide variety of diseases, while the PCPs cared almost exclusively for tumor patients.

In agreement with other authors [22–24], we see HH-POCUS as a practical diagnostic tool that can be easily and rapidly used bedside during home care visits to supplement the clinical examination and obtain clinically relevant additional information. Nuernberg et al. have described possible HH-POCUS applications in PC as a noninvasive, low-threshold, mobile, and targeted bedside diagnostic and intervention method [7, 25]. Our study results support this assessment. It was shown in this study that HH-POCUS gives medical professionals in outpatient care a higher degree of confidence in their decisions on further medical treatment and patient management. By integrating HHUS devices as an imaging tool in their daily practice, participating GPs and PCPs were confirmed in 82 % of their clinical working diagnoses, and the diagnosis was modified or



► Fig. 1 10 most common pathological findings of HH-POCUS examinations performed by GPs.

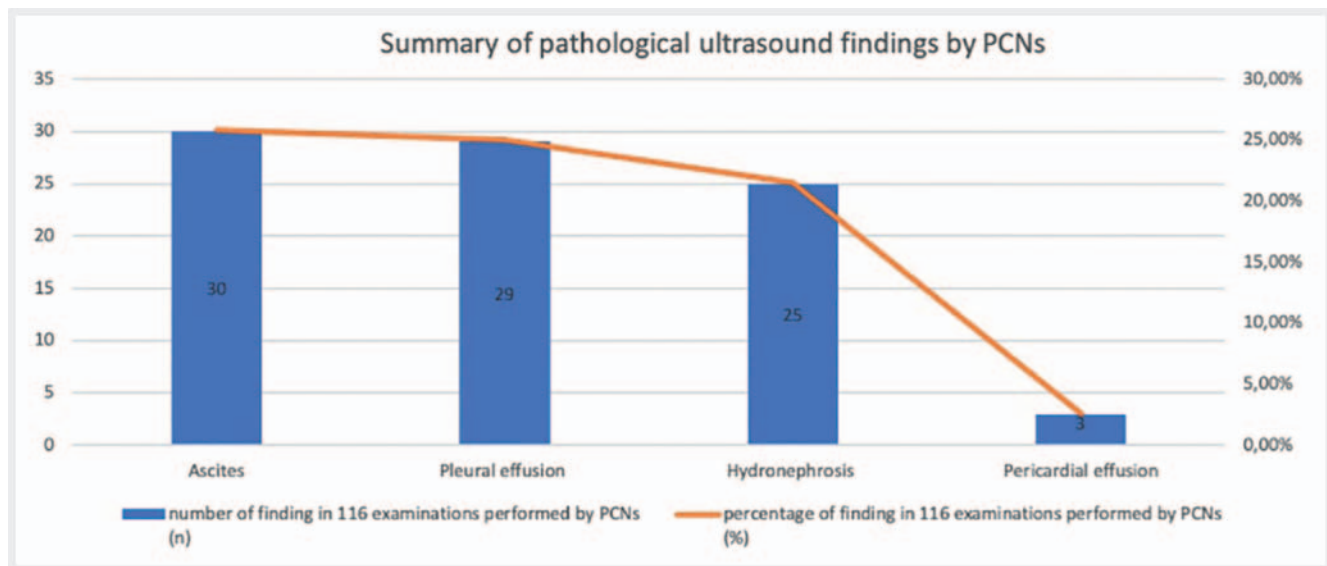


► Fig. 2 Most common pathological US findings of HH-POCUS examinations performed by PCPs.

supplemented in a substantial proportion of cases. Accordingly, the combination of clinical and HH-POCUS findings influenced patient care in eight out of ten patients. The influence of HH-POCUS was not limited to modifying medications, but also extended to other care decisions such as hospital or specialist referrals or even the implementation of interventional procedures (e.g. abdominal paracentesis). In one case, a patient diagnosed with peritoneal carcinomatosis benefited from several bedside paracentesis procedures during this study. In such a setting, bedside HH-POCUS gives PCPs

the opportunity to alleviate patient suffering by performing immediate therapeutic intervention. Moreover, US guidance of bedside interventions has been reported to reduce the risk of procedural complications [26]. Most of the PC patients are weak and have limited mobility. Avoidance of hospital admission by enabling effective and safe home care interventions unburdens community health care resources.

Since the introduction of SAPV in Germany in 2009, PCNs play a vital role as team members in PC. In the event of sudden de-



► **Fig. 3** Most common pathological findings of HH-POCUS examinations performed by PCNs.

terioration of a patient's condition, they are often the first health professionals involved and could provide clinically relevant information to the physician by using HH-POCUS. Dyspnea, pain, and bladder voiding disorders are prevalent symptoms in PC patients. By using HH-POCUS, PCNs can inform the PCPs in advance of their home visit, whether these symptoms are caused by pleural effusion, ascites, or urinary retention, thereby allowing for preparation of the drainage kit. The HH-POCUS findings collected from the PCNs in our study indicate that, in principle, specialized non-physician healthcare professionals can be empowered through structured training to conduct focused US examinations like FAST scan. However, the relatively low satisfaction rate of PCNs of 63.8% with the ultrasound image quality despite the simple and limited examination tasks might indicate that the HH-POCUS training for non-medical medical personnel needs to be intensified compared to physicians with ultrasound experience. PCNs were highly motivated to use HH-POCUS in their daily practice, and this was highly appreciated by the patients. These results should feed into the discussion on the reorganization of medical care under the conditions of the expected future shortage of GPs in rural areas. Our and other similar preliminary experiences [8, 9] should be evaluated by further studies and taken into account in the current debate on the review of DEGUM statements of 2011 (advisory board) and 2018 (executive board) against US investigations performed by non-physician medical staff [27].

### Limitations

Although this study represents an essential first step in HH-POCUS research in Germany's rural area and its benefit in improving outpatient care, there are some notable limitations. The findings were based on physicians' self-reports, and due to technical limitations, US images were not saved for further review. Therefore, the self-reported 93% rate of qualitatively sufficient (good and moderate) US images and the correctness of HH-POCUS findings cannot be checked objectively. In order to enable later review and

comparison with other imaging findings, it is urgently necessary to establish legally acceptable technical solutions for the storage of HH-POCUS images while guaranteeing data security [28, 29].

There was also no structured follow-up of study patients, which makes it difficult to assess whether the decision-making process related to HH-POCUS was effective in terms of the quality of life, safety, and health status of the patients involved. PCNs participating in this study had to report their US findings to the PCPs or GPs of the patients for review and decision. US results with potential impact on further patient management obtained by PCNs were reviewed by study supervisors or family doctors/PCPs with sufficient US experience. In order to better evaluate the impact of HH-POCUS on outpatient medical care, a comparison of health care effectiveness, safety, costs, and acceptance with and without the availability of HH-POCUS would be desirable in future studies.

Recruitment of patients and motivation of physicians to participate was hampered due to a "lack of time" expressed by several participants. To increase the use of HH-POCUS by GPs and PCPs in the ambulatory setting, a specific POCUS curriculum for outpatient care and appropriate financial reimbursement for POCUS examinations should be provided. This would facilitate financial and time investments of health care providers and GPs in HH-POCUS.

### Conclusion

The use of HH-POCUS in outpatient care in rural areas such as Brandenburg may improve patient diagnosis and management and potentially also relieve the limited resources of the health care system. The results of this pilot study provide further arguments that non-expert physicians are able to use HH-POCUS as a clinically useful tool in selected indications after completing a special US training course. Based on the initial experience with PCNs described above, the delegation of HH-POCUS studies with limited examination tasks to non-physician healthcare professionals seems feasible but needs further evaluation.

HH-US is not intended to replace advanced comprehensive US but can improve clinical decision-making, especially for immobile palliative patients in the ambulatory point-of-care setting.

By demonstrating a range of indications and an impact on patient management, the results of this study could help to promote the use of HH-POCUS in outpatient care and also stimulate the debate regarding the reimbursement of this service. To further improve the use of HH-POCUS, US teleconsulting with a technical safeguard to maintain privacy and confidentiality of the patient's data is currently being tested [30]. As part of the Internet expansion in Brandenburg, this project will be evaluated in further clinical trials.

## Funding

Ministry of Science and Culture Brandenburg; digilog program (144 000 € in 2018/2019 for systems and personal cost)

## Conflict of interest

D. Nuernberg has received lecture fees from Falk Foundation. C. Jenssen has received lecture fees from Falk Foundation and support in ultrasound courses by Bracco, GE Healthcare, Hitachi und Canon.

## Acknowledgements

This study was supported by research grants of the Ministry of Culture & Science of the State of Brandenburg (Germany) and by GE Healthcare (Munich, Germany).

The authors express their thanks to the participating physicians, nurses and palliative care services: D. Schade, M. Thierock, E. M. Frisch, A. Polzin, T. Föller, H. Parthe, L. Hegen, L. Kuball, C. Kaup-Franzen, L. Schönherr; Krammer & Krammer, Mensch & Mehr, StellaMed.

In addition, we would like to thank the non-profit association for hospice and palliative care HOSPA (Neuruppin, Germany) for providing 2 VScan devices.

## References

- [1] Bhagra A, Tierney DM, Sekiguchi H et al. Point-of-Care Ultrasonography for Primary Care Physicians and General Internists. *Mayo Clin Proc* 2016; 91: 1811–1827
- [2] Wagner M, Shen-Wagner J, Zhang KX et al. Point-of-Care Ultrasound Applications in the Outpatient Clinic. *South Med J* 2018; 111: 404–410
- [3] Spencer JK, Adler RS. Utility of portable ultrasound in a community in Ghana. *J Ultrasound Med* 2008; 27: 1735–1743
- [4] Becker DM, Tafoya CA, Becker SL et al. The use of portable ultrasound devices in low- and middle-income countries: a systematic review of the literature. *Trop Med Int Health* 2016; 21: 294–311
- [5] Wright J, Noriega O, Ho H. The application of hand-held ultrasound scanner in teaching of telemedicine and rural medicine. *Donald Scholl J Ultrasound Obstet Gynecol* 2014; 8: 87–91
- [6] Piscaglia F, Dietrich CF, Nolsoe C et al. Birth of echoscopy. *Ultraschall in Med* 2013; 34: 92
- [7] Nuernberg D, Jenssen C, Frohlich E et al. Ultrasound in palliative care medicine, Part II. *Z Gastroenterol* 2017; 55: 582–591
- [8] Robertson TE, Levine AR, Verceles AC et al. Remote tele-mentored ultrasound for non-physician learners using FaceTime: A feasibility study in a low-income country. *J Crit Care* 2017; 40: 145–148
- [9] Levine AR, McCurdy MT, Zubrow MT et al. Tele-intensivists can instruct non-physicians to acquire high-quality ultrasound images. *J Crit Care* 2015; 30: 871–875
- [10] Levine AR, Buchner JA, Verceles AC et al. Ultrasound images transmitted via FaceTime are non-inferior to images on the ultrasound machine. *J Crit Care* 2016; 33: 51–55
- [11] Shah S, Noble VE, Umulisa I et al. Development of an ultrasound training curriculum in a limited resource international setting: successes and challenges of ultrasound training in rural Rwanda. *Int J Emerg Med* 2008; 1: 193–196
- [12] Adler D, Mgalula K, Price D et al. Introduction of a portable ultrasound unit into the health services of the Lugufu refugee camp, Kigoma District, Tanzania. *Int J Emerg Med* 2008; 1: 261–266
- [13] Shmueli H, Burstein Y, Sagy I et al. Briefly trained medical students can effectively identify rheumatic mitral valve injury using a hand-carried ultrasound. *Echocardiography* 2013; 30: 621–626
- [14] Flick D. Bedside Ultrasound Education in Primary Care. *J Ultrasound Med* 2016; 35: 1369–1371
- [15] Mjølstad OC, Snare SR, Folkvord L et al. Assessment of left ventricular function by GPs using pocket-sized ultrasound. *Fam Pract* 2012; 29: 534–540
- [16] Prager R, Sedgwick C, Lund A et al. Prospective Evaluation of Point-of-Care Ultrasound at a Remote, Multi-Day Music Festival. *Prehosp Disaster Med* 2018; 33: 484–489
- [17] Nixon G, Blattner K, Muirhead J et al. Scope of point-of-care ultrasound practice in rural New Zealand. *J Prim Health Care* 2018; 10: 224–236
- [18] Olgers TJ, Azizi N, Blans MJ et al. Point-of-care Ultrasound (PoCUS) for the internist in Acute Medicine: a uniform curriculum. *Neth J Med* 2019; 77: 168–176
- [19] Leschyna M, Hatam E, Britton S et al. Current State of Point-of-care Ultrasound Usage in Canadian Emergency Departments. *Cureus* 2019; 11: e4246
- [20] Leger P, Fleet R, Maltais-Giguere J et al. A majority of rural emergency departments in the province of Quebec use point-of-care ultrasound: a cross-sectional survey. *BMC Emerg Med* 2015; 15: 36
- [21] Adler AC, Brown KA, Conlin F et al. Cardiac and Lung Point of Care Ultrasound in Pediatric Anesthesia and Critical Care Medicine: Uses, Pitfalls, and Future Directions to optimize pediatric care. *Paediatr Anaesth* 2019; 8: 790–798
- [22] Frohlich E, Beller K, Muller R et al. Point of Care Ultrasound in Geriatric Patients: Prospective Evaluation of a Portable Handheld Ultrasound Device. *Ultraschall in Med* 2019; 41: 308–316
- [23] Sabatino V, Caramia MR, Curatola A et al. Point-of-care ultrasound (POCUS) in a remote area of Sierra Leone: impact on patient management and training program for community health officers. *J Ultrasound* 2020; 23: 521–527
- [24] Epstein D, Petersiel N, Klein E et al. Pocket-size point-of-care ultrasound in rural Uganda – A unique opportunity “to see”, where no imaging facilities are available. *Travel Med Infect Dis* 2018; 23: 87–93
- [25] Nuernberg D, Jenssen C, Cui X et al. Ultrasound in palliative care medicine. *Z Gastroenterol* 2015; 53: 409–416
- [26] Brass P, Hellmich M, Kolodziej L et al. Ultrasound guidance versus anatomical landmarks for subclavian or femoral vein catheterization. *Cochrane Database Syst Rev* 2015; 1: Cd011447
- [27] Statement from the DEGUM board regarding the editorial entitled “Who's Doing Your Scan? A European Perspective on Ultrasound Services.”. *Ultraschall in Med* 2018; 40: 11–13
- [28] Nielsen MB, Cantisani V, Sidhu PS et al. The Use of Handheld Ultrasound Devices – An EFSUMB Position Paper. *Ultraschall in Med* 2019; 40: 30–39
- [29] Dietrich CF, Goudie A, Chiorean L et al. Point of Care Ultrasound: A WFUMB Position Paper. *Ultrasound Med Biol* 2017; 43: 49–58
- [30] Nuernberg D, Esfahani AH, Boten D et al. Sono-Teleconsulting (USTeleCon) – update 2019. *Ultraschall in Med* 2019; 40 (Suppl. 1): 54