

## Retinal Vasculitis Case Developing in the Early Period after COVID-19

### Retinaler Vaskulitisfall, der sich in der frühen Phase nach COVID-19 entwickelt

#### Background

Coronavirus disease (COVID-19) is a new disease that can potentially be fatal and affect the lungs and airways. The virus is thought to be most likely transmitted by an interspecies jump from bats to intermediate hosts and from animal hosts to humans [1]. COVID-19, which is highly contagious and often manifests itself with fever, cough, weakness, muscle pain, and shortness of breath, is thought to be transmitted mainly through droplets in the environment as a result of contact with infected patients [2,3]. It has been reported that COVID-19 caused by severe acute respiratory syndrome coronavirus 2 (SARS-CoV-2), which infects host cells using renin angiotensin-converting enzyme 2 (ACE2) receptors, which are widely expressed in the body, causes tissue hypoperfusion and thrombosis in different stages of the disease by causing endothelial cell inflammation and dysfunction [4–7].

In this study, we aimed to present a case that developed retinal vasculitis in the early period after a SARS-CoV-2 infection, which causes COVID-19.

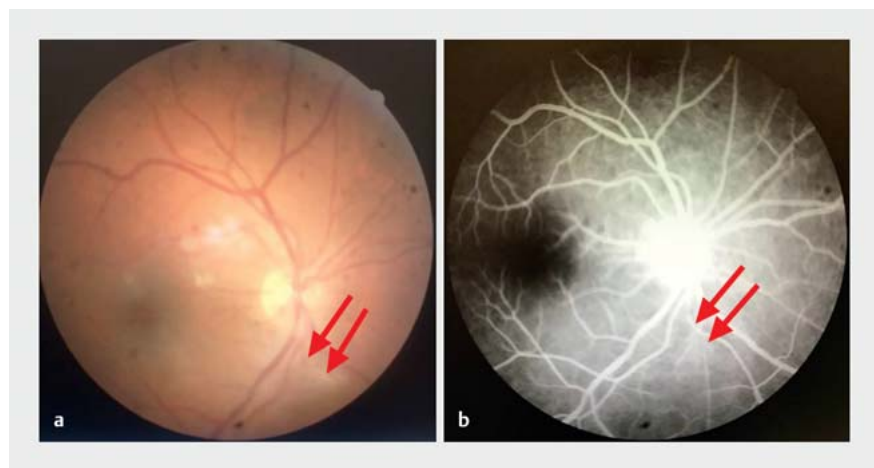
#### Case Report

A 37-year-old male patient presented to our ophthalmology outpatient clinic with a complaint of vision loss in the right eye for about 2 weeks. It was found that the patient did not have any systemic disease such as diabetes mellitus or hypertension in his history, but a diagnosis of COVID-19 was made in the reverse transcriptase-polymerase chain reaction (PCR) analysis 1 month prior. In the patient's examination, best-corrected visual acuity was 20/100 in the right eye and 20/20 in the left eye, respectively. Both anterior segments were normal. Intraocular pressure was measured as 14 mmHg in both eyes. On fundus examination, vitritis was found in the right eye. In addition, while the optic

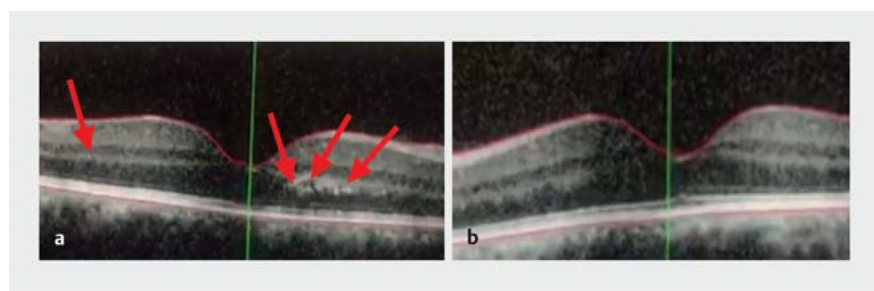
disc was observed normally, there was vasculitis in the lower nasal vessel arcuate (► **Fig. 1 a**). The patient's left eye fundus examination was normal. In the fundus fluorescein angiography (FFA), vasculitis was detected in the right eye (► **Fig. 1 b**), while the left eye was normal. While retinal hyperreflective lesions in the outer nuclear layer were detected in the right eye on optical coherence tomography (OCT), OCT findings were found to be normal in the left eye (► **Fig. 2 a, b**).

In the systemic study of the patient, a TORCH (toxoplasma, rubella, cytomegalovirus, herpes simplex virus) panel, Rose Bengal (brucella), pathergy test (for the di-

agnosis of Behçet's disease), syphilis, and HIV tests as well as ANCA, dsDNA, and anti-phospholipid antibodies were found to be normal. Red blood cell count ( $5.25 \cdot 10^6/\mu\text{L}$ ) and hemoglobin (15.1 g/dL) were found to be increased in the complete blood count, while other values were normal. Biochemical parameters, except C reactive protein (0.63 mg/dL), were within normal limits. Among the coagulation parameters, APTT, PT, and INR were within normal limits, while fibrinogen (431.03 mg/dL) was found to have a high value. There was no involvement in the chest X-ray of the patient, and sarcoidosis was excluded in the patient as a result of chest diseases consultation.



► **Fig. 1** Vasculitis image (see arrows) in a color fundus photograph (a, left) and FFA in the right eye (b, right).



► **Fig. 2** Retinal hyperreflective lesions (see arrows) in the outer nuclear layer were detected in the right eye on OCT (a, left), while normal OCT findings were seen in the left eye (b, right).

Before applying to our clinic, the patient was diagnosed with Covid-19 in the PCR test performed after complaints of fever, cough, weakness, and muscle pain, and the patient was quarantined at home for 10 days without hospitalization. In the second test performed on the 10th day afterwards, the PCR test was negative. Therefore, the patient was diagnosed with COVID-19-associated vasculitis. Then, methylprednisolone was administered in 1 g pulse for 3 days and 1 mg/kg afterward. On the 3rd day of the treatment, it was observed that the patient's best-corrected visual acuity increased to 20/25.

## Discussion

Studies have reported that COVID-19 is associated with systemic vasculitis as well as lung, liver, kidney, and skin involvement. Although it has been reported in experimental studies that ophthalmologic diseases such as retinitis and optic neuritis can be seen in this infection, there are limited studies on this subject [8, 9]. ACE2, the cellular receptor of SARS-CoV-2, has been reported to exist in ocular tissues such as aqueous humor and retina in humans. In addition, SARS-CoV-2 viral RNA was shown in retinal biopsy samples of patients [4]. It was reported that subtle cotton wool spots and microhemorrhages were seen in the retina of patients with COVID-19 [10].

In this case, it was found that the patient developed vasculitis 2 weeks after the SARS-CoV-2 infection. These findings are consistent with a recent study that reported that retinal vein occlusion developed with vasculitis 10 days after infection [11]. Vasculitis developing due to SARS-CoV-2 infection may be secondary to either the "cytokine storm" or the immune reaction against virus particles. Similarly, in some viral diseases that cause retinal vasculitis, it has been reported that a delayed immune response against viral antigens may play a role in the pathogenesis of the disease [12, 13].

In a study examining COVID patients with normal visual acuity and no signs of intraocular inflammation, subtle cotton wool spots and microhemorrhages along the retinal arcade were reported. In this study, hyperreflective lesions at the level of the

ganglion cell and inner plexiform layers were also detected in both eyes of all patients included in the study [14]. In our study, this is consistent with both hyperreflective lesions the outer nuclear layer detected on OCT.

In conclusion, in this case, vasculitis, which we detected in the early period after COVID-19, may be important in terms of revealing the necessity of close follow-up of the patients in terms of decreasing the morbidity and mortality that may occur as a result of systemic vascular pathologies that may develop due to this disease in the early period after infection.

## Conflict of Interest

The authors declare that they have no conflict of interest.

## Authors

Seyfettin Erdem , Mine Karahan, Mehmet Emin Dursun, Sedat Ava, Leyla Hazar, Ibrahim Katran, Ugur Keklikci  
Ophthalmology, Dicle University, Dicle üniversitesi tip fakültesi Göz Hastalıkları Anabilim dali, Sur, Diyarbakir, Turkey

## Correspondence

**Dr. Seyfettin Erdem**  
Dicle University  
Ophthalmology  
Dicle üniversitesi tip fakültesi Göz Hastalıkları Anabilim dali, Sur, Diyarbakir 21280 Diyarbakir  
Turkey  
Phone: +90 53 03 94 74 55  
Fax: +90 41 22 48 80 01  
serdem2147@hotmail.com

## References

- [1] Ashour HM, Elkhatib WF, Rahman MM et al. Insights into the recent 2019 novel coronavirus (Sars-coV-2) in light of past human coronavirus outbreaks. *Pathogens* 2020; 9: 186. doi:10.3390/pathogens9030186
- [2] Fan Q, Zhang W, Li B et al. Association Between ABO Blood Group System and COVID-19 Susceptibility in Wuhan. *Front Cell Infect Microbiol* 2020; 10: 404. doi:10.3389/fcimb.2020.00404
- [3] Van Doremalen N, Bushmaker T, Morris DH et al. Aerosol and surface stability of SARS-CoV-2 as compared with SARS-CoV-1. *N Engl J Med* 2020; 382: 1564–1567. doi:10.1056/NEJMc2004973

- [4] Casagrande M, Fitzek A, Püschel K et al. Detection of SARS-CoV-2 in Human Retinal Biopsies of Deceased COVID-19 Patients. *Ocul Immunol Inflamm* 2020; 28: 721–725. doi:10.1080/09273948.2020.1770301
- [5] Becker RC. COVID-19 update: Covid-19-associated coagulopathy. *J Thromb Thrombolysis* 2020; 50: 54–67. doi:10.1007/s11239-020-02134-3
- [6] Varga Z, Flammer AJ, Steiger P et al. Endothelial cell infection and endothelitis in COVID-19. *Lancet* 2020; 395: 1417–1418. doi:10.1016/S0140-6736(20)30937-5
- [7] Carnevale S, Beretta P, Morbini P. Direct endothelial damage and vasculitis due to SARS-CoV-2 in small bowel submucosa of COVID-19 patient with diarrhea. *J Med Virol* 2020. doi:10.1002/jmv.26119
- [8] Seah I, Agrawal R. Can the Coronavirus Disease 2019 (COVID-19) Affect the Eyes? A Review of Coronaviruses and Ocular Implications in Humans and Animals. *Ocul Immunol Inflamm* 2020; 28: 391–395. doi:10.1080/09273948.2020.1738501
- [9] Wang Y, Detrick B, Yu ZX et al. The role of apoptosis within the retina of coronavirus-infected mice. *Invest Ophthalmol Vis Sci* 2000; 41: 3011–3018
- [10] Marinho PM, Marcos AAA, Romano AC et al. Retinal findings in patients with COVID-19. *Lancet* 2020; 395: 1610. doi:10.1016/S0140-6736(20)31014-X
- [11] Sheth JU, Narayanan R, Goyal J et al. Retinal vein occlusion in COVID-19: A novel entity. *Indian J Ophthalmol* 2020; 68: 2291–2293. doi:10.4103/ijoo.IJO\_2380\_20
- [12] Lalitha P, Rathinam S, Banushree K et al. Ocular involvement associated with an epidemic outbreak of chikungunya virus infection. *Am J Ophthalmol* 2007; 144: 552–556. doi:10.1016/j.ajo.2007.06.002
- [13] Chan DPL, Teoh SCB, Tan CSH et al.; Eye Institute Dengue-Related Ophthalmic Complications Workgroup. Ophthalmic complications of dengue. *Emerg Infect Dis* 2006; 12: 285–289. doi:10.3201/eid1202.050274
- [14] Marinho PM, Marcos AAA, Romano AC et al. Retinal findings in patients with COVID-19. *Lancet* 2020; 395: 1610. doi:10.1016/S0140-6736(20)31014-X

## Bibliography

published online 14.4.2021  
Klin Monatsbl Augenheilkd 2022; 239: 1132–1133  
DOI 10.1055/a-1363-1326  
ISSN 0023-2165  
© 2021, Thieme. All rights reserved.  
Georg Thieme Verlag KG, Rüdigerstraße 14,  
70469 Stuttgart, Germany