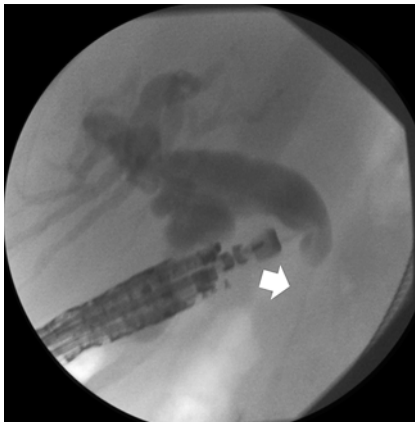


Rendezvous ERCP via endoscopic ultrasound-guided gallbladder drainage to salvage a dislodged lumen-apposing metal stent during choledochoduodenostomy

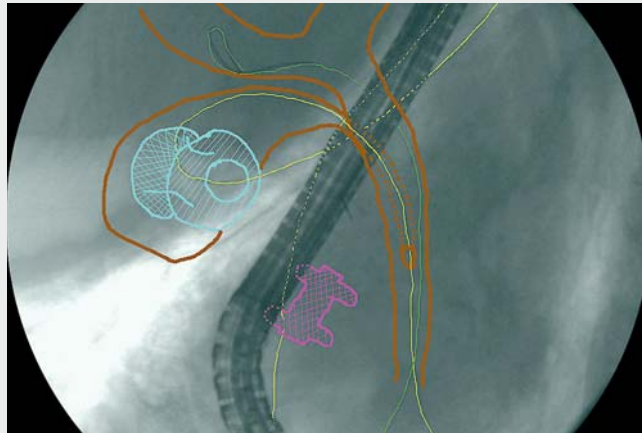


► **Fig. 1** Transduodenal endoscopic ultrasound (EUS)-guided cholangiography showing a dilated common bile duct and patent cystic duct above a malignant distal biliary stricture (white solid arrow).

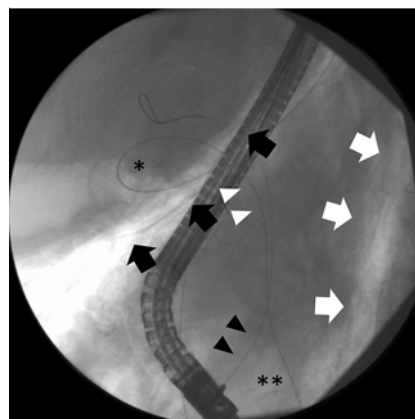
A patient with metastatic pancreatic adenocarcinoma underwent combined endoscopic ultrasound-guided fine needle aspiration (EUS-FNA) and endoscopic biliary drainage. Tumor involvement of a creased papilla precluded endoscopic retrograde cholangiopancreatography (ERCP). EUS-cholangiography revealed a dilated common bile duct (CBD) and a patent cystic duct above a distal stricture (► **Fig. 1**).

EUS-choledochoduodenostomy was performed with an 8×8-mm lumen-apposing metal stent (LAMS). Bile and contrast outflow into the duodenum confirmed satisfactory placement of the LAMS (► **Video 1**). The LAMS was balloon dilated prior to the intended insertion of an axis-orienting double-pigtail stent. However, during dilation, the distal flange of the LAMS dislodged from the CBD and guidewire access was lost. Duct decompression and aerobilia prevented repeat EUS-guided CBD puncture being performed.

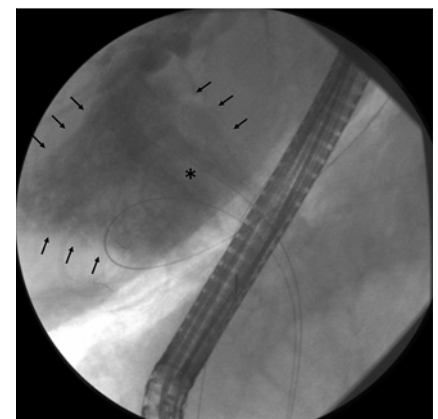
The gallbladder was imaged from the antrum and drained under EUS guidance with a cautery-enhanced 15×10-mm



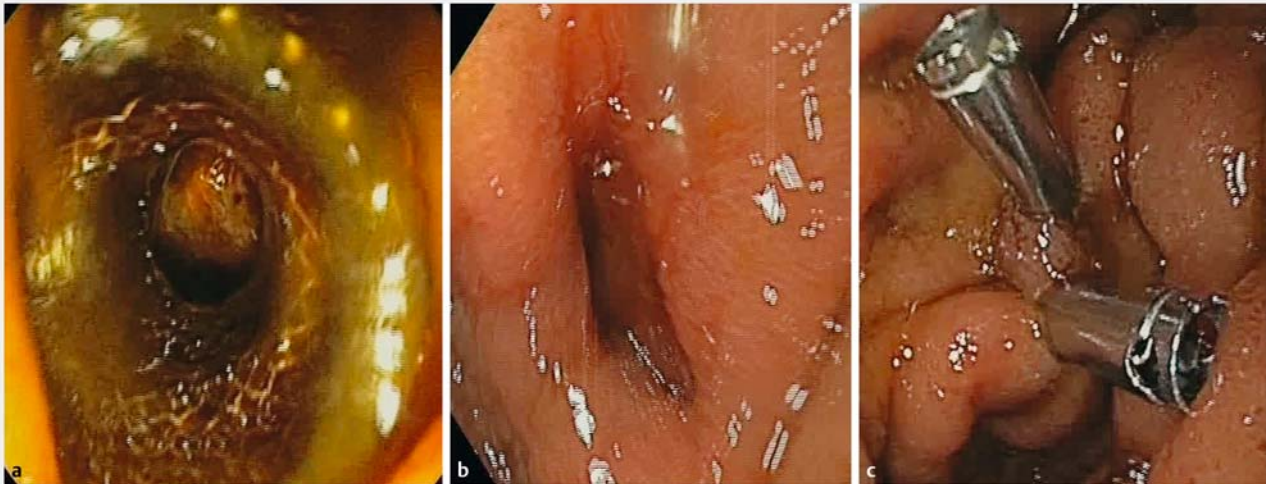
► **Video 1** Endoscopic ultrasound (EUS)-guided choledochoduodenostomy is performed, but dislodgement of the lumen-apposing metal stent occurs, resulting in a choledochal perforation. A salvage procedure consisting of EUS-guided gallbladder drainage as a portal for antegrade transcystic guidewire passage, followed by rendezvous endoscopic retrograde cholangiopancreatography is then performed, with eventual placement of a biliary metal stent and clips to seal the perforation.



► **Fig. 2** Fluoroscopic view of biliary cannulation with an incoming guidewire (black arrowheads) parallel to the guidewire entering the gallbladder through the cholecystogastric stent (*) from the patient's mouth and passing in antegrade fashion through the cystic duct (white arrowheads) into the duodenum (**). Note the retro-capnoperitoneum below the liver (black solid arrows) and next to the spine (white solid arrows), which was absent on the baseline cholangiogram.



► **Fig. 3** Contrast injection into the proximal bile duct results in gross retroperitoneal extravasation (arrows) producing a double-contrast fluoroscopic image of the common bile duct (*). This confirms the presence of an active perforation, suggesting gallbladder drainage alone might be insufficient to control it.



► **Fig. 4** Endoscopic views showing the duodenal perforation resulting from distal flange dislodgment: **a** with the dislodged lumen-apposing metal stent (LAMS) still positioned across the duodenal wall; **b** after LAMS removal with forceps traction; **c** following double clip closure.

LAMS. A gastroscope was passed through the cholecystogastric LAMS after successful balloon dilation. The cystic-duct orifice was identified using cholecystoscopy. A guidewire was advanced in an antegrade fashion through the cystic duct until it was coiled in the duodenum. The gastroscope was removed over the wire. A duodenoscope was advanced to the papilla alongside the wire. A parallel guidewire was placed into the CBD (► **Fig. 2**) through a homemade monorail sphincterotome, as previously described [1]. A covered biliary metal stent was placed over the second guidewire across the malignant stricture and the choledochal perforation that had resulted from the dislodgement of the LAMS (► **Fig. 3**). The dislodged LAMS was retrieved, with clip closure of the duodenal perforation being performed (► **Fig. 4**). The patient was given intravenous antibiotics and analgesia, and recovered within 48 hours. Acute LAMS dislodgment from nonadherent organs results in a double perforation. LAMS are increasingly used for EUS-choledochoduodenostomy, with 10% unplanned procedural events reported [2]. Standard salvage strategies include a





bridging stent if the guidewire is in place or repeat EUS-guided CBD puncture to create a new tract. Unfortunately, neither of these was possible in this case. In malignant biliary obstruction, EUS-guided gallbladder drainage allows symptomatic decompression when the cystic duct is involved [3] and rescue biliary drainage when it is patent [4]. Two-stage transluminal cholecystoscopy for biliary rendezvous was reported after failed cannulation in a poor operative candidate with acute cholecystitis and choledocholithiasis [5]. We similarly used transluminal-transcystic rendezvous to perform a single-session ERCP with biliary stenting to seal the CBD perforation that had resulted from the dislodgement of the LAMS.

Endoscopy_UCTN_Code_TTT_1AS_2AD

Competing interests

Dr. Manuel Perez-Miranda is a consultant for Boston Scientific, Olympus, Medtronic, and M.I.Tech.

The authors

Ramon Sanchez-Ocana  Marina de Benito Sanz  Rodrigo Nájera-Muñoz  Carlos Chavarria, Carlos de la Serna-Higuera, Manuel Perez-Miranda 

Gastroenterology Department, Hospital Universitario Rio Hortega, Valladolid, Spain

Corresponding author

Manuel Perez-Miranda, MD, PhD

Gastroenterology Department, Hospital Universitario Rio Hortega, Calle Dulzaina 2, 47012 Valladolid, Spain
mperezmiranda@saludcastillayleon.es

References

- [1] Martinez B, Martinez J, Casellas JA et al. Endoscopic ultrasound-guided rendezvous in benign biliary or pancreatic disorders with a 22-gauge needle and a 0.018-inch guidewire. *Endosc Int Open* 2019; 07: E1038–E1043
- [2] de Benito Sanz M, Nájera-Muñoz R, de la Serna-Higuera C et al. Lumen apposing metal stents versus tubular self-expandable metal stents for endoscopic ultrasound-

guided choledocho-duodenostomy in malignant biliary obstruction. *Surg Endosc*. doi:10.1007/s00464-020-08179-y

- [3] Choi JH, Kim HW, Lee JC et al. Percutaneous transhepatic versus EUS-guided gallbladder drainage for malignant cystic duct obstruction. *Gastrointest Endosc* 2017; 85: 357–364
- [4] Issa D, Irani S, Law R et al. Endoscopic ultrasound-guided gallbladder drainage as a rescue therapy for unresectable malignant biliary obstruction: A multicenter experience. *Endoscopy*. doi:10.1055/a-1259-0349
- [5] Law R, Baron TH. Endoscopic ultrasound-guided gallbladder drainage to facilitate

biliary rendezvous for the management of cholangitis due to choledocholithiasis. *Endoscopy* 2017; 49: E309–E310

Bibliography

Endoscopy 2022; 54: E65–E67

DOI 10.1055/a-1368-3985

ISSN 0013-726X

published online 5.3.2021

© 2021. Thieme. All rights reserved.

Georg Thieme Verlag KG, Rüdigerstraße 14, 70469 Stuttgart, Germany

ENDOSCOPY E-VIDEOS

<https://eref.thieme.de/e-videos>



Endoscopy E-Videos is an open access online section, reporting on interesting cases and new techniques in gastroenterological endoscopy. All papers include a high quality video and all contributions are freely accessible online. Processing charges apply (currently EUR 375), discounts and waivers acc. to HINARI are available.

This section has its own submission website at

<https://mc.manuscriptcentral.com/e-videos>