

Management of Intrahepatic Cholestasis of Pregnancy: Recommendations of the Working Group on Obstetrics and Prenatal Medicine – Section on Maternal Disorders

Management der intrahepatischen Schwangerschaftscholestase (Intrahepatic Cholestasis of Pregnancy – ICP): Empfehlungen der Arbeitsgemeinschaft Geburtshilfe und Pränatalmedizin (AGG – Sektion Maternale Erkrankungen)



Authors

Carsten Hagenbeck¹, Amr Hamza^{2,3}, Sven Kehl⁴, Holger Maul⁵, Frank Lammert⁶, Verena Keitel⁷, Matthias C. Hütten⁸, Ulrich Pecks⁹

Affiliations

- 1 Universitätsklinikum Düsseldorf, Frauenklinik, Düsseldorf, Germany
- 2 Universitätsklinikum des Saarlandes, Klinik für Frauenheilkunde, Geburtshilfe und Reproduktionsmedizin, Homburg, Germany
- 3 Kantonsspital Baden AG, Baden, Switzerland
- 4 Frauenklinik, Friedrich Alexander University Erlangen Nuremberg, Faculty of Medicine, Erlangen, Germany
- 5 Section of Prenatal Disgnostics and Therapy, Asklepios Klinik Barmbek, Hamburg, Germany
- 6 Klinik für Innere Medizin II, Universitätsklinikum des Saarlandes und Medizinische Fakultät der Universität des Saarlandes, Homburg, Germany
- 7 Universitätsklinikum Düsseldorf, Klinik für Gastroenterologie, Hepatologie und Infektiologie, Düsseldorf, Germany
- 8 Clinique E2 Neonatology, Maastricht Universitair Medisch Centrum+, Maastricht, Netherlands
- 9 Universitätsklinikum Schleswig-Holstein, Campus Kiel, Klinik für Gynäkologie und Geburtshilfe, Kiel, Germany

Key words

stillbirth, induction of labour, bile acids, liver disease, ursodeoxycholic acid, pruritus

Schlüsselwörter

Totgeburt, Weheneinleitung, Gallensäuren, Lebererkrankung, Ursodeoxycholsäure, Pruritus

received 13.1.2021
accepted after revision 5.2.2021

Bibliography

Geburtsh Frauenheilk 2021; 81: 922–939

DOI 10.1055/a-1386-3912

ISSN 0016-5751

© 2021. The Author(s).

This is an open access article published by Thieme under the terms of the Creative Commons Attribution-NonDerivative-NonCommercial-Licence, permitting copying and reproduction so long as the original work is given appropriate credit. Contents may not be used for commercial purposes, or adapted, remixed, transformed or built upon. (<https://creativecommons.org/licenses/by-nc-nd/4.0/>)

Georg Thieme Verlag KG, Rüdigerstraße 14, 70469 Stuttgart, Germany

Correspondence

Dr. Carsten Hagenbeck

Universitätsklinikum Düsseldorf Frauenklinik
Moorenstraße 5, 40225 Düsseldorf, Germany
Carsten.Hagenbeck@med.uni-duesseldorf.de



Deutsche Version unter:

<https://doi.org/10.1055/a-1386-3912>

ABSTRACT

Intrahepatic cholestasis of pregnancy (ICP) is the most common liver disease specific to pregnancy. The cardinal symptom of pruritus and a concomitant elevated level of bile acids in the serum and/or alanine aminotransferase (ALT) are suggestive for the diagnosis. Overall, the maternal prognosis is good. The fetal outcome depends on the bile acid level. ICP is associated with increased risks for adverse perinatal outcomes, including preterm delivery, meconium-stained amniotic fluid, and stillbirth. Acute fetal asphyxia and not chronic uteroplacental dysfunction leads to stillbirth. Therefore, predictive fetal monitoring is not possible. While medication with ursodeoxycholic acid (UDCA) improves pruritus, it has not been shown to affect fetal outcome. The indication for induction of

labour depends on bile acid levels and gestational age. There is a high risk of recurrence in subsequent pregnancies.

ZUSAMMENFASSUNG

Die Schwangerschaftscholestase (Intrahepatic Cholestasis of Pregnancy, ICP) ist die häufigste schwangerschaftsspezifische Lebererkrankung. Das Leitsymptom Juckreiz und eine begleitende Konzentrationserhöhung von Gallensäuren im Serum und/oder der Alanin-Aminotransferase (ALT) sind richtungsweisend für die Diagnosestellung. Insgesamt ist die mütterliche Prognose gut. Das fetale Outcome ist abhängig von der

Gallensäurenkonzentration. Die ICP ist sowohl mit einer Frühgeburt als auch mit dem intrauterinem Fruchttod (IUFT) assoziiert. Ursächlich ist eine akute fetale Asphyxie und nicht eine chronische uteroplazentare Dysfunktion. Daher ist ein prädiktives Monitoring, z. B. durch CTG oder Ultraschall nicht möglich. Eine medikamentöse Therapie mit Ursodeoxycholsäure (UDCA) bessert den Juckreiz – beeinflusst jedoch das fetale Outcome nicht nachweislich. Eine Entbindungsindikation ergibt sich in Abhängigkeit der Gallensäurenkonzentration und des Gestationsalters. In Folgeschwangerschaften besteht ein hohes Wiederholungsrisiko.

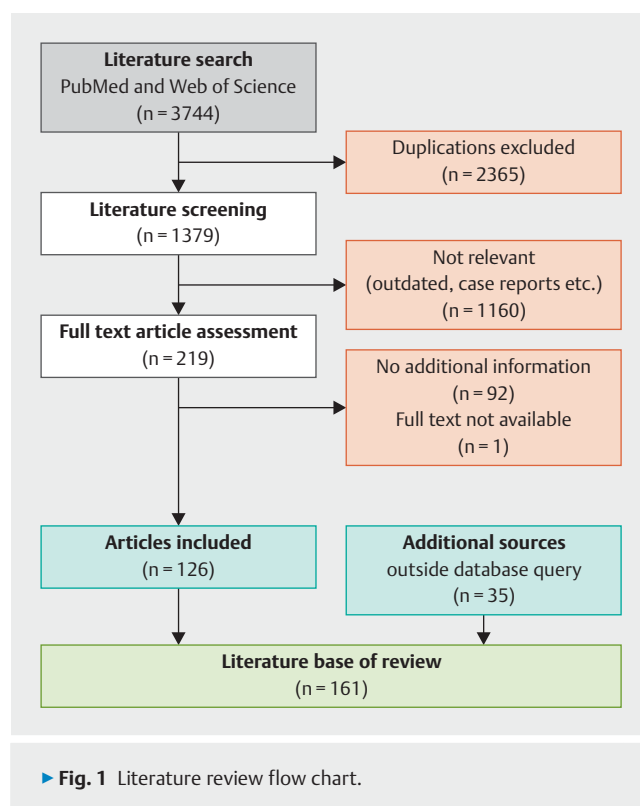
Background

Intrahepatic cholestasis of pregnancy (ICP) is the most common liver disease in pregnancy. Its prevalence in Western Europe is 0.3% to 0.7%. ICP is an interdisciplinary challenge as it is associated with serious perinatal complications such as prematurity; meconium stained amniotic fluid; neonatal adaptation syndrome; and even intrauterine fetal death. There are no uniform international recommendations. On the contrary, algorithms for pregnancy management vary considerably between international guidelines. There are no national recommendations.

This paper aims to summarise the current literature on intrahepatic cholestasis of pregnancy into structured background information and to provide interdisciplinary consensus-based recommendations based on the available evidence.

Method

In preparation for the present recommendations, a systematic literature search in PubMed and Web of Science was undertaken in October 2020. The database search was performed without time limitation using the search terms “intrahepatic cholestasis of pregnancy”, “obstetric cholestasis”, “intrahepatic cholestasis in pregnancy” and “pregnancy cholestasis” as “OR” links and after exclusion of duplicates yielded 1379 publications. Based on the literature, the statements in the existing guidelines of various multidisciplinary medical societies were reviewed according to the latest evidence-based research. The structure was revised and primarily follows a pragmatic sequence for clinical application while considering didactic aspects. To this end, the criteria of currentness and relevance for clinical management of ICP identified 219 articles from the the search output above. After completion of the full text review, 126 publications were considered for the compilation of the present recommendation. Significant sources from the associated disciplines of hepatology/gastroenterology and neonatology as well as pharmacological product characteristics complemented this review. The guideline #53 “Intrahepatic Cholestasis of Pregnancy” published by the Society for Maternal-Fetal Medicine (SMFM) in November 2020 and the study protocol of the TURRIFIC study (published on 12 January 2021) were included later on. Thus, this paper includes a total of 161 sources (► Fig. 1).



Definition

Intrahepatic cholestasis of pregnancy is characterised by a pathological elevation of hepatobiliary retention parameters in maternal blood in pregnancy. Clinical signs are pruritus without skin rash in combination with elevated bile acid and/or transaminase levels in the blood. Complications in ICP are mainly associated with elevated bile acid levels, which is why the bile acid level should be assayed. In case of bile acid levels > 10 µmol/L (fasting) or > 14 µmol/L (postprandial), ICP is likely. Usually spontaneous remission after birth can be expected. ICP is a diagnosis of exclusion.

STATEMENT BY THE WORKING GROUP ON OBSTETRICS AND PRENATAL MEDICINE

Intrahepatic cholestasis of pregnancy (ICP) is present in bile acid levels > 10 µmol/L (fasting) or > 14 µmol/L (postprandial). The diagnosis of ICP may also be raised if bile acid levels are unremarkable and the patient has both pruritus and elevated transaminase levels.

Epidemiology

ICP is the most common pregnancy-related disease of the liver [1]. Due to ethnicity, its prevalence varies greatly between geographical regions and is significantly higher in Latin American than Caucasian women [2]. The prevalence of ICP is estimated at 0.1% to 15% of all pregnancies worldwide [3,4], even reaching 22% in certain populations in Chile (Araucanian Indians) [5]. The robustness of this data, most of which is over 50 years old, is questionable on the grounds of inconsistent definitions. A recent multi-ethnic study from Australia found an overall prevalence of 0.7%. High prevalence is seen in pregnant Asian (especially from India and Pakistan) and indigenous women [6,7]. In Sweden, a population-based analysis of 1213668 singleton pregnancies in the Swedish Birth Registry from 1997 to 2009 reported an incidence of 0.32% to 0.58% [8]. Similar data is described for Finland (0.4%) [9]. There is no accurate data on the incidence in Germany.

STATEMENT BY THE WORKING GROUP ON OBSTETRICS AND PRENATAL MEDICINE

In Europe, the incidence of ICP is < 1% of all pregnancies. It varies greatly between ethnic groups.

Aetiology and Pathogenesis

ICP aetiology is multifactorial and not fully understood. A combination of genetic disposition, hormonal and environmental factors appears to favour its onset [10–13]. It is caused by impaired hepatobiliary transport resulting in retention of substances physiologically excreted with bile. Membrane-bound transport systems of hepatocytes are responsible for the elimination of bile acids and other toxic substances. The processes take place via ATP-binding cassette transporters (ABC), whose expression is regulated via transcription factors, such as FXR and SXR/PXR [14–16]. These transport processes may be affected by various mechanisms [17–20]:

1. Genetic mutations alter the expression or function of membrane-bound transporters such as ABCB4, ABCB11 and ATP8B1.
2. Endogenous and exogenous substances, such as steroid hormones and medication (cetirizine, methyl dopa, macrolide antibiotics, etc.), can interfere with transcription factors regulating the activity of the hepatobiliary transport system [14–16, 21–24].

3. One result of the reduced excretion is the accumulation of toxic substances, which has a negative impact on the function and expression of transport proteins [25].

The retention of hepatobiliary substances such as bile acids and progesterone sulphates leads to elevated blood levels with accumulation in organs resulting in cytotoxic and hormone-mediated organ dysfunction.

The primary bile acids are conjugated with glycine and taurine and secreted into the duodenum. Glycine-conjugates predominate in unremarkable pregnancies, whereas in ICP the blood levels of toxic taurine-conjugates are elevated [26]. In the in vitro animal model, taurine-conjugates have an irreversible negative effect on the rhythm and contraction amplitude of neonatal cardiomyocytes [27].

Risk Factors

► **Table 1** lists the risk factors for ICP development. Genetic mutation variants (see above) and previous or concomitant hepatobiliary disease [28–30] in particular, as well as elevated maternal oestrogen levels, favour the development of ICP [22].

High oestrogen levels in multiple pregnancies [31] as well as in early pregnancy after ovarian hyperstimulation [32, 33] are independent risk factors. The prevalence in large population twin pregnancies has been reported at 6.2–8.7% [6, 34, 35], in analyses of small case numbers up to 22% [31]. Changes in progesterone metabolism leading to large amounts of sulphated progesterone metabolites may also contribute to saturation of hepatocellular

► **Table 1** Risk factors in ICP.

Contributory factor	Risk
Genetic predisposition: particularly: ABCB4, ABCB11, ATP8B1, ABCC2, NR1H4, TJP2	unclear, effect more likely strong [41, 42]
Liver disease:	
<ul style="list-style-type: none"> ▪ Hepatitis C ▪ Hepatitis B ▪ Cholelithiasis 	OR 20.40 (95% CI 9.39–44.33) [28] OR 1.68 (95% CI 1.43–1.97) [29] OR 3.29 (95% CI 2.02–5.36) [30]
Multiple pregnancy (prevalence)	6–9% [6, 34, 35]
Elevated oestrogen/ progesterone levels	unclear
Stimulation in assisted reproductive technology (ART)	RR 3.8 (95% CI 1.0–15.0) [43]
Nutritional deficits	Vitamin D [44] Selenium [45]
Environmental factors	unclear, more frequent in winter months [46]
ICP in previous pregnancy (risk of recurrence)	45–70% [47]

transport systems and cholestasis-inducing reduction of bile secretion [21].

There is evidence that vaginal and oral progesterone application as part of treatment or prophylaxis of preterm birth increases the risk of ICP [3,36]. Other studies were unable to confirm this correlation [37].

The geographic and seasonal variability of ICP with an increase in winter months suggests that environmental factors may modulate the expression of the disease [7,38]. Specific causal factors in the environment have not been identified. Low dietary selenium and vitamin D levels (reduced sunlight exposure) are part of the debate [39,40].

STATEMENT BY THE WORKING GROUP ON OBSTETRICS AND PRENATAL MEDICINE

Hepatobiliary diseases are predisposing, in particular hepatitis C. There is no possibility of preventing ICP in case of existing risks factors.

STATEMENT BY THE WORKING GROUP ON OBSTETRICS AND PRENATAL MEDICINE

The rate of ICP recurrence in subsequent pregnancies is high, reportedly at 45–70%.

Maternal risks

Maternal prognosis during pregnancy is favourable. The mainly nocturnal pruritus can be quite distressing, even agonising. The resulting mental stress can be exacerbated by insomnia and fatigue. However, the severity of the pruritus does not correlate with the maternal bile acid serum level [48,49].

In addition, the course of pregnancy can be affected by comorbidities such as diabetes mellitus/gestational diabetes and arterial hypertension/pre-eclampsia [8]. Compared to pregnancies without ICP, the incidence of gestational diabetes is higher (13.6% vs. 8.5%, OR 1.68; 95% CI 1.04–2.72, $p < 0.03$), as is the incidence of pre-eclampsia (7.78% vs. 2.41%, OR 3.74; 95% CI 12.0–7.02, $p < 0.0001$) [50–52]. The probability of pre-eclampsia increases the earlier ICP manifests in pregnancy. The time lag is about 2–4 weeks, with proteinuria usually preceding hypertension [53]. The coincident presence of acute fatty liver in pregnancy has been described, but without proven causality [54]. Prolonged prothrombin time may be secondary to ICP-induced steatorrhea and the use of bile acid complexing agents (e.g., colestyramine) [55] with subsequent vitamin K deficiency, thus increasing the peripartum bleeding risk [56–58]. In an ICP cohort of 348 pregnant women treated solely with UDCA, postpartum blood loss did not differ from the normal population [59].

An increased rate of cardiac arrhythmias has been described, the cause of which is a direct arrhythmogenic effect of bile acids on adult cardiomyocytes [60–63]. This observation has no clinical consequence.

In the long term, patients who have experienced ICP are at increased risk of developing various liver; biliary; pancreatic; metabolic; and immune-mediated diseases (see section on “Postpartum care and follow-up”) [10,30,64,65].

STATEMENT BY THE WORKING GROUP ON OBSTETRICS AND PRENATAL MEDICINE

The severity of the pruritus does not correlate with the bile acid level. ICP has been shown to coincide with the development of gestational diabetes and pre-eclampsia.

STATEMENT BY THE WORKING GROUP ON OBSTETRICS AND PRENATAL MEDICINE

The maternal prognosis of ICP for the pregnancy is favourable. Severe maternal complications are not expected.

Fetal and neonatal risks in ICP

Bile acids accumulate in the placenta, fetus and amniotic fluid [3,66]. They can thus harmfully affect the fetus.

Stillbirth – intrauterine fetal demise (IUFD)

Stillbirth is the most feared complication of ICP. For singleton pregnancies, the prevalence is 0.83% compared to 0.32–0.44% in healthy pregnant women [67,68]. Currently, there are no predictive markers linked to the event of IUFD. The aetiology is poorly understood. It is argued that fetal peak bile acid levels are crucial and that toxic levels of taurine-conjugates induce fetal arrhythmias and vasoconstriction of the chorionic veins [69–71]. Even if placental morphology is altered [72,73], intrauterine death is an acute event.

The level of the bile acid concentration affects the risk for the onset of stillbirth. Common clusters for risk determination are levels up to 40 $\mu\text{mol/L}$, 40–99 $\mu\text{mol/L}$ and $\geq 100 \mu\text{mol/L}$ [74–78]. In a recent meta-analysis of individual patient data by Ovadia et al. of 4936 women with ICP, the IUFD rate increased significantly after gestational week 34 when a bile acid level $\geq 100 \mu\text{mol/L}$ was exceeded. The prevalence in singleton pregnancies was 3 in 2310 women with serum bile acid levels $< 40 \mu\text{mol/L}$ (0.13%; 95% CI 0.02–0.38), 4 in 1412 women (0.28%; 0.08–0.72) with levels of 40–99 $\mu\text{mol/L}$ (HR 2.35; 95% CI 0.52–10.50; $p = 0.26$) and 18 (3.44%; 2.05–5.37) in 524 women with levels $\geq 100 \mu\text{mol/L}$ (HR 30.50; 8.83–105.30); $p < 0.0001$) [68].

STATEMENT BY THE WORKING GROUP ON OBSTETRICS AND PRENATAL MEDICINE

There is an association between bile acid level, gestational age and occurrence of stillbirth.

STATEMENT BY THE WORKING GROUP ON OBSTETRICS AND PRENATAL MEDICINE

ICP is associated with increased risks for adverse perinatal outcomes, including stillbirth. The highest risk of stillbirth occurred in women with a total bile acid level $\geq 100 \mu\text{mol/L}$, regardless of the time of measurement.

Preterm birth

Increased rates of indicated and spontaneous preterm birth have been described in women with ICP [3, 8, 56, 57, 74, 79–84]. In studies the iatrogenic preterm birth resulting from a physician's decision to deliver is consistently and significantly increased [56, 57, 68, 76, 81–83]. Of equal clinical importance is spontaneous preterm birth: the meta-analysis by Ovadia et al. showed an increased risk of almost 3.5-fold (OR 3.47 [95% CI 3.06–3.95]). According to them, the risk increases with the bile acid level and particularly so at levels above $100 \mu\text{mol/L}$ ($\geq 100 \mu\text{mol/L}$ vs. $< 40 \mu\text{mol/L}$): HR 2.77 (95% CI 2.13–3.61; $p < 0.0001$); $40\text{--}99 \mu\text{mol/L}$ vs. $< 40 \mu\text{mol/L}$: HR 1.34 (95% CI 1.06–1.69; $p = 0.0158$). The population-based Swedish cohort study of more than 1.2 million singleton pregnancies by Wikström Shemer et al. found an increased rate of late preterm births among women with ICP ($32 + 0$ to $37 + 0$; aOR 3.30, 95% CI 3.00–3.63), but fewer preterm births before gestational week $32 + 0$ (aOR 0.47, 95% CI 0.27–0.81) [8].

STATEMENT BY THE WORKING GROUP ON OBSTETRICS AND PRENATAL MEDICINE

The risk of spontaneous and iatrogenic preterm birth in ICP is increased.

Meconium stained amniotic fluid

Meconium stained amniotic fluid at birth is about 4 to 7 times more common in ICP than in women without ICP [83, 85] and depends on the bile acid level. Lee et al. found that in women with bile acid levels $> 20 \mu\text{mol/L}$ each $10 \mu\text{mol/L}$ increase resulted in a 19.7% increase in meconium stained amniotic fluid [86]. In levels of $> 40 \mu\text{mol/L}$, Glantz et al. observed meconium stained amniotic fluid in 44% of cases [74]. According to two recent studies, the risk increases by a factor of 1.6–3.5 for bile acid levels between 40 and $100 \mu\text{mol/L}$, and by a factor of 3.7–4.6 for levels above $100 \mu\text{mol/L}$ [76, 85]. A rare but serious complication in meconium stained amniotic fluid is fetal meconium aspiration [87]. The incidence of meconium aspiration syndrome in meconium stained amniotic fluid reportedly is up to 5% [87]. It is characterised by early postnatal onset of severe respiratory distress syndrome with subsequent hypoxia. However, the onset of symptoms can also be delayed. Up to one third of neonates with meconium aspiration require intubation with mechanical ventilation to ensure oxygenation [88]. Routine intrapartum aspiration of meconium stained amniotic fluid is not recommended [89].

STATEMENT BY THE WORKING GROUP ON OBSTETRICS AND PRENATAL MEDICINE

The frequently seen meconium stained amniotic fluid in ICP increases the risk of meconium aspiration syndrome in neonates.

Perinatal management should therefore consider the diagnosis of ICP. Neonatologists should already be informed before birth and be aware of the risk.

Neonatal complications

The risk of the neonate being admitted to a neonatal unit more than doubles with severe maternal cholestasis (12% vs. 5.6%) [34, 68]. The most important factor here is prematurity [90]. Regardless, neonatal respiratory distress syndrome was a specific risk of ICP (aOR 2.56; 95% CI 1.26–5.18) [91]. Elevated bile acid levels are thought to affect alveolar enzyme function, resulting in surfactant inactivation and a pulmonary inflammatory response with resultant respiratory distress syndrome [92–94]. The association of ICP with other neonatal complications has only been described in small populations. In a retrospective cohort study in infants of mothers with bile acid levels $> 100 \mu\text{mol/L}$, the retrospective cohort study by Herrera et al. showed a risk, increased by a factor of 5.6 after adjustment for gestational age at delivery, of neonatal morbidity defined as hypoxic ischaemic encephalopathy (HIE), severe intraventricular haemorrhage (IVH, grade 3–4), bronchopulmonary dysplasia (BPD), necrotising enterocolitis (NEC), and postnatal death. However, the total number of events (30 in 785 pregnancies) in this study was small, and no patient developed isolated IVH or HIE [85]. In contrast, Kawakita et al. in a retrospective multicentre cohort study of 233 women after adjustment (age; ethnicity; hypertension; diabetes; BMI; duration of pregnancy; bile acid level; intrahepatic cholestasis of pregnancy; use of UDCA; transaminase level; and pre-existing liver disease) could not demonstrate significant neonatal morbidity [76].

STATEMENT BY THE WORKING GROUP ON OBSTETRICS AND PRENATAL MEDICINE

There is evidence of increased rates of neonatal admissions of exposed neonates independent of prematurity, but data on increased long-term neonatal morbidity in ICP are inconsistent.

Symptoms and Time of Manifestation

Pruritus is the hallmark symptom of ICP, and in many cases the only symptom reported. Initially, this typically affects the palms of the hands and soles of the feet. Sometimes the symptoms undergo secondary generalisation. The subjective spectrum of intensity is described as ranging from “mild” to “unbearable”, markedly intensified at night [95]. In up to 80% of cases, ICP manifests after the 30th week of gestation; the time of manifestation is usually in the late 2nd and early 3rd trimester [47, 82]. Transitory symptoms in the first trimester are associated with ovarian hyper-

stimulation syndrome following in vitro fertilisation [32], while persistent and worsening symptoms are characteristic of naturally conceived pregnancies [96]. While localised and generalised pruritus is a common symptom in pregnancy, in up to 9% of cases it is ICP [47, 97, 98]. However, in more than 80% of cases, ICP manifests as pruritus [34, 56]. Although bile acid deposits in the skin are blamed for pruritus, its severity does not correlate with serum bile acid level [48, 49]. There are no characteristic skin changes. Scratching may cause secondary efflorescence (dermatographica artefacta), which must be differentiated from other pregnancy dermatoses. These include atopic eruption of pregnancy (AEP), polymorphic eruption of pregnancy (PEP; previously known as PUPP: pruritic urticarial papules and plaques of pregnancy) and gestational pemphigoid (syn.: pemphigus gravidarum, gestational herpes) [99, 100]. Accompanying symptoms may include pain in the upper abdomen, nausea, loss of appetite, sleep deprivation, and steatorrhoea. Icterus as an accompanying symptom is quite rare and then occurs with a time lag of about 1 to 4 weeks after the initial pruritus. Some regional data put the incidence of jaundice as high as 25% [74, 100–103]. Symptoms of icterus, such as dark urine and light to greyish stools, should be assessed by differential diagnosis.

STATEMENT BY THE WORKING GROUP ON OBSTETRICS AND PRENATAL MEDICINE

Pruritus, especially at night and starting on the palms of the hands and soles of the feet, is considered the cardinal symptom of ICP. Accompanying symptoms may include pain in the upper abdomen, nausea, loss of appetite, sleep deprivation, and steatorrhoea.

Diagnosis

ICP is a diagnosis by exclusion. The cardinal symptom pruritus is suggestive and should prompt further workup [104]. The medical history must include a family history and physical examination. In unclear cases, especially in the case of primary skin eruptions, dermatological consultation should be obtained. Clinical chemistry panels can further confirm the suspected diagnosis [57]. It is recommended that the patient be seen by an internist to undergo liver ultrasonography to rule out other cholestatic disease. ► **Table 2** gives an overview of the diseases to be included in the differential diagnosis.

Laboratory evaluation

Bile acids

Bile acids are synthesised from cholesterol in the liver. First, the primary bile acids (chenodeoxycholic acid and cholic acid) are conjugated with glycine or taurine and secreted into the duodenum. In the intestine, the primary bile acids are transformed into secondary or tertiary bile acids mainly through the action of bacterial enzymes. These are absorbed in the terminal ileum and are thus subject to the enterohepatic circulation. The bile acids detected in the blood originate from intestinal reabsorption.

Various assay techniques are used in bile acid measurement. Total serum bile acids (TBA) and bile acid fractions can be assayed by mass spectrometry and liquid chromatography, which is typically performed in specialised laboratories. Total serum bile acids can also be quantified by an enzymatic assay. This assay is also performed in some hospital laboratories. The enzymatic assay does not detect bile acid fractions individually. Accordingly, medication with the tertiary bile acid ursodeoxycholic acid can result in levels that are falsely high.

The reference values of the different assay techniques are based on fasting samples (according to most manufacturers fasting > 12 h). However, postprandial assaying is possible. Numerous studies show that the postprandial elevation in bile acid levels is only minor [105, 106]. If postprandial levels $\geq 100 \mu\text{mol/L}$ are reached in some cases (without UDCA administration – depending on the type of assay [see above]), follow-up testing can also measure the fasting level for differential diagnostic consideration.

Fasting healthy pregnant women have a normal bile acid level of 6–10 $\mu\text{mol/L}$ and a postprandial level of 10–14 $\mu\text{mol/L}$. The meta-analysis by Ovardia et al. of fasting pregnant women with ICP (n = 1726) showed a median level of 23.0 $\mu\text{mol/L}$ (IQR 14.7–41) versus 32.0 $\mu\text{mol/L}$ (IQR 19.0–61.5) in postprandial patients (n = 2795) [68]. Irrespective of fasting and UDCA therapy, various analyses have shown the elevated total serum bile acid level to be a sensitive and specific marker (OR = 4.17, p = 0.0037, AUC = 0.62, p = 0.046) in the diagnosis of ICP and the related adverse perinatal outcome [107, 108].

Furthermore, normal bile acid levels in pruritus do not rule out the diagnosis of ICP, as it can sometimes take weeks for laboratory changes to manifest [3, 56, 79–83, 109, 110]. Follow-up testing is indicated in these cases if unexplained pruritus persists, and bile acid levels should always be considered in the context of the overall clinical presentation.

STATEMENT BY THE WORKING GROUP ON OBSTETRICS AND PRENATAL MEDICINE

- In fasting blood, the upper reference range of bile acid levels is 6–10 $\mu\text{mol/L}$ and in postprandial blood 10–14 $\mu\text{mol/L}$.
- Sometimes it may take up to four weeks after the initial pruritus for laboratory results to become abnormal.
- Normal bile acid levels in pruritus do not rule out the diagnosis of ICP.
- Ursodeoxycholic acid medication may yield falsely high values, depending on the assay technique employed.

Transaminases

When pruritus is present in ICP, 60% of patients can be expected to develop elevated AST/ALT levels two to thirty times above normal. The elevation in transaminase levels does not correlate with bile acid levels [111–113]. ALT activity is independent of pregnancy and together with corresponding clinical signs can firm up the diagnosis even if there is no bile acid elevation [109, 112].

► **Table 2** Differential diagnoses in ICP [99, 100, 116–118].

Differential diagnoses	Clinical presentation	Time of manifestation	Features differentiating it from ICP
Pruritus in pregnancy			
Pruritus gravidarum	Pruritus (generalised)	mostly 3rd trimester	as in ICP, no change in laboratory values (AST/ALT, TBA)
Atopic eruption of pregnancy (AEP)	Pruritus, extensive eczematous papules on the flexor aspect (70%) or disseminated papules and prurigo lesions on the extensor aspect (30%)	75% before 3rd trimester	no changes in clinical chemistry (AST/ALT, TBA), typical skin rashes
Gestational pemphigoid (syn.: pemphigus gravidarum, gestational herpes)	Pruritus days to weeks before vesicular exanthema. Plump periumbilical bullae on pruritic urticarial erythema.	Onset in the 3rd trimester, postpartum	Typical skin efflorescences, complement-binding autoantibodies also bind to basement membrane of the chorionic and amniotic epithelium (→ SGA, IUGR). Diagnosis confirmed by immunofluorescence. Lab panel: Eosinophilia, AST/ALT, TBA not elevated.
Polymorphic eruption of pregnancy (PEP, formerly: PUPP)	Pruritus – frequent onset in the striae distensae. Exanthema (nodules, plaques) on the abdomen (periumbilical sparing), thighs, buttocks, arms, and lateral aspects of the trunk.	last weeks of pregnancy or immediately postpartum (15%)	no changes in clinical chemistry (AST/ALT, TBA), typical skin rashes
Pre-existing causes of pruritus			
Atopic dermatitis	Pruritus	entire pregnancy	Medical history, neurodermatitis
Allergic skin reactions	Pruritus	entire pregnancy	Medical history
Clinical conditions with liver dysfunction specific to pregnancy			
HELLP syndrome	Pain upper quadrants, hypertension, headache, neurological deficits	2. + 3rd trimester and postpartum	Pain upper quadrants, haemolysis, neurological deficits. Lab panel: Haptoglobin ↓, AST/ALT ↑, thrombocytopenia, proteinuria
Acute fatty liver of pregnancy	General feeling of malaise, polydipsia, polyuria, icterus, nausea, vomiting	2. + 3rd trimester and postpartum	Hypoglycaemia, leukocytosis, hyperbilirubinaemia, antithrombin ↓, prothrombin time ↑, (creatinine ↑)
Hyperemesis gravidarum	Nausea, vomiting	mainly 1st trimester	Usually limited to 1st trimester, AST/ALT ↑ – rapidly normal after cessation of symptoms, ketonuria, ketonaemia
Other liver dysfunctions			
Viral hepatitis (A, B, C, D, E)	Icterus, nausea, vomiting, abdominal pain	entire pregnancy	General symptoms, antibodies in the blood
Primary sclerosing cholangitis (PSC), primary biliary cirrhosis (PBC)	Pruritus, icterus, nausea, lethargy, fatigue, performance slump	Symptoms before pregnancy	Liver ultrasonography, MRCP. Antibodies: PSC: pANCA PBC: AMA
Autoimmune hepatitis	Icterus, fatigue, nausea, loss of appetite	Symptoms before pregnancy	Antibody constellation: ANA, SMA, SLA
Bile duct obstruction (e.g. cholelithiasis)	abdominal pain	entire pregnancy	Liver ultrasonography, MRI
Medication, drugs	Pruritus, icterus	at any time	Medical history, timing of application/abuse and symptoms

Acronyms: PEP – Polymorphic eruption of pregnancy, PUPP – pruritic urticarial papules and plaques of pregnancy, MRCP-Magnetic resonance cholangio-pancreatography, SMA – smooth muscle antibody, SLA – soluble liver antigen, pANCA – perinuclear staining pattern of anti-neutrophil cytoplasmic antibodies, AMA – anti-mitochondrial antibody, ANA – anti-nuclear antibody, AST – aspartate transaminase, ALT – alanine transaminase, TBA – total bile acids

► **Table 3** Differential diagnosis of liver disease in pregnancy (from [119]).

Criteria	HELLP	Acute fatty liver of pregnancy	Acute viral hepatitis	ICP
Haemolysis	++	(+)	–	–
Transaminases ↑	++	++	+++	+
Thrombocytopenia	++	secondary +	–	–
Hypertension	++	+	–	–
Proteinuria	+++	+	–	–
Leukocytosis	–	+++	++	–
Kidney failure	+ → +++	secondary +	–	–
Neurological symptoms	+ → +++	++	–	–
Icterus	(+)	+	+++	(+)
Other	DIC	Hypoglycaemia DIC → Bleeding	Bilirubin ↑ Virus serology	Pruritus Cholestasis

Hemostasis

ICP does not affect coagulation. In case of pre-existing vitamin K deficiency in the context of steatorrhoea or the administration of bile acid complexing agents (e.g., colestyramine), prothrombin time may be prolonged. This is caused by a decrease in vitamin K-dependent factors (II, VII, IX or X) and thus there is an increased risk of peripartum haemorrhage [56–58].

Other laboratory parameters

Elevated direct bilirubin levels are present in up to 20% of cases [57]. Serum gamma GT activity is normal or only moderately elevated, which may be helpful in differential diagnosis. Familial gene mutations, e.g., ABCB4 (MDR3), associated with ICP may present with elevated levels [3, 113, 114]. Due to placental isoenzyme expression with resulting elevated levels, alkaline phosphatase does not play a role in the diagnostic workup of ICP.

RECOMMENDATION BY THE WORKING GROUP ON OBSTETRICS AND PRENATAL MEDICINE

The diagnosis of ICP should be confirmed by determining the following laboratory parameters: bile acids, transaminases, gamma GT, total bilirubin, and prothrombin time.

Ultrasonography of the liver

Ultrasound imaging of the liver helps in the differential diagnosis (see section on “Differential diagnoses”). There are no specific findings typical of ICP, the bile ducts are unremarkable [115].

RECOMMENDATION BY THE WORKING GROUP ON OBSTETRICS AND PRENATAL MEDICINE

ICP differential diagnosis should rule out especially the hepatitises. This requires the medical history, clinical examination as well as clinical chemistry and possibly sonographic evaluation.

RECOMMENDATION BY THE WORKING GROUP ON OBSTETRICS AND PRENATAL MEDICINE

Differential diagnosis should include abdominal ultrasonography, particularly to rule out the possibility of obstructive cholestasis.

Differential diagnoses

► **Table 2** provides an overview of the various differential diagnoses in ICP, considering the clinical presentation, time of manifestation and their specific characteristics. ► **Table 3** compares the various manifestations of different parameters in liver disease during pregnancy.

Management of Intrahepatic Cholestasis

Currently, there are no uniform international recommendations for monitoring pregnant women with ICP. Depending on symptom severity, bile acid level and the subjective stress situation of the pregnant woman, both she and her physician should agree on a common goal for the treatment. This also includes setting the timing of delivery against the backdrop of the risk situation, which may have to be readjusted during the pregnancy.

Monitoring the pregnancy

It is unclear how and how often monitoring makes sense, and this is the subject of discussion. Sometimes the laboratory changes only develop with delay. Therefore, follow-up can be useful. If the clinical symptoms are dynamic and TBA $\geq 100 \mu\text{mol/L}$, ALT and/or AST $> 200 \text{ IU/L}$, laboratory evaluations (bile acids; ALT; AST; gamma GT; bilirubin; and prothrombin time) should be performed more often and, if necessary, inpatient monitoring should be considered. There are no evidence-based follow-up intervals – serial check-ups (e.g., weekly) are not recommended [120].

Rapid, excessive increase or normalisation of the liver enzymes should prompt questioning of the diagnosis of ICP and assessment of possible differential diagnoses.

Bile acid levels $\geq 100 \mu\text{mol/L}$ are relevant for treatment (see section on “Delivery timing”). It is unclear whether clinical consequences should also be considered if the levels were initially above the cut-off limits but then were lowered, e.g., with medication. Based on the theory that peak bile acid levels affect outcome, this should be considered when timing the delivery.

The laboratory-specific assay technique is significant when measuring bile acid levels (see section on “Bile acids”). To reduce inaccuracy, UDCA should only be administered after blood has been drawn.

STATEMENT BY THE WORKING GROUP ON OBSTETRICS AND PRENATAL MEDICINE

It is unclear how and how often pregnant women should be monitored.

RECOMMENDATION BY THE WORKING GROUP ON OBSTETRICS AND PRENATAL MEDICINE

Follow-up blood chemistry allows an assessment of the following parameter dynamics: bile acids; ALT; AST; gamma GT; total bilirubin; and prothrombin time. The testing intervals depend on the symptoms of each patient.

Fetal monitoring

Neither CTG nor Doppler ultrasonography can predict the timing of a possible ICP-specific complication [121]. Therefore, antenatal monitoring is controversial. While CTG changes in ICP have been reported, they are not associated with intrauterine fetal death [38]. Stillbirth in ICP is a sudden event without evidence of placental dysfunction. There is no association with either fetal growth restriction or oligohydramnios [3, 82, 84, 109]. Other fetal monitoring techniques, such as amniocentesis and transcervical amniocentesis (for meconium identification in amniotic fluid) [83], fetal electrocardiography [122], fetal kinetography or an fetal movement pattern monitoring have not been adequately explored in studies. Fetal echocardiography with evaluation of the left ventricular myocardial performance index (MPI) offers promising predictive approaches [123–125] but has not yet played a role in standard care.

Even without evident proof of efficacy, regular follow-up is established in clinical routine, mostly by CTG and ultrasonography. Follow-up intervals should be based on pre-existing comorbidities of the mother and the ICP-specific risk profile in TBA $\geq 100 \mu\text{mol/L}$. During delivery, continuous fetal monitoring should be performed.

STATEMENT BY THE WORKING GROUP ON OBSTETRICS AND PRENATAL MEDICINE

Neither ultrasonography/Doppler ultrasound nor cardiocotography are able to predict stillbirth in ICP patients. Evidence-based follow-up intervals therefore do not exist.

RECOMMENDATION BY THE WORKING GROUP ON OBSTETRICS AND PRENATAL MEDICINE

Prenatal monitoring should be guided by pre-existing comorbidities and the ICP-specific risk profile in TBA $\geq 100 \mu\text{mol/L}$.

RECOMMENDATION BY THE WORKING GROUP ON OBSTETRICS AND PRENATAL MEDICINE

During delivery, continuous fetal monitoring should be performed.

Treatment

STATEMENT BY THE WORKING GROUP ON OBSTETRICS AND PRENATAL MEDICINE

ICP management pursues two therapeutic goals:

1. Managing maternal symptoms, especially pruritus.
2. Reducing perinatal morbidity and mortality.

STATEMENT BY THE WORKING GROUP ON OBSTETRICS AND PRENATAL MEDICINE

While medication can alleviate symptoms typical of ICP, it does not improve fetal outcome. Giving birth is the only known causal treatment.

Topical agents

Various creams and ointments are used: For example, 2% water-based menthol cream or dimetindene maleate gel may help relieve the itching. Topical treatment does not affect laboratory parameters or perinatal outcome [126].

RECOMMENDATION BY THE WORKING GROUP ON OBSTETRICS AND PRENATAL MEDICINE

Topical applications are part of the basic treatment and should be offered to patients.

Ursodeoxycholic acid (UDCA)

UDCA is a naturally occurring bile acid derivative with an anticholestatic effect in the human body. UDCA is commonly used off-label in the treatment of ICP. UDCA has several cholestasis-preventing effects, in particular the induction of hepatic metabolic enzymes and bile acid transporters increases the excretion of bile acids, protects the cholangiocytes of the bile epithelium from the cytotoxicity of bile acids and protects hepatocytes from bile acid-induced apoptosis.

Several prospective randomised trials on the treatment of ICP have been carried out [127–131]. The PITCHES trial, published in

2019, aimed to prevent stillbirths by UDCA medication. 605 pregnant women with ICP were prospectively randomised in double-blind fashion to the study arm UDCA (initial 2 × 500 mg daily) or placebo: The UDCA group demonstrated an improvement in pruritus and ALT levels. Compared to placebo, UDCA treatment did not improve the combined perinatal outcome (neonatal mortality, preterm birth, NICU admission): 23 vs. 27% (RR 0.85; 95% CI 0.62–1.15). However, the total number of stillbirths (n = 3) in the trial was rather small [127]. The strict induction policy of the trial, conducted in England and Wales, from 37 + 0 weeks gestation may have contributed to this [57]. A secondary subgroup analysis could not identify any cohort in whom UDCA significantly reduced TBA levels or pruritus [132]. The analyses did not consider which dose of UDCA each pregnant woman had taken and over which period, which considerably weakens the significance [133]. A Cochrane review published in July 2020 on the use of UDCA in ICP highlights the benefit in reducing pruritus, but not in preventing stillbirth or spontaneous preterm birth [126]. However, there are the following trends in perinatal outcome with UDCA compared to placebo:

- IUFT/stillbirths: RR 0.33 (95% CI 0.08–1.37; 6 trials, n = 955).
- Transfer to NICU: RR 0.77 (95% CI 0.55– 1.08; 2 trials, n = 764).
- Spontaneous preterm birth: RR 0.78 (95% CI 0.49–1.23; 3 trials, n = 749).
- Spontaneous and iatrogenic preterm births: RR 0.60 (95% CI 0.37–0.97; 3 trials, n = 819).

In addition to the perinatal effects, long-term effects are also suspected. For example, it has recently been shown that treatment with UDCA has a favourable effect on fetal lipid metabolism [134].

UDCA treatment is safe and has few side effects [127]. The latter are limited to gastrointestinal symptoms ranging from pasty stools to diarrhoea [135]. The initial oral dose usually is 3 × 250 mg or 2 × 500 mg. Dosing may be adjusted depending on the maternal symptoms. The maximum UDCA dose often administered in trials is 2000 mg. In this context it is used off-label. Dosage recommendations vary and are mostly 10–15 mg/kg bw [104, 127].

STATEMENT BY THE WORKING GROUP ON OBSTETRICS AND PRENATAL MEDICINE

Ursodeoxycholic acid can improve both maternal symptoms and liver function in ICP. According to current evidence, the therapy does not change the perinatal outcome.

RECOMMENDATION BY THE WORKING GROUP ON OBSTETRICS AND PRENATAL MEDICINE

Bile acid levels should be determined before initiating treatment. Depending on the laboratory assay technique, it should be noted that ursodeoxycholic acid medication may yield falsely high serum bile acid levels.

RECOMMENDATION BY THE WORKING GROUP ON OBSTETRICS AND PRENATAL MEDICINE

If ICP is suspected clinically, oral treatment with ursodeoxycholic acid should be initiated irrespective of bile acid levels, with the goal of alleviating maternal symptoms.

Rifampicin

Rifampicin is a broad-spectrum antibiotic administered in pregnancy to treat tuberculosis [136]. The medication lowers the serum bile acid level in cholestasis outside pregnancy [137]. Experience with ICP treatment is limited to a handful of reports on pregnant women in combined use with UDCA after failed single-agent therapy [138, 139]. The total daily dose of rifampicin was between 300 and 1200 mg. Pruritus improved in 11 out of 16 (69%) patients and bile acid levels decreased in 14 out of 27 (54%). All infants were delivered between 32 and 37 weeks gestation with an unremarkable outcome. The recruiting Australian TURREFIC-trial (EudraCT number: 2018-004011-44) [140] targets a comparison of rifampicin with UDCA.

RECOMMENDATION BY THE WORKING GROUP ON OBSTETRICS AND PRENATAL MEDICINE

If pruritus persists during UDCA therapy, additional administration of rifampicin may be considered in individual cases.

Colestyramine

As an anion-exchange resin, colestyramine prevents the reabsorption of bile acids in the enterohepatic circulation. The sequela of this malabsorptive treatment is steatorrhoea with excretion of fat-soluble vitamins. Decreased vitamin K levels may result in significant peripartum bleeding complications in mothers and neonates [141]. A trial with 84 pregnant women comparing UDCA with colestyramine revealed that the anion exchange resin was inferior in all outcome parameters (reduction of pruritus, bile acids and AST/ALT) and worse tolerated (29% nausea/vomiting/diarrhoea vs. 0% adverse events in the UDCA group) [142]. Because of the mechanism of action, combined treatment with UDCA is counter-productive in terms of the pharmacokinetics.

RECOMMENDATION BY THE WORKING GROUP ON OBSTETRICS AND PRENATAL MEDICINE

ICP should not be treated with colestyramine.

S-Adenosyl-L-methionine (SAME)

SAME is metabolised in the liver, among other organs, and serves as a methyl group donor in the biosynthesis of phospholipids for the excretion of oestrogen metabolites [143, 144]. In animal models, SAME has been shown to reduce cholestasis; the exact mechanism of action is unclear [145]. Studies on SAME in pregnant women with ICP as a single agent or additive with a dosage of

400–1600 mg per day did not demonstrate clinical superiority to treatment with UDCA alone [131, 146–148].

RECOMMENDATION BY THE WORKING GROUP ON OBSTETRICS AND PRENATAL MEDICINE

At this stage, SAME cannot be recommended in the treatment of ICP.

Dexamethasone

Three observational studies found improvement in symptoms and laboratory parameters with dexamethasone in the treatment of ICP [149–151]. In a prospective randomised trial comparing oral dexamethasone dosed at 10–12 mg/d with UDCA, no therapeutic benefit was seen [128]. In addition, there are considerable concerns about long-term effects in the child with repeated high doses [152].

RECOMMENDATION BY THE WORKING GROUP ON OBSTETRICS AND PRENATAL MEDICINE

Treatment for ICP should not include systemic dexamethasone.

Antihistamines

The use of antihistamines in ICP has not been tested in clinical trials but appears to provide symptomatic relief of pruritus – the extent to which a sedative side effect has any effect in this regard is unknown [126].

Tremors and diarrhoea have been observed in the neonates with long-term administration of some first-generation H1 antagonists (chlorpheniramine, diphenhydramine, hydroxyzine). These side effects have not yet been reported with the agents clemastine (1st generation) and cetirizine (2nd generation) more commonly administered in Germany [153].

RECOMMENDATION BY THE WORKING GROUP ON OBSTETRICS AND PRENATAL MEDICINE

Systemic use of antihistamines in the relief of pruritus may be considered.

Other treatment approaches

In severe refractory pruritus, endoscopic placement of a nasobiliary tube, MARS (Molecular Adsorbent Recirculating System) therapy or plasmapheresis can provide short-term and effective relief of itching [154]. Due to inadequate studies, there is no evidence of efficacy for other treatment options such as UV light, herbal remedies and phenobarbital.

RECOMMENDATION BY THE WORKING GROUP ON OBSTETRICS AND PRENATAL MEDICINE

In rare severe individual cases with marked maternal symptoms, invasive procedures may be useful to prolong the pregnancy after standard therapy aiming at symptom improvement has been exhausted.

Delivery Management

Delivery timing

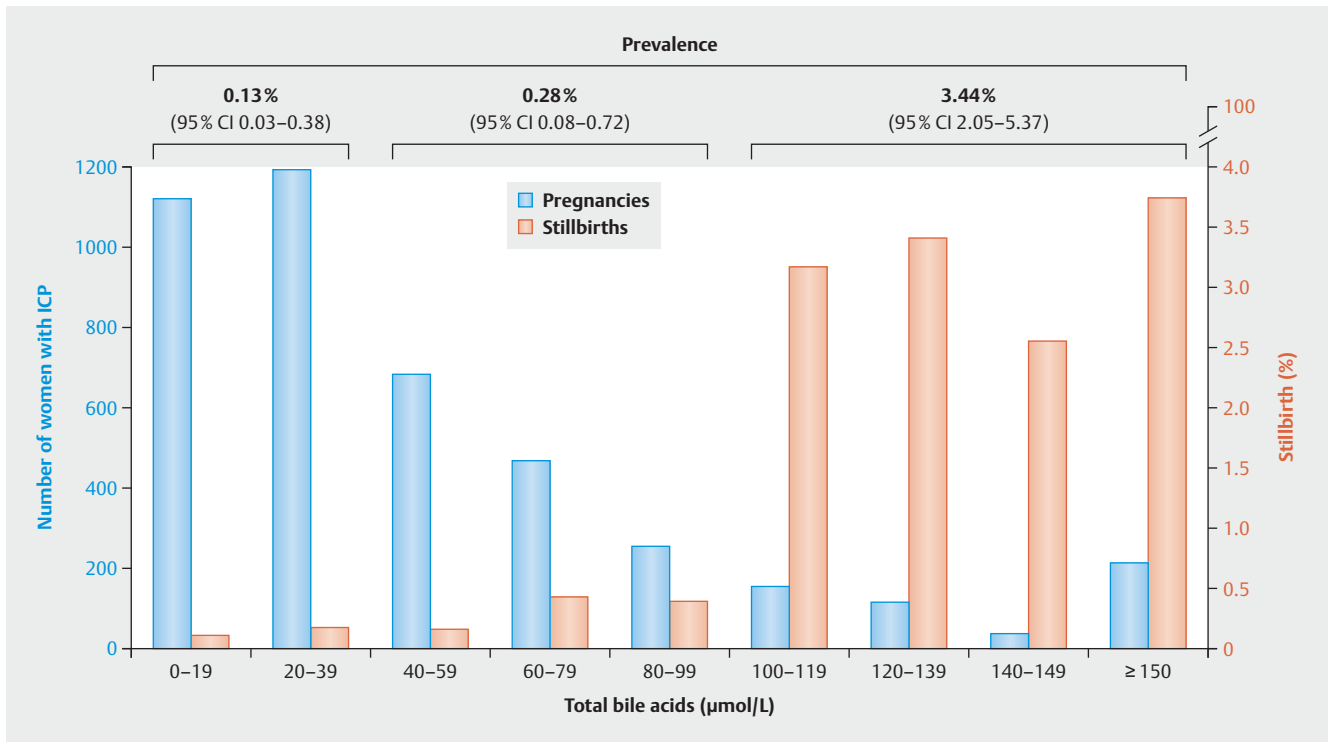
When deciding on the time of delivery, it is important to weigh the risk of IUFT against iatrogenic prematurity with its consequences for the neonate [155, 156]. The bile acid level plays a decisive role as a predictive marker for stillbirth and neonatal complications. In trials its cut-off level ranges from $>40 \mu\text{mol/L}$ to $\geq 100 \mu\text{mol/L}$ [68, 74–76]. In the trial with the highest evidence level by Ovadia et al. in 5269 women with ICP, the rate of stillbirth in bile acid levels $\geq 100 \mu\text{mol/L}$ increases significantly from 34 + 0 weeks of gestation to a prevalence of 3.44%, which is a more than 30-fold increase in the risk compared with the $<40 \mu\text{mol/L}$ group (HR 30.5; 95% CI 8.83–105.3) ▶ **Figs. 2 and 3**. In contrast, the risk of stillbirth for bile acid levels of 40–99 $\mu\text{mol/L}$ and $<40 \mu\text{mol/L}$ does not differ significantly compared to healthy pregnant women and has a prevalence of 0.28% and 0.13%, respectively [67, 68].

Prospective randomised clinical trials on the issue of optimal time of delivery in ICP are lacking. In a retrospective British study, Williamson et al. found 23 (7%) IUFTs among the 352 patients analysed. In singleton pregnancies, IUFTs occurred at a median of 38 + 0 weeks of gestation; in the three gemini pregnancies before 37 + 0 weeks of gestation [77].

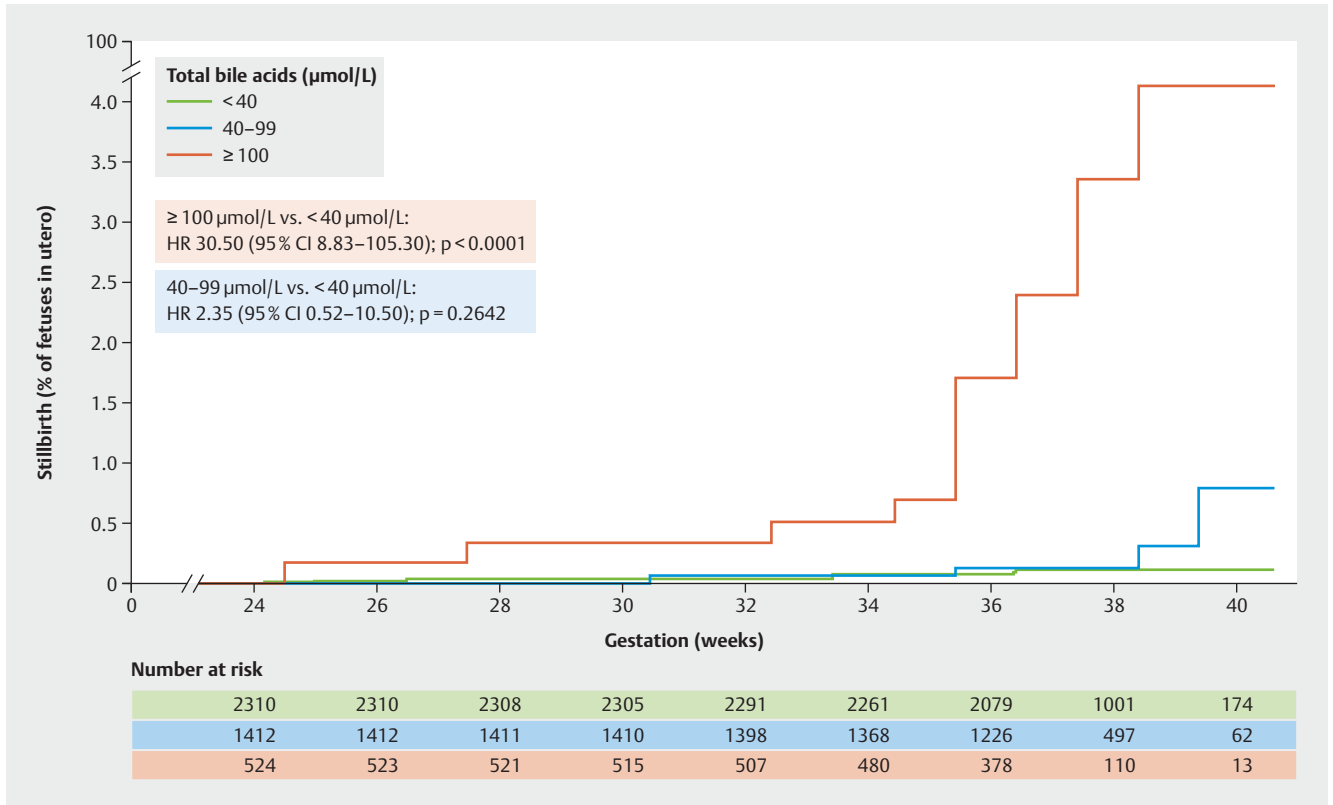
The PITCHES trial compared treatment with UDCA versus placebo and reported three (0.5%) IUFTs among the 604 patients with ICP analysed [127]. Here, the delivery management of the patients followed routine care. Since this trial was conducted in the United Kingdom, it was based on the NICE guideline, which recommends delivery from 37 + 0 weeks of gestation. Thus, the median gestational age at delivery in the PITCHES trial was 38 weeks of gestation, which may have contributed to a reduction in the rate of IUFT. Since in this trial the bile acid levels were only moderately elevated in most patients, this was more of a low-risk ICP population.

STATEMENT BY THE WORKING GROUP ON OBSTETRICS AND PRENATAL MEDICINE

A bile acid level $\geq 100 \mu\text{mol/L}$ is a predictive marker for stillbirth and neonatal complications. The time during pregnancy at which the bile acid levels should be determined is not defined.



► **Fig. 2** Number of singleton pregnancies with ICP (blue columns) and percentage with IUFT (red columns), by bile acid level. IUFT prevalence by bile acid group (<40 µmol/L, 40–99 µmol/L and ≥100 µmol/L) is shown in the graph above (data from [68]).



► **Fig. 3** Kaplan-Meier graph – percentage of foetuses with IUFT between 24 and 40 weeks of gestation in singleton pregnancies with ICP (data from [68]).

STATEMENT BY THE WORKING GROUP ON OBSTETRICS AND PRENATAL MEDICINE

The decision to deliver is based on weighing the risk of intrauterine fetal death against iatrogenic preterm morbidity and mortality.

RECOMMENDATION BY THE WORKING GROUP ON OBSTETRICS AND PRENATAL MEDICINE

Bile acid levels in maternal blood should be part of the decision-making process regarding the best time of delivery. The time of delivery is determined individually, in a shared decision-making process with the expectant mother.

RECOMMENDATION BY THE WORKING GROUP ON OBSTETRICS AND PRENATAL MEDICINE

Analogous to the German AWMF S2k guideline Induction of labour (expert consensus) [157]:

≥ 100 µmol/L:

- induction of labour may be recommended between 34 + 0 and 36 + 6 weeks of gestation.

< 100 µmol/L:

- induction of labour should be recommended at 37 + 0 weeks of gestation.
- induction of labour must be recommended at 38 + 0 weeks of gestation.

Delivery modality

In their retrospective study, Wickström Shemer et al. analysed 25 780 births to determine the risk of emergent caesarean section after active induction management in ICP between 37 + 0 and 39 + 0 weeks of gestation. Of these, 231 women with ICP gave birth during this period. When labour started spontaneously, women with ICP had the same rate of emergent caesarean section (aOR, 1.33; 95% CI 0.60–2.96) and were less likely to undergo emergent caesarean section after induction of labour (aOR, 0.47; 95% CI 0.26–0.86) compared with non-ICP expectant mothers. There was no difference in the risk of fetal asphyxia [158]. Another retrospective case-control study of 64 inductions of labour due to ICP revealed no increased risk of vaginal surgical delivery or caesarean section. Other complication rates, e.g., for postpartum haemorrhage, were comparable to the control group of induced labour without ICP [159].

STATEMENT BY THE WORKING GROUP ON OBSTETRICS AND PRENATAL MEDICINE

Induction of labour for ICP between 37 + 0 and 39 + 0 weeks of gestation is not associated with an increased risk of caesarean section or operative vaginal delivery.

RECOMMENDATION BY THE WORKING GROUP ON OBSTETRICS AND PRENATAL MEDICINE

Choosing the mode of delivery should follow obstetric criteria.

Postpartum Management and Follow-up

The laboratory and clinical changes normalise completely postpartum. In case of persistence beyond a period of 4–8 weeks, the diagnosis of ICP should be questioned.

There is a high rate of recurrence of up to 70% in subsequent pregnancies [47]. Transient recurrent symptoms may also occur in reproductive stimulation treatment; treatment can then take place in the natural or modified natural cycle. In addition, the risk of cholestasis is also increased outside pregnancy. Oestrogen-containing drugs such as contraceptives can cause ICP-like symptoms. With gestagen-only preparations (systemic or IUD), the risk is low [160].

New evidence suggests an increased risk of developing various liver, biliary, pancreatic, metabolic, and immune-mediated disorders. It remains unclear whether pregnancy activates the disease cascade or whether these disorders were already present subclinically before pregnancy [10, 30, 64, 65].

The hazard ratios for subsequent hepatobiliary disease after initial diagnosis of ICP is 2.62 (95% CI 2.47–2.77) with a cumulative annual increase of ~ 1%. In addition, following ICP the risk is highest for the diagnosis of chronic hepatitis (HR 5.96, 95% CI 3.43–10.33), liver fibrosis/cirrhosis (HR 5.11, 95% CI 3.29–10.33), hepatitis C (HR 4.16, 95% CI 3.14–5.51) and cholangitis (HR 4.22, 95% CI 3.13–5.69) [30].

The presence of heterozygous, disease-associated ABCB4 variants favours hepatobiliary sequelae [161]. If genetic testing has detected certain ABCB4 variants, lifelong UDCA administration and annual ultrasound studies (elastography if necessary) and monitoring of laboratory parameters are recommended. Information about the increased incidence of sequelae is mandatory.

STATEMENT BY THE WORKING GROUP ON OBSTETRICS AND PRENATAL MEDICINE

The laboratory and clinical changes normalise completely postpartum. Subsequent pregnancies are at elevated risk of recurrence. Outside of pregnancy, the risk of hepatobiliary disorders is increased. Life expectancy is not affected.

STATEMENT BY THE WORKING GROUP ON OBSTETRICS AND PRENATAL MEDICINE

The administration of oestrogen-containing preparations is based on a risk-benefit analysis. Gestagen-only medications are appropriate for contraception after ICP.

RECOMMENDATION BY THE WORKING GROUP ON OBSTETRICS AND PRENATAL MEDICINE

Women with ICP should be informed about the increased risk of developing sequelae. Liver enzymes, especially the transaminases, should be monitored after 6 weeks at the latest. In the case of persistently elevated transaminase levels, the patient should be seen by a hepatologist. More detailed regular follow-up intervals should be scheduled on an individual basis.

Acknowledgements

Many thanks to all who actively participated in this recommendation.

Conflict of Interest

The authors declare that they have no conflict of interest.

References

- [1] Sasamori Y, Tanaka A, Ayabe T. Liver disease in pregnancy. *Hepatology* 2020; 50: 1015–1023. doi:10.1111/hepr.13540
- [2] Lee RH, Goodwin TM, Greenspoon J et al. The prevalence of intrahepatic cholestasis of pregnancy in a primarily Latina Los Angeles population. *J Perinatol* 2006; 26: 527–532. doi:10.1038/sj.jp.7211545
- [3] Bacq Y, Sapay T, Brechot MC et al. Intrahepatic cholestasis of pregnancy: a French prospective study. *Hepatology* 1997; 26: 358–364. doi:10.1002/hep.510260216
- [4] Bacq Y. Intrahepatic cholestasis of pregnancy. *Clin Liver Dis* 1999; 3: 1–13
- [5] Reyes H, Gonzalez MC, Ribalta J et al. Prevalence of intrahepatic cholestasis of pregnancy in Chile. *Ann Intern Med* 1978; 88: 487–493. doi:10.7326/0003-4819-88-4-487
- [6] Gardiner FW, McCuaig R, Arthur C et al. The prevalence and pregnancy outcomes of intrahepatic cholestasis of pregnancy: A retrospective clinical audit review. *Obstet Med* 2019; 12: 123–128. doi:10.1177/1753495x18797749
- [7] Smith DD, Rood KM. Intrahepatic Cholestasis of Pregnancy. *Clin Obstet Gynecol* 2020; 63: 134–151. doi:10.1097/GRF.0000000000000495
- [8] Wikström Shemer E, Marschall HU, Ludvigsson JF et al. Intrahepatic cholestasis of pregnancy and associated adverse pregnancy and fetal outcomes: a 12-year population-based cohort study. *BJOG* 2013; 120: 717–723. doi:10.1111/1471-0528.12174
- [9] Rissanen AS, Jernman RM, Gissler M et al. Maternal complications in twin pregnancies in Finland during 1987–2014: a retrospective study. *BMC Pregnancy Childbirth* 2019; 19: 337. doi:10.1186/s12884-019-2498-x
- [10] Ropponen A, Sund R, Riikonen S et al. Intrahepatic cholestasis of pregnancy as an indicator of liver and biliary diseases: a population-based study. *Hepatology* 2006; 43: 723–728. doi:10.1002/hep.21111
- [11] Turunen K, Molsa A, Helander K et al. Health history after intrahepatic cholestasis of pregnancy. *Acta Obstet Gynecol Scand* 2012; 91: 679–685. doi:10.1111/j.1600-0412.2012.01403.x
- [12] Lammert F, Marschall HU, Matern S. Intrahepatic Cholestasis of Pregnancy. *Curr Treat Options Gastroenterol* 2003; 6: 123–132. doi:10.1007/s11938-003-0013-x
- [13] Dixon PH, Williamson C. The pathophysiology of intrahepatic cholestasis of pregnancy. *Clin Res Hepatol Gastroenterol* 2016; 40: 141–153. doi:10.1016/j.clinre.2015.12.008
- [14] Pecks U, Mohaupt MG, Hütten MC et al. Cholesterol acceptor capacity is preserved by different mechanisms in preterm and term fetuses. *Biochim Biophys Acta* 2014; 1841: 251–258. doi:10.1016/j.bbali.2013.11.008
- [15] Zollner G, Marschall HU, Wagner M et al. Role of nuclear receptors in the adaptive response to bile acids and cholestasis: pathogenetic and therapeutic considerations. *Mol Pharm* 2006; 3: 231–251. doi:10.1021/mp060010s
- [16] Di Guida F, Pirozzi C, Magliocca S et al. Galactosylated Pro-Drug of Ursodeoxycholic Acid: Design, Synthesis, Characterization, and Pharmacological Effects in a Rat Model of Estrogen-Induced Cholestasis. *Mol Pharm* 2018; 15: 21–30. doi:10.1021/acs.molpharmaceut.7b00626
- [17] Dixon PH, Weerasekera N, Linton KJ et al. Heterozygous MDR3 missense mutation associated with intrahepatic cholestasis of pregnancy: evidence for a defect in protein trafficking. *Hum Mol Genet* 2000; 9: 1209–1217. doi:10.1093/hmg/9.8.1209
- [18] Gendrot C, Bacq Y, Brechot MC et al. A second heterozygous MDR3 non-sense mutation associated with intrahepatic cholestasis of pregnancy. *J Med Genet* 2003; 40: e32. doi:10.1136/jmg.40.3.e32
- [19] Floreani A, Carderi I, Paternoster D et al. Intrahepatic cholestasis of pregnancy: three novel MDR3 gene mutations. *Aliment Pharmacol Ther* 2006; 23: 1649–1653. doi:10.1111/j.1365-2036.2006.02869.x
- [20] Painter JN, Savander M, Ropponen A et al. Sequence variation in the ATP8B1 gene and intrahepatic cholestasis of pregnancy. *Eur J Hum Genet* 2005; 13: 435–439. doi:10.1038/sj.ejhg.5201355
- [21] Abu-Hayyeh S, Ovadia C, Lieu T et al. Prognostic and mechanistic potential of progesterone sulfates in intrahepatic cholestasis of pregnancy and pruritus gravidarum. *Hepatology* 2016; 63: 1287–1298. doi:10.1002/hep.28265
- [22] Pecks U, Rath W, Kleine-Eggebrecht N et al. Maternal Serum Lipid, Estradiol, and Progesterone Levels in Pregnancy, and the Impact of Placental and Hepatic Pathologies. *Geburtshilfe Frauenheilkd* 2016; 76: 799–808. doi:10.1055/s-0042-107078
- [23] Aleksunes LM, Yeager RL, Wen X et al. Repression of hepatobiliary transporters and differential regulation of classic and alternative bile acid pathways in mice during pregnancy. *Toxicol Sci* 2012; 130: 257–268. doi:10.1093/toxsci/kfs248
- [24] Padda MS, Sanchez M, Akhtar AJ et al. Drug-induced cholestasis. *Hepatology* 2011; 53: 1377–1387. doi:10.1002/hep.24229
- [25] Geier A, Wagner M, Dietrich CG et al. Principles of hepatic organic anion transporter regulation during cholestasis, inflammation and liver regeneration. *Biochim Biophys Acta* 2007; 1773: 283–308. doi:10.1016/j.bbamcr.2006.04.014
- [26] Tribe RM, Dann AT, Kenyon AP et al. Longitudinal profiles of 15 serum bile acids in patients with intrahepatic cholestasis of pregnancy. *Am J Gastroenterol* 2010; 105: 585–595. doi:10.1038/ajg.2009.633
- [27] Gorelik J, Shevchuk A, de Swiet M et al. Comparison of the arrhythmogenic effects of tauro- and glycoconjugates of cholic acid in an in vitro study of rat cardiomyocytes. *BJOG* 2004; 111: 867–870. doi:10.1111/j.1471-0528.2004.00166.x
- [28] Wijampreecha K, Thongprayoon C, Sanguankeo A et al. Hepatitis C infection and intrahepatic cholestasis of pregnancy: A systematic review and meta-analysis. *Clin Res Hepatol Gastroenterol* 2017; 41: 39–45. doi:10.1016/j.clinre.2016.07.004
- [29] Jiang R, Wang T, Yao Y et al. Hepatitis B infection and intrahepatic cholestasis of pregnancy: A systematic review and meta-analysis. *Medicine (Baltimore)* 2020; 99: e21416. doi:10.1097/MD.00000000000021416
- [30] Marschall HU, Wikström Shemer E, Ludvigsson JF et al. Intrahepatic cholestasis of pregnancy and associated hepatobiliary disease: a population-based cohort study. *Hepatology* 2013; 58: 1385–1391
- [31] Gonzalez MC, Reyes H, Arrese M et al. Intrahepatic cholestasis of pregnancy in twin pregnancies. *J Hepatol* 1989; 9: 84–90. doi:10.1016/0168-8278(89)90079-2

- [32] Mutlu MF, Aslan K, Guler I et al. Two cases of first onset intrahepatic cholestasis of pregnancy associated with moderate ovarian hyperstimulation syndrome after IVF treatment and review of the literature. *J Obstet Gynaecol* 2017; 37: 547–549. doi:10.1080/01443615.2017.1286302
- [33] Wanggren K, Sparre LS, Wrambsby H. Severe jaundice in early IVF pregnancy. *Eur J Obstet Gynecol Reprod Biol* 2004; 112: 228–229. doi:10.1016/s0301-2115(03)00339-7
- [34] Geenes V, Chappell LC, Seed PT et al. Association of severe intrahepatic cholestasis of pregnancy with adverse pregnancy outcomes: a prospective population-based case-control study. *Hepatology* 2014; 59: 1482–1491. doi:10.1002/hep.26617
- [35] Liu X, Landon MB, Chen Y et al. Perinatal outcomes with intrahepatic cholestasis of pregnancy in twin pregnancies. *J Matern Fetal Neonatal Med* 2016; 29: 2176–2181. doi:10.3109/14767058.2015.1079612
- [36] Zipori Y, Bachar G, Farago N et al. Vaginal progesterone treatment for the prevention of preterm birth and intrahepatic cholestasis of pregnancy: A case-control study. *Eur J Obstet Gynecol Reprod Biol* 2020; 253: 117–120. doi:10.1016/j.ejogrb.2020.08.043
- [37] Jie Z, Yiling D, Ling Y. Association of assisted reproductive technology with adverse pregnancy outcomes. *Iran J Reprod Med* 2015; 13: 169
- [38] Geenes V, Williamson C. Intrahepatic cholestasis of pregnancy. *World J Gastroenterol* 2009; 15: 2049–2066. doi:10.3748/wjg.15.2049
- [39] Floreani A, Gervasi MT. New Insights on Intrahepatic Cholestasis of Pregnancy. *Clin Liver Dis* 2016; 20: 177–189. doi:10.1016/j.cld.2015.08.010
- [40] Parizek A, Duskova M, Vitek L et al. The role of steroid hormones in the development of intrahepatic cholestasis of pregnancy. *Physiol Res* 2015; 64: S203–S209. doi:10.33549/physiolres.933117
- [41] Dixon PH, Sambrotta M, Chambers J et al. An expanded role for heterozygous mutations of ABCB4, ABCB11, ATP8B1, ABCG2 and TJP2 in intrahepatic cholestasis of pregnancy. *Sci Rep* 2017; 7: 11823. doi:10.1038/s41598-017-11626-x
- [42] Droge C, Haussinger D, Keitel V. Genetic variants in adult liver diseases. *Z Gastroenterol* 2015; 53: 1436–1446. doi:10.1055/s-0035-1566903
- [43] Koivurova S, Hartikainen A-L, Karinen L et al. The course of pregnancy and delivery and the use of maternal healthcare services after standard IVF in Northern Finland 1990–1995. *Hum Reprod* 2002; 17: 2897–2903
- [44] Wikstrom Shemer E, Marschall HU. Decreased 1,25-dihydroxy vitamin D levels in women with intrahepatic cholestasis of pregnancy. *Acta Obstet Gynecol Scand* 2010; 89: 1420–1423. doi:10.3109/00016349.2010.515665
- [45] Kauppila A, Korpela H, Makila UM et al. Low serum selenium concentration and glutathione peroxidase activity in intrahepatic cholestasis of pregnancy. *Br Med J (Clin Res Ed)* 1987; 294: 150–152. doi:10.1136/bmj.294.6565.150
- [46] Berg B, Helm G, Petersohn L et al. Cholestasis of pregnancy: clinical and laboratory studies. *Acta Obstet Gynecol Scand* 1986; 65: 107–113
- [47] Lammert F, Marschall HU, Glantz A et al. Intrahepatic cholestasis of pregnancy: molecular pathogenesis, diagnosis and management. *J Hepatol* 2000; 33: 1012–1021. doi:10.1016/s0168-8278(00)80139-7
- [48] Kremer AE, Bolier R, Dixon PH et al. Autotaxin activity has a high accuracy to diagnose intrahepatic cholestasis of pregnancy. *J Hepatol* 2015; 62: 897–904. doi:10.1016/j.jhep.2014.10.041
- [49] Ghent CN, Bloomer JR, Klatskin G. Elevations in skin tissue levels of bile acids in human cholestasis: relation to serum levels and to pruritus. *Gastroenterology* 1977; 73: 1125–1130
- [50] Arafa A, Dong JY. Association between intrahepatic cholestasis of pregnancy and risk of gestational diabetes and preeclampsia: a systematic review and meta-analysis. *Hypertens Pregnancy* 2020; 39: 354–360. doi:10.1080/10641955.2020.1758939
- [51] Majewska A, Godek B, Bomba-Opon D et al. Association between intrahepatic cholestasis in pregnancy and gestational diabetes mellitus. A retrospective analysis. *Ginekol Pol* 2019; 90: 458–463. doi:10.5603/GP.2019.0079
- [52] Martineau M, Raker C, Powrie R et al. Intrahepatic cholestasis of pregnancy is associated with an increased risk of gestational diabetes. *Eur J Obstet Gynecol Reprod Biol* 2014; 176: 80–85. doi:10.1016/j.ejogrb.2013.12.037
- [53] Raz Y, Lavie A, Vered Y et al. Severe intrahepatic cholestasis of pregnancy is a risk factor for preeclampsia in singleton and twin pregnancies. *Am J Obstet Gynecol* 2015; 213: 395.e1–395.e8. doi:10.1016/j.ajog.2015.05.011
- [54] Vanjak D, Moreau R, Roche-Sicot J et al. Intrahepatic cholestasis of pregnancy and acute fatty liver of pregnancy. An unusual but favorable association? *Gastroenterology* 1991; 100: 1123–1125. doi:10.1016/0016-5085(91)90292-s
- [55] Jiang ZH, Qiu ZD, Liu WW et al. Intrahepatic cholestasis of pregnancy and its complications. Analysis of 100 cases in Chongqing area. *Chin Med J (Engl)* 1986; 99: 957–960
- [56] Kenyon AP, Piercy CN, Girling J et al. Obstetric cholestasis, outcome with active management: a series of 70 cases. *BJOG* 2002; 109: 282–288
- [57] AP Kenyon, Girling JC; Royal College of Obstetricians and Gynaecologists. *Obstetric Cholestasis (Green-top Guideline No. 43)*. 2011. Accessed December 14, 2020 at: <https://www.rcog.org.uk/en/guidelines-research-services/guidelines/gtg43/>
- [58] Maldonado M, Alhousseini A, Awadalla M et al. Intrahepatic Cholestasis of Pregnancy Leading to Severe Vitamin K Deficiency and Coagulopathy. *Case Rep Obstet Gynecol* 2017; 2017: 5646247. doi:10.1155/2017/5646247
- [59] Furrer R, Winter K, Schäffer L et al. Postpartum blood loss in women treated for intrahepatic cholestasis of pregnancy. *Obstet Gynecol* 2016; 128: 1048–1052
- [60] Biberoglu EH, Kirbas A, Kirbas O et al. Prediction of cardiovascular risk by electrocardiographic changes in women with intrahepatic cholestasis of pregnancy. *J Matern Fetal Neonatal Med* 2015; 28: 2239–2243
- [61] Rainer PP, Primessnig U, Harenkamp S et al. Bile acids induce arrhythmias in human atrial myocardium—implications for altered serum bile acid composition in patients with atrial fibrillation. *Heart* 2013; 99: 1685–1692
- [62] Desai MS, Penny DJ. Bile acids induce arrhythmias: old metabolite, new tricks. *Heart* 2013; 99: 1629–1630. doi:10.1136/heartjnl-2013-304546
- [63] Vasavan T, Ferraro E, Ibrahim E et al. Heart and bile acids – Clinical consequences of altered bile acid metabolism. *Biochim Biophys Acta Mol Basis Dis* 2018; 1864 (4 Pt B): 1345–1355. doi:10.1016/j.bbdis.2017.12.039
- [64] Keitel V, Droge C, Stepanow S et al. Intrahepatic cholestasis of pregnancy (ICP): case report and review of the literature. *Z Gastroenterol* 2016; 54: 1327–1333. doi:10.1055/s-0042-118388
- [65] Shemer EAW, Stephansson O, Thuresson M et al. Intrahepatic cholestasis of pregnancy and cancer, immune-mediated and cardiovascular diseases: A population-based cohort study. *J Hepatol* 2015; 63: 456–461
- [66] Geenes V, Lovgren-Sandblom A, Benthin L et al. The reversed fetomaternal bile acid gradient in intrahepatic cholestasis of pregnancy is corrected by ursodeoxycholic acid. *PLoS One* 2014; 9: e83828. doi:10.1371/journal.pone.0083828
- [67] Blencowe H, Cousens S, Jassir FB et al. National, regional, and worldwide estimates of stillbirth rates in 2015, with trends from 2000: a systematic analysis. *Lancet Glob Health* 2016; 4: e98–e108
- [68] Ovadia C, Seed PT, Sklavounos A et al. Association of adverse perinatal outcomes of intrahepatic cholestasis of pregnancy with biochemical markers: results of aggregate and individual patient data meta-analyses. *Lancet* 2019; 393: 899–909. doi:10.1016/S0140-6736(18)31877-4
- [69] Williamson C, Gorelik J, Eaton BM et al. The bile acid taurocholate impairs rat cardiomyocyte function: a proposed mechanism for intra-uterine fetal death in obstetric cholestasis. *Clin Sci (Lond)* 2001; 100: 363–369

- [70] Williamson C, Miragoli M, Sheikh Abdul Kadir S et al. Bile acid signaling in fetal tissues: implications for intrahepatic cholestasis of pregnancy. *Dig Dis* 2011; 29: 58–61. doi:10.1159/000324130
- [71] Sepulveda WH, Gonzalez C, Cruz MA et al. Vasoconstrictive effect of bile acids on isolated human placental chorionic veins. *Eur J Obstet Gynecol Reprod Biol* 1991; 42: 211–215. doi:10.1016/0028-2243(91)90222-7
- [72] Wikstrom Shemer E, Thorsell M, Ostlund E et al. Stereological assessment of placental morphology in intrahepatic cholestasis of pregnancy. *Placenta* 2012; 33: 914–918. doi:10.1016/j.placenta.2012.08.005
- [73] Geenes VL, Lim YH, Bowman N et al. A placental phenotype for intrahepatic cholestasis of pregnancy. *Placenta* 2011; 32: 1026–1032. doi:10.1016/j.placenta.2011.09.006
- [74] Glantz A, Marschall HU, Mattsson LA. Intrahepatic cholestasis of pregnancy: Relationships between bile acid levels and fetal complication rates. *Hepatology* 2004; 40: 467–474. doi:10.1002/hep.20336
- [75] Brouwers L, Koster MP, Page-Christiaens GC et al. Intrahepatic cholestasis of pregnancy: maternal and fetal outcomes associated with elevated bile acid levels. *Am J Obstet Gynecol* 2015; 212: 100.e1–100.e7. doi:10.1016/j.ajog.2014.07.026
- [76] Kawakita T, Parikh LI, Ramsey PS et al. Predictors of adverse neonatal outcomes in intrahepatic cholestasis of pregnancy. *Am J Obstet Gynecol* 2015; 213: 570.e1–570.e8. doi:10.1016/j.ajog.2015.06.021
- [77] Williamson C, Hems LM, Gouls DG et al. Clinical outcome in a series of cases of obstetric cholestasis identified via a patient support group. *BJOG* 2004; 111: 676–681. doi:10.1111/j.1471-0528.2004.00167.x
- [78] Puljic A, Kim E, Page J et al. The risk of infant and fetal death by each additional week of expectant management in intrahepatic cholestasis of pregnancy by gestational age. *Am J Obstet Gynecol* 2015; 212: 667.e1–667.e5. doi:10.1016/j.ajog.2015.02.012
- [79] Heinonen S, Kirkinen P. Pregnancy outcome with intrahepatic cholestasis. *Obstet Gynecol* 1999; 94: 189–193. doi:10.1016/s0029-7844(99)00254-9
- [80] Reid R, Ivey KJ, Rencoret RH et al. Fetal complications of obstetric cholestasis. *Br Med J* 1976; 1: 870–872. doi:10.1136/bmj.1.6014.870
- [81] Fisk NM, Storey GN. Fetal outcome in obstetric cholestasis. *Br J Obstet Gynaecol* 1988; 95: 1137–1143. doi:10.1111/j.1471-0528.1988.tb06791.x
- [82] Rioseco AJ, Ivankovic MB, Manzur A et al. Intrahepatic cholestasis of pregnancy: a retrospective case-control study of perinatal outcome. *Am J Obstet Gynecol* 1994; 170: 890–895. doi:10.1016/s0002-9378(94)70304-3
- [83] Roncaglia N, Arreghini A, Locatelli A et al. Obstetric cholestasis: outcome with active management. *Eur J Obstet Gynecol Reprod Biol* 2002; 100: 167–170
- [84] Alsulyman OM, Ouzounian JG, Ames-Castro M et al. Intrahepatic cholestasis of pregnancy: perinatal outcome associated with expectant management. *Am J Obstet Gynecol* 1996; 175: 957–960. doi:10.1016/s0002-9378(96)80031-7
- [85] Herrera CA, Manuck TA, Stoddard GJ et al. Perinatal outcomes associated with intrahepatic cholestasis of pregnancy. *J Matern Fetal Neonatal Med* 2018; 31: 1913–1920. doi:10.1080/14767058.2017.1332036
- [86] Lee RH, Kwok KM, Ingles S et al. Pregnancy outcomes during an era of aggressive management for intrahepatic cholestasis of pregnancy. *Am J Perinatol* 2008; 25: 341–345. doi:10.1055/s-2008-1078756
- [87] Hutton EK, Thorpe J. Consequences of meconium stained amniotic fluid: what does the evidence tell us? *Early Hum Dev* 2014; 90: 333–339. doi:10.1016/j.earlhumdev.2014.04.005
- [88] Dargaville PA, Copnell B, Australian et al. The epidemiology of meconium aspiration syndrome: incidence, risk factors, therapies, and outcome. *Pediatrics* 2006; 117: 1712–1721. doi:10.1542/peds.2005-2215
- [89] Walsh MC, Fanaroff JM. Meconium stained fluid: approach to the mother and the baby. *Clin Perinatol* 2007; 34: 653–665, viii. doi:10.1016/j.clp.2007.10.005
- [90] Ovadia C, Chappell LC, Williamson C. Intrahepatic cholestasis: suggested future investigations – Authors’ reply. *Lancet* 2019; 394: e18. doi:10.1016/s0140-6736(19)31389-3
- [91] Arthuis C, Diguisto C, Lorphelin H et al. Perinatal outcomes of intrahepatic cholestasis during pregnancy: An 8-year case-control study. *PLoS One* 2020; 15: e0228213. doi:10.1371/journal.pone.0228213
- [92] Porembka DT, Kier A, Sehlhorst S et al. The pathophysiologic changes following bile aspiration in a porcine lung model. *Chest* 1993; 104: 919–924
- [93] Kaneko T, Sato T, Katsuya H et al. Surfactant therapy for pulmonary edema due to intratracheally injected bile acid. *Crit Care Med* 1990; 18: 77–83
- [94] Zecca E, De Luca D, Marras M et al. Intrahepatic cholestasis of pregnancy and neonatal respiratory distress syndrome. *Pediatrics* 2006; 117: 1669–1672
- [95] Bacq Y, Sentilhes L. Intrahepatic cholestasis of pregnancy: Diagnosis and management. *Clin Liver Dis (Hoboken)* 2014; 4: 58–61. doi:10.1002/cld.398
- [96] Hubschmann AG, Orzechowski KM, Berghella V. Severe First Trimester Recurrent Intrahepatic Cholestasis of Pregnancy: A Case Report and Literature Review. *AJP Rep* 2016; 6: e38–e41. doi:10.1055/s-0035-1565922
- [97] Ikoma A, Steinhoff M, Stander S et al. The neurobiology of itch. *Nat Rev Neurosci* 2006; 7: 535–547. doi:10.1038/nrn1950
- [98] Szczęch J, Wiatrowski A, Hirlin L et al. Prevalence and Relevance of Pruritus in Pregnancy. *Biomed Res Int* 2017; 2017: 4238139. doi:10.1155/2017/4238139
- [99] Ambros-Rudolph CM, Sticherling M. [Specific dermatoses of pregnancy]. *Hautarzt* 2017; 68: 87–94. doi:10.1007/s00105-016-3922-z
- [100] Williamson C, Geenes V. Intrahepatic cholestasis of pregnancy. *Obstet Gynecol* 2014; 124: 120–133. doi:10.1097/AOG.0000000000000346
- [101] Reyes H. The spectrum of liver and gastrointestinal disease seen in cholestasis of pregnancy. *Gastroenterol Clin North Am* 1992; 21: 905–921
- [102] Kondrackiene J, Kupcinskas L. Intrahepatic cholestasis of pregnancy-current achievements and unsolved problems. *World J Gastroenterol* 2008; 14: 5781–5788. doi:10.3748/wjg.14.5781
- [103] Reyes H. Review: intrahepatic cholestasis. A puzzling disorder of pregnancy. *J Gastroenterol Hepatol* 1997; 12: 211–216. doi:10.1111/j.1440-1746.1997.tb00410.x
- [104] Bicocca MJ, Sperling JD, Chauhan SP. Intrahepatic cholestasis of pregnancy: Review of six national and regional guidelines. *Eur J Obstet Gynecol Reprod Biol* 2018; 231: 180–187. doi:10.1016/j.ejogrb.2018.10.041
- [105] Adams A, Jacobs K, Vogel RI et al. Bile acid determination after standardized glucose load in pregnant women. *AJP reports* 2015; 5: e168
- [106] Egan N, Bartels A, Khashan A et al. Reference standard for serum bile acids in pregnancy. *BJOG* 2012; 119: 493–498
- [107] Walker IA, Nelson-Piercy C, Williamson C. Role of bile acid measurement in pregnancy. *Ann Clin Biochem* 2002; 39: 105–113. doi:10.1258/0004563021901856
- [108] Guszczynska-Losy M, Wirstlein PK, Wender-Ozegowska E et al. Evaluation of predictive value of biochemical markers for adverse obstetric outcomes in pregnancies complicated by cholestasis. *Ginekol Pol* 2020; 91: 269–276. doi:10.5603/gp.2020.0051
- [109] Shaw D, Frohlich J, Wittmann BA et al. A prospective study of 18 patients with cholestasis of pregnancy. *Am J Obstet Gynecol* 1982; 142: 621–625. doi:10.1016/s0002-9378(16)32430-9
- [110] Berg B, Helm G, Petersohn L et al. Cholestasis of pregnancy. Clinical and laboratory studies. *Acta Obstet Gynecol Scand* 1986; 65: 107–113. doi:10.3109/00016348609158363

- [111] Fisk NM, Bye WB, Storey GN. Maternal features of obstetric cholestasis: 20 years experience at King George V Hospital. *Aust N Z J Obstet Gynaecol* 1988; 28: 172–176. doi:10.1111/j.1479-828x.1988.tb01657.x
- [112] Heikkinen J. Serum bile acids in the early diagnosis of intrahepatic cholestasis of pregnancy. *Obstet Gynecol* 1983; 61: 581–587
- [113] Laatikainen T, Ikonen E. Serum bile acids in cholestasis of pregnancy. *Obstet Gynecol* 1977; 50: 313–318
- [114] Milkiewicz P, Gallagher R, Chambers J et al. Obstetric cholestasis with elevated gamma glutamyl transpeptidase: incidence, presentation and treatment. *J Gastroenterol Hepatol* 2003; 18: 1283–1286. doi:10.1046/j.1440-1746.2003.03171.x
- [115] European Association for the Study of the Liver. EASL Clinical Practice Guidelines: management of cholestatic liver diseases. *J Hepatol* 2009; 51: 237–267
- [116] Lammert F. Leber und Schwangerschaft. In: Tannapfel A, Klöppel G, Hrsg. *Pathologie: Leber, Gallenwege und Pankreas*. Berlin, Heidelberg: Springer; 2020: 429–436. doi:10.1007/978-3-642-04557-8_12
- [117] Rath W, Tsikouras P, Stelzl P. HELLP Syndrome or Acute Fatty Liver of Pregnancy: A Differential Diagnostic Challenge: Common Features and Differences. *Geburtshilfe Frauenheilkd* 2020; 80: 499–507. doi:10.1055/a-1091-8630
- [118] Herold G. *Innere Medizin-Ausgabe* 2013. In: Herold G, Hrsg. Köln: 2014: 514–539
- [119] Kainer F. *Facharztwissen Geburtsmedizin*. 3. Aufl. Jena: Urban & Fischer Verlag/Elsevier GmbH; 2016
- [120] Lee RH, Greenberg M, Metz TD et al. Society for Maternal-Fetal Medicine Consult Series #53: Intrahepatic cholestasis of pregnancy: Replaces Consult #13, April 2011. *Am J Obstet Gynecol* 2021; 224: B2–B9. doi:10.1016/j.ajog.2020.11.002
- [121] Toprak V, Kafadar MT. Intrahepatic cholestasis of pregnancy: Is fetoplacental doppler ultrasound useful in the diagnosis and follow-up? *Ann Clin Anal Med* 2020. doi:10.4328/ACAM.20203
- [122] Joutsiniemi T, Ekblad U, Rosén KG et al. Waveform analysis of the fetal ECG in labor in patients with intrahepatic cholestasis of pregnancy. *J Obstet Gynaecol Res* 2019; 45: 306–312. doi:10.1111/jog.13812
- [123] Sanhal CY, Kara O, Yucel A. Can fetal left ventricular modified myocardial performance index predict adverse perinatal outcomes in intrahepatic cholestasis of pregnancy? *J Matern Fetal Neonatal Med* 2017; 30: 911–916. doi:10.1080/14767058.2016.1190824
- [124] Henry A, Welsh AW. Monitoring intrahepatic cholestasis of pregnancy using the fetal myocardial performance index: a cohort study. *Ultrasound Obstet Gynecol* 2015; 46: 571–578. doi:10.1002/uog.14769
- [125] Vasavan T, Williamson C. Chapter 65 – Sex and cardiac electrophysiology: fetal arrhythmia in intrahepatic cholestasis of pregnancy. In: Malik M, ed. *Sex and Cardiac Electrophysiology*. New York: Academic Press; 2020: 727–735. doi:10.1016/B978-0-12-817728-0.00065-6
- [126] Walker KF, Chappell LC, Hague WM et al. Pharmacological interventions for treating intrahepatic cholestasis of pregnancy. *Cochrane Database Syst Rev* 2020; (7): CD000493. doi:10.1002/14651858.CD000493.pub3
- [127] Chappell LC, Bell JL, Smith A et al. Ursodeoxycholic acid versus placebo in women with intrahepatic cholestasis of pregnancy (PITCHES): a randomised controlled trial. *Lancet* 2019; 394: 849–860. doi:10.1016/s0140-6736(19)31270-x
- [128] Glantz A, Marschall HU, Lammert F et al. Intrahepatic cholestasis of pregnancy: a randomized controlled trial comparing dexamethasone and ursodeoxycholic acid. *Hepatology* 2005; 42: 1399–1405. doi:10.1002/hep.20952
- [129] Palma J, Reyes H, Ribalta J et al. Ursodeoxycholic acid in the treatment of cholestasis of pregnancy: a randomized, double-blind study controlled with placebo. *J Hepatol* 1997; 27: 1022–1028. doi:10.1016/s0168-8278(97)80146-8
- [130] Joutsiniemi T, Timonen S, Leino R et al. Ursodeoxycholic acid in the treatment of intrahepatic cholestasis of pregnancy: a randomized controlled trial. *Arch Gynecol Obstet* 2014; 289: 541–547. doi:10.1007/s00404-013-2995-5
- [131] Zhang L, Liu XH, Qi HB et al. Ursodeoxycholic acid and S-adenosylmethionine in the treatment of intrahepatic cholestasis of pregnancy: a multi-centered randomized controlled trial. *Eur Rev Med Pharmacol Sci* 2015; 19: 3770–3776
- [132] Fleminger J, Seed PT, Smith A et al. Ursodeoxycholic acid in intrahepatic cholestasis of pregnancy: a secondary analysis of the PITCHES trial. *BJOG* 2020. doi:10.1111/1471-0528.16567
- [133] Haslinger C. The problem of uncertain adherence to study interventions: what can we conclude? *BJOG* 2020. doi:10.1111/1471-0528.16613
- [134] Borges Manna L, Papacleovoulou G, Flaviani F et al. Ursodeoxycholic acid improves fetoplacental and offspring metabolic outcomes in hypercholanemic pregnancy. *Sci Rep* 2020; 10: 10361. doi:10.1038/s41598-020-67301-1
- [135] Fachinformation. Ursofalk® 250 mg Kapseln. 2018. Accessed December 14, 2020 at: <https://www.fachinfo.de/pdf/002220>
- [136] Loto OM, Awowole I. Tuberculosis in pregnancy: a review. *J Pregnancy* 2012; 2012: 379271. doi:10.1155/2012/379271
- [137] Marschall HU, Wagner M, Zollner G et al. Complementary stimulation of hepatobiliary transport and detoxification systems by rifampicin and ursodeoxycholic acid in humans. *Gastroenterology* 2005; 129: 476–485. doi:10.1016/j.gastro.2005.05.009
- [138] Liu J, Murray AM, Mankus EB et al. Adjuvant Use of Rifampin for Refractory Intrahepatic Cholestasis of Pregnancy. *Obstet Gynecol* 2018; 132: 678–681. doi:10.1097/AOG.0000000000002794
- [139] Geenes V, Chambers J, Khurana R et al. Rifampicin in the treatment of severe intrahepatic cholestasis of pregnancy. *Eur J Obstet Gynecol Reprod Biol* 2015; 189: 59–63. doi:10.1016/j.ejogrb.2015.03.020
- [140] Hague WM, Callaway L, Chambers J et al. A multi-centre, open label, randomised, parallel-group, superiority Trial to compare the efficacy of Ursodeoxycholic acid with Rifampicin in the management of women with severe early onset Intrahepatic Cholestasis of pregnancy: the TURRIFIC randomised trial. *BMC Pregnancy Childbirth* 2021; 21: 51. doi:10.1186/s12884-020-03481-y
- [141] Sadler LC, Lane M, North R. Severe fetal intracranial haemorrhage during treatment with cholestyramine for intrahepatic cholestasis of pregnancy. *Br J Obstet Gynaecol* 1995; 102: 169–170. doi:10.1111/j.1471-0528.1995.tb09077.x
- [142] Kondrackiene J, Beuers U, Kupcinskas L. Efficacy and safety of ursodeoxycholic acid versus cholestyramine in intrahepatic cholestasis of pregnancy. *Gastroenterology* 2005; 129: 894–901. doi:10.1053/j.gastro.2005.06.019
- [143] Boelsterli UA, Rakhit G, Balazs T. Modulation by S-adenosyl-L-methionine of hepatic Na⁺,K⁺-ATPase, membrane fluidity, and bile flow in rats with ethinyl estradiol-induced cholestasis. *Hepatology* 1983; 3: 12–17. doi:10.1002/hep.1840030102
- [144] Cantoni G. The nature of the active methyl donor formed enzymatically from L-methionine and adenosinetriphosphate¹, 2. *J Am Chem Soc* 1952; 74: 2942–2943
- [145] Stramentinoli G, Di Padova C, Gualano M et al. Ethynylestradiol-induced impairment of bile secretion in the rat: protective effects of S-adenosyl-L-methionine and its implication in estrogen metabolism. *Gastroenterology* 1981; 80: 154–158
- [146] Roncaglia N, Locatelli A, Arreghini A et al. A randomised controlled trial of ursodeoxycholic acid and S-adenosyl-L-methionine in the treatment of gestational cholestasis. *BJOG* 2004; 111: 17–21. doi:10.1046/j.1471-0528.2003.00029.x

- [147] Triunfo S, Tomaselli M, Ferraro MI et al. Does mild intrahepatic cholestasis of pregnancy require an aggressive management? Evidence from a prospective observational study focused on adverse perinatal outcomes and pathological placental findings. *J Matern Fetal Neonatal Med* 2020. doi:10.1080/14767058.2020.1714583
- [148] Nicastrì PL, Diaferia A, Tartagni M et al. A randomised placebo-controlled trial of ursodeoxycholic acid and S-adenosylmethionine in the treatment of intrahepatic cholestasis of pregnancy. *Br J Obstet Gynaecol* 1998; 105: 1205–1207. doi:10.1111/j.1471-0528.1998.tb09976.x
- [149] Hirvioja ML, Tuimala R, Vuori J. The treatment of intrahepatic cholestasis of pregnancy by dexamethasone. *Br J Obstet Gynaecol* 1992; 99: 109–111. doi:10.1111/j.1471-0528.1992.tb14465.x
- [150] Diac M, Kenyon A, Nelson-Piercy C et al. Dexamethasone in the treatment of obstetric cholestasis: a case series. *J Obstet Gynaecol* 2006; 26: 110–114. doi:10.1080/01443610500443246
- [151] Kretowicz E, McIntyre HD. Intrahepatic cholestasis of pregnancy, worsening after dexamethasone. *Aust N Z J Obstet Gynaecol* 1994; 34: 211–213. doi:10.1111/j.1479-828x.1994.tb02695.x
- [152] Melamed N, Asztalos E, Murphy K et al. Neurodevelopmental disorders among term infants exposed to antenatal corticosteroids during pregnancy: a population-based study. *BMJ Open* 2019; 9: e031197. doi:10.1136/bmjopen-2019-031197
- [153] embryotox.de. Pharmakovigilanz- und Beratungszentrum für Embryonaltoxikologie. 2020. Accessed December 14, 2020 at: <https://www.embryotox.de/arzneimittel>
- [154] Kremer AE, van Dijk R, Leckie P et al. Serum autotaxin is increased in pruritus of cholestasis, but not of other origin, and responds to therapeutic interventions. *Hepatology* 2012; 56: 1391–1400. doi:10.1002/hep.25748
- [155] Henderson CE, Shah RR, Gottimukkala S et al. Primum non nocere: how active management became modus operandi for intrahepatic cholestasis of pregnancy. *Am J Obstet Gynecol* 2014; 211: 189–196
- [156] Cheng YW, Kaimal AJ, Bruckner TA et al. Perinatal morbidity associated with late preterm deliveries compared with deliveries between 37 and 40 weeks of gestation. *BJOG* 2011; 118: 1446–1454
- [157] Kehl S, Abou-Dakn M, Hösl I et al. Induction of labour. Guideline of the German Society of Gynecology and Obstetrics (S2k, AWMF Registry No. 015–088, December 2020). 2020. Accessed December 22, 2020 at: https://www.awmf.org/uploads/tx_szleitlinien/015-088ladd_S2k_Geburtseinleitung_2021-04.pdf
- [158] Wikstrom Shemer EA, Thorsell M, Marschall HU et al. Risks of emergency cesarean section and fetal asphyxia after induction of labor in intrahepatic cholestasis of pregnancy: a hospital-based retrospective cohort study. *Sex Reprod Healthc* 2013; 4: 17–22. doi:10.1016/j.srhc.2012.11.005
- [159] Webster JR, Chappell L, Cheng F et al. Operative delivery rates following induction of labour for obstetric cholestasis. *Obstet Med* 2011; 4: 66–69. doi:10.1258/om.2011.110080
- [160] Curtis KM, Tepper NK, Jatlaoui TC et al. US medical eligibility criteria for contraceptive use, 2016. *MMWR Recomm Rep* 2016; 65: 1–103
- [161] Gudbjartsson DF, Helgason H, Gudjonsson SA et al. Large-scale whole-genome sequencing of the Icelandic population. *Nat Genet* 2015; 47: 435–444. doi:10.1038/ng.3247