

Reference Ranges for Vermis Biometry on Prenatal Ultrasound: Systematic Review and Meta-Analysis

Referenzbereiche für die Biometrie des Vermis cerebelli im pränatalen Ultraschall: Systematischer Überblick und Metaanalyse

Authors

Joshua I Rosenbloom^{1, 2} , Lauren H. Yaeger³, Shay Porat¹

Affiliations

- 1 Obstetrics and Gynecology Hadassah Medical Organization and Faculty of Medicine Hebrew University of Jerusalem Jerusalem, Israel
- 2 Obstetrics and Gynecology, Washington University in Saint Louis School of Medicine, Saint Louis, United States
- 3 Bernard Becker Medical Library, Washington University in Saint Louis School of Medicine, Saint Louis, United States

Key words

obstetrics, neurology, vermis

received 14.07.2020

accepted 15.02.2021

published online 09.04.2021

Bibliography

Ultraschall in Med 2023; 44: e25–e38

DOI 10.1055/a-1408-1998

ISSN 0172-4614

© 2021, Thieme. All rights reserved.

Georg Thieme Verlag KG, Rüdigerstraße 14,
70469 Stuttgart, Germany


Correspondence

Dr. Joshua I Rosenbloom

Obstetrics and Gynecology, Hadassah University Hospital,
Kiryat Hadassah, POB 12000, 91999 Jerusalem, Israel

Tel.: +972/58/630 26 31

rosenbloomj@wustl.edu

 Supplementary material is available under
<https://doi.org/10.1055/a-1408-1998>

ABSTRACT

Purpose To conduct a systematic review and meta-analysis of published nomograms for fetal vermis biometry.

Materials and Methods A structured literature search was conducted to identify studies that reported normal measurements of the fetal vermis. A customized quality assessment tool was used to review the selected articles. Random effects meta-analysis was used to calculate normal ranges for vermian craniocaudal diameter, anteroposterior diameter, and surface area.

Results A total of 21 studies were included for qualitative review and 3 studies were included for quantitative synthesis. The 3 included articles comprised a total of 10910 measurements from gestational ages 17–35 weeks. The quality assessment demonstrated that there was generally poor reporting regarding maternal characteristics and neonatal outcomes. Except for one article with a large sample size, the mean number of fetuses per week of gestational age was 15.9, with the lowest number being 5. There was significant statistical heterogeneity. Non-visualization rates ranged from 0–35.4%. The craniocaudal diameter (reported in 3 articles) increased from a mean of 7.90 mm (95% confidence interval [CI] 7.42, 8.38) at 17 weeks to 21.90 mm (95% CI 20.63, 23.16) at 35 weeks gestation. The anteroposterior diameter (reported in 2 articles) increased from 6.30 mm (95% CI 5.42, 7.18) at 17 weeks to 15.85 (95% CI 15.49, 16.21) at 32 weeks.

Conclusion Reference ranges for vermis biometry across gestation based on meta-analysis of existing references are provided. However, because many of the underlying studies suffered from significant methodological issues, the ranges should be used with caution.

ZUSAMMENFASSUNG

Ziel Durchführung eines systematischen Reviews und Metaanalyse veröffentlichter Nomogramme für die Biometrie des fetalen Vermis cerebelli.

Material und Methoden Eine strukturierte Literaturrecherche wurde durchgeführt, um Studien zu identifizieren, die über normale Messungen des fetalen Vermis berichteten. Ein angepasstes Qualitätsbewertungs-Tool wurde verwendet, um die ausgewählten Artikel zu überprüfen. Eine Metaanalyse mit Random Effects wurde angewandt, um Normalbereiche für den kraniokaudalen Durchmesser des Vermis, den anteroposterioren Durchmesser und die Oberfläche zu berechnen.

Ergebnisse Insgesamt wurden 21 Studien zur qualitativen Überprüfung und 3 Studien zur quantitativen Synthese eingeschlossen. Die 3 eingeschlossenen Artikel umfassten insgesamt 10910 Messungen von der 17.–35. SSW. Die Qualitätsbewertung zeigte, dass es im Allgemeinen eine schlechte Berichterstattung bezüglich mütterlicher Charakteristiken und des neonatalen Outcomes gab. Mit Ausnahme eines Artikels mit großer Stichprobengröße betrug die durchschnitt-

liche Anzahl der Föten pro SSW 15,9, wobei die niedrigste Anzahl 5 betrug. Es gab eine signifikante statistische Heterogenität. Die Raten für Nichtdarstellbarkeit lagen zwischen 0 und 35,4%. Der kraniokaudale Durchmesser (in 3 Artikeln angegeben) stieg von durchschnittlich 7,90 mm (95%-Konfidenzintervall (KI) 7,42–8,38) in der 17. SSW auf 21,90 mm (95%-KI 20,63–23,16) in der 35. SSW. Der anteroposteriore Durchmesser (in 2 Artikeln angegeben) stieg von 6,30 mm (95%-KI

5,42–7,18) in der 17. SSW auf 15,85 mm (95%-KI 15,49–16,21) in der 32. SSW.

Schlussfolgerung Basierend auf einer Metaanalyse bestehender Literatur werden Referenzbereiche für die Biometrie des Vermis nach Schwangerschaftsalter angegeben. Da jedoch viele der zugrunde liegenden Studien unter erheblichen methodischen Problemen litten, sollten diese Bereiche mit Vorsicht angewandt werden.

Introduction

Accurate sonography of the fetal posterior fossa is an essential component of antenatal screening and diagnosis [1]. In particular, identification of an abnormal vermis size is a critical component in the diagnosis of vermis hypoplasia, which can occur as an isolated lesion or accompany Dandy Walker malformation [2] and many other syndromes. However, a number of published nomograms for vermis size as well as techniques for measurement are described in the literature [3–29]. Many of these studies are flawed by small sample size or unclear measurement techniques. This leaves the practicing sonologist in a position of having to choose one of the published references or to compare a measured value to multiple published nomograms. Recently there has been a call for greater uniformity in reporting results of studies in obstetrics and gynecology and improvement in reporting of ultrasound-derived reference ranges [30, 31]. The purpose of the present study was twofold: first, to conduct a systematic review and meta-analysis of published nomograms for fetal vermis biometry, and second, based on the findings of the meta-analysis, to offer suggestions for improving the reporting of studies meant to establish normal parameters in prenatal imaging.

Methods

Study Design

This was a systematic review and meta-analysis conducted according to the Preferred Reporting Items for Systematic Reviews and Meta-Analyses (PRISMA) guidelines [32]. The study was exempt from review by the Institutional Review Board and was registered with PROSPERO.

Sources and Search

A medical librarian (LHY) searched the literature for records including the concepts fetus, ultrasound, measurement, vermis, corpus callosum, and cavum septum pellucidum. Articles pertaining to the corpus callosum and cavum septum pellucidum were gathered for a separate study, and only articles pertaining to the vermis were included in this systematic review and meta-analysis. The librarian created search strategies using a combination of keywords and controlled vocabulary in Ovid Medline 1946-, Embase.com 1947-, Scopus 1823-, Cochrane Central Register of Controlled Trials (CENTRAL), Cochrane Database of Systematic Reviews, and Clinicaltrials.gov 1997-. The search was initially com-

pleted on December 4, 2019 and was updated by re-running the original searches from database conception to June 15, 2020. Fully reproducible search strategies for each database can be found in the Appendix.

Inclusion Criteria

For the initial search, all published articles in any language that provided values for any of four vermian dimensions (craniocaudal diameter [CCD], anteroposterior diameter [APD], surface area [SA], or perimeter/circumference [P]) obtained by prenatal ultrasound in normal low-risk fetuses were considered eligible for further review. Ultrasound techniques including 3D, 2D, transvaginal, and transabdominal imaging were included. Articles that dealt only with magnetic resonance imaging (MRI) were excluded although those that included both ultrasound and MRI-based imaging were considered. All such articles were included for qualitative review. For quantitative synthesis, only articles that included numerical data (means and standard deviations or medians and quartiles) stratified by gestational age in weekly increments were included. Additionally, after comparison of measurement techniques, we selected the articles that used the most common measurement techniques in 2D for quantitative synthesis, in order to include as much of the published data as possible.

Review Outcomes

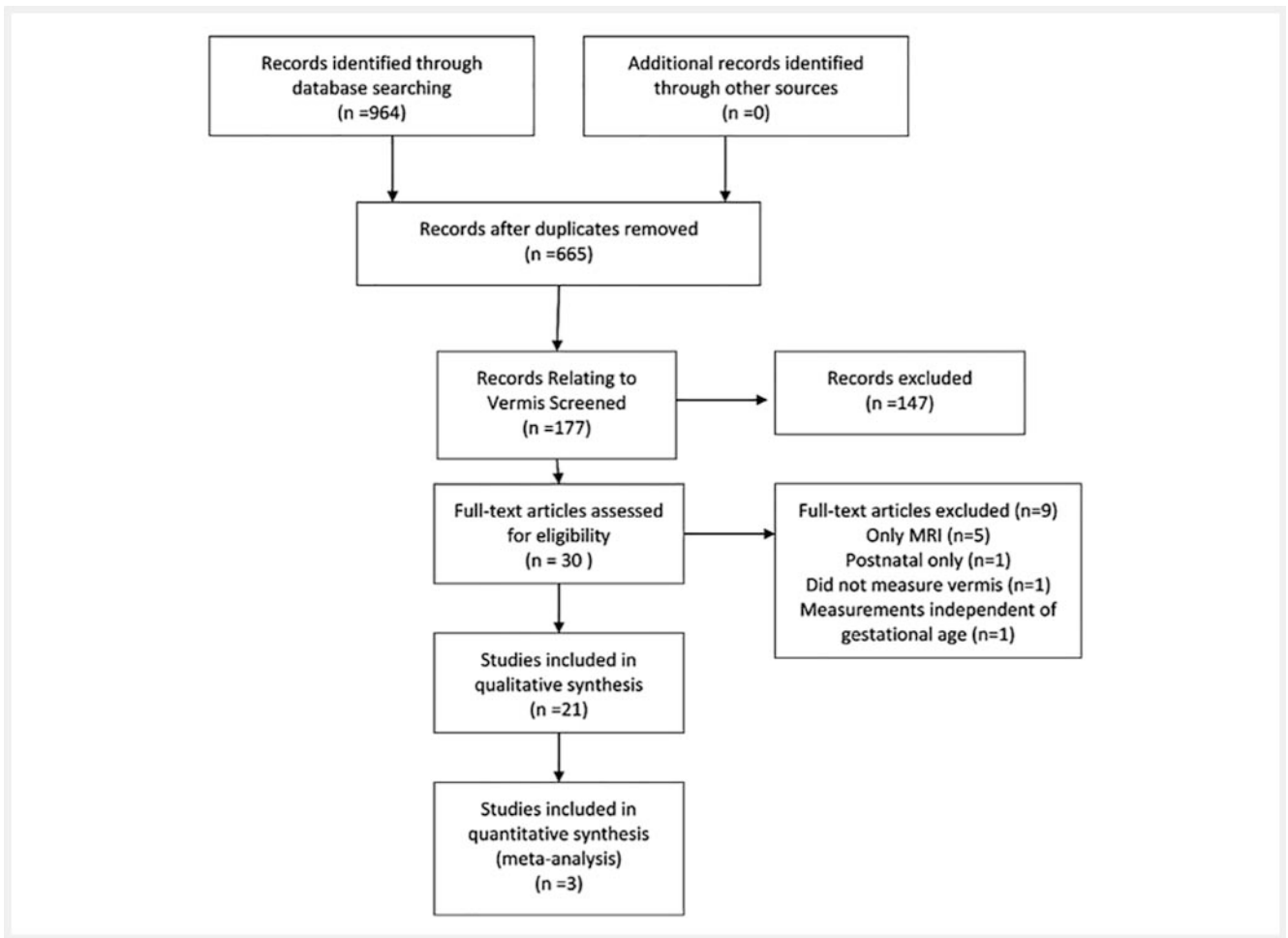
The outcomes that were considered included CCD, APD, SA, and P as well as the rate of non-visualization or inability to measure the vermian anatomy.

Study Selection and Data Extraction

All retrieved titles and abstracts were reviewed by two investigators (JIR and SP) for potential inclusion. Any disagreements were resolved by consensus. Then articles selected for full-text review were also reviewed by the two investigators against the inclusion and exclusion criteria. Data from included articles were extracted into a database. We also abstracted information about measurement techniques and reporting methods for qualitative synthesis and quality assessment.

Quality Assessment

The quality of each study was assessed by two investigators (JIR and SP). Because studies meant to establish a normal range are different from studies that evaluate an intervention or diagnostic accuracy, we created a specific quality assessment tool to



► Fig. 1 PRISMA flowchart.

evaluate the articles, as has been done elsewhere [31, 33, 34]. Domains included how a “normal” population of mothers and fetuses was defined, quality of measurements, and how the results were reported.

Data Analysis

Data published as median, first, and third quartiles were transformed into estimated mean and standard deviation using standard methodology [35]. Meta-analysis was performed in Stata 14 (StataCorp, College Station, TX, USA). DerSimonian-Laird random effects models were used to estimate pooled means and 95% confidence intervals for the different dimensions of vermis biometry by gestational week [36]. Heterogeneity was assessed using the I^2 and Cochran’s Q [37]. Random effects models were used regardless of the absence of statistical heterogeneity because this approach yields a more conservative estimate and because heterogeneity tests may have low power [38]. Only 2D imaging techniques were considered for the meta-analysis. Results are presented in tabular form as well as forest plots. We also present nomograms from the meta-analysis.

Results

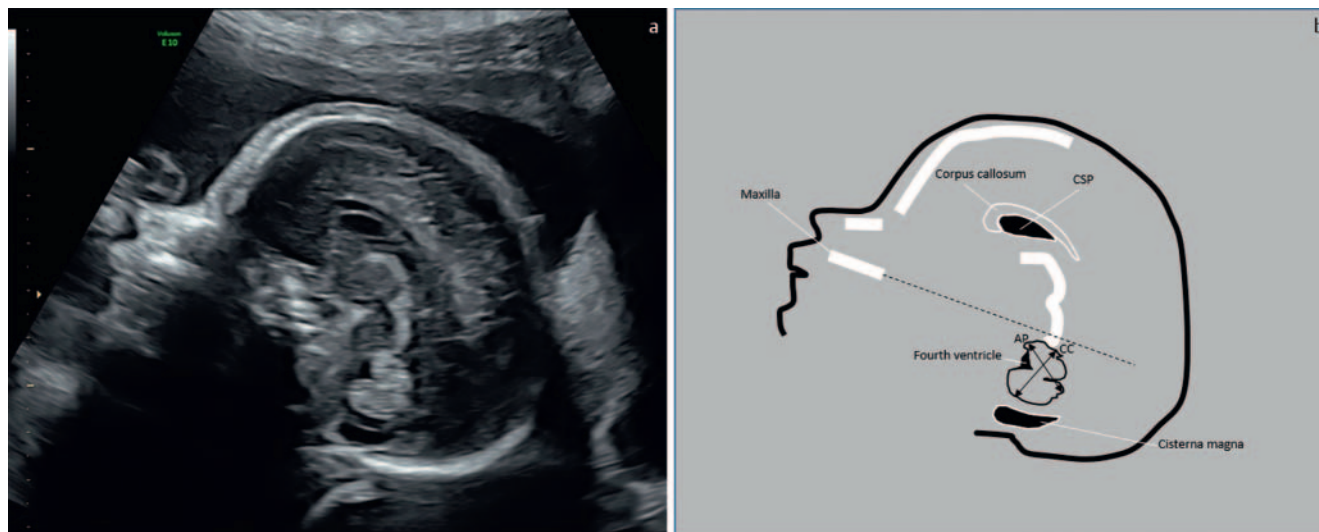
Eligibility Criteria and Study Selection

A total of 964 results were found and 299 duplicate records were deleted after using the de-duplication processes described in “De-duplication of database search results for systematic reviews in EndNote” resulting in a total of 665 unique citations being included in the project library [39]. Of these, 177 referenced the vermis and were further reviewed (► Fig. 1). The updated search revealed 24 articles, none of which met the inclusion criteria. Thirty articles were selected for full-text review. Bibliographies of selected papers were reviewed to search for other relevant papers, and none were found. Of the 30 papers, nine were excluded from further review. The reasons for exclusion were: they dealt only with MRI ($n = 5$), were only about postnatal measurements ($n = 1$), did not measure the vermis ($n = 1$), were based on pathology ($n = 1$), or provided measurements independent of gestational age ($n = 1$). The remaining 21 articles were reviewed qualitatively (► Table 1) and of these, 3 were included for quantitative review [3, 4, 22]. The reasons for exclusion from quantitative review included articles that provided only graphs without numerical tables ($n = 6$), articles that provided data in 2-week increments

► Table 1 Characteristics of included studies.

author year of publication country	imaging modality	measurements included				gestational ages included (weeks)	total number of fetuses	longitudinal? (i. e., multiple exams per fetus)	data reporting/ statistics	non-visualization or inability to measure vermis (%)
		craniocaudal diameter	anteroposterior diameter	perimeter	surface area					
studies included for quantitative synthesis										
Cignini [3] 2016 Italy	2D US	+				20–35	10 605	no	means, SD, 95 %CI, and 4 different statistical models for quantiles	0 %
Gezer [4] 2016 Turkey	2D TAUS	+	+			17–30	157	no	means, SD, calculated percentiles	25.4 %
Zhao [22] 2013 China	2D TAUS, 3D TAUS	+	+			18–32	362	no	means and SD	35.6 % in 2D and 0.6 % in 3D
studies excluded from quantitative synthesis because they did not report values in weekly gestational age increments										
Achiron [23] 2004 Israel	2D TAUS/TVUS	+				19–34	293	no	percentiles in 2-week intervals	2.0 %
Bertucci [24] 2011 Israel	3D TAUS/TVUS	+		+		18–35	73 normal and 12 abnormal	for some fetuses	means and SD in 2-week intervals	0
Ginath [5] 2013 Israel	2D TAUS/TVUS	+	+			18–39	21 with 173 exams	yes	graphs and percentiles in 2-week intervals	not reported
Leibovitz [25] 2014 Israel	3D TAUS/TVUS	+	+			16–35	334	no	graphs and means and SD in 2-week intervals	32.9 % of CCD, 35.7 % of APD
Malinger [11] 2001 Israel	2D TVUS	+	+	+		21–39	101	no	mean and SD in 2-week intervals	8 %
Vinals [14] 2005 Chile	3D TAUS	+	+			18–33	203	no	mean and SD in 2-week intervals	0 %
studies excluded from quantitative synthesis because results only reported graphically										
Altmann [26] 2016 Austria	3D TVUS	"length"				CRL 45–84 mm (11 + 3–13 + 6wga)	80	no	graphs only	1.25 %
Altmann [27] 2018 Austria	3D TVUS	"longest diameter"				CRL 45–84 mm (11 + 3–13 + 6wga)	216	no	graphs and formula	22.5 % (only examined in 40 patients)

▶ Table 1 (Continuation)										
author year of publication country	imaging modality	measurements included				gestational ages included (weeks)	total number of fetuses	longitudinal? (i. e., multiple exams per fetus)	data reporting/ statistics	non-visualization or inability to measure vermis (%)
		craniocaudal diameter	anteroposterior diameter	perimeter	surface area					
Paladini [28] 2006 Italy	3D TAUS/TVUS	angles and ratio of vermis diameter to biparietal diameter				18–37	51	no	graph	not reported
Rizzo [12] 2012 Italy	3D TAUS	“largest length and area”				18–32	342	no	graphs and predicted reference ranges in mostly 2-week intervals with 10/50/90 % percentile	3.3 %
Spinelli [13] 2016 Switzerland	2D TAUS/TVUS			+		18–33	328	no	graphs and predicted percentiles in 2-week intervals	10.1 %
Xie [15] 2019 China	3D TAUS	+	+	+		16–41	438	no	graphs only	not reported
studies excluded from quantitative synthesis because they used nonstandard imaging techniques or 3D only										
Mirlesse [29] 2010 France	2D TVUS/TAUS	+				21–36	643	no	mean and SD and smoothing percentiles	3.3 %
Goldstein [2] 2001 Israel	2D TAUS/TVUS	width (axial plane)				20–37	266	no	graphs and percentiles	not reported
Zalel [17] 2002 Israel	2D TAUS	+				18–38	256	no	graphs and means/SD	< 5 %
Katorza [8] 2016 Israel	3D TAUS/TVUS, 2D TAUS/TVUS, MRI	+	+	+		21–35	172	no	means, SD	not reported
Zalel [18] 2009 Israel	3D TAUS	+				18–26	173	no	median and percentiles	0.6 %
study excluded because it included fetuses at high risk for neurological abnormalities										
Zhao [21] 2018 China	2D TAUS, 3D TAUS, MRI	+	+			24–32	180	no	means and SD	31.1 % in 2D and 0 % in 3D
TAUS: transabdominal ultrasound, TVUS: transvaginal ultrasound, MRI: magnetic resonance imaging, SD: standard deviation, CI: confidence interval, 2D: two-dimensional, 3D: 3-dimensional.										



► **Fig. 2** Depiction of recommended vermian measurement technique. **a** demonstrates a sample midsagittal view at 24 weeks. **b** shows the suggested method of measurement of the vermian diameters. Note the use of an imaginary line in continuation to the maxilla (dashed line). CC – cranio-caudal, AP – antero-posterior.

($n = 6$), articles that used non-standard imaging planes or measurement techniques ($n = 5$), and an article that included fetuses at high risk for neurological abnormalities ($n = 1$).

Characteristics of Studies Included For Quantitative Synthesis

The 3 included articles comprised a total of 10 910 measurements from gestational ages 17–35 weeks, with one article contributing 97 % of the data [3]. 2 of the articles used only 2D ultrasound [3, 4] and the remaining 1 used both 3D and 2D [22]. All 3 articles reported on the CCD, while 2 articles reported on the APD [4, 22]. None of the included articles reported on the P, and 1 reported on the SA [4]. In all cases the measurements were obtained from a midsagittal view. There were minimal variations in the way the different articles defined the CCD and the APD. For the CCD one article used the spine [22] as an axis which was parallel to the axis of measurement, and two studies used the definition of the maximal distance between the most cranial portion of the culmen to the most caudal portion of the uvula [3, 4]. For the APD one study used a definition of the distance from the central lobule anteriorly to the tuber posteriorly [4], and one study used a definition of the maximum distance between the most anterior portion and the most posterior portion of the cerebellar vermis [22].

In ► **Fig. 2** we present the suggested way to measure the vermian CCD and APD based on the included articles. Specifically, the perfect midsagittal image should include the following structures: corpus callosum, cavum septum pellucidum, fourth ventricle, midbrain, and cisterna magna. If possible, the maxilla should also be visualized as it denotes the perfect anteroposterior line. As such, the vertical axis lies perpendicular to this line. The vermis is visualized as a hyperechoic structure anterior to the cisterna magna and posterior to the fourth ventricle. The CCD is defined as the maximal diameter between the highest and lowest points, referred to as the culmen cranially and uvula caudally. The APD should

be measured between the most anterior point (referred to as the central lobule) and the most posterior point (referred to as the tuber). It is important to note that the anteroposterior diameter is not perpendicular to the CCD. Although the definitions differed slightly we still considered the definitions close enough to be meta-analyzed together. Rates of vermian non-visualization varied in the included studies from 0 % to 35.4 %.

The quality assessment (► **Table 2**) demonstrated that there was generally poor reporting regarding maternal characteristics. For instance, although the studies purported to only include low-risk, healthy women, the specific criteria used to make this determination were vague or not specified. In fact, we were unable to assess many of the quality criteria due to insufficient descriptions of the underlying populations that were studied. Similarly, no studies included postnatal verification of a normal, liveborn, neonate [8]. Information about diagnostic genetic testing was also vague or missing. Except in the article by Cignini et al., the mean number of fetuses per week of gestational age was 10.5, with the lowest number being only 5 [4]. No articles mentioned blinding of the sonologist to the gestational age of the fetus.

Normal Vermis Measurements

► **Table 3–5** depict the results of the meta-analysis for CCD, APD, and SA, respectively, by gestational week. In general, there was a significant degree of statistical heterogeneity and, with the exception of the study by Cignini, a small number of fetuses included at each gestational age [3]. The vermis was noted to increase in all measured dimensions across gestation. The CCD (reported in 3 articles) increased from a mean of 7.90 mm (95 % confidence interval [CI] 7.42, 8.38) at 17 weeks to 21.90 mm (95 % CI 20.63, 23.16) at 35 weeks gestation. The APD (reported in 2 articles) increased from 6.30 mm (95 % CI 5.42, 7.18) at 17 weeks to 15.85 mm (95 % CI 15.49, 16.21) at 32 weeks. The SA (reported in 1 article) increased from 43.00 mm² (95 % CI 38.20, 47.00) at 17 weeks to

► **Table 2** Quality assessment of articles included for quantitative synthesis.

		criteria	author		
			Cignini	Gezer	Zhao
definition of normal population – mother		no hypertension	+	not noted	not noted
		no diabetes	+	not noted	not noted
		no history of stillbirth or recurrent pregnancy loss	not noted	not noted	not noted
		no major co-morbidities	not noted	+	not noted
		normal weight	not noted	not noted	not noted
		no mullerian abnormalities	not noted	not noted	not noted
		no smoking/alcohol/drugs	smokers included	not noted	not noted
		teratogen exposure	radiation exposure excluded	not noted	not noted
		over 18 years	not noted	not noted	not noted
definition of normal pregnancy		mode of conception	not noted	not noted	not noted
		no bleeding	not noted	not noted	not noted
definition of normal population – fetus	definition of fetus population	male vs. female	both	both	both
		singleton vs. twin	no twins	no twins	no twins
		ethnic background	99.4% caucasian	not noted	not noted
	history	excluded family history of anomalous siblings/family members	+	not noted	not noted
	biochemical screening	first-trimester screening	not noted	not noted	not noted
		second-trimester screening	not noted	not noted	not noted
		combined first- and second-trimester screening	not noted	not noted	not noted
	anatomic screening	normal anatomic survey noted	not noted	not noted	not noted
		growth	not noted	iugr excluded	IUGR excluded
	genetic testing	abnormal genetics excluded	+	+	+
	clinical validation	postnatal follow-up	not done	not done	not done
		livebirth	not noted	not noted	not noted
normal birthweight		not noted	not noted	not noted	
quality of measurement		accuracy of determination of gestational age	first-trimester CRL	first-trimester CRL	12-week ultrasound
		examiner blinded to gestational age	no	no	no
		clear definition of the technique	+	+	+
		inter- and intra-class correlation discussed	no	one examiner only	+
		unique patient population (i. e., never published before/after in another publication)	+	+	+
statistics		number of patients per gestational week noted	+	+	+
		results in 1-week interval	+	+	+

IUGR: intrauterine growth restriction, CRL: crown-rump length. +- met criteria.

▶ **Table 3** Craniocaudal diameter across gestation (mm) from random effects meta-analysis.

gestational age (week)	author		Gezer				Zhao				Pooled				p (heterogeneity)			
	n	mean	SD	weight	n	mean	SD	weight	n	mean	SD	weight	total N	mean		lower bound 95% CI	upper bound 95% CI	I-squared
17					6	7.9	0.6	100.0%					6	7.90	7.42	8.83	-	-
18					9	8.4	0.8	35.9%	18	7.91	0.25	64.1%	27	8.09	7.63	8.55	68.9%	0.073
19					7	9.9	0.8	47.8%	16	8.51	0.32	52.2%	23	9.17	7.81	10.54	94.9%	<0.001
20	636	11.27	0.58	33.6%	10	10.4	0.7	32.9%	18	9.12	0.3	33.5%	664	10.26	8.61	11.92	99.8%	<0.001
21	4549	11.96	0.67	33.7%	11	11.6	0.8	32.6%	18	10.04	0.27	33.7%	4578	11.20	9.70	12.69	99.8%	<0.001
22	4160	12.71	0.76	34.8%	9	13	1.4	30.7%	16	10.83	0.43	34.5%	4185	12.15	10.66	13.64	99.3%	<0.001
23	692	13.5	0.85	35.1%	8	14.1	0.6	31.8%	15	12.43	0.64	33.1%	715	13.34	12.58	14.09	95.9%	<0.001
24	89	14.32	0.94	37.9%	7	14.9	0.8	26.2%	15	14.99	0.55	35.9%	111	14.71	14.20	15.23	87.7%	<0.001
25	66	15.16	1.03	34.1%	8	15.3	0.8	31.4%	15	16.46	0.3	34.5%	89	15.65	14.65	16.65	97.6%	<0.001
26	56	16.01	1.12	34.3%	15	16.2	1.2	30.4%	12	17.15	0.29	32.3%	83	16.47	15.60	17.34	95.9%	<0.001
27	52	16.85	1.21	34.5%	8	16.9	0.9	14.7%	12	17.21	0.36	50.7%	72	17.04	16.77	17.31	46.4%	0.16
28	36	17.67	1.3	3.5%	7	17.4	1.2	0.8%	10	17.54	0.13	95.8%	53	17.54	17.47	17.62	0.0%	0.8
29	47	18.47	1.39	20.3%	7	17.8	0.1	43.2%	8	17.79	0.25	36.5%	62	17.93	17.69	18.17	81.3%	0.005
30	51	19.22	1.48	40.2%	5	20.1	1.8	16.0%	6	18.4	0.25	43.8%	62	19.00	18.22	19.79	87.7%	<0.001
31	77	19.91	1.57	44.7%					5	19.46	0.23	55.3%	82	19.66	19.22	20.10	79.0%	0.029
32	53	20.54	1.66	50.1%					4	19.93	0.46	49.9%	57	20.24	19.64	20.84	71.8%	0.06
33	26	21.09	1.75	100.0%									26	21.09	20.42	21.76	-	-
34	6	21.54	1.84	100.0%									6	21.54	20.07	23.01	-	-
35	9	21.9	1.93	100.0%									9	21.90	20.64	23.16	-	-

SD: standard deviation, CI: confidence interval.

► **Table 4** Anteroposterior diameter of vermis across gestation (mm) from random effects meta-analysis.

gestational age (week)	author													
	Gezer					Zhao					Pooled			
	n	mean	SD	weight	n	mean	SD	weight	total N	mean	lower bound 95% CI	upper bound 95% CI	I-squared	p (hetero-geneity)
17	6	6.3	1.1	100.0%					6	6.30	5.42	7.18	-	-
18	9	6.7	1	34.0%	18	6.12	0.26	66.0%	27	6.32	5.78	6.86	65.9%	0.087
19	7	7.8	0.5	49.1%	16	6.49	0.23	50.9%	23	7.13	5.85	8.42	97.7%	<0.001
20	10	8.5	0.4	49.7%	18	7.09	0.31	50.3%	28	7.79	6.41	9.17	98.9%	<0.001
21	11	9.5	0.4	49.8%	18	7.94	0.27	50.2%	29	8.72	7.19	10.25	99.2%	<0.001
22	9	10.7	1.1	48.3%	16	8.78	0.4	51.7%	25	9.71	7.83	11.59	96.1%	<0.001
23	8	11.1	0.7	47.3%	15	10.21	0.52	52.7%	23	10.63	9.76	11.50	90.0%	0.002
24	7	12.2	0.1	51.6%	15	11.76	0.34	48.4%	22	11.99	11.56	12.42	95.3%	<0.001
25	8	12.8	0.1	58.3%	15	12.61	0.33	41.6%	23	12.72	12.54	12.90	76.4%	0.039
26	15	12.9	0.7	41.2%	12	13.32	0.14	58.8%	27	13.15	12.74	13.55	80.6%	0.023
27	8	13.3	0.7	43.1%	12	13.93	0.28	56.9%	20	13.66	13.05	14.27	82.9%	0.016
28	7	14	0.6	36.4%	10	14.4	0.28	63.6%	17	14.25	13.88	14.63	63.0%	0.1
29	7	15.1	0.8	14.5%	8	14.75	0.19	85.5%	15	14.80	14.56	15.04	21.7%	0.258
30	5	16.2	0.7	45.2%	6	15.23	0.21	54.8%	11	15.67	14.72	16.61	88.8%	0.03
31					5	15.58	0.19	100.0%	5	15.58	15.41	15.75	-	-
32					4	15.85	0.37	100.0%	4	15.85	15.49	16.21	-	-

SD: standard deviation, CI: confidence interval.

► **Table 5** Vermis surface area across gestation (mm²) from random effects meta-analysis.

	author				
	Gezer				
gestational age (weeks)	n	mean	SD	lower bound 95 % CI	upper bound 95 % CI
17	6	43.00	6.00	38.20	47.80
18	9	48.00	10.00	41.47	55.43
19	7	77.00	15.00	65.89	88.11
20	10	85.00	12.00	77.56	92.44
21	11	94.00	11.00	87.50	100.50
22	9	119.00	23.00	104.97	134.03
23	8	140.00	24.00	123.37	156.63
24	7	153.00	20.00	138.18	167.82
25	8	159.00	12.00	150.68	167.32
26	15	185.00	21.00	174.37	195.63
27	8	193.00	14.00	183.30	202.70
28	7	199.00	16.00	187.15	210.85
29	7	220.00	25.00	201.48	238.52
30	5	276.00	36.00	244.45	307.55

SD: standard deviation, CI: confidence interval.

276.00 mm² (95 %CI 244.45, 307.55) at 30 weeks. Forest plots for all measurements by gestational week are found in the Appendix.

► **Fig. 3** graphically depicts the mean and 95 %CI of the measurements for the results of the meta-analysis for the CCD (► **Fig. 3a**), APD (► **Fig. 3b**), and SA (► **Fig. 3c**).

Discussion

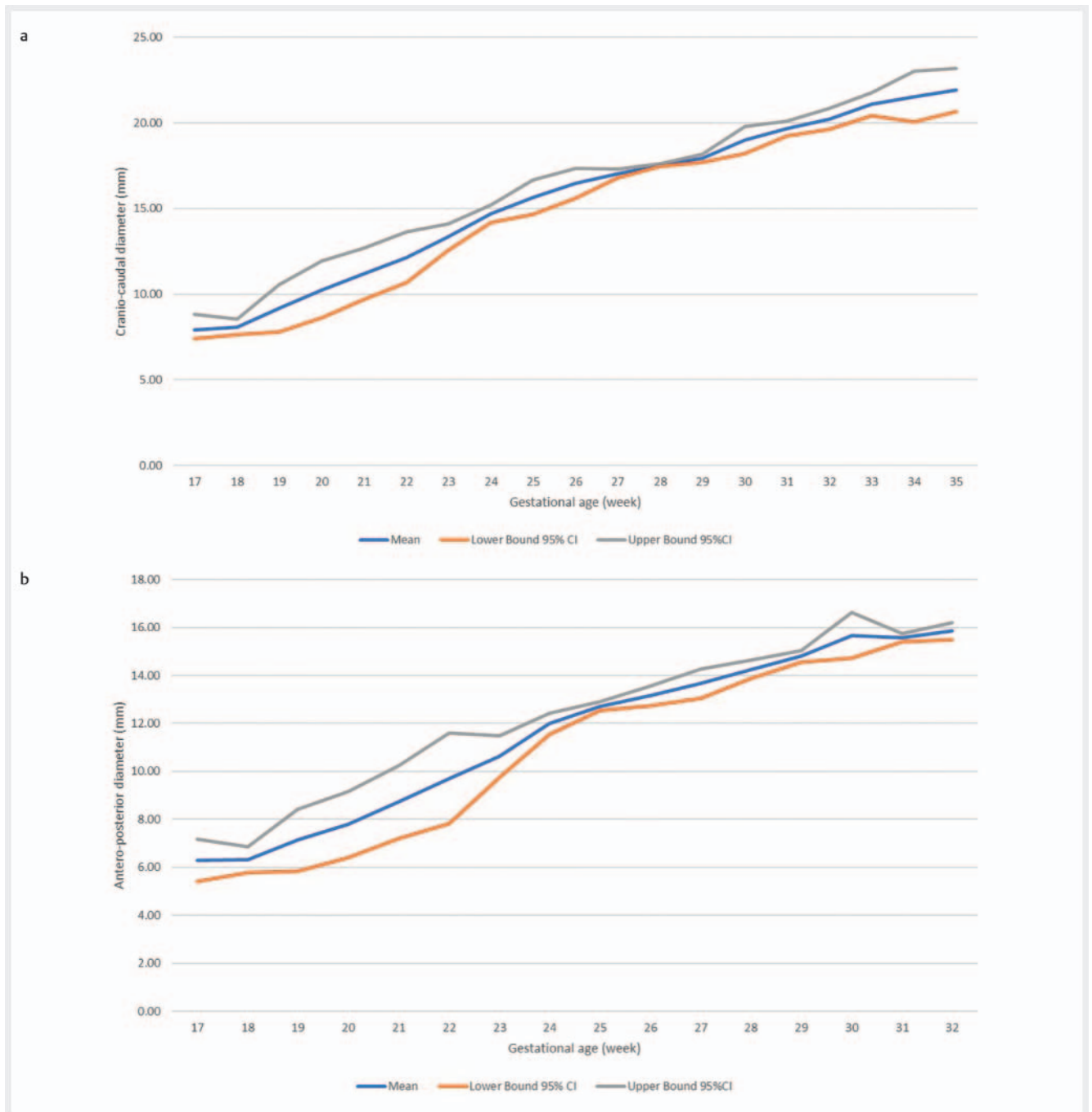
In this systematic review and meta-analysis of prenatal vermis biometry, we found that although there were 21 articles that reported normal vermis biometric measurements, the majority of them reported data in ways that made it infeasible to perform meta-analysis. In particular, data were often provided in 2-week intervals (but the intervals were often different across studies, precluding synthesis) or were provided only in graphical references. Additionally, most of the included studies had only a small number of fetuses per week of gestational age.

Attention has been drawn to the need to accurately classify posterior fossa anomalies [40]. Agenesis of the vermis is different than vermian hypoplasia, which is different from problems relating to rotation of an otherwise normal vermis, such as in Blake's pouch cyst [41]. Indeed a now classic study reported on a large discrepancy between prenatally diagnosed Dandy-Walker syndrome and autopsy findings, highlighting the need for accurate assessment of the posterior fossa prenatally [42]. One potential tool for improving the diagnostic accuracy of posterior fossa malformations is accurate measurement of the vermis. Therefore, it is essential to utilize accurate reference ranges when there is a ques-

tion as to possible vermian hypoplasia. The results of our study may therefore be useful to clinicians and could be incorporated into ultrasound reporting packages.

However, our results highlight a need for better reporting of studies of normal reference ranges in prenatal ultrasound. In particular, it is essential that studies be adequately powered to provide meaningful reference ranges [43, 44]. In our experience, the sample size that was used to generate reference curves is rarely taken into consideration during their clinical use. Furthermore, as recently highlighted in a systematic review of Doppler parameters during pregnancy, studies meant to establish reference ranges should report results in a numerical (not only graphical) fashion, should utilize more than one sonographer per examination to ensure inter-observer validity, and should be blinded to gestational age when the examination is performed [31]. Finally, non-visualization rates ranged from 0–35.4 % in the included studies. Missing data on the cases in which the vermis was not visualized may have biased results. For instance, vermis non-visualization could theoretically be related to an abnormal vermian shape or size. The wide range of vermis non-visualization also calls into question the sonographic techniques that were used and inclusion criteria for the studies.

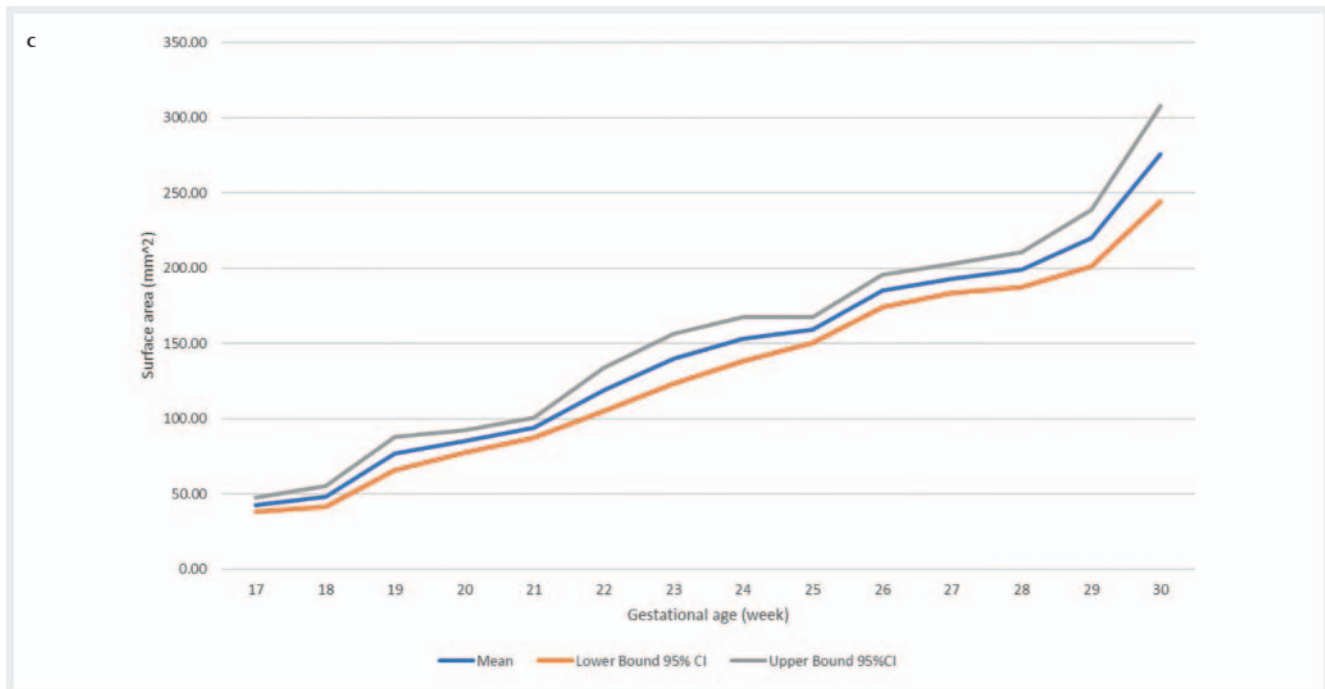
We also presented a potential tool for quality assessment of studies meant to establish normal prenatal biometry. Domains such as a full description of the maternal population, full assessment and description of how fetal “normality” was established (e. g. genetic testing), inclusion of an adequate number of patients, a full description of the measurement technique, and postnatal fol-



► **Fig. 3** **a** Mean and 95 % confidence intervals for the vermian crano-caudal diameter from the meta-analysis. **b** Mean and 95 % confidence intervals for the vermian antero-posterior diameter from the meta-analysis.

low-up are essential to ensure that generated reference ranges are generalizable. The included studies were heterogeneous in ethnic origin: one from China, one from Italy, and one from Turkey. The other studies included for qualitative review represent a broader population. The question of whether vermian measurements differ by ethnic origin deserves further study. Certainly, the use of customized ethnic-based growth percentiles in general fetal biometry is advocated by some, but whether this recommendation should extend to specific sub-organs is not known [45–47].

Our study has a number of strengths. We performed a systematic review and meta-analysis in accordance with published guidelines and registered the protocol [32]. We used a comprehensive search strategy that was implemented by a trained research librarian. Finally, we conducted a comprehensive quality assessment of each article and performed both qualitative and quantitative synthesis. However, there are also some limitations to consider. First, although we had planned to use the Newcastle



► **Fig. 3c** Mean and 95 % confidence intervals for the vermiform surface area diameter from the meta-analysis.

Ottawa bias assessment and registered the protocol as such, we found that this tool was not well-suited to evaluation of the included studies. Second, we were unable to include the majority of studies in the quantitative review due to the methodological issues outlined above. Certainly, by excluding many studies with results that were not suitable for meta-analysis, our results may also be subject to selection bias. This fact further reinforces the importance of reporting biometric studies with reproducible techniques and reporting in numerical and not only graphical fashion. Finally, the majority of the data used to generate the reference ranges for the CCD (but not for the APD or the SA) come from one large study, although at extremes of gestational age the study by Cignini had relatively few participants [3].

In conclusion, we have provided reference ranges for vermiform biometry across gestation based on meta-analysis of existing references. Furthermore, by conducting a systematic review, we have provided a list of available reference ranges. However, because many of the underlying studies suffered from significant methodological issues, our ranges should be used with caution. Large, prospective, well-designed studies should be conducted when attempting to determine normal reference ranges for prenatal ultrasound parameters.

Conflict of Interest

The authors declare that they have no conflict of interest.

References

- [1] International Society of Ultrasound in Obstetrics and Gynecology Education Committee. Sonographic examination of the fetal central nervous system: guidelines for performing the 'basic examination' and the 'fetal neurosonogram'. *Ultrasound Obstet Gynecol* 2007; 29: 109–116. doi:10.1002/uog.3909
- [2] Goldstein I, Tamir A, Reece EA. The fetal superior cerebellar vermian width in normal, growth-restricted and macrosomic fetuses. *J Matern Fetal Med* 2001; 10: 23–27
- [3] Cignini P, Giorlandino M, Brutti P et al. Reference charts for fetal cerebellar vermiform height: A prospective cross-sectional study of 10605 fetuses. *PLoS One* 2016; 11: doi:10.1371/journal.pone.0147528
- [4] Gezer C, Ekin A, Gezer NS et al. Quantitative evaluation of the fetal cerebellar vermiform using the median view on two-dimensional ultrasound. *Iranian Journal of Radiology* 2016; 13: doi:10.5812/iranjradiol.34870
- [5] Ginath S, Lerman-Sagie T, Haratz Kraiden K et al. The Fetal vermiform, pons and brainstem: Normal longitudinal development as shown by dedicated neurosonography. *Journal of Maternal-Fetal and Neonatal Medicine* 2013; 26: 757–762. doi:10.3109/14767058.2012.755508
- [6] Huang CC, Liu CC. The differences in growth of cerebellar vermiform between appropriate-for-gestational-age and small-for-gestational-age newborns. *Early Hum Dev* 1993; 33: 9–19. doi:10.1016/0378-3782(93)90169-U
- [7] Kapur RP, Mahony BS, Finch L et al. Normal and abnormal anatomy of the cerebellar vermiform in midgestational human fetuses. *Birth Defects Research Part A – Clinical and Molecular Teratology* 2009; 85: 700–709. doi:10.1002/bdra.20589
- [8] Katorza E, Bertucci E, Perlman S et al. Development of the fetal vermiform: New biometry reference data and comparison of 3 diagnostic modalities-3d ultrasound, 2d ultrasound, and mr imaging. *American Journal of Neuroradiology* 2016; 37: 1359–1366. doi:10.3174/ajnr.A4725
- [9] Lei T, Xie HN, Zhu YX et al. Date-Independent Parameters: an Innovative Method to Assess Fetal Cerebellar Vermiform. *Cerebellum* 2015; 14: 231–239. doi:10.1007/s12311-014-0632-x

- [10] Liu W, Cai AL, Zhao D et al. Evaluation of the fetal cerebellar vermis with three-dimensional ultrasound VOCAL technique. *Chinese Journal of Medical Imaging Technology* 2008; 24: 1795–1798
- [11] Malinger G, Ginath S, Lerman-Sagie T et al. The fetal cerebellar vermis: normal development as shown by transvaginal ultrasound. *Prenat Diagn* 2001; 21: 687–692. doi:10.1002/pd.137
- [12] Rizzo G, Pietrolucci ME, Mammarella S et al. Assessment of cerebellar vermis biometry at 18–32 weeks of gestation by three-dimensional ultrasound examination. *Journal of Maternal-Fetal and Neonatal Medicine* 2012; 25: 519–522. doi:10.3109/14767058.2011.622006
- [13] Spinelli M, Sica C, Meglio LD et al. Fetal Cerebellar Vermis Circumference Measured by 2-Dimensional Ultrasound Scan: Reference Range, Feasibility and Reproducibility. *Ultrasound International Open* 2016; 2: E124–E128
- [14] Viñals F, Muñoz M, Naveas R et al. The fetal cerebellar vermis: Anatomy and biometric assessment using volume contrast imaging in the C-plane (VCI-C). *Ultrasound Obstet Gynecol* 2005; 26: 622–627. doi:10.1002/uog.2606
- [15] Xie JX, You JH, Chen XK et al. Three-dimensional sonographic minute structure analysis of fetal cerebellar vermis development and malformations: utilizing volume contrast imaging. *Journal of Medical Ultrasonics* 2019; 46: 113–122. doi:10.1007/s10396-018-0906-x
- [16] Yang J, Yuan JJ, Qu XZ. Three-dimensional ultrasound visualization for fetal corpus callosum and cerebellar vermis midline image. *Chinese Journal of Medical Imaging Technology* 2012; 28: 1574–1576
- [17] Zalel Y, Seidman DS, Brand N et al. The development of the fetal vermis: An in-utero sonographic evaluation. *Ultrasound Obstet Gynecol* 2002; 19: 136–139. doi:10.1046/j.0960-7692.2001.00621.x
- [18] Zalel Y, Yagel S, Achiron R et al. Three-dimensional ultrasonography of the fetal vermis at 18 to 26 weeks' gestation: Time of appearance of the primary fissure. *J Ultrasound Med* 2009; 28: 1–8. doi:10.7863/jum.2009.28.1.1
- [19] Zhang XW, Xie LM. Measurement of fetal vermis using OmniView combining with volume contrast imaging technology with three-dimensional ultrasound. *Chinese Journal of Medical Imaging Technology* 2012; 28: 1706–1708
- [20] Zhao D, Cai A, Zhang J et al. 3D ultrasonography and MRI quantitative evaluation of fetal cerebellar vermis. *Chinese Journal of Medical Imaging Technology* 2016; 32: 109–114. doi:10.13929/j.1003-3289.2016.01.028
- [21] Zhao D, Cai A, Zhang J et al. Measurement of normal fetal cerebellar vermis at 24–32 weeks of gestation by transabdominal ultrasound and magnetic resonance imaging: A prospective comparative study. *Eur J Radiol* 2018; 100: 30–35. doi:10.1016/j.ejrad.2018.01.013
- [22] Zhao D, Liu W, Cai A et al. Quantitative evaluation of the fetal cerebellar vermis using the median view on three-dimensional ultrasound. *Prenat Diagn* 2013; 33: 153–157. doi:10.1002/pd.4027
- [23] Achiron R, Kivilevitch Z, Lipitz S et al. Development of the human fetal pons: In utero ultrasonographic study. *Ultrasound Obstet Gynecol* 2004; 24: 506–510. doi:10.1002/uog.1731
- [24] Bertucci E, Gindes L, Mazza V et al. Vermian biometric parameters in the normal and abnormal fetal posterior fossa: three-dimensional sonographic study. *Journal of ultrasound in medicine: official journal of the American Institute of Ultrasound in Medicine* 2011; 30: 1403–1410
- [25] Leibovitz Z, Shkolnik C, Haratz KK et al. Assessment of fetal midbrain and hindbrain in mid-sagittal cranial plane by three-dimensional multiplanar sonography. Part 1: comparison of new and established nomograms. *Ultrasound in obstetrics & gynecology: the official journal of the International Society of Ultrasound in Obstetrics and Gynecology* 2014; 44: 575–580. doi:10.1002/uog.13308
- [26] Altmann R, Scharnreitner I, Scheier T et al. Sonoembryology of the fetal posterior fossa at 11 + 3 to 13 + 6 gestational weeks on three-dimensional transvaginal ultrasound. *Prenat Diagn* 2016; 36: 731–737. doi:10.1002/pd.4852
- [27] Altmann R, Specht C, Scharnreitner I et al. Reference Ranges for Transvaginal Examined Fossa Posterior Structures in Fetuses from 45 to 84 mm Crown-Rump Length. *Gynecol Obstet Invest* 2018; 83: 375–380. doi:10.1159/000486334
- [28] Paladini DVP. Posterior fossa and vermian morphometry in the characterization of fetal cerebellar abnormalities: A prospective three-dimensional ultrasound study. *Ultrasound Obstet Gynecol* 2006; 27: 482–489. doi:10.1002/uog.2748
- [29] Mirlesse V, Courtiol C, Althuser M et al. Ultrasonography of the fetal brainstem: A biometric and anatomical, multioperator, cross-sectional study of 913 fetuses of 21–36 weeks of gestation. *Prenat Diagn* 2010; 30: 739–745. doi:10.1002/pd.2501
- [30] Khan K, Chief Editors of Journals participating in The Crown Initiative. The CROWN Initiative: journal editors invite researchers to develop core outcomes in women's health. *Ultrasound Obstet Gynecol* 2014; 44: 497–498. doi:10.1002/uog.14625
- [31] Oros D, Ruiz-Martinez S, Staines-Urias E et al. Reference ranges for Doppler indices of umbilical and fetal middle cerebral arteries and cerebroplacental ratio: systematic review. *Ultrasound Obstet Gynecol* 2019; 53: 454–464. doi:10.1002/uog.20102
- [32] Moher D, Liberati A, Tetzlaff J et al. Preferred reporting items for systematic reviews and meta-analyses: the PRISMA statement. *PLoS Med* 2009; 6: e1000097. doi:10.1371/journal.pmed.1000097
- [33] Raisi-Estabragh Z, Kenawy AAM, Aung N et al. Variation in left ventricular cardiac magnetic resonance normal reference ranges: systematic review and meta-analysis. *Eur Heart J Cardiovasc Imaging* 2020. doi:10.1093/ehjci/jeaa089
- [34] Levy PT, Sanchez Mejia AA, Machevsky A et al. Normal ranges of right ventricular systolic and diastolic strain measures in children: a systematic review and meta-analysis. *J Am Soc Echocardiogr* 2014; 27: 549–560. e543. doi:10.1016/j.echo.2014.01.015
- [35] Wan X, Wang W, Liu J et al. Estimating the sample mean and standard deviation from the sample size, median, range and/or interquartile range. *BMC Med Res Methodol* 2014; 14: 135. doi:10.1186/1471-2288-14-135
- [36] Der Simonian R, Laird N. Meta-analysis in clinical trials. *Control Clin Trials* 1986; 7: 177–188. doi:10.1016/0197-2456(86)90046-2
- [37] Higgins JPT, Green S. *Cochrane Handbook for Systematic Reviews of Interventions*; Wiley; 2011
- [38] Carter EB, Temming LA, Akin J et al. Group Prenatal Care Compared With Traditional Prenatal Care: A Systematic Review and Meta-analysis. *Obstet Gynecol* 2016; 128: 551–561. doi:10.1097/AOG.0000000000001560
- [39] Bramer WM, Giustini D, de Jonge GB et al. De-duplication of database search results for systematic reviews in EndNote. *J Med Libr Assoc* 2016; 104: 240–243. doi:10.3163/1536-5050.104.3.014
- [40] Guibaud L, des Portes V. Plea for an anatomical approach to abnormalities of the posterior fossa in prenatal diagnosis. *Ultrasound Obstet Gynecol* 2006; 27: 477–481. doi:10.1002/uog.2777
- [41] Malinger G, Lev D, Lerman-Sagie T. The fetal cerebellum. Pitfalls in diagnosis and management. *Prenat Diagn* 2009; 29: 372–380. doi:10.1002/pd.2196
- [42] Carroll SG, Porter H, Abdel-Fattah S et al. Correlation of prenatal ultrasound diagnosis and pathologic findings in fetal brain abnormalities. *Ultrasound Obstet Gynecol* 2000; 16: 149–153. doi:10.1046/j.1469-0705.2000.00199.x
- [43] Nevo D, Mandel M, Ein-Mor E et al. A comparison of methods for construction of fetal reference charts. *Stat Med* 2016; 35: 1226–1240. doi:10.1002/sim.6774
- [44] Wellek S, Lackner KJ, Jennen-Steinmetz C et al. Determination of reference limits: statistical concepts and tools for sample size calculation. *Clin Chem Lab Med* 2014; 52: 1685–1694. doi:10.1515/cclm-2014-0226

- [45] Melamed N, Ray JG, Shah PS et al. Should we use customized fetal growth percentiles in urban Canada? *J Obstet Gynaecol Can* 2014; 36: 164–170. doi:10.1016/s1701-2163(15)30663-0
- [46] Gardosi J, Francis A, Turner S et al. Customized growth charts: rationale, validation and clinical benefits. *Am J Obstet Gynecol* 2018; 218: S609–S618. doi:10.1016/j.ajog.2017.12.011
- [47] Smith NA, Bukowski R, Thomas AM et al. Identification of pathologically small fetuses using customized, ultrasound and population-based growth norms. *Ultrasound Obstet Gynecol* 2014; 44: 595–599. doi:10.1002/uog.13333