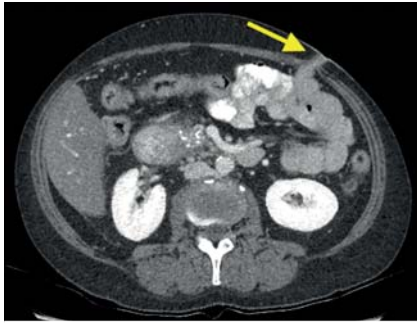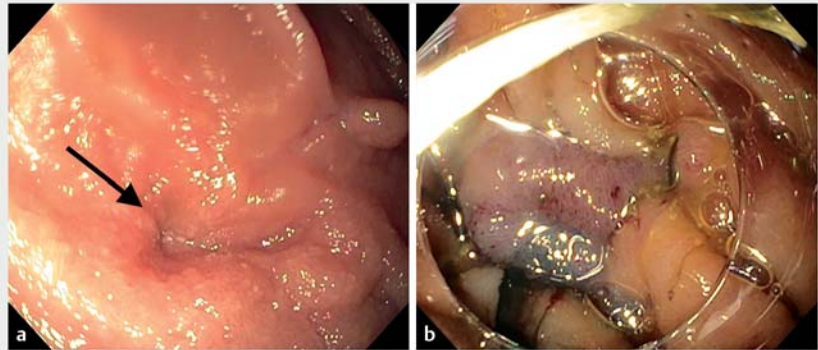


Enterocutaneous fistula closure using a balloon-assisted enteroscope preloaded with an over-the-scope clip – narrowing the gap



► **Fig. 1** Computed tomography scan of the abdomen revealing a communication between the jejunal loops and the skin, consistent with an enterocutaneous fistula.



► **Fig. 2** Endoscopic views of the jejunum showing: **a** the fistulous opening; **b** the closed jejunal fistula after deployment of the 12-mm over-the-scope clip.

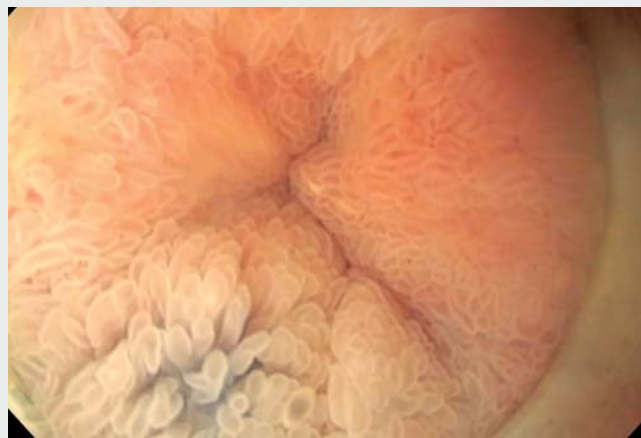Enterocutaneous fistulas (ECFs) are abnormal connections between the intestinal tract and the skin. The over-the-scope (OTS) clip system is an effective tool in closing gastrointestinal leaks, perforations, and fistulas [1, 2].

A 52-year-old woman with a history of necrotizing pancreatitis presented for evaluation of an iatrogenic ECF. She had undergone a balloon-assisted enteroscopy (BAE)-guided direct percutaneous endoscopic jejunostomy (DPEJ) placement for enteral nutrition in the setting of necrotizing pancreatitis 1 year previously. After the J-tube was removed, the defect had failed to heal and a moderate output ECF had formed. A computed tomography (CT) scan of the abdomen revealed a connection between the jejunum and the skin, consistent with an ECF (► **Fig. 1**).

An antegrade single-balloon enteroscopy was performed for fistula closure using the EVIS EXERA II (SIF-Q180; Olympus America), which revealed the fistulous tract (► **Fig. 2 a**). To confirm the endoscopic finding, a large volume of contrast was injected, and active leakage was noted proximal to the mid-jejunum. The enteroscope was withdrawn and a 12-mm OTS clip device was mounted onto the tip of the single-balloon entero-

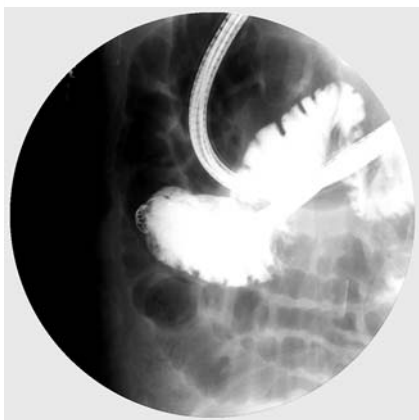scope that was preloaded with the over-tube (► **Video 1**). The enteroscope was advanced to the fistulous tract and adequate closure was achieved (► **Fig. 2 b**). A large volume of contrast was again injected after closure, which revealed no evidence of further leakage (► **Fig. 3**). At 3 months after closure, the patient reported no further leakage of intestinal contents and her nutritional status had improved.

ECFs have devastating consequences if left untreated. Most case series have reported the safety and efficacy of mounting the OTS clip on either a gastro-scope or colonoscope [3]. The challenges in this case were appropriate selection and mounting of the fitting device onto the enteroscope, being able to safely traverse the small bowel, and achieving good visualization, apposition, and delivery for successful closure. In conclu-



► **Video 1** Closure of an enterocutaneous fistula using a single-balloon enteroscope preloaded with an over-the-scope clip.





► **Fig. 3** Fluoroscopic image showing a large volume of contrast being injected after deployment of the over-the-scope clip, with no evidence of further leakage.

sion, we have demonstrated that an enteroscope-mounted OTS clip placed during BAE is a safe and feasible option for a small-bowel fistula.

Endoscopy_UCTN_Code_TTT_1AP_2AD

Competing interests

The authors declare that they have no conflict of interest.

The authors

Ramzi Mulki  **Ali Ahmed, Kondal Kyanam, Shajan Peter**

The University of Alabama at Birmingham, Birmingham, Alabama, USA

Corresponding author

Shajan Peter, MD, FASGE, FACC

Basil Hirshowitz Advanced Endoscopy Center of Excellence, Division of Gastroenterology and Hepatology, University of Alabama at Birmingham, 1702 2nd Avenue South, BDB 363 Birmingham, AL 35294, USA
ssugandha@uabmc.edu

References

- [1] Manta R, Manno M, Bertani H et al. Endoscopic treatment of gastrointestinal fistulas using an over-the-scope clip (OTSC) device: case series from a tertiary referral center. *Endoscopy* 2011; 43: 545–548
- [2] Monkemüller K, Martínez-Alcalá A, Schmidt AR et al. The use of the over the scope clips beyond its standard use: a pictorial description. *Gastrointest Endosc Clin N Am* 2020; 30: 41–74
- [3] Weiland T, Fehlker M, Gottwald T et al. Performance of the OTSC System in the endoscopic closure of gastrointestinal fistulae – a meta-analysis. *Minim Invasive Ther Allied Technol* 2012; 21: 249–258

Bibliography

Endoscopy 2022; 54: E158–E159

DOI 10.1055/a-1471-2037

ISSN 0013-726X

published online 28.4.2021

© 2021. Thieme. All rights reserved.

Georg Thieme Verlag KG, Rüdigerstraße 14, 70469 Stuttgart, Germany

ENDOSCOPY E-VIDEOS

<https://eref.thieme.de/e-videos>



Endoscopy E-Videos is an open access online section, reporting on interesting cases

and new techniques in gastroenterological endoscopy. All papers include a high quality video and all contributions are freely accessible online. Processing charges apply (currently EUR 375), discounts and waivers acc. to HINARI are available.

This section has its own submission website at

<https://mc.manuscriptcentral.com/e-videos>