

Durability of per-oral endoscopic myotomy beyond 6 years



Authors

Jad P. AbiMansour¹, Yervant Ichkhanian¹, Hitomi Minami², Pietro Familiari³, Rosario Landi³, Guido Costamagna³, Stefan Seewald⁴, Zachary M. Callahan⁵, Michael B. Ujiki⁵, Mathieu Pioche⁶, Thierry Ponchon⁶, Sabine Roman⁶, Joo Young Cho⁷, In Kyung Yoo⁷, Megan Sippey⁸, Jeffrey M. Marks⁸, Nikolas Eleftheriadis⁹, Vivek Khumbari¹, Olaya I. Brewer Gutierrez¹, Mouen A. Khashab¹

Institutions

- 1 Division of Gastroenterology and Hepatology Johns Hopkins Hospital, Baltimore, USA
- 2 Department of Gastroenterology and Hepatology Nagasaki University Hospital Nagasaki, Japan
- 3 Digestive Endoscopy Unit Fondazione Policlinico Universitario Agostino Gemelli IRCCS Rome, Italy
- 4 Center of Gastroenterology Hirslanden Private Clinic Group Zürich, Switzerland
- 5 Department of Surgery NorthShore University HealthSystem Evanston, USA
- 6 Gastroenterology Unit/Unit of Functional Disease and Digestive Physiology Edouard Herriot Hospital Lyon, France
- 7 Department of Gastroenterology, Cha Bundang Medical Center, Cha University College of Medicine, Seongnam-si, Korea
- 8 Case Western/University Hospitals Cleveland Medical Center, Cleveland, USA
- 9 Metropolitan Hospital, Athens, Greece

submitted 3.8.2020

accepted after revision 26.4.2021

Bibliography

Endosc Int Open 2021; 09: E1595–E1601

DOI 10.1055/a-1553-9846

ISSN 2364-3722

© 2021. The Author(s).

This is an open access article published by Thieme under the terms of the Creative Commons Attribution-NonDerivative-NonCommercial License, permitting copying and reproduction so long as the original work is given appropriate credit. Contents may not be used for commercial purposes, or adapted, remixed, transformed or built upon. (<https://creativecommons.org/licenses/by-nc-nd/4.0/>)

Georg Thieme Verlag KG, Rüdigerstraße 14,
70469 Stuttgart, Germany

Corresponding author

Mouen A. Khashab, MD, Division of Gastroenterology and Hepatology, Johns Hopkins Hospital, 1800 Orleans Street, Suite 7125G, Baltimore, MD 21287, USA
Fax: +1-443-683-8335
mkhasha1@jhmi.edu

ABSTRACT

Background and study aims The aim of this study was to assess long-term clinical outcomes beyond 6 years in patients who underwent per-oral endoscopic myotomy (POEM) for the treatment of achalasia.

Patients and methods Patients with achalasia who underwent POEM between 2010 and 2012 and had follow-up of at least 6 years were retrospectively identified at eight tertiary care centers. The primary outcome evaluated was clinical success defined by an Eckardt symptom score (ESS) ≤ 3 for the duration of the follow-up period. The clinical success cohort was compared to failure (ESS > 3 at any time during follow-up) in order to identify characteristics associated with symptom relapse. The incidence of patient-reported gastroesophageal reflux (GER) was also evaluated.

Results Seventy-three patients with 6-year follow-up data were identified. Sustained clinical remission was noted in 89% (65/73) at 6-years. Mean ESS decreased from 7.1 ± 2.3 pre-procedure to 1.1 ± 1.1 at 6 years ($P < 0.001$). Symptomatic reflux was reported by 27 of 72 patients (37.5%). Type I achalasia (OR 10.8, $P = 0.04$) was found to be associated with clinical failure on logistic regression analysis.

Conclusions In patients with achalasia, POEM provides high initial clinical success with excellent long-term outcomes. There are high rates of patient-reported gastroesophageal reflux post-procedure which persist at long-term follow-up.

Introduction

Achalasia is a rare motility disorder of the esophagus associated with the loss of myenteric neurons that control peristalsis and relaxation of the lower esophageal sphincter (LES). Esophageal dysfunction leads to progressive symptoms of solid and liquid dysphagia, regurgitation, and atypical chest pain which significantly impact quality of life [1]. There is no known cure for achalasia but the mainstay of treatment is disruption of the LES using botulinum toxin injection, pneumatic balloon dilation, or myotomy.

Per-oral endoscopic myotomy (POEM), a type of natural orifice transluminal endoscopic surgery, performed without any cutaneous incisions, has emerged as a novel, safe, and effective treatment of achalasia [2, 3]. It has quickly become the gold-standard in experienced centers, and studies have shown a robust clinical response in greater than 90% of patients within the first year [4–11]. However, the natural history of achalasia is one of an incurable and progressive disease. Response to therapy tends to diminish over time regardless of treatment modality, making the assessment of long-term outcomes critically important [12, 13].

Studies suggest treatment response to POEM is maintained in the first two to three years with remission rates between 88–90%, but true long-term follow-up is sparse and limited to small cohorts and single-center case series [14–16]. There are currently no studies examining outcomes of POEM beyond 5 years. We performed this international, multicenter cohort study to assess the long-term (>6 years) effectiveness of POEM and identify clinical features that may be associated with treatment failure over time.

Patients and methods

This retrospective cohort study was approved by the Institutional Review Board for Human Research at The Johns Hopkins Hospital and subsequently by each center enrolled in the study. We retrospectively identified consecutive, adult patients (>18 years old) who underwent POEM for the treatment of achalasia between 2010 and 2012 at eight tertiary care centers (2 United States, 4 Europe, 2 Asia). Records were identified from electronic health records and procedural databases. Those with telephone or in-person follow-up after at least 6 years were included in the study. Efforts were made at each center to obtain follow-up information by telephone when not available in the medical record, but ultimately patients without documented follow-up at 6 years were excluded. Patients who underwent POEM for alternative indications, including diffuse esophageal spasm, esophagogastric junction outflow obstruction, and jackhammer esophagus, were also excluded. The majority of patients in this cohort were included in previously published studies on shorter-term outcomes, incidence of gastroesophageal reflux disease, and adverse events (AEs) after POEM however clinical outcomes have never been reported beyond 4 years [6, 17–21].

While POEM technique has been well-described in the current literature, specific technical aspects of the procedure as

well as post-operative management were determined by the standard of practice at each individual center. Generally, the procedure was performed with a cap-fitted endoscopic approach with patients under general anesthesia and on positive-pressure ventilation. Patients were kept nil per os overnight and underwent esophagram with water-soluble contrast on post-operative day one to exclude esophageal leak prior to diet advancement and discharge.

Chart review was performed by each center and data extracted into a central database. In addition to baseline demographic and clinical information, procedural data collected included myotomy orientation, myotomy thickness, esophageal and gastric myotomy length, and procedure-related AEs. AEs were graded as mild, moderate, or severe based on the American Society for Gastrointestinal Endoscopy (ASGE) lexicon for endoscopic AEs [22]. All data analysis was conducted at the coordinating center (The Johns Hopkins Hospital).

Clinical response was evaluated at 6 years using Eckardt symptom score (ESS). The ESS is a validated self-assessment tool that is the gold-standard for assessing symptom severity with fair reliability and validity [23, 24]. It includes patient-reported grading of dysphagia, chest pain, regurgitation and weight loss. Scores at 6, 12, 24, 36 and 48 months were reported when available. The primary outcome was clinical success defined as $ESS \leq 3$ for the duration of follow-up with treatment failure representing a score > 3 at any time during the follow-up period. In patients with missing data for specified time points, the last observation was carried forward. A score ≤ 3 has been shown to be suggestive of active achalasia, and this definition is consistent with that used in prior studies, including multiple randomized controlled trials [24–26]. Additional outcomes of interest included clinical characteristics associated with treatment failure and prevalence of gastroesophageal reflux as defined by patient-reported symptoms, use of proton pump inhibitors (PPIs), and presence of esophagitis on esophagogastroduodenoscopy.

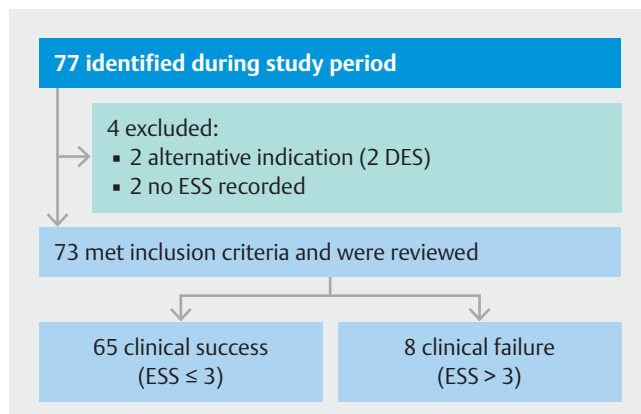
Patients were divided into clinical success ($ESS \leq 3$) and clinical failure ($ESS > 3$) cohorts. Baseline characteristics included patient demographics, prior therapies, esophagus shape, LES relaxation pressure, and pre-procedure ESS. Diagnosis was categorized based on the Chicago Classification of esophageal motility disorders [27]. Procedural data was collected as described above. Symptomatic reflux and PPI use were assessed at last follow-up. Esophageal acid exposure/pH measurement, endoscopy findings, and manometry were reported when available.

Quantitative variables were described with mean value and standard deviation. Categorical values were described with frequencies (%). We assessed for clinically relevant differences among patients who experienced treatment failure. Univariate analysis was performed using standard paired *t*-test for quantitative data and, for categorical data, chi-square tests or Fisher's exact tests when event frequency was less than five. Missing data that was not available from retrospective chart review were excluded in comparisons. $P \leq 0.05$ was considered statistically significant. Statistical analysis was performed using SPSS software (SPSS version 25, Chicago, Illinois, United States).

Results

A total of 76 patients from eight centers were initially identified during the study period. The number of patients contributed by each center was 32, 31, 11, nine, three, three, two, and one. Four patients (21%) were excluded alternative indication of diffuse esophageal spasm (2/19), and lack of documented ESS (2/19) (► Fig. 1). Therefore, 73 patients (63.0% female, mean age 49.7 years) with a median follow-up time of 79.5 months (IQR 73.9–82.6) were analyzed. Baseline demographic and clinical information are reported in ► Table 1. Preoperative diagnoses were achalasia type I (16 patients, 21.9%), type 2 (15 patients, 20.6%), type 3 (4 patients, 5.5%), and achalasia of unspecified type (38 patients, 52.1%). Six patients (8.2%) had a sigmoid-shaped esophagus. Twenty-three patients (31.5%) had undergone prior treatment, three of which underwent multiple interventions. These treatments included 21 pneumatic dilation (28.8%), four botulinum toxin injection (5.5%), and two Heller myotomy (2.7%). The mean baseline ESS was 7.1 ± 2.3 . All procedures resulted in successful completion of the myotomy. Anterior orientation was used in sixty-three (86.3%) of cases. The majority of myotomies were partial-thickness (52 [69.9%]) compared to 22 (30.1%) full-thickness. Mean esophageal and gastric myotomy length was 9.5 ± 3.2 cm and 2.7 ± 1.6 cm, respectively. A total of six AEs occurred (8.2%), including one cardiac arrhythmia (severe), one delayed bleed (moderate), one esophageal leak (severe), and three mucosotomies (all mild).

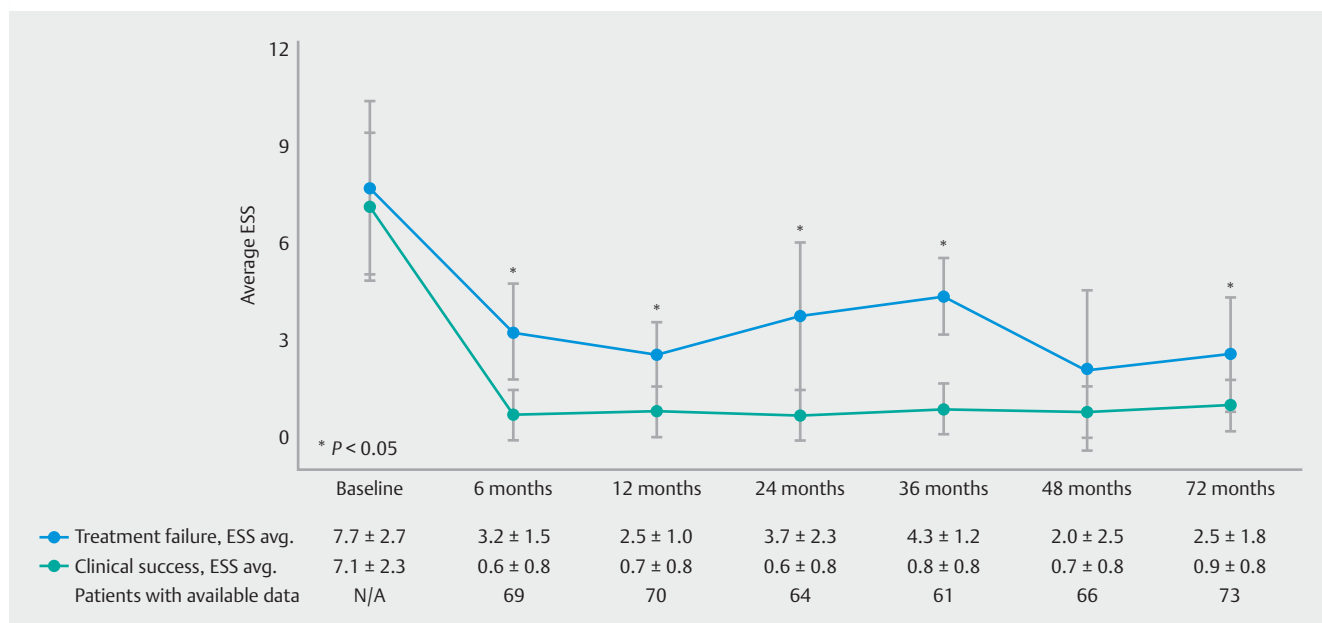
At 6 years, clinical success was noted in 89% (65/73) with a 95% confidence interval ranging from 82 to 96%. Not all patients had follow-up data available at the pre-specified interval follow-up times. The average number of follow-up visits per patient was 5.5 ± 1.2 visits. Three patients had two follow-up visits



► Fig. 1 Flow diagram of study design and patient identification. DES, diffuse esophageal spasm; ESS, Eckardt symptom score.

documented due to unavailability of records. ESS was carried forward from the most recent follow-up to calculate interval success rates of 96% (70/73), 94% (69/73), 93% (68/73) and 92% (67/73) at 6, 12, 24, and 48 months, respectively.

In subgroup analysis of patients who achieved remission by 6 months, the clinical success rate at 6 years increased to 95.5%. Three of eight patients failed within the first 6 months and average ESS was higher in the treatment failure cohort 6 months post-procedure (3.2 vs 0.6, $P=0.007$). This persisted for most of the follow-up duration (► Fig. 2). Achalasia subtype was also slightly different between the two groups. Patients who experienced treatment failure were more likely to have a diagnosis of type I achalasia (75% vs. 15.4%, $P=0.005$) but otherwise showed similar demographic, procedural, and clinical characteristics to those with clinical success (► Table 2). Clinical char-



► Fig. 2 Average Eckardt symptom score (ESS) in patients with clinical failure (black line) and clinical success (gray line) with standard deviation as error bars. Significant differences are seen as early as 6 months post-procedure.

► **Table 1** Baseline and peri-procedural characteristics.

	Patients with available data N=73 unless specified	Overall (n 73)
Age, years (mean ± SD)		49.7 ± 17.4
BMI, kg/m ² (mean ± SD)	37	26.5 ± 12.4
Female, no. (%)		46 (63.0)
Disease Classification		
▪ Type 1		16 (21.9)
▪ Type 2		15 (20.6)
▪ Type 3		4 (5.5)
Unspecified		38 (52.1)
Any prior therapy, no. (%)		23 (31.5)
Pneumatic dilation, no. (%)		21 (28.8)
Botox, no. (%)		4 (5.5)
Heller myotomy, no. (%)		2 (2.7)
Sigmoidal esophageal shape, no. (%)	72	6 (8.2)
HRM IRP, mm Hg (mean ± SD)	25	32.5 ± 14.2
HRM resting pressure, mmHg (mean ± SD)	45	41.2 ± 20.0
Pre-poem Eckhart score, mean ± SD	71	7.1 ± 2.3
Anterior orientation of myotomy, no. (%)	67	63 (86.3)
Full-thickness LES myotomy, no. (%)		22 (30.1)
Esophageal myotomy length, cm (mean ± SD)		9.5 ± 3.2
Gastric myotomy length, cm (mean ± SD)	71	2.5 ± 0.8
Patients with adverse events, no. (%)		6 (8.2)
Follow-up time, months, median (IQR)	50	79.5 (73.9 – 82.6)

HRM, high-resolution manometry; IRP, integrated relaxation pressure; LES, lower esophageal sphincter; IQR, interquartile range; PPI, proton pump inhibitor.

acteristics of patients who experienced clinical failure (8/73 (11%)) are shown in ► **Table 3**.

Symptomatic reflux was reported by 23 patients (31.5%) at 6-year follow-up with a similar number (23 [31.5%]) taking daily PPIs. Six patients (8.2%) were using PPIs intermittently and 44 (60.3%) were not on any PPI therapy at last follow-up. Endoscopy information was available in 60 cases; however, the majority were performed within 3 years of the original procedure (average 1.7 ± 1.4 years post-procedure). Esophagitis was pres-

► **Table 2** Comparison of baseline and peri-procedural characteristics of patients who experienced clinical response versus clinical failure.

	Clinical success (ESS ≤ 3) n = 65	Clinical failure (ESS > 3) n = 8
Age, years (mean ± SD)	50.6 ± 18.0	42.4 ± 10.1
BMI, kg/m ² (mean ± SD)	26.3 ± 12.6	28.3 ± 11.6
Female, no. (%)	41 (63.1)	5 (62.5)
Disease Classification		
Type 1	10 (15.4) ¹	6 (75.0) ¹
Type 2	14 (21.5)	1 (12.5)
Type 3	4 (6.2)	0 (0.0)
Unspecified	37 (56.9)	1 (12.5)
Any prior therapy, no. (%)	22 (33.9)	1 (12.5)
Pneumatic dilation, no. (%)	20 (30.8)	1 (12.5)
Botox, no. (%)	4 (6.2)	0 (0.0)
Heller myotomy, no. (%)	2 (3.1)	0 (0.0)
Sigmoidal esophageal shape, no. (%)	6 (9.2)	0 (0.0)
Pre-POEM HRM, mean ± SD		
IRP, mmHg	32.4 ± 15.1	33.1 ± 9.2
Resting pressure, mmHg	41.2 ± 20.1	41.4 ± 21.1
Pre-POEM ESS, mean ± SD	7.1 ± 2.3	7.7 ± 2.7
Anterior orientation of myotomy, no. (%)	57 (93.4)	6 (100.0)
Full thickness LES myotomy, no. (%)	18 (27.7)	4 (50.0)
Esophageal myotomy length, cm (mean ± SD)	9.5 ± 3.3	8.9 ± 2.1
Gastric myotomy length, cm (mean ± SD)	2.5 ± 0.8	2.7 ± 0.8
Patients with adverse events, no. (%)	16 (24.6)	0 (0.0)
Follow up time, months, median (IQR)	76.9 (73.9–82.2)	81.6 (74.7–89.1)
Pre-POEM HRM, mmHg (mean ± SD)		
IRP, mmHg	11.4 ± 7.8	16.7 ± 14.2
Resting pressure, mmHg	18.1 ± 9.1	14.1 ± 7.5

ESS, Eckardt Symptom Score; HRM, high-resolution manometry; IRP, integrated relaxation pressure; LES, lower esophageal sphincter; IQR, interquartile range; PPI, proton pump inhibitor; SD, standard deviation.

¹ P ≤ 0.05.

ent in 20 cases (28.3%) with 13 grade A, 3 grade B, one grade D, and three unknown grading as defined by the Los Angeles Classification System.

► **Table 3** Demographic and clinical information of patients who experienced clinical failure.

	Age (y)	Gender	Achalasia Subtype	Eckardt Score (pre, post)	HRM IRP, mm Hg (pre, post)	Response at 6 months?	Time of failure	Further treatment	Symptomatic improvement
1	33	Female	Type I	5, 4	30.0, 36.0	–	6 months	Conservative management	+
2	50	Male	Type I	6, 5	23.4, 6.6	–	6 months	Conservative management	–
3	61	Male	Type I	6, 4	Na	–	6 months	Conservative management	+
4	54	Female	Type II	7, 1	33.5, 11.7	+	12 months	Pneumatic dilation	+
5	25	Female	Type II	11, 3	45.4, 18.7	+	24 months	Pneumatic dilation	+
6	42	Female	Type I	11, 2	43.5, 5.3	+	36 months	Pneumatic dilation	+
7	52	Male	Type I	Na, 4	Na	Na	6 years	Conservative management	NA
8	37	Female	Unspecified	Na, 6	Na	Na	6 years	Pneumatic dilation	+

HRM, high-resolution manometry; IRP integrated relaxation pressure; NA, data not available.

► **Table 4** Gastroesophageal reflux after POEM in patients with clinical response versus clinical failure.

	Overall n = 73	Clinical success (ESS ≤ 3) n = 65	Clinical failure (ESS > 3) n = 8
Symptomatic reflux at last follow-up, no. (%)	27/72 (37.5)	25/64 (39.1)	2/8 (25.0)
PPI use at last follow up, no. (%)	29 (39.7)	27 (41.5)	2 (25.0)
Daily	23 (31.5)	22 (33.9)	1 (12.5)
Occasionally	6 (8.2)	5 (7.7)	1 (12.5)
None	44 (60.3)	38 (58.5)	6 (75.0)
Esophagitis on EGD, no. (%)	20/65 (30.8)	17/57 (29.8)	3/3 (100.0)

EGD, esophagogastroduodenoscopy; ESS, Eckardt Symptom Score; PPI, proton pump inhibitor.

Discussion

This is the first study examining POEM outcomes at 6 years and we have shown a robust and durable clinical response in this patient cohort. A clinical success rate of 89% is consistent with existing 3- to 5-year data ranging from 83% to 90% [3, 25, 28–30]. While 6-year data have not been previously published, a handful of groups have reported retrospective 5-year data from individual centers. In North America, Stravapoulos et al. reported a 5-year success rate of 90% in 49 patients (abstract) and Teitelbaum et al. 83% in 29 patients [28, 30]. Li et al. reported an 87% success rate in 47 patients with follow-up ranging from 4 to 5 years from a single center in Asia [29].

In our cohort, significant differences in average ESS emerged as early as 6 months post-procedure and over 95% of patients with clinical success at 6 months remained in remission for the duration of follow-up. As a point of comparison, laparoscopic Heller myotomy remission rates after 5 years vary from 57% to 88% but studies directly comparing long-term

outcomes with POEM are not available, given the novelty of the procedure, variability in study design, and limited randomized data [31–33]. Our results suggest that long-term effectiveness is comparable to conventional therapy based on historic data, but further studies are certainly needed.

Type I achalasia was the sole clinical factor associated with clinical failure (OR 10.8, $P < 0.001$). However, the high number of patients with unspecified achalasia subtype in this cohort makes inferring the clinical significance of this finding difficult and limits generalizability. In larger series, POEM has been shown to be effective across all three manometric subtypes [34]. Type III achalasia has been least responsive to traditional therapy, but POEM is thought to be particularly advantageous as it allows for customization and lengthening of the myotomy [35, 36]. All four patients with type III achalasia in this cohort were treated successfully. In these patients, average esophageal and gastric myotomy lengths were 2.3 ± 1.0 and 7.0 ± 3.6 cm, respectively. Further assessment of the impact of achalasia

subtype on clinical outcome was limited by a high number of unclassified diagnoses (38 patients [52.1%]) attributed to delayed adoption of high-resolution manometry as the first procedures were performed in early 2012.

Other than achalasia subtype, failure and success groups showed similar clinical and procedural characteristics. Outcome was notably independent of any prior treatment (OR 3.58, 95%CI 0.41–30.97), which is consistent with prior studies suggesting POEM is effective in patients who have failed previous endoscopic and surgical interventions. Studies report remission rates of 75% to 100% for patients with prior myotomy and 87% to 100% with prior PD but are limited by follow-up length of less than 1 year [7,37–40]. Two of two patients (100%) with prior surgical myotomy and 20 of 21 (95%) with prior PD had sustained response at 6 years, supporting the role of POEM as salvage therapy in previously treating patients.

Pathologic gastroesophageal reflux (GER) remains a critical disadvantage of POEM in this study with over one-third of patients reporting symptomatic reflux (37.5%) and a similar number on daily PPI therapy (31.5%). Esophagitis was noted in 28% of individuals who underwent endoscopy (► **Table 4**). Evaluation with endoscopy and pH monitoring was typically performed in the early postoperative period, but objective, long-term data were not available for the vast majority of patients. POEM is typically performed at tertiary centers where routine follow-up may involve extra travel and cost for patients, but the lack of objective reflux data highlights significant variability in post-procedure surveillance at each center. In a recent randomized trial comparing POEM to laparoscopic Heller myotomy with rigorous post-procedure monitoring, 30% of POEM patients had abnormal esophageal pH exposure at 24 months [26]. While objective pH exposure data were not available in our cohort, the symptomatic reflux rates and PPI use at 6 years are consistent with this. Determining the optimal approach to iatrogenic GER remains an area of ongoing investigation.

The limitations of this study include its retrospective design and reliance on ESS as the primary outcome. While ESS remains the gold standard in current literature and achalasia trials, a patient with a score of 3 (defined as clinical success) may still be experience dysphagia on a daily basis. Using the score as the sole indicator of clinical success also makes it difficult to determine if failure was due to true clinical failure or pseudoachalasia secondary to reflux. In future studies, consideration should be given to additional, objective evaluation of disease activity using other data like HRM, bolus retention time, and quality of life measurements. It is also important to note that this cohort represents some of the earliest patients to undergo POEM in these centers, which resulted in significant variation in procedural volume and half of the centers contributing fewer than 10 cases. These limited samples and selection bias (including self-selection by patients and operator case selection) may limit generalizability to current practice. Data that were not available during retrospective chart review also were excluded from comparisons, which limits external and internal validity.

Conclusions

In conclusion, this international, multicenter study reports the longest follow-up of a POEM cohort to date and shows enduring symptomatic relief. Sustained clinical response was noted in 89% of patients regardless of prior treatment and, if in clinical remission at 6 months, the probability of response at 6 years was even higher. This information contributes to the limited body of literature regarding true long-term data as POEM adoption increases around the world. GER remains a common occurrence that continues to impact patients many years after their procedure, and further investigation is required to establish standardized long-term surveillance and management.

Competing interests

Dr. N. Thosani is a consultant for Boston Scientific, Medtronic, Endogastric Solutions, and Pentax of America; a speaker for Abbvie, and receives royalties from UpToDate. Dr. M.A. Khashab is a consultant for Boston Scientific, Medtronic and Olympus. Dr. Alessandro Repici MD -Boston consulting fee, speaker fee, research grant. Fujifilm advisory board speaker fee. ERBE advisory board consulting fee. EndoKey advisory board. EndoStart advisory board. Medtronic research grant, consulting fee, advisory board. Dr. Sachin Wani is a Consultant for Boston Scientific, Medtronic, Cernostics and Interpace. Supported by the University of Colorado Department of Medicine Outstanding Early Scholars Program. All remaining authors declare they have nothing to disclose.

References

- [1] Boeckstaens GE, Zaninotto G, Richter JE. Achalasia. *Lancet* 2014; 383: 83–93
- [2] Pasricha PJ, Hawari R, Ahmed I et al. Submucosal endoscopic esophageal myotomy: a novel experimental approach for the treatment of achalasia. *Endoscopy* 2007; 39: 761–764
- [3] Inoue H, Minami H, Kobayashi Y et al. Per-oral endoscopic myotomy (POEM) for esophageal achalasia. *Endoscopy* 2010; 42: 265–271
- [4] Parsa N, Khashab MA. POEM in the treatment of esophageal disorders. *Curr Treat Options Gastroenterol* 2018; 16: 27–40
- [5] Evensen H, Kristensen V, Larssen L et al. Outcome of per-oral endoscopic myotomy (POEM) in treatment-naive patients. A systematic review. *Scand J Gastroenterol* 2019; doi:10.1080/00365521.2018.1549271
- [6] Familiari P, Gigante G, Marchese M et al. Per-oral Endoscopic myotomy for esophageal achalasia: outcomes of the first 100 patients with short-term follow-up. *Ann Surg* 2016; 263: 82–87
- [7] Ling T, Guo H, Zou X. Effect of per-oral endoscopic myotomy in achalasia patients with failure of prior pneumatic dilation: A prospective case-control study. *J Gastroenterol Hepatol* 2014; 29: 1609–1613
- [8] Ramchandani M, Reddy DN, Darisetty S et al. Per-oral endoscopic myotomy for achalasia cardia: Treatment analysis and follow up of over 200 consecutive patients at a single center. *Dig Endosc* 2016; 28: 19–26
- [9] Sharata AM, Dunst CM, Pescarus R et al. Per-oral endoscopic myotomy (POEM) for esophageal primary motility disorders: analysis of 100 consecutive patients. *J Gastrointest Surg* 2015; 19: 161–170
- [10] Von Renteln D, Fuchs K, Fockens P et al. Per-oral endoscopic myotomy for the treatment of achalasia: an international prospective multicenter study. *Gastroenterology* 2013; 145: 309–311.e3

- [11] von Renteln D, Inoue H, Minami H et al. Per-oral endoscopic myotomy for the treatment of achalasia: a prospective single center study. *Am J Gastroenterol* 2012; 107: 411–417
- [12] Ellis FG. The natural history of achalasia of the cardia abridged. *Proc R Soc Med* 1960; 53: 663–666
- [13] Salvador R, Voltarel G, Savarino E et al. The natural history of achalasia: Evidence of a continuum – “The evolutive pattern theory”. *Dig Liver Dis* 2018; 50: 342–347
- [14] Guo H, Yang H, Zhang X et al. Long-term outcomes of per-oral endoscopic myotomy for patients with achalasia: a retrospective single-center study. *Dis Esophagus* 2017; 30: 1–6
- [15] Hungness ES, Sternbach JM, Teitelbaum EN et al. Per-oral endoscopic myotomy (POEM) after the learning curve: durable long-term results with a low complication rate. *Ann Surg* 2016; 264: 508–517
- [16] Martinek J, Svecova H, Vackova Z et al. Per-oral endoscopic myotomy (POEM): mid-term efficacy and safety. *Surg Endosc* 2018; 32: 1293–1302
- [17] Kumbhari V, Familiari P, Bjerregaard NC et al. Gastroesophageal reflux after per-oral endoscopic myotomy: a multicenter case-control study. *Endoscopy* 2017; 49: 634–642
- [18] Arevalo G, Sippey M, Martin-Del-Campo LA et al. Post-POEM reflux: who's at risk? *Surg Endosc* 2019; doi:10.1007/s00464-019-07086-1
- [19] Haito-Chavez Y, Inoue H, Beard KW et al. Comprehensive Analysis of adverse events associated with per oral endoscopic myotomy in 1826 patients: an international multicenter study. *Am J Gastroenterol* 2017; 112: 1267–1276
- [20] Chen Y-I, Inoue H, Ujiki M et al. An international multicenter study evaluating the clinical efficacy and safety of per-oral endoscopic myotomy in octogenarians. *Gastrointest Endosc* 2018; 87: 956–961
- [21] Brewer Gutierrez OI, Moran R, Familiari P et al. Long-term outcomes of per-oral endoscopic myotomy in achalasia patients with a minimum follow-up of 4 years: a multicenter study. *Gastrointest Endosc* 2018; 87: AB564–AB565
- [22] Cotton PB, Eisen GM, Aabakken L et al. A lexicon for endoscopic adverse events: report of an ASGE workshop. *Gastrointest Endosc* 2010; 71: 446–454
- [23] Eckardt VF, Aignherr C, Bernhard G. Predictors of outcome in patients with achalasia treated by pneumatic dilation. *Gastroenterology* 1992; 103: 1732–1738
- [24] Taft TH, Carlson DA, Triggs J et al. Evaluating the reliability and construct validity of the Eckardt symptom score as a measure of achalasia severity. *Neurogastroenterol Motil* 2018; 30: e13287
- [25] Peng L, Tian S, Du C et al. Outcome of per-oral endoscopic myotomy (POEM) for treating achalasia compared with laparoscopic Heller myotomy. *Surg Laparosc Endosc Percutan Tech* 2017; 27: 60–64
- [26] Werner YB, Hakanson B, Martinek J et al. Endoscopic or surgical myotomy in patients with idiopathic achalasia. *N Engl J Med* 2019; 381: 2219–2229
- [27] Kahrilas PJ, Bredenoord AJ, Fox M et al. The Chicago Classification of esophageal motility disorders, v3.0. *Neurogastroenterol Motil Off J Eur Gastrointest Motil Soc* 2015; 27: 160–174
- [28] Teitelbaum EN, Dunst CM, Reavis KM et al. Clinical outcomes five years after POEM for treatment of primary esophageal motility disorders. *Surg Endosc* 2018; 32: 421–427
- [29] Li Q-L, Wu Q-N, Zhang X-C et al. Outcomes of per-oral endoscopic myotomy for treatment of esophageal achalasia with a median follow-up of 49 months. *Gastrointest Endosc* 2018; 87: 1405–1412.e3
- [30] Stavropoulos SN, Modayil RJ, Zhang X et al. Tu1146 per oral endoscopic myotomy (POEM) For achalasia: long term outcomes from a large prospective single-center US series. *Gastrointest Endosc* 2018; 87: AB540–AB541
- [31] Ujiki MB, Yetasook AK, Zapf M et al. Per-oral endoscopic myotomy: A short-term comparison with the standard laparoscopic approach. *Surgery* 2013; 154: 893–900
- [32] Bhayani NH, Kurian AA, Dunst CM et al. A comparative study on comprehensive, objective outcomes of laparoscopic Heller myotomy with per-oral endoscopic myotomy (POEM) for achalasia. *Ann Surg* 2014; 259: 1098–1103
- [33] Teitelbaum EN, Rajeswaran S, Zhang R et al. Per-oral esophageal myotomy (POEM) and laparoscopic Heller myotomy produce a similar short-term anatomic and functional effect. *Surgery* 2013; 154: 885–891; discussion 891–892
- [34] Inoue H, Sato H, Ikeda H et al. Per-oral endoscopic myotomy: a series of 500 patients. *J Am Coll Surg* 2015; 221: 256–264
- [35] Kim WH, Cho JY, Ko WJ et al. Comparison of the outcomes of per-oral endoscopic myotomy for achalasia according to manometric subtype. *Gut Liver* 2017; 11: 642–647
- [36] Kumbhari V, Tieu AH, Onimaru M et al. Per-oral endoscopic myotomy (POEM) vs laparoscopic Heller myotomy (LHM) for the treatment of Type III achalasia in 75 patients: a multicenter comparative study. *Endosc Int Open* 2015; 3: E195–E201
- [37] Tyberg A, Seewald S, Sharaiha RZ et al. A multicenter international registry of redo per-oral endoscopic myotomy (POEM) after failed POEM. *Gastrointest Endosc* 2017; 85: 1208–1211
- [38] Li Q-L, Yao L-Q, Xu X-Y et al. Repeat per-oral endoscopic myotomy: a salvage option for persistent/recurrent symptoms. *Endoscopy* 2016; 48: 134–140
- [39] Ngamruengphong S, Inoue H, Ujiki MB et al. Efficacy and safety of per-oral endoscopic myotomy for treatment of achalasia after failed Heller myotomy. *Clin Gastroenterol Hepatol Off Clin Pract J Am Gastroenterol Assoc* 2017; 15: 1531–1537.e3
- [40] Fumagalli U, Rosati R, De Pascale S et al. Repeated Surgical or endoscopic myotomy for recurrent dysphagia in patients after previous myotomy for achalasia. *J Gastrointest Surg* 2016; 20: 494–499