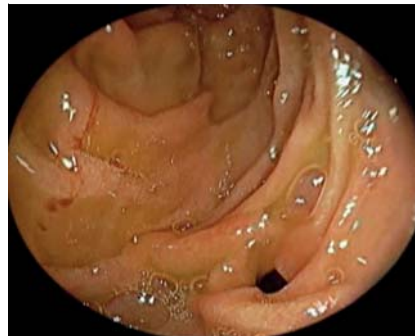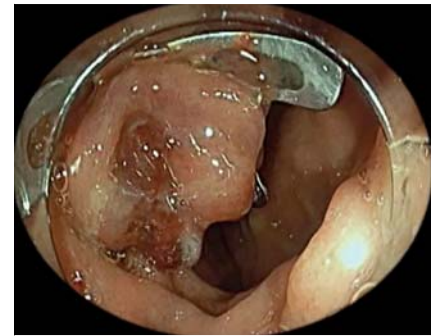


Endoscopic closure of duodenocolic fistula by using an over-the-scope clip

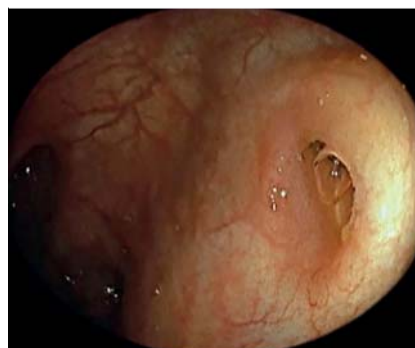A 61-year-old woman was admitted to the hospital because of persistent vomiting and diarrhea for the past year. In esophagogastroduodenoscopy performed for the etiology of these symptoms, a fistula was seen in the descending part of the duodenum without any erosion and ulceration. The fistula mouth was about 8 mm wide, and endoscopy was used to view the transverse colon from the fistula mouth (▶ **Fig. 1**). Colonoscopy revealed the fistula mouth in the hepatic flexure and diverticulum nearby (▶ **Fig. 2**). No additional pathology such as tumors or ulcers was seen in the duodenum and colon. During esophagogastroduodenoscopy, the fistula on the descending part of the duodenum was closed by performing suction and using an over-the-scope (OTS) clip (12/6/t; Ovesco Endoscopy AG, Tübingen, Germany) (▶ **Fig. 3**; ▶ **Video 1**). When the fistula mouth was checked with colonoscopy, it was observed to be closed (▶ **Fig. 4**). Oral intake started the day after the procedure and there were no problems. As a result, in selected cases, an OTS clip is an effective and safe method in full-thickness closure of transmural defects such as duodenocolic fistula [1–4].



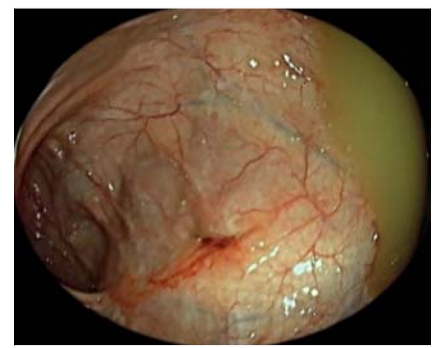
▶ **Fig. 1** Esophagogastroduodenoscopy and fistula in the descending part of the duodenum.



▶ **Fig. 3** Final view of the duodenocolic fistula after placement of the over-the-scope clip (12/6t).



▶ **Fig. 2** Colonoscopy and fistula mouth in the hepatic flexure.



▶ **Fig. 4** Colonoscopy and closed view of the fistula mouth in the hepatic flexure.

Endoscopy_UCTN_Code_CCL_1AB_2AC_3AF

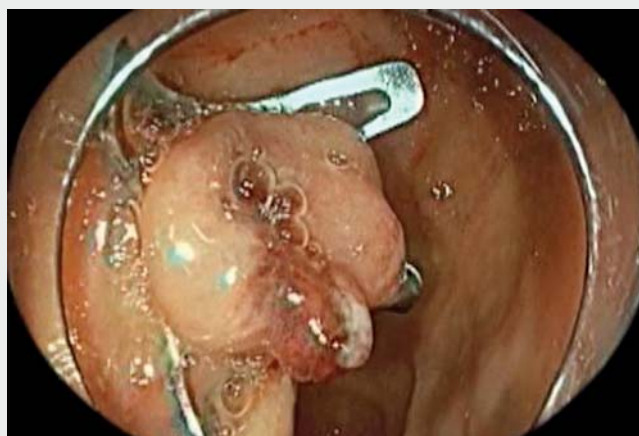
Competing interests

The authors declare that they have no conflict of interest.

The author

Erol Cakmak 

Department of Gastroenterology, Cumhuriyet University Faculty of Medicine, Sivas, Turkey



▶ **Video 1** Duodenocolic fistula treated with over-the-scope clip (12/6t).



Corresponding author

Erol Cakmak, MD

Cumhuriyet University Faculty of Medicine,
Department of Gastroenterology, Sivas,
58140, Turkey
Fax: +90-346-2580024
drecakmak@hotmail.com

References

- [1] Ocana RS, Herbozo CC, Marrero AF et al. Endoscopic clip closure of a duodenocolic fistula secondary to a migrated biliary stent. *Endoscopy* 2016; 48: 230–231
- [2] Mizrahi I, Eltawil R, Haim N et al. The clinical utility of over-the-scope clip for the treatment of gastrointestinal defects. *J Gastrointest Surg* 2016; 20: 1942–1949

- [3] Mennigen R, Colombo-Benkmann M, Senninger N et al. Endoscopic closure of post-operative gastrointestinal leakages and fistulas with the over-the-scope clip (OTSC). *J Gastrointest Surg* 2013; 17: 1058–1065
- [4] Manta R, Manno M, Bertani H et al. Endoscopic treatment of gastrointestinal fistulas using an over-the-scope clip (OTSC) device: case series from a tertiary referral center. *Endoscopy* 2011; 43: 545–548

Bibliography

Endoscopy 2022; 54: E423–E424
DOI 10.1055/a-1559-1830
ISSN 0013-726X
published online 8.9.2021
© 2021. Thieme. All rights reserved.
Georg Thieme Verlag KG, Rüdigerstraße 14,
70469 Stuttgart, Germany

ENDOSCOPY E-VIDEOS

<https://eref.thieme.de/e-videos>



Endoscopy E-Videos is an open access online section, reporting on interesting cases and new techniques in gastroenterological endoscopy. All papers include a high quality video and all contributions are freely accessible online. Processing charges apply (currently EUR 375), discounts and waivers acc. to HINARI are available.

This section has its own submission website at
<https://mc.manuscriptcentral.com/e-videos>