Article published online: 2021-09-08

Endoscopic submucosal dissection of high-grade dysplasia recurrence in ulcerative colitis using a multitraction technique

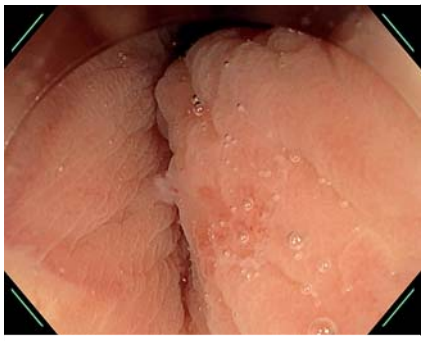

▶ **Fig. 1** In a 71-year-old man who 3 years ago had undergone ESD for high-grade dysplasia and focal intramucosal carcinoma in the left colon, high-grade dysplasia recurrence was detected in the area previously treated.

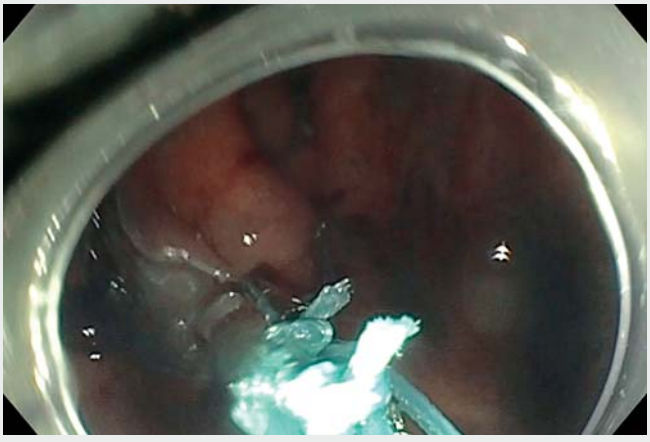

Video 1 Endoscopic submucosal dissection of high-grade dysplasia in a 71-year-old patient with long-standing ulcerative colitis, using a multitraction technique.

Endoscopic submucosal dissection (ESD) is the gold standard for removing superficial tumor in the digestive tract [1]. Dyplasia in inflammatory bowel disease (IBD) patient is a major concern due to the risk of neoplastic progression. ESD for dysplasia in IBD is feasible, but long-term follow-up data are lacking especially for the management of dysplasia recurrence in an area previously treated by ESD [2–5].

We report the case of a 71-year-old man with a history of long-standing ulcerative colitis who underwent ESD for high-grade dysplasia and focal intramucosal carcinoma in the left colon. The resection was incomplete with dysplasia in the lateral margin. Three years later, recurrence of high-grade dysplasia was detected in the area previously treated (▶ **Fig. 1**). Another ESD was decided upon (▶ **Video 1**). After marking of the lesion and circumferential incision, a new multitraction technique was employed using a device made of three intertwined loops (▶ **Fig. 2**). Each of the loops was attached to an edge of the lesion, then the entire device was attached to the opposite wall, facilitating the exposure of the submucosal area and enabling en bloc resection despite intense fibrosis (▶ **Fig. 3**). We wanted to extend the dissection to the upper pole of the lesion because of the suspicion of a serrated lesion. However, a small perforation was made so we stopped the procedure as the diagnosis was not certain. The defect was closed and the patient discharged the day after without any adverse event. The pathology report confirmed complete en bloc resection of a high-grade dysplasia, with chronic inflammatory changes with focal low-grade dysplasia on the area not removed. Our multidisciplinary team decided on endoscopic surveillance.

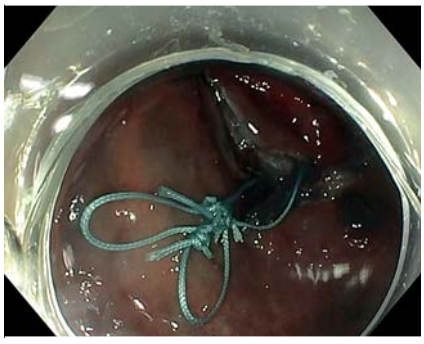

▶ **Fig. 2** A new multitraction technique was employed using a device made of three intertwined loops.

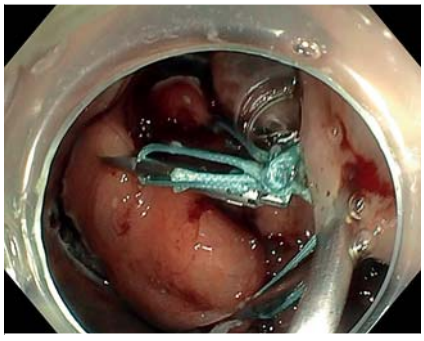

▶ **Fig. 3** Each loop was attached to an edge of the lesion, then the entire device was attached to the opposite wall, thus facilitating the exposure of the submucosal area.

ESD is feasible in patients with IBD, even in a fibrotic area that has previously been resected, and can be facilitated by a multitraction technique. Patients with dysplasia should always be referred to a center of endoscopic expertise before colectomy is considered.

Endoscopy_UCTN_Code_TTT_1AQ_2AD

Competing interests

Clara Yzet has received speaker fees from Abbvie, Janssen, and Takeda. The remaining authors have no conflict of interest to declare.

The authors

Clara Yzet[1], Thomas Lambin[2,3], Pierre Lafeuille[2], Mathurin Fumery[1], Joanna Pofelski[4], Eddy Cotte[5], Mathieu Pioche[2,3]

1 Gastroenterology Unit, Amiens University Hospital, Université de Picardie Jules Verne, France
2 Gastroenterology and Endoscopy Unit, Pavillon L, Edouard Herriot Hospital, Lyon, France
3 Inserm U1032, Labtau, Lyon, France
4 Gastroenterology Unit, Centre Hospitalier Annecy Genevois, Epagny Metz-Tessy, France
5 Department of Gastrointestinal Surgery, Hospices Civils de Lyon, Université de Lyon, Centre Hospitalier Lyon-Sud, France

Corresponding author

Clara Yzet, MD
Service Hépato-Gastroentérologie, CHU Amiens Picardie, Rond Point du Pr Cabrol, 80054 Amiens, France
Clara.yzet@gmail.com

References

[1] Pimentel-Nunes P, Dinis-Ribeiro M, Ponchon T et al. Endoscopic submucosal dissection: European Society of Gastrointestinal Endoscopy (ESGE) Guideline. Endoscopy 2015; 47: 829–854
[2] Iacopini F, Saito Y, Yamada M et al. Curative endoscopic submucosal dissection of large nonpolypoid superficial neoplasms in ulcerative colitis (with videos). Gastrointest Endosc 2015; 82: 734–738
[3] Suzuki N, Toyonaga T, East J. Endoscopic submucosal dissection of colitis-related dysplasia. Endoscopy 2017; 49: 1237–1242
[4] Manta R, Zullo A, Telesca D-A et al. Endoscopic submucosal dissection for visible dysplasia treatment in ulcerative colitis patients: cases series and systematic review of literature. J Crohns Colitis 2021; 15: 165–168
[5] Matsumoto K, Oka S, Tanaka S et al. Long-term outcomes after endoscopic submucosal dissection for ulcerative colitis-associated dysplasia. Digestion 2021; 102: 205–215

Bibliography

Endoscopy 2022; 54: E433–E434
DOI 10.1055/a-1581-7361
ISSN 0013-726X
published online 8.9.2021

Georg Thieme Verlag KG, Rüdigerstraße 14, 70469 Stuttgart, Germany