

# Vacuum-Assisted Suction Drainage as a Successful Treatment Option for Postoperative Symptomatic Lymphoceles

## Vakuum-assistierte Saugdrainage als erfolgreiche Therapieoption für postoperative symptomatische Lymphozelen

### Authors

Mareike Franke<sup>1,2</sup>, Christian Saager<sup>1</sup>, Jan-Robert Kröger<sup>2</sup>, Jan Borggreffe<sup>2</sup>, Kersten Mückner<sup>1</sup>

### Affiliations

- 1 Diagnostic and Interventional Radiology, Klinik Dr. Hancken GmbH, Stade, Germany
- 2 Diagnostic and Interventional Radiology, Mühlenkreiskliniken, Minden, Germany

### Key words

symptomatic lymphocele, negative pressure therapy, drainage, interventional procedures

received 27.05.2021

accepted 27.07.2021

published online 14.10.2021

### Bibliography

Fortschr Röntgenstr 2022; 194: 384–390

DOI 10.1055/a-1586-3652

ISSN 1438-9029

© 2021. Thieme. All rights reserved.

Georg Thieme Verlag KG, Rüdigerstraße 14, 70469 Stuttgart, Germany

### Correspondence

Dr. Mareike Franke

Diagnostic and Interventional Radiology, Klinik

Dr. Hancken GmbH, Harsefelder Straße 8, 21680 Stade, Germany

Tel.: +49/41 41/97 15 51

mfr@hancken.de

### ZUSAMMENFASSUNG

**Ziel** Lymphozelen können innerhalb von Wochen oder sogar Monaten nach chirurgischen Eingriffen auftreten. Bleiben diese asymptomatisch, werden sie meist nicht diagnostiziert und heilen von selbst aus. Ein kleiner Prozentsatz der postoperativen Lymphozelen wird jedoch symptomatisch mit Schmerzen, Infektionszeichen oder Kompression von benachbarten Strukturen, was eine Therapie erfordert. Viele verschiedene Behandlungsmethoden sind in der Literatur beschrieben, wie Drainageeinlage mit oder ohne Sklerotherapie, Embolisation von Lymphgefäßen oder chirurgische Operation mit Laparoskopie oder Laparotomie. Inspiriert durch Berichte über postoperative Saugdrainagen, die eine Ausbildung von Lymphozelen verhindern, haben wir ein einfaches Protokoll für eine Vakuum-assistierte Saugdrainage von symptomati-

schen Lymphozelen entwickelt, welches sich bei uns bewährt hat. Dieses Protokoll möchten wir im Rahmen dieser Studie vorstellen.

**Material und Methoden** Von 2008–2020 wurden 35 Patienten mit symptomatischen postoperativen Lymphozelen mit unserer Vakuum-assistierte Saugdrainage behandelt (insgesamt 39 Lymphozelen). Ein vorangegangener chirurgischer Eingriff fand zwischen 8 und 572 Tage zuvor statt. Die Diagnose wurde durch eine Untersuchung des Aspirats biochemisch und zytologisch bestätigt. Die klinischen Daten und Bilddaten wurden gesammelt und retrospektiv analysiert.

**Ergebnisse** Insgesamt wurden 43 Saugdrainagen unter CT-Kontrolle eingebracht. Der technische Erfolg lag bei 100 %. Ein Patient starb leider aufgrund einer vorbestehenden Lungenarterienembolie, einer Sepsis und einem schlechten Allgemeinzustand. Bei 94,8 % der Lymphozelen konnte eine komplette Ausheilung erreicht werden. Vier Lymphozelen benötigten eine zweite Drainage aufgrund eines Rezidivs oder einer Drainagedislokation. Zwei Lymphozelen wurden letztendlich bei fehlender Ausheilung operiert. Die Komplikationsrate der Prozedur betrug 4,6 % (minor complications). Die mittlere Einliegedauer der Drainagen betrug 8–9 Tage.

**Schlussfolgerung** Die positiven Effekte der Unterdrucktherapie in lokalen Wunden sind schon seit Langem untersucht. Diese positiven Effekte scheinen auch bei der Saugdrainage von symptomatischen Lymphozelen zu einer hohen Ausheilungsrate zu führen.

### Kernaussagen:

- Die Saugdrainage ist eine einfache und schnelle Methode zur Ausheilung von symptomatischen Lymphozelen in verschiedenen Körperlokalisationen.
- Wir glauben, dass dies durch die Kollabierung der Lymphozele und Verkleben der Lymphozelenwand zustande kommt.
- In den meisten Fällen konnte durch unsere Methode ein schnelles Abklingen der Beschwerden erreicht werden.

### ABSTRACT

**Purpose** Lymphoceles often occur within several weeks or even months after surgery. Mostly asymptomatic and therefore undiagnosed, they may be self-healing without any treatment. A small percentage of postoperative lymphoceles are symptomatic with significant pain, infection, or compression

of vital structures, thus requiring intervention. Many different treatment options are described in the literature, like drainage with or without sclerotherapy, embolization of lymph vessels, and surgical approaches with laparoscopy or laparotomy. Inspired by reports stating that postoperative suction drainage can prevent the formation of lymphoceles, we developed a simple protocol for vacuum-assisted drainage of symptomatic lymphoceles, which proved to be successful and which we would therefore like to present.

**Materials and Method** Between 2008 and 2020, 35 patients with symptomatic postoperative lymphoceles were treated with vacuum-assisted suction drainage (in total 39 lymphoceles). The surgery that caused lymphocele formation had been performed between 8 and 572 days before. All lymphoceles were diagnosed based on biochemical and cytologic findings in aspirated fluid. The clinical and imaging data were collected and retrospectively analyzed.

**Results** In total, 43 suction drainage catheters were inserted under CT guidance. The technical success rate was 100%. One patient died of severe preexisting pulmonary embolism, sepsis, and poor conditions (non-procedure-related death). In 94.8% of symptomatic lymphoceles, healing and total disappearance could be achieved. 4 lymphoceles had a

relapse or dislocation of the drainage catheter and needed a second drainage procedure. Two lymphoceles needed further surgery. The complication rate of the procedure was 4.6% (2/43, minor complications). The median indwelling time of a suction drainage catheter was 8–9 days (range: 1–30 days).

**Conclusion** The positive effects of negative pressure therapy in local wound therapy have been investigated for a long time. These positive effects also seem to have an impact on suction drainage of symptomatic lymphoceles with a high cure rate.

#### Key Points:

- Suction drainage of lymphoceles is an easy and successful method to cure symptomatic lymphoceles at various locations.
- We believe this to be due to the induction of cavity collapse and surface adherence.
- In most cases rapid clinical improvement could be obtained.

#### Citation Format

- Franke M, Saager C, Kröger J et al. Vacuum-Assisted Suction Drainage as a Successful Treatment Option for Postoperative Symptomatic Lymphoceles. *Fortschr Röntgenstr* 2022; 194: 384–390

## Introduction

Lymphoceles are collections of lymphatic fluid without a distinct epithelial lining. They typically occur after surgery in areas with an extensive lymphatic network and are most commonly seen in the retroperitoneum. Procedures such as prostatectomy, perineal resection for genitourinary malignancy, renal transplantation, vascular bypass procedures, and breast surgery have a relatively high risk of lymphocele formation [1] with a reported incidence of up to 32% [2–4]. Lymphoceles mostly occur within weeks up to many months after surgery [5]. Most of them are self-limiting and therefore undiagnosed [6]. Only 4–7% of lymphoceles become symptomatic [7] with several risk factors that have been reported to be associated with the development of symptoms such as number of lymph nodes removed, body-mass index, size of lymphoceles, and age [8]. Symptoms of lymphoceles can be pain, infection, lymphorrhoea, and compression of surrounding structures [4]. When causing deep vein thromboses and pulmonary embolism due to local compression of pelvic veins, they can cause devastating consequences for patients.

As lymphoceles tend to relapse, treatment may be difficult. Several different techniques for treatment have been described in the literature [1, 2, 9], including simple aspiration, drainage, instillation of sclerosing agents such as alcohol, povidone iodine and doxycycline, lymphatic embolization, and laparoscopic or open lymphocele marsupialization. The success rate of these therapies has been reported to be between 50% and 98% (reviewed in [1, 4]).

In our department the standard technique for dealing with symptomatic lymphoceles is vacuum-assisted suction drainage, which we believe to have several advantages: it is an easy, cost-

effective, and not painful procedure that can induce cavity collapse and surface adherence. The reported effects of negative pressure therapy on wound healing are an increase in local blood flow, stimulation of angiogenesis, formation of granulation tissue, stimulation of cell proliferation, removing of soluble healing inhibitors and bacterial load (even pus may be drained completely) [10]. Thus, we believe that vacuum-assisted suction drainage is a good option for the treatment of symptomatic lymphoceles. Therefore, we conducted this analysis regarding the success and complication rate and compared our results to the existing literature.

## Materials and Methods

All patients over 18 years who underwent vacuum-assisted suction drainage of symptomatic, postoperative lymphoceles during the years 2008–2020 were included in this study. During this time period, no other treatment methods for symptomatic lymphoceles (e. g., simple drainage without suction) were employed. The local PACS and RIS were interrogated as a source of data. Data retrieved for each patient included: age, sex, diagnosis, clinical condition, previous surgery, time span between previous surgery, a diagnosis of symptomatic lymphocele, CT imaging (including volume of lymphocele), success of vacuum-assisted suction drainage, number of drainage procedures, complication rate and indwelling time for the suction drain. Ethical approval for this study was obtained from the local ethics committee (*Ethikkommission der Medizinischen Fakultät der Ruhr-Universität Bochum, Sitz Ostwestfalen; Approval Number 2021–788*).

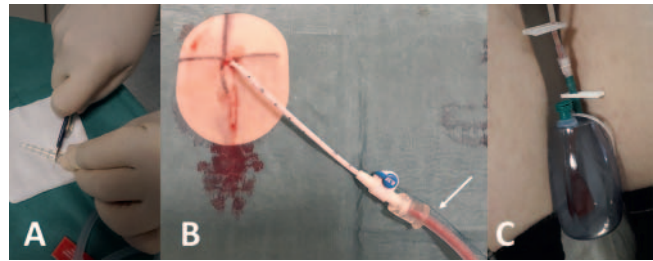
All drainage catheters were placed under local anesthesia and mild sedation (2–3 mg Midazolam i. v.) and CT guidance. Before the intervention, coagulation parameters were checked to make sure that there was no elevated risk for bleeding. In all cases thrombocytes were  $>50\,000/\mu\text{l}$  and INR  $<1.5$ . In cases of superinfection, antibiotics were administered.

Fully informed consent was obtained in all cases by the radiologist performing the drainage procedure with an explanation of the principles of the procedure, the resulting consequences, possible complications, and their potential solutions. For the procedure, the patient was placed either in a prone or a supine position. After a native CT planning scan and CT-guided marking of the puncture side on the skin, sterile draping and disinfection of the skin was performed. A contrast-enhanced CT scan for planning was only performed when we suspected the presence of dangerous vascular variants or varices, which could lead to further complications. Local anesthesia of the skin and puncture canal was then carried out. In the trocar technique, a needle-mounted 8.5 F drain (Resolve locking catheter, 15 cm, Merit Medical Systems Inc., South Jordan, Utah, USA) or a needle-mounted 8 F drain (Malecot direct puncture basket-drainage set [Malecot Direkt-punktions-Körbchen-Set, hydrophil], Sikamed, Wiehl, Germany), which is very suitable for small lymphoceles, was advanced into the lymphocele after skin puncture. After verification of the correct position of the drain in the lymphocele by removing the inner needle and aspiration, the drain was pushed further into the lymphocele (without needle) and the pigtail was unrolled and locked. The drainage catheter was then fixed at skin level by suture. A small amount of cystic fluid was aspirated for cytological and microbiological analysis. Then, the Redon container (PRIVAC 400 OP-System; vacuum 900 mbar) was prepared according to ► **Fig. 1** by cutting off the head of the cone of the tube (► **Fig. 1**) and was connected with the drainage catheter. The vacuum locks of the Redon container were removed, and lymph fluid was aspirated continuously. Sterile dressing of the drain was carried out afterwards.

The postprocedural management is recommended as follows: The drainage catheter should remain in place for at least 4 days with vacuum suction after output had ceased. The vacuum and the Redon container should be checked twice a day, i. e., this includes regular changes of the Redon container when full (to ensure continuous suction) and regular changes of the sterile dressing (at least every two days). Regular flushing of the drainage catheter with small amounts of sterile saline every day to avoid blocking of the catheter was recommended as well. This procedure could also be performed on an outpatient basis. Before removal of the catheter, CT imaging should be performed to make sure that the lymphocele is no longer visible.

## Results

Between 2008 and 2020, 35 patients with symptomatic postoperative lymphoceles were treated in our department. In total, 39 symptomatic lymphoceles occurred in these patients. The mean time interval between surgery and onset of symptoms was 71 days (ranging from 8 days to 572 days). Most patients



► **Fig. 1** Material preparation for connection of Redon tube and drainage catheter. **A** After cutting off the tip of the connective tube of Redon, it fits perfectly over the end of the drainage catheter **B**. You can see the suture of the locking mechanism (white arrow in **B**). **C** Shows Redon container (400 ml).

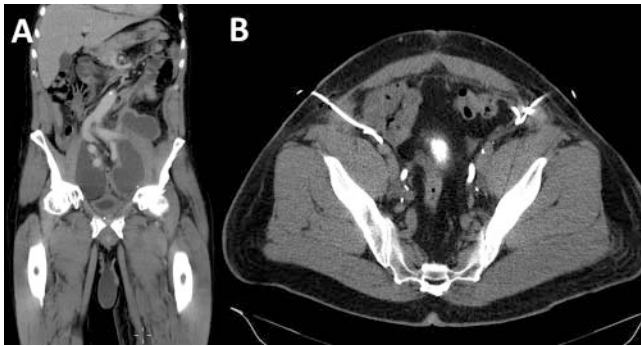► **Abb. 1** Vorbereitung des Materials für die Verbindung von Redon-Schlauch und Drainage **A**: Nach Zuschneiden des Redon-Universalverbinders passt dieser perfekt über das Drainageende **B**. Man kann die Fadensicherung der Drainage (zur Sicherung der Pigtail-Konfiguration) sehen (weißer Pfeil in **B**). **C** Diese Abb. zeigt die Redon-Flasche.

► **Table 1** Overview of patient characteristics and number and location within the patients.

► **Tab. 1** Übersicht der Patientencharakteristiken sowie der Anzahl und Seite innerhalb der Patienten.

number of patients	35
male	27
female	8
mean age	65 (range: 36–86)
previous surgery performed:	
▪ prostatectomy	24
▪ cystectomy	3
▪ gynecological tumor surgery	7
▪ cervical lymph node resection	1
number of treated symptomatic lymphoceles	39
number and location within the patients:	
▪ patients with single symptomatic lymphocele	30 (28 pelvic, 1 retroperitoneal, 1 cervical)
▪ patients with bilateral symptomatic lymphocele	1 (pelvic)
▪ patients with two ipsilateral symptomatic lymphoceles	2 (pelvic)
▪ patients with three ipsilateral symptomatic lymphoceles	1 (pelvic)

were male and had previous surgery due to prostatic carcinoma (for patient characteristics see ► **Table 1**). 30 patients had a single symptomatic lymphocele. One patient post-prostatectomy had two bilateral symptomatic lymphoceles that were drained simultaneously (see ► **Fig. 2**). In two patients, there were two ipsilateral



► **Fig. 2** Successful drainage catheter placement in a patient 43 days post-prostatectomy with symptomatic postoperative lymphoceles. **A** In total, three lymphoceles could be detected on CT scan. The third smaller lymphocele on the left side cranial to the two in the pelvis was assessed as non-symptomatic and was therefore not treated. **B** The CT image shows the result after double-sided drainage catheter placement in the lymphoceles neighboring the iliac vessels which causes total deflation of lymphocele cavities and immediate pain relief.

► **Abb. 2** Erfolgreiche Drainageeinlage in einen Patienten 43 Tage nach Prostatektomie bei symptomatischen Lymphozelen beidseits. **A** Insgesamt konnten 3 Lymphozelen in der CT-Untersuchung abgegrenzt werden. Die kleinste der 3 Lymphozelen außerhalb des kleinen Beckens links wurde als nichtsymptomatisch eingestuft und daher nicht drainiert. **B** Diese Abb. zeigt das Ergebnis nach beidseitiger Drainageeinlage in die Lymphozelen mit direkter Lagebeziehung zu den Iliakalgefäßen. Die Drainageeinlagen resultierten in einer vollständigen Deflation der Lymphzelen, was zu einer sofortigen Schmerzlinderung führte.

symptomatic lymphoceles in different locations that were drained. One patient had 3 ipsilateral symptomatic lymphoceles in different locations that occurred successively and therefore were drained successively.

Patients suffered from several different symptoms of lymphoceles (see ► **Table 2**). 27 patients had signs of infection. Since some patients had more than one symptomatic lymphocele, 29 lymphoceles had signs of superinfection. Three patients had additional deep vein thrombosis, with two developing pulmonary embolisms. Unfortunately, one patient died after placement of the drainage catheter due to pulmonary embolism (non-procedure-related death). Therefore, this case was excluded from statistical analysis. This patient had not only already suffered a severe pulmonary embolism but also a sepsis. Therefore, the drainage catheter was placed despite pulmonary embolism to remove the infected lymphocele and thus eliminate the underlying cause of infection.

Before the procedure, all patients received a CT or MRI scan in order to estimate the location and volume of the lymphocele according to the approximation formula [11, 12]: craniocaudal diameter × sagittal diameter × axial diameter × 0.5.

In total, 39 symptomatic lymphoceles were treated with 43 drainage catheters in 35 patients. 4 lymphoceles needed a second drainage because of relapse or dislocation of the drainage catheter. Diagnosis of lymphocele and superinfection was retro-

► **Table 2** Overview of clinical manifestation of symptomatic lymphoceles. Most patients had signs of infection. Many patients had additional complaints or manifestations like edema or deep vein thrombosis.

► **Tab. 2** Übersicht über die klinische Manifestation der Lymphozelen. Die meisten Patienten hatten Zeichen der Superinfektion. Viele Patienten hatten darüber hinaus noch weitere Beschwerden oder Manifestationen wie Ödeme oder Thrombosen.

symptoms	no. of patients
infection (fever, sepsis)	27
pain and/or edema	6
leg paresis	1
gastrointestinal dysfunction/disturbed transit due to local compression	1
some patients had additional symptoms:	
▪ deep vein thrombosis	2
▪ deep vein thrombosis and pulmonary embolism	2
▪ acute urinary retention	1

spectively confirmed on the basis of biochemical and cytologic findings in aspirated fluid.

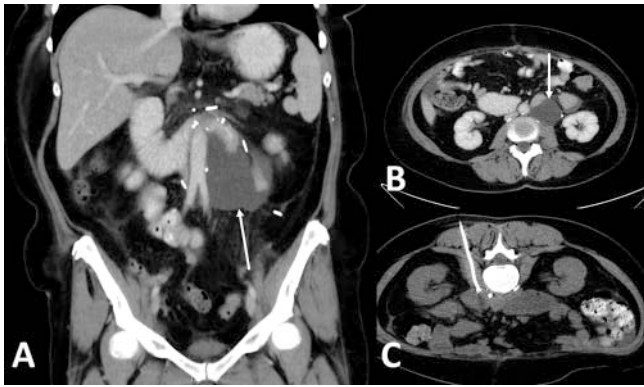All but two lymphoceles had a maximum diameter of > 5 cm. For these two very small lymphoceles, the basket-drainage catheter (Sikamed) was used, for the other larger lymphoceles the pig-tail drainage catheter (Merrit) was used. The mean volume of lymphoceles was 220 ml (range 9–1393 ml).

The technical success of 8–8.5 F drainage catheter placement was 100%. Quick improvement of (local) clinical symptoms of lymphocele could be achieved in all patients. The mean time interval with the drainage catheter in place was 8.5 days (ranging from 1 to 30 days). One patient died after drainage catheter placement due to a fatal preexisting pulmonary embolism on the basis of a deep vein thrombosis and sepsis and therefore was excluded from statistical analysis (non-procedure-related death). 4 lymphoceles needed a second drainage procedure due to relapse. In all 4 cases the time period with the drainage catheter in place was only 3 days for unknown reasons, which was relatively short and against our recommendation. In these cases, the time interval until the appearance of relapse was between 18 and 30 days.

The success rate of the procedure was 94.8%, with 37 of 39 lymphoceles being able to be cured completely with disappearance of lymphocele (see ► **Fig. 3**). In two patients (one with a cervical lymphocele after lymph node excision (see ► **Fig. 4**) and one with sepsis after prostatectomy), interdisciplinary discussion decided to perform surgery after 10 days of vacuum-assisted suction drainage with no tendency toward suspended output.

The complication rate was 4.6% (2/43). Both complications were minor complications [13] and according to the CIRSE Classification system Grade 2 and Grade 3, respectively [14]. One patient had a small hematoma in the drainage canal and one showed





► **Fig. 3** Successful drainage catheter placement in a female patient with symptomatic lymphocele 22 days after extended tumor surgery due to ovarian carcinoma. A paraaortal lymph node excision was performed as well. The patient suffered from disturbed gastric and duodenal transit because of a retroperitoneal lymphocele compressing the distal duodenum (white arrow in **A** and **B**). Drainage catheter placement was carried out with the patient in prone position using the trocar technique. **C** shows the result after drainage catheter placement with total deflation of the lymphocele cavity and relief of symptoms.

► **Abb. 3** Erfolgreiche Drainageeinlage in eine Patientin mit symptomatischer Lymphozele 22 Tage nach ausgedehnter Tumoroperation aufgrund eines Ovarialkarzinoms. Eine Exzision der paraaortalen Lymphknoten wurde ebenfalls durchgeführt. Die Patientin litt an einer gestörten duodenalen und gastrischen Passage aufgrund der Kompression des Duodenum durch eine symptomatische Lymphozele (weißer Pfeil in **A** und **B**). Die Drainageeinlage in Tokar-Technik wurde mit der Patientin in Bauchlagerung durchgeführt. **C** Diese Abb. zeigt das Resultat der Drainageeinlage mit einer totalen Deflation der Lymphozele. Die Patientin war danach beschwerdefrei.

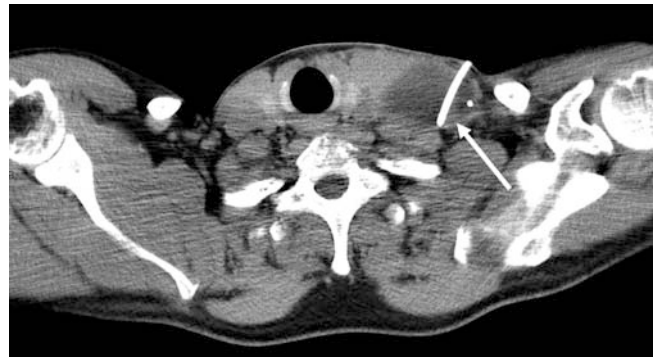signs of infection of the drainage canal several weeks after removal of the drainage catheter.

## Discussion

Many methods for the treatment of symptomatic lymphoceles have been described. None of these methods is explicitly recommended as the standard of care, as there are no distinctive guidelines.

With a success rate of 94.8%, our results using vacuum drainage are in the upper range of reported success rates for different treatment options for lymphoceles: Instillation of povidone iodine has a reported success rate of 90% [15], and the success rate of sclerotherapy has been described to range from 77% to 94% with a higher catheterization duration (up to 60 days) [1, 16, 17] compared to our method. In the past, surgery was the treatment of choice with reported success rates of 80–90% for internal marsupialization [18, 19]. Lymphangiography and lymphatic embolization have been proposed as a second-line treatment after failed percutaneous drainage with a success rate of 100% [20] in a small patient cohort.

Existing literature has reported that most symptomatic lymphoceles have a diameter exceeding 5 cm [8]. In our patient



► **Fig. 4** Drainage catheter placement in a symptomatic cervical lymphocele post-lymph node excision with the patient suffering from fever and pain failed to cure the lymphocele completely. Even after 10 days of catheter drainage (white arrow), the lymphocele was still visible. The positive effect of the drainage procedure was symptom relief.

► **Abb. 4** Drainageeinlage in eine symptomatische zervikale Lymphozele nach Lymphknotenexzision: Der Patient litt an Fieber und Schmerzen. Die Drainage (weißer Pfeil) konnte die Lymphozele in diesem Fall leider nicht zur Ausheilung bringen. Sogar nach 10 Tagen mit einliegender Drainage war die Lymphozele noch abzugrenzen. Der positive Effekt der Drainage war jedoch die Beschwerdelinderung.

collective, all but two symptomatic lymphoceles were quite large with at least one diameter exceeding 5 cm. In the case of quite large lymphoceles, drainage catheter placement was easy, and the technical success rate was 100%. Dislocation of the drainage catheter was a problem in the beginning after implementation of the protocol. However, after materials were replaced with locked drainage catheters with suture-fixed pigtailed, dislocation was less frequent.

A simple drainage catheter can be inserted into symptomatic lymphoceles as a valuable therapy, but it has been reported that 23–50% of lymphoceles re-expand after removal of the catheter [21]. As suction drainage can prevent the formation of lymphoceles or can treat lymphatic leakages [22–27] and suction drainage of wounds after surgery is a long-established surgical practice since the introduction of suction drainage in the 1950s [28], we think that suction drainage of existing symptomatic lymphoceles is also a valuable and a successful method. We think that the effects of suction drainage of lymphoceles are as follows: (1) suction drainage can induce cavity collapse and (2) surface adherence, (3) and even pus may be drained completely [30]. Indeed, we observed that due to the suction, even purulent lymphoceles could be immediately and totally drained after drainage insertion. Additionally, there are investigations in the literature dealing with different sizes of drainage catheters. In that study [29], no relevant difference between large and small drainage catheters concerning drainage outcome was observed, even in particularly viscous – and thus complicated – necrotizing pancreatitis. Therefore, it was not necessary to use larger catheter sizes. The 8 F and 8.5 F drainage catheters worked fine for our treatment of lymphoceles. As stated above, our protocol included regular checks of the catheter and flushing with small amounts of sterile saline to avoid

obstruction of the drainage catheter. Positive effects of negative-pressure therapy in local wound therapy have been investigated since the 1980s (reviewed in [10]). The following effects have been described: increase in blood flow, promotion of angiogenesis, and induction of cell proliferation. We believe that due to these effects and due to continuous suction/aspiration of lymph fluid, surface adherence and also healing is induced as long as continuous suction is present. To find a suture-locked catheter with pigtail configuration and a Redon container in combination that could maintain the vacuum after connecting the catheter with the container needed a bit of research and testing of different combinations. A premounted drainage catheter with a suture locking mechanism with a pigtail configuration (Merrit Resolve locking catheter) or basket configuration (basket drainage catheter, Sikamed) was ultimately suitable to maintain the vacuum after connection with the Redon container. We determined that our “preparation” of the container tube was the best method to connect both. As another positive effect of our protocol, we could not find any catheter dislodgement. In our patient collective the suture-locked pigtail configuration seems to be able to effectively prevent catheter dislodgement. Our protocol has some other positive effects: It is an easy and minimally invasive procedure in a closed system with rapid clinical improvement in all patients. Regarding relapse, our protocol was able to prevent re-expansion in all but 4 lymphoceles (relapse rate: 11 %), which is much better than previously published results [16, 17]. Our therapy with suction drainage failed in two patients (one with a cervical lymphocele after lymph node excision and one with sepsis after prostatectomy). A connection between this failure and the underlying condition of the patients could not be observed, and due to the low number of cases (n = 2), statistical evaluation was not possible. To investigate if the underlying entity has an influence of the rate of failure, further investigation with larger case numbers is necessary.

Compared to surgical procedures like marsupialization [31], the minimally invasive method of image-guided drainage has the advantage of a relatively small access way, which corresponds to the thickness of the drainage catheter. As a result, the interventionalist has more freedom when choosing the access trajectory of the drainage catheter. Aspects like postoperative and/or age-related anatomical alterations (e. g., vessel kinking or varices) as well as patient comfort (especially given the relatively long duration of the indwelling drainage catheter) can be taken into account when planning the access way for the drainage catheter. However, due to the greater freedom compared to a surgical procedure and the other restrictions mentioned above, access planning in this minimally invasive approach is harder to standardize or formalize. Therefore, it requires more experience on the part of the interventionalist in planning the access trajectory. The disadvantage of our protocol is the relatively long time period of suction to ensure surface adherence. The drainage catheter should remain for at least 4 days with vacuum suction after output had stopped. This time period of treatment with a drainage catheter present is comparable with some other therapy options. For lymphangiography and lymphatic embolization, the median time to resolution was 7 days [20]. For sclerotherapy there are also quite long mean catheterization times of 11.8 days (1–60 days;

[17]). We had a median time of indwelling catheter of 8.5 days until resolution. As the procedure is not painful, most patients did not complain.

Clinical relevance of this study: Our protocol of suction drainage is an easy and successful method to cure symptomatic lymphoceles at various locations with rapid clinical improvement and a low tendency of relapse.

## Conflict of Interest

The authors declare that they have no conflict of interest.

## References

- [1] Mahrer A, Ramchandani P, Trerotola SO et al. Sclerotherapy in the management of postoperative lymphocele. *J Vasc Interv Radiol* 2010; 21: 1050–1053
- [2] Baek Y, Won JH, Chang SJ et al. Lymphatic Embolization for the Treatment of Pelvic Lymphoceles: Preliminary Experience in Five Patients. *J Vasc Interv Radiol* 2016; 27: 1170–1176. doi:10.1016/j.jvir.2016.04.011
- [3] Offensperger F, Richter GM, Sommer CM. Symptomatische Lymphozelen nach Nierentransplantation. *Rofo* 2021; 193: 582–583
- [4] Karcaaltincaba M, Akhan O. Radiologic imaging and percutaneous treatment of pelvic lymphocele. *European journal of radiology* 2005; 55: 340–354
- [5] Kim HY, Kim JW, Kim SH et al. An analysis of the risk factors and management of lymphocele after pelvic lymphadenectomy in patients with gynecologic malignancies. *Cancer research and treatment* 2004; 36: 377–383
- [6] Nghiem DD, Beckman I. Intraperitoneal catheter drainage of lymphocele: an outpatient procedure. *Transplant international* 2005; 18: 721–723
- [7] Ghezzi F, Uccella S, Cromi A et al. Lymphoceles, lymphorrhea, and lymphedema after laparoscopic and open endometrial cancer staging. *Annals of surgical oncology* 2012; 19: 259–267
- [8] Lv S, Wang Q, Zhao W et al. A review of the postoperative lymphatic leakage. *Oncotarget* 2017; 8: 69062–69075
- [9] Schurawitzki H, Karnel F, Mostbeck G et al. Radiologische Therapie von symptomatischen Lymphozelen nach Nierentransplantation [Radiologic therapy of symptomatic lymphoceles following kidney transplantation]. *Rofo* 1990; 152: 71–75
- [10] Mouës CM, Heule F, Hovius SE. A review of topical negative pressure therapy in wound healing: sufficient evidence? *Am J Surg* 2011; 201: 544–556
- [11] Dicuio M, Pomara G, Menchini Fabris F et al. Measurements of urinary bladder volume: comparison of five ultrasound calculation methods in volunteers. *Arch Ital Urol Androl* 2005; 77: 60–62
- [12] Hvarness H, Skjoldbye B, Jakobsen H. Urinary bladder volume measurements: comparison of three ultrasound calculation methods. *Scand J Urol Nephrol* 2002; 36: 177–181
- [13] Khalilzadeh O, Baerlocher MO, Shyn PB et al. Proposal of a New Adverse Event Classification by the Society of Interventional Radiology Standards of Practice Committee. *J Vasc Interv Radiol* 2017; 28: 1432–1437.e3
- [14] Filippiadis DK, Binkert C, Pellerin O et al. Cirse Quality Assurance Document and Standards for Classification of Complications: The Cirse Classification System. *Cardiovasc Intervent Radiol* 2017; 40: 1141–1146
- [15] Zomorodi A, Buhluli A. Instillation of povidone iodine to treat lymphocele and leak of lymph after renal transplantation. *Saudi J Kidney Dis Transpl* 2007; 18: 621–624

- [16] Caliendo MV, Lee DE, Queiroz R et al. Sclerotherapy with use of doxycycline after percutaneous drainage of postoperative lymphoceles. *J Vasc Interv Radiol* 2001; 12: 73–77
- [17] Akhan O, Karcaaltincaba M, Ozmen MN et al. Percutaneous transcatheter ethanol sclerotherapy and catheter drainage of postoperative pelvic lymphoceles. *Cardiovasc Intervent Radiol* 2007; 30: 237–240
- [18] Gill IS, Hodge EE, Munch LC et al. Transperitoneal marsupialization of lymphoceles: a comparison of laparoscopic and open techniques. *J Urol* 1995; 153: 706–711
- [19] Hsu TH, Gill IS, Grune MT et al. Laparoscopic lymphoectomy: a multi-institutional analysis. *J Urol* 2000; 163: 1096–1098
- [20] Chu HH, Shin JH, Kim JW et al. Lymphangiography and Lymphatic Embolization for the Management of Pelvic Lymphocele After Radical Prostatectomy in Prostatic Cancer. *Cardiovasc Intervent Radiol* 2019; 42: 873–879
- [21] Kim JK, Jeong YY, Kim YH et al. Postoperative pelvic lymphocele: treatment with simple percutaneous catheter drainage. *Radiology* 1999; 212: 390–394
- [22] Van Den Brande P, Von Kemp K, Aerden D et al. Treatment of lymphocutaneous fistulas after vascular procedures of the lower limb: accurate wound reclosure and 3 weeks of consistent and continuing drainage. *Ann Vasc Surg* 2012; 26: 833–838
- [23] Choo YC, Wong LC, Ma HK. The management of intractable lymphocyst following radical hysterectomy. *Gynecol Oncol* 1986; 24: 309–316
- [24] Monaghan JM, Ireland D, Mor-Yosef S et al. Role of centralization of surgery in stage IB carcinoma of the cervix: a review of 498 cases. *Gynecol Oncol* 1990; 37: 206–209
- [25] Orr JW Jr, Barter JF, Kilgore LC et al. Closed suction drainage after radical pelvic surgical procedures. *Am J Obstet Gynecol* 1986; 155: 867–871
- [26] Symmonds RE, Pratt JH. Prevention of fistulas and lymphocysts in radical hysterectomy. *Obstet Gynecol* 1961; 17: 57–64
- [27] Yuan Y, Niu Y, Xiao W et al. The Effect and Mechanism of Negative Pressure Wound Therapy (NPWT) on Lymphatic Leakage in Rabbits. *Journal of Surgical Research* 2019; 235: 329–339
- [28] Redon H. Closing of large wounds by suppression. *Presse Med* 1955; 63: 1034
- [29] Bruennler T, Langgartner J, Lang S et al. Outcome of patients with acute, necrotizing pancreatitis requiring drainage-does drainage size matter? *World J Gastroenterol* 2008; 14: 725–730
- [30] Cummin AR, Wright NL, Joseph AE. Suction drainage: a new approach to the treatment of empyema. *Thorax* 1991; 46 (4): 259–260. doi:10.1136/thx.46.4.259
- [31] Khoder WY, Gratzke C, Haseke N et al. Laparoscopic marsupialisation of pelvic lymphoceles in different anatomic locations following radical prostatectomy. *Eur Urol* 2012; 62: 640–648