Article published online: 2021-10-08

Application of a novel artificial intelligence system in guiding the targeted puncture of a pancreatic mass

Endoscopic ultrasound-guided fine-needle aspiration (EUS-FNA) is a first choice for acquiring samples from a pancreatic lesion [1]. However, due to the heterogeneity of the tumor, inaccurate localization of the positive puncture site will lead to a missed diagnosis The combination of contrast-enhanced harmonic endoscopic ultrasound and EUS-FNA can help to avoid puncture in necrotic areas, thus improving the diagnostic rate [2]. Unfortunately, the naked eye is not reliable for identifying and differentiating the targeted puncture sites suggested by contrast-enhanced harmonic EUS.

Therefore, we developed a novel system based on deep convolutional neural networks and random forest algorithms in order to identify and track the pancreatic masses dynamically in real time via describing time–intensity curve characteristics of each area of the pancreas, identifying points of interest, and guiding EUS-FNA.

A 55-year-old man was admitted to our department because of abdominal pain for 4 months. Computed tomography (CT) showed a lesion 8.3 × 6.3 cm in the pancreatic body and tail (▶ **Fig. 1**). The patient decided to undergo EUS-FNA with the guidance of the novel system (▶ **Video 1**).

EUS confirmed a lesion 6.5 cm in diameter in the pancreatic body and tail (▶ **Fig. 2**). The optimal insertion region was determined with the guidance of the system. A targeted puncture was performed in the malignant area based on diagnosis via artificial intelligence (AI) (▶ **Fig. 3**). Adequate tissue specimens were acquired after one pass with a 22G needle. The cytological examination found tumor cells (▶ **Fig. 4**).

No adverse event and complications were observed during or after the procedure. The patient underwent surgery, and postoperative pathology suggested pancreatic adenocarcinoma. Chemotherapy was then confirmed. The novel AI system is a valuable option for improving the diagnostic accuracy of EUS-FNA that can distinguish the malignant, benign, and necrotic regions in a lesion and guide the puncture.

Endoscopy_UCTN_Code_TTT_1AS_2AD

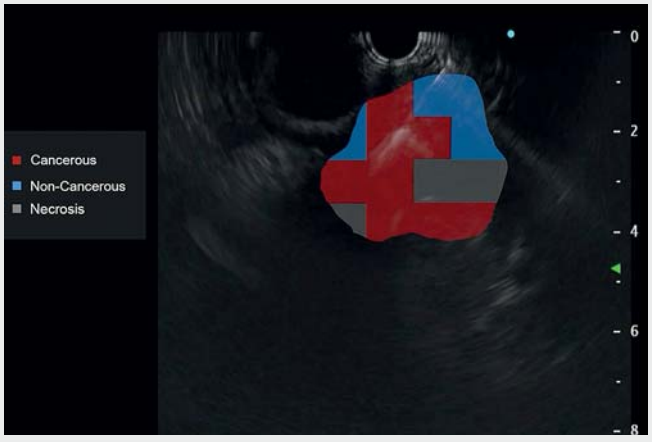

▶ **Video 1** Application of a novel artificial intelligence system in targeted puncture of a pancreatic mass. Red areas represent the malignancy where puncture was made, the blue areas are inflammation, and the gray areas are necrosis.

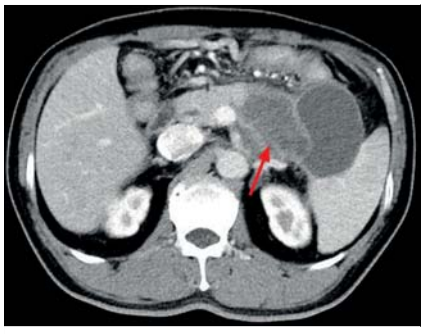

▶ **Fig. 1** Computed tomography showed a space-occupying lesion in the pancreatic body and tail.

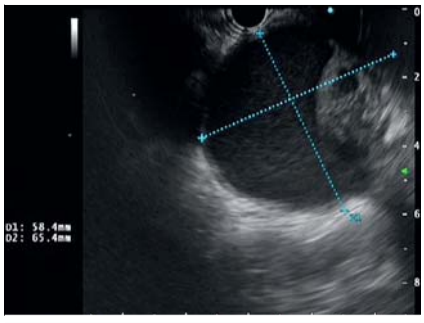

▶ **Fig. 2** Endoscopic ultrasound confirmed a lesion 6.5 cm in diameter in the pancreatic body and tail.

Acknowledgement

We thank Jinzhu Liu, Wujun Wang and Long Zeng from Wuhan EndoAngel Medical Technology Co., Ltd. to build the AI system.

Funding

the Hunan Provincial Science&Technology Department of China
2020SK2013

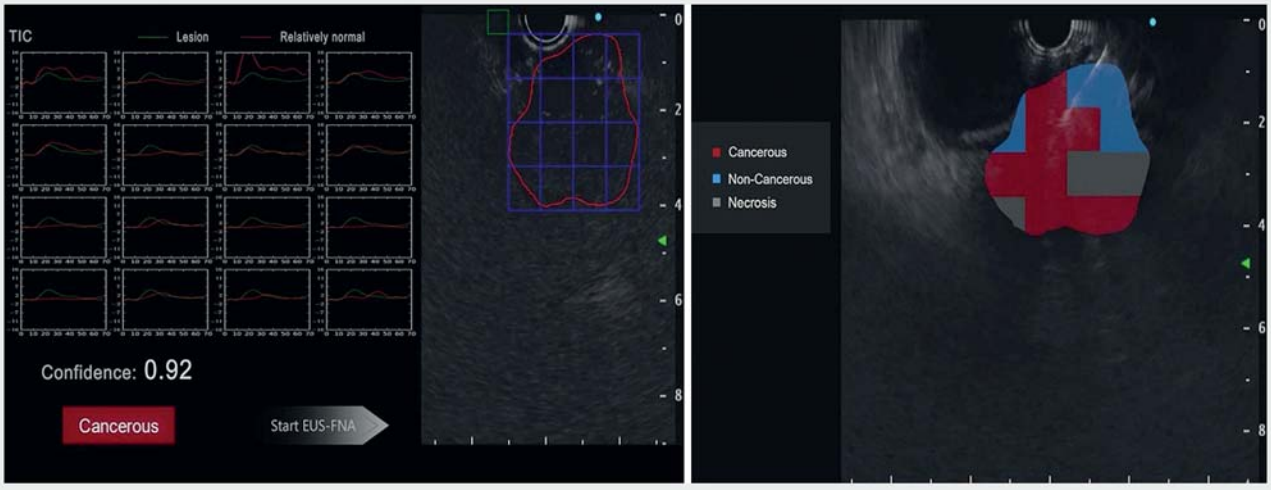

▶ **Fig. 3** The optimal insertion region was determined with guidance from the system.

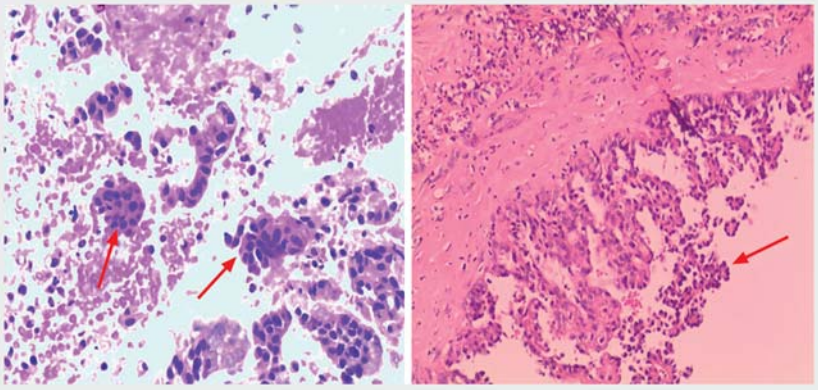

▶ **Fig. 4** The pathological examination found tumor cells and confirmed an adenocarcinoma of the pancreas.

Competing interests

The authors declare that they have no conflict of interest.

The authors

Xiaoyu Yu[1], Zinan Zhang[1], Ningxin Zhu[1], Anliu Tang[1], Shan Hu[2], Xiaoyan Wang[1 *], Li Tian[1 *]

1 Department of Gastroenterology, The Third Xiangya Hospital of Central South University, Hunan, China
2 Wuhan EndoAngel Medical Technology Company, Wuhan, China

Corresponding author

Li Tian, MD
Department of Gastroenterology, The Third Xiangya Hospital of Central South University, 138 Tongzipo Road, Yuelu District, Changsha, Hunan, China, 410013
f3tianli@outlook.com

References

[1] Facciorusso A, Del Prete V, Buccino V et al. Diagnostic yield of Franseen and Fork-Tip biopsy needles for endoscopic ultrasound-guided tissue acquisition: a meta-analysis. Endosc Int Open 2019; 7: E1221–E1230. doi:10.1055/a-0982-2997

[2] Kamata K, Takenaka M, Omoto S et al. Impact of avascular areas, as measured by contrast-enhanced harmonic EUS, on the accuracy of FNA for pancreatic adenocarcinoma. Gastrointest Endosc 2018; 87: 158–163. doi:10.1016/j.gie.2017.05.052

Bibliography

Endoscopy 2022; 54: E500–E501
DOI 10.1055/a-1625-3396
ISSN 0013-726X
published online 8.10.2021

Georg Thieme Verlag KG, Rüdigerstraße 14, 70469 Stuttgart, Germany

* These authors contributed equally.