

Best Practice Guideline – DEGUM Recommendations on Breast Ultrasound

Part I – Examination technique, DEGUM ultrasound criteria, and documentation

Best Practice Guideline – Empfehlungen der DEGUM zur Durchführung und Beurteilung der Mammasonografie

TEIL I – Untersuchungstechnik, Ultraschall-DEGUM-Kriterien und deren Dokumentation

Authors

Werner Bader^{1*}, Claudia Maria Vogel-Minea^{2*}, Jens-Uwe Blohmer³, Volker Duda⁴, Christian Eichler⁵, Eva Fallenberg⁶, André Farrokhi⁷, Michael Golatta⁸, Ines Gruber⁹, Bernhard-Joachim Hackelöer¹⁰, Jörg Heil⁸, Helmut Madjar¹¹, Ellen Marzotko¹², Eberhard Merz¹³, Markus Müller-Schimpfle¹⁴, Alexander Mundinger¹⁵, Ralf Ohlinger¹⁶, Uwe Peisker¹⁷, Fritz K. W. Schäfer¹⁸, Ruediger Schulz-Wendtland¹⁹, Christine Solbach²⁰, Mathias Warm²¹, Dirk Watermann²², Sebastian Wojcinski¹, Markus Hahn⁹

Affiliations

- 1 Zentrum für Frauenheilkunde, Brustzentrum, Universitätsklinikum OWL Bielefeld, Germany
- 2 Brustzentrum, Diagnostische und Interventionelle Senologie, Rottal-Inn-Kliniken Eggenfelden, Germany
- 3 Klinik für Gynäkologie mit Brustzentrum, Charité-Universitätsmedizin Berlin, Germany
- 4 Senologische Diagnostik, Universitätsklinikum Gießen und Marburg, Germany
- 5 CIO Gebäude 70, Brustzentrum, Köln, Germany
- 6 Brustzentrum, Diagnostische und Interventionelle Senologie, LMU Klinikum der Universität München Medizinische Klinik und Poliklinik IV, München, Germany
- 7 Klinik für Gynäkologie und Geburtshilfe, Universitätsklinikum Schleswig-Holstein Campus Kiel, Germany
- 8 Sektion Senologie, Universitäts-Frauenklinik Heidelberg, Germany
- 9 Department für Frauengesundheit, Universitätsfrauenklinikum Tübingen, Germany
- 10 Pränatale-Gynäkologie-Mammasonografie Hamburg, Praxis, Hamburg, Germany
- 11 Gynäkologie und Senologie Wiesbaden, Praxis, Wiesbaden, Germany
- 12 Mammadiagnostik, Frauenheilkunde und Geburtshilfe, Praxis, Erfurt, Germany
- 13 Ultraschall und Pränatalmedizin Frankfurt, Zentrum, Frankfurt/Main, Germany
- 14 DKG-Brustzentrum, Klinik für Radiologie, Neuroradiologie und Nuklearmedizin Frankfurt, Frankfurt am Main, Germany
- 15 Brustzentrum Osnabrück – Bildgebende und interventionelle Mamma Diagnostik, Franziskus Hospital Harderberg, Niels-Stensen-Kliniken, Georgsmarienhütte, Germany
- 16 Interdisziplinäres Brustzentrum, Universitätsmedizin Greifswald, Klinik für Frauenheilkunde und Geburtshilfe, Greifswald, Germany

- 17 BrustCentrum Aachen-Kreis Heinsberg, Hermann-Josef-Krankenhaus, Akademisches Lehrkrankenhaus der RWTH Aachen, Erkelenz, Germany
- 18 Bereich Mammadiagnostik und Interventionen, Universitätsklinikum Schleswig-Holstein Campus Kiel, Germany
- 19 Radiologisches Institut, Gynäkologische Radiologie, Universitätsklinikum Erlangen, Germany
- 20 Senologie, Klinik für Frauenheilkunde und Geburtshilfe, Universitätsklinikum Frankfurt, Germany
- 21 Brustzentrum, Krankenhaus Holweide, Kliniken der Stadt Köln, Köln, Germany
- 22 Frauenklinik, Evangelisches Diakoniekrankenhaus, Freiburg, Germany

Key words

breast, guideline, gynecology, DEGUM, ultrasound

received 07.04.2021

accepted 02.09.2021

published online 17.12.2022

Bibliography

Ultraschall in Med 2022; 42: 570–582

DOI 10.1055/a-1634-5021

ISSN 0172-4614

© 2021. Thieme. All rights reserved.

Georg Thieme Verlag KG, Rüdigerstraße 14, 70469 Stuttgart, Germany

Correspondence

Dr. Claudia Maria Vogel-Minea
Brustzentrum, Rottal-Inn-Kliniken Eggenfelden,
Simonsöder Allee 20, 84307 Eggenfelden, Germany
Tel.: +49/87 21/98 39 72 20
Fax: +49/87 21/9 83 72 09
vogel-minea.claudia@rottalincliniken.de

* Contributed equally (first-shared authors).

ABSTRACT

For many years, breast ultrasound has been used in addition to mammography as an important method for clarifying breast findings. However, differences in the interpretation of findings continue to be problematic [1, 2]. These differences decrease the diagnostic accuracy of ultrasound after detection of a finding and complicate interdisciplinary communication and the comparison of scientific studies [3]. In 1999, the American College of Radiology (ACR) created a working group (International Expert Working Group) that developed a classification system for ultrasound examinations based on the established BI-RADS classification of mammographic findings under consideration of literature data [4]. Due to differences in content, the German Society for Ultrasound in Medicine (DEGUM) published its own BI-RADS-analogue criteria catalog in 2006 [3]. In addition to the persistence of differences in content, there is also an issue with formal licensing with the current 5th edition of the ACR BI-RADS catalog, even though the content is recognized by the DEGUM as another system for describing and documenting findings. The goal of the Best Practice Guideline of the Breast Ultrasound Working Group of the DEGUM is to provide colleagues specialized in senology with a current catalog of ultrasound criteria and assessment categories as well as best practice recommendations for the various ultrasound modalities.

ZUSAMMENFASSUNG

Die Mammasonografie hat sich seit vielen Jahren neben der Mammografie als wichtige Methode zur Abklärung von Brustbefunden etabliert. Problematisch bleiben jedoch Unterschiede in der Interpretation von Befunden [1, 2]. Dies vermindert die diagnostische Treffsicherheit der Sonografie nach Detektion eines Befundes, erschwert die interdisziplinäre Kommunikation und den Vergleich von wissenschaftlichen Arbeiten [3]. Das American College of Radiology (ACR) hatte 1999 eine Arbeitsgruppe gebildet (International Expert Working Group), die auf der Basis der langjährig etablierten BI-RADS-Klassifizierung von mammografischen Befunden und unter Berücksichtigung von Literaturdaten eine ähnliche Einteilung für die Ultraschalluntersuchung erarbeitet hatte [4]. Aufgrund inhaltlicher Unterschiede hatte die DEGUM bereits 2006 einen eigenen BI-RADS-analogen Kriterienkatalog publiziert [3]. Die aktuelle 5. Edition des ACR-BI-RADS-Katalogs offenbart neben diesen weiterhin bestehenden inhaltlichen Unterschieden zudem das Problem der formalen Lizenzierung, wird aber inhaltlich von der DEGUM als weiteres Befundbeschreibungs- und Dokumentationssystem anerkannt.

Der Arbeitskreis Mammasonografie der DEGUM beabsichtigt mit der „Best Practice Guideline“, den senologisch tätigen Kolleginnen und Kollegen einen aktuellen Dignitätskriterien- und Befundungskatalog sowie „Best Practice“-Empfehlungen zu den verschiedenen Modalitäten an die Hand zu geben.

1. Introduction

Breast cancer is the most common malignant disease in women in western industrialized countries. According to current data of the Robert Koch Institute, 67 300 women were diagnosed with breast cancer in 2017 in Germany¹. On the base of current data 1 of 8 women develops breast cancer once in her lifetime. There are multiple methods for detecting breast cancer early. Mammography screening is available to all women between the ages of 50 and 70 in Germany. However almost 3 from 10 women diagnosed with breast cancer are younger than 55 and 30 % are older than 70. Breast ultrasound has a very important status in the assessment of breast findings.

The goal of this Best Practice Guideline is to meet quality assurance requirements and to ensure that breast ultrasound is performed in a standardized manner. The guidelines are based on the standards recommended and practiced by the Breast Ultrasound Working Group of the DEGUM.

2. Fundamentals of breast ultrasound

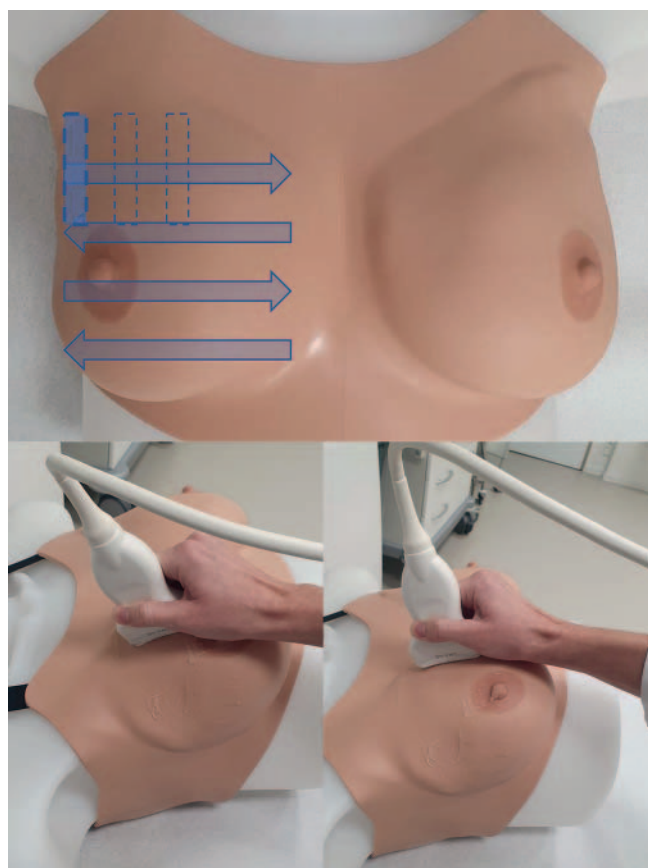
Ultrasound is an imaging method for diagnosing diseases of the breast that is characterized by minimal stress for the patient, a lack of radiation, low cost, and ubiquitous availability. It is used

to clarify clinically and radiologically conspicuous findings and to monitor biopsies and interventions. It is an established part of aftercare and is a supplementary method for the early detection of breast cancer in dense breast tissue and in young women and in the case of a high risk of breast cancer.

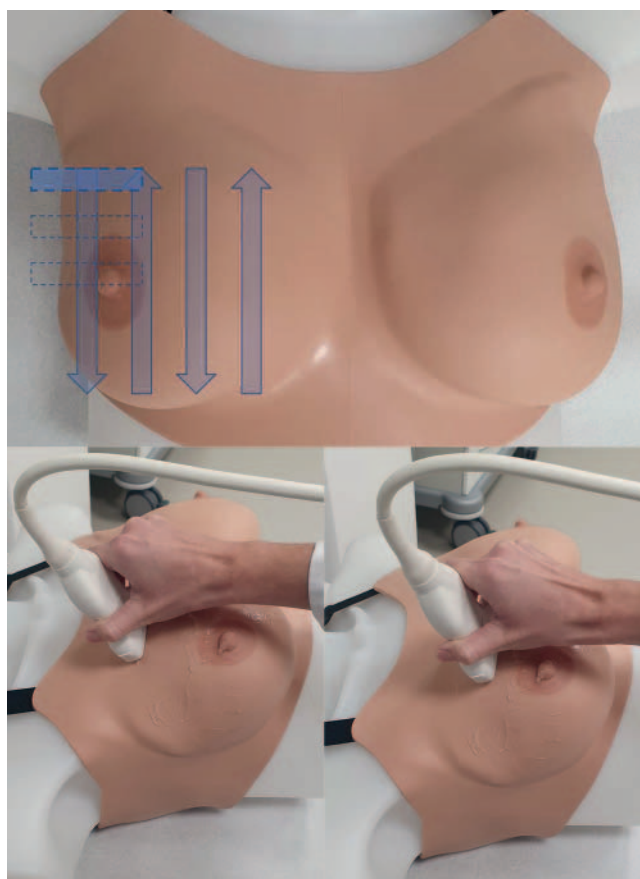
High breast density presents a diagnostic challenge in the case of mammography [5]. Although there is no linear relationship between breast density and breast cancer, the diagnostic reliability of radiology decreases with increasing breast density [6]. The denser the tissue the more difficult it is to assess and detect a malignancy [7] and the greater the risk of malignancy [8]. According to the current S3 guidelines, supplementary breast ultrasound is indicated in the case of dense breast tissue [9]. According to data from the Mammography Screening Program, 46 % of women over the age of 50 have dense breast tissue and approx. 6 % of women have extremely dense breast tissue [10]. Dense breast tissue presents less of a diagnostic challenge for breast ultrasound than mammography [11]. The use of breast ultrasound in addition to mammography increases the detection rate for breast cancer [11–13].

To ensure examination quality, it is important to comply with technical requirements and particularly examiner qualifications. Main factors influencing the quality of the diagnostic results of an ultrasound examination include the quality of the equipment being used and the frequency of the transducer.

1 https://www.krebsdaten.de/Krebs/DE/Content/Krebsarten/Brustkrebs/brustkrebs_node.html



► Fig. 1 Sagittal/parasagittal scan orientation.



► Fig. 2 Transverse/horizontal scan orientation.

3. Examination technique

Patient positioning

The patient should ideally be in a supine position. The ipsilateral arm should be elevated at least 90 degrees and the corresponding hand should be placed behind the head. This allows a comfortable and seamless examination of the breast, axilla, and the supraclavicular and infraclavicular lymph nodes. Lifting the arms, unilaterally or bilaterally, also causes the pectoral muscles to tense thereby causing the breast to flatten and stay in place. The latter is only applicable on a limited basis for patient with macromastia. Due to increased mobility of the breast in such cases, the supine position should be adapted during the examination by lifting the ipsilateral shoulder region so that the breast is medialized as a result of the rotation of the body. The examination can then be performed with fewer problems and in its entirety.

Examination procedure and handling of the transducer

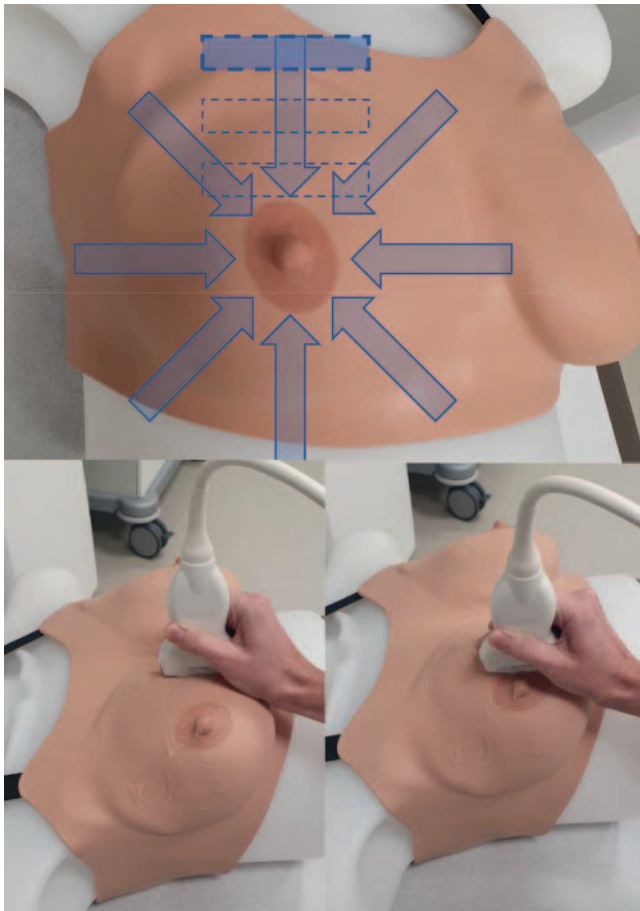
It is helpful to hold the transducer at the base, while “resting” the hand holding the transducer on the breast. Holding the transducer without support should be avoided. Application pressure should be selected so that the anatomy is visualized on the B-mode image without artifacts and the amount of pressure applied to the breast is not uncomfortable for the patient. Including orientation points like the clavicle, sternum, ribs, and

nipple-areola complex allows continuous image interpretation without the examiner having to change the field of view intermittently.

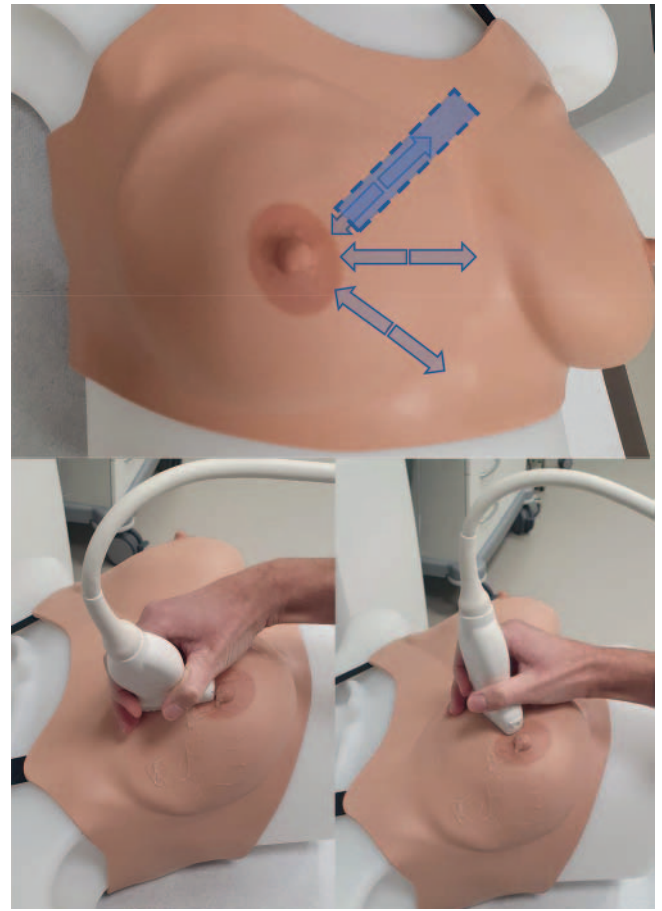
The goal is the complete examination and documentation of both breasts, the axillae, and the supraclavicular and infraclavicular lymphatic drainage regions where appropriate.

In practice, four main transducer and scan orientations are used in breast ultrasound. The examiner decides which technique to use. However, it is important that the entire breast is scanned and visualized in an overlapping manner. The four basic techniques are:

- I. **Sagittal/parasagittal scan orientation:** The transducer is applied perpendicular to the breast region. This results in a sagittal or parasagittal slice plane. The breast is examined fully from the anterior axillary line to the parasternal line in a meandering pattern by moving the transducer horizontally (► Fig. 1). To examine the entire breast, the transducer is always moved caudally or cranially less than the width of the transducer.
- II. **Transverse/horizontal scan orientation:** The transducer is applied horizontally so that a transverse view on the B-mode image is achieved. Examination of the breast is also performed in a meandering pattern, from cranial to caudal. The transducer is again moved medially or laterally by slightly less than the width of the transducer (► Fig. 2).



► Fig. 3 Antiradial/tangential scan orientation.



► Fig. 4 Radial scan orientation.

The combination of the two examination techniques is recommended by The DEGUM and allows dual systematic and gapless examination of the entire breast thereby providing visualization of findings on two planes (► Fig. 1, 2).

- III. **Antiradial/tangential scan orientation:** This approach is particularly suitable for evaluating larger breasts but can also be used as an alternative to the aforementioned methods. The transducer is applied tangentially to the base of the breast and is moved from the periphery toward the center perpendicular to the lactiferous ducts in clockwise direction toward the nipple. It must be ensured that there are complete regions of overlap particularly in the periphery (► Fig. 3).
- IV. **Radial scan orientation :** A radial scan orientation is suitable particularly for tracking ductal structures. This approach is thus primarily used to diagnose duct ectasia and intraductal formations (► Fig. 4). The transducer is moved from the periphery in a central direction along a lactiferous duct and then in a clockwise direction to the next lactiferous duct, which is then followed from the periphery in a central direction to the nipple.

Caution

Regardless of the selected technique, the examination must be performed in an overlapping manner without any gaps so that even small pathological findings are not missed.

Sonopalpation and compression

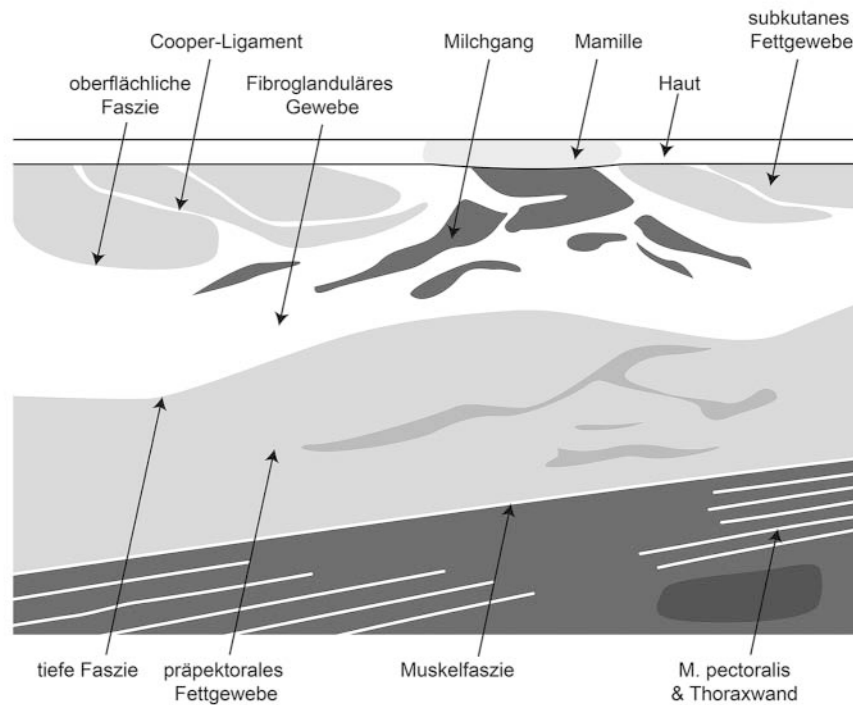
In the age of shear wave elastography and strain elastography, sonopalpation with manual compression for the evaluation of the elasticity of findings visible on ultrasound is considered secondary but is a good tool for optimized visualization.

4. Sonoanatomy of the breast and axilla

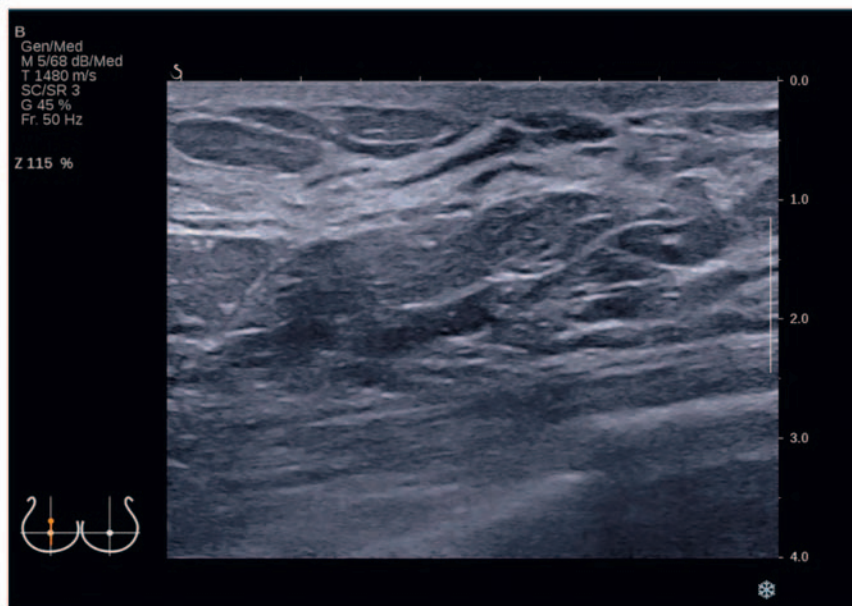
Ultrasound evaluation of the breast and axilla requires exact knowledge of the physiological and anatomical conditions.

Sonoanatomy of the breast

The visible part of the mammary gland is located on the chest wall between the second and the seventh rib, with the subcutaneous body of the mammary gland overlying the fascia of the pectoralis major muscle. The body of the mammary gland is comprised of approximately 15–20 individual lobes that are situated radially around the nipple. The individual excretory ducts open to one or multiple lactiferous ducts in the nipple. The lobes are surrounded by connective tissue and the Cooper ligaments that stretch subcutaneous to prepectoral and provide support to the breast. A layer of fat tissue separates the body of the mammary gland from the skin as well as from the pectoralis muscle fascia.



► **Fig. 5** Schematic cross section of a breast © LOGO! Design & mehr.

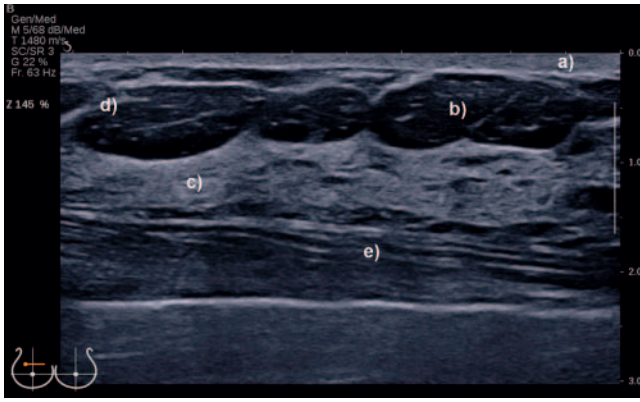


► **Fig. 6** Ultrasound image correlating to ► **Fig. 5**.

To systematically scan the individual anatomical breast structures, the transducer should be moved in a meandering pattern transverse or sagittal or antiradial (see chapter 3).

In the cross section of the breast (► **Fig. 5, 6**), the sonomorphologically relevant structures can be followed from anterior to posterior (► **Fig. 7**) [14]:

- Hyperechoic skin and hypoechoic nipple,



► **Fig. 7** B-mode image with sonomorphologically relevant structures: **a** hyperechoic skin, **b** hypoechoic fat tissue, **c** hyperechoic fibroglandular tissue, **d** hyperechoic Cooper ligament, **e** pectoralis major muscle.

- Hypoechoic subcutaneous fat tissue and hyperechoic Cooper ligaments
- Hyperechoic fibroglandular tissue
- Hypoechoic retromammary prepectoral fat tissue
- Hyperechoic fascia of the pectoralis major muscle.
- Thoracic wall with musculature and ribs

It must be taken into consideration that the fine structure of the mammary gland and thus also the sonomorphological image can be affected by hormonal status among other things [15, 16]. In premenopausal women, breast tissue is affected by estrogen and progesterone with the lobes temporarily enlarging and the connective tissue retaining fluid after ovulation in the middle of the cycle. The typical sonomorphological image of the breast in a young premenopausal woman usually shows mostly dense fibroglandular tissue and just a few fat lobules (► **Fig. 8a**). The amount of functioning glandular tissue decreases with age while the amount of fat increases. With the start of menopause and the associated decrease in estrogen, the fibroglandular tissue atrophies and fat tissue becomes dominant (involution) (► **Fig. 8b**) [3].

Pregnancy and lactation result in physiological and thus sonomorphological changes in the breast. The constant estrogen and progesterone levels from the placenta and the prolactin from the pituitary gland during pregnancy result in ductal-lobular proliferation. The mammary gland cells differentiate to milk-producing alveolar cells within the lobes (lactogenesis). This proliferation and differentiation can be correlated sonomorphologically with an increase in volume and density of the gland (► **Fig. 9a**). In addition, there is increased perfusion of the gland (► **Fig. 9b**) and enlargement of the lactiferous ducts due to lactogenesis (► **Fig. 9c**).

Sonomorphologically, the male breast is mainly comprised of hypoechoic fat tissue interspersed with hyperechoic reticular connective tissue (► **Fig. 10a**). However, in the event of a hormonal imbalance with a lack of male hormones and an excess of estrogen (e.g., due to chronic disease or medication), gynecomastia can occur [17]. Histology shows fibrosis of the parenchyma

associated with epithelial hyperplasia of the glandular ducts, sonomorphologically recognizable as predominantly retroareolar hypoechoic fibroglandular tissue (► **Fig. 10b**).

Sonoanatomy of the lymphatic drainage regions

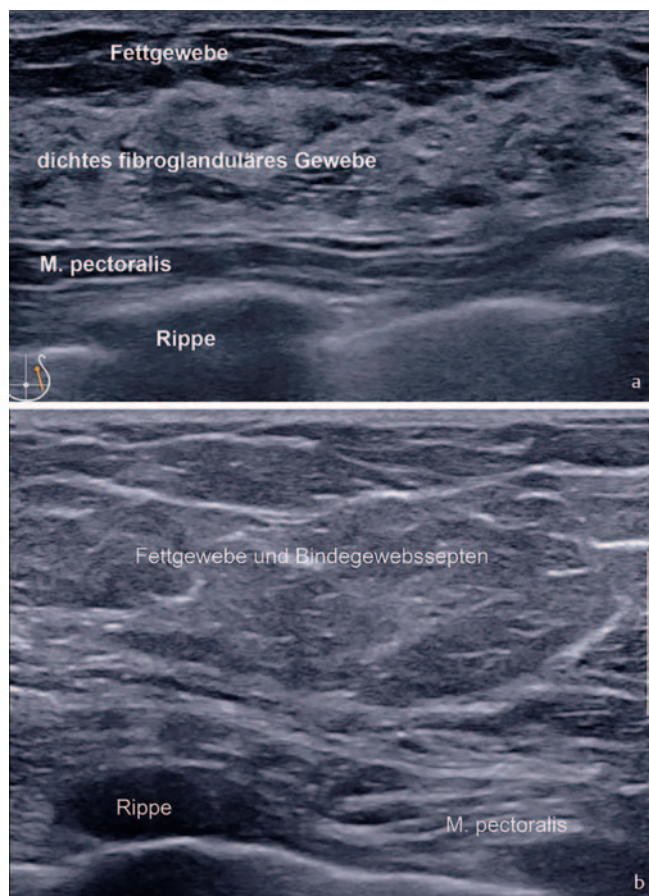
Axillary ultrasound is indicated for early detection, preoperative sonographic lymph node staging, and aftercare [18]. Precise anatomical knowledge of the guide structures is a requirement for correct topographical classification and visualization of the individual lymph node region levels I-III (► **Fig. 11**). Level I is bordered laterally by the humeral head and the latissimus dorsi muscle, cranially by the axillary artery and vein, and medially by the pectoralis minor muscle. Level II stretches from the lateral to the medial margin of the minor pectoralis muscle. Abnormal lymph nodes are located in the underlying fat tissue or between the pectoralis major and the pectoralis minor muscles (interpectoral (Rotter) group). Level III is defined as the region medial to the pectoralis minor muscle.

The following criteria are used for the sonomorphological assessment of nodal status: Lymph node shape, corticomedullary ratio, structure, and vascularization [18, 19], with a multimodal approach being used. A histologically benign lymph node appears oval in shape, with a hyperechoic fatty central hilar area, histomorphologically corresponding to the medulla, and a thin hypoechoic rim, corresponding to the cortex (► **Fig. 12**) [18]. Isolated blood vessels are seen in a central location. An increase in the size of the individual lymph node is caused by reactive-inflammatory processes occurring over the course of a lifetime. These lymph nodes with a central massive collection of hilar fat are also to be assessed as benign.

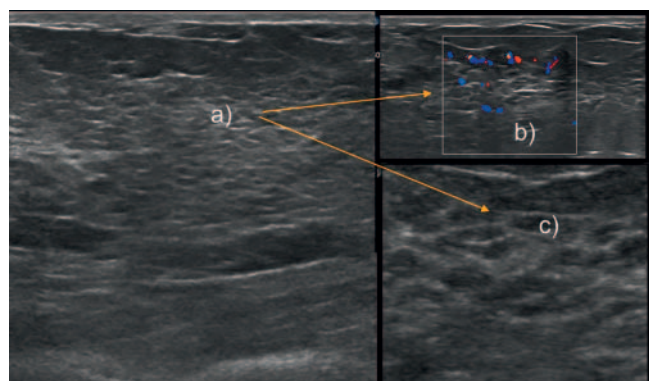
Metastases follow the lymphatic drainage usually from the periphery (cortex) toward the center (medulla) with the corticomedullary structure changing sonomorphologically as follows (► **Fig. 13a-d**) [18, 19]:

- Asymmetric enlargement of the hypoechoic peripheral zone (cortex) and thus compression of the hyperechoic medullary structure
- Loss of the corticomedullary structure due to loss of the hyperechoic medullary structure and transition to a hypoechoic round structure
- Subcapsular, peripheral, aberrant vascularization
- Extracapsular invasion of the surrounding tissue and irregular outer contour

Hypoechoic areas are the result of localized malignant infiltration. However, they can also be observed in the case of pronounced inflammatory liquefaction with focal coagulation necrosis in systemic lymphadenopathies, for example. The supplementary use of US elastography with the identification of “hard” lymph node areas can be used for further differentiation between benign and malignant lymph nodes [20]. Metastases change the corticomedullary structure and thus the sonomorphological relationship between the longitudinal and transverse diameter of the lymph node. The Solbiati index describes the ratio of the longitudinal diameter to the transverse diameter and can be used as a further



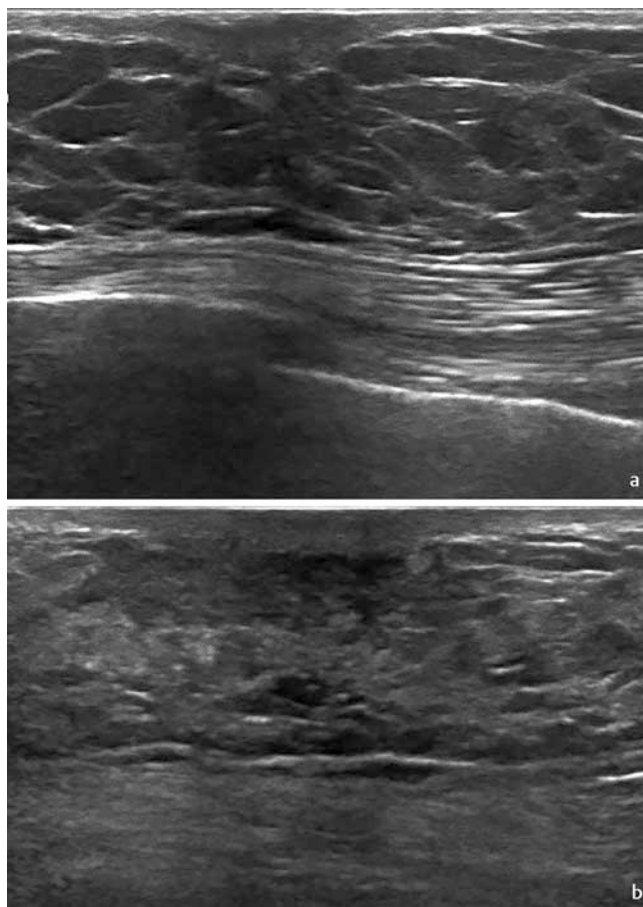
► **Fig. 8** **a** Premenopausal. **b** Postmenopausal.



► **Fig. 9** Sonomorphological changes during pregnancy and lactation: **a** Increased density of the glandular tissue, **b** Increased perfusion, **c** Enlargement of the lactiferous ducts.

criterion for assessing malignancy. Therefore, a Solbiati Index of <1.5 indicates malignancy, while an index value of >2 tends to indicate benign lymph nodes [21].

Due to the improved spatial and contrast resolution of modern high-frequency ultrasound, a cortical thickness of ≤ 3.0 mm is considered a significant and accurate criterion of a lymph node not requiring clarification according to current data. The likeli-



► **Fig. 10** **a** Retroareolar visualization of normal male breast. **b** Gynecomastia, retroareolar hypoechoic glandular tissue.

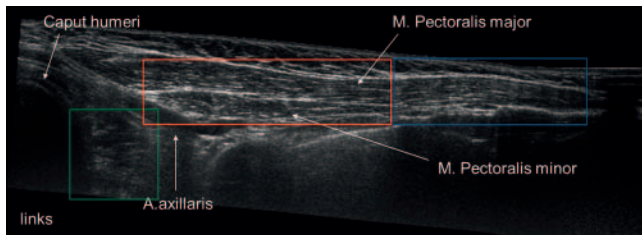
hood of metastases increases with the thickness of the cortex [22].

A further rare but specific sign of lymph node metastasis is an irregular nodular outer contour due to extracapsular invasion of the surrounding tissue (► **Fig. 13 d**) [23]. Semiquantitative evaluation of the total vascularization also contributes to the differentiation between benign and malignant lymph nodes. Therefore, benign lymph nodes show only isolated hilar blood vessels, while malignant lymph nodes can show peripheral cortical vascularity as well as aberrant vessels or locally absent vascularity (► **Fig. 13c**).

5. US-DEGUM categories, assessment criteria, and documentation

5.1 US-DEGUM categories

In general, the final evaluation of a breast ultrasound examination includes assessment of the parenchyma (parenchyma category) and one or more potential findings (assessment category).



► **Fig. 11** Sonographic visualization of lymph node regions: Level I (green), level II (red), level III (blue).

Assessment categories

In addition to an insufficient ability to evaluate a lesion (US category 0) and already histologically confirmed malignant findings (US category 6), there are five more assessment categories:

- **0** Diagnostic imaging insufficient, additional diagnostics required
- **1** Inconspicuous with no lesions, tiny simple cysts and retro-areolar, symmetrical ductectasia are not described separately
- **2** Benign findings, e. g., uncomplicated larger cysts, known fibroadenomas, intramammary lymph nodes, fat necrosis, implants, scars that remain constant over time, and scars that decrease in size
- **3** Probably benign findings requiring monitoring (risk of malignancy $\leq 2\%$)
- **4** Suspicious for malignancy (risk of malignancy $> 2\%$ to $< 95\%$) – histological examination required anstatt necessary
- **5** Highly suspicious for malignancy (risk of malignancy $\geq 95\%$) – histological examination required
- **6** Histopathologically confirmed malignancy

A category is assigned to every breast after description of all findings. The finding with the highest (worst) category is always the assessed category.

Parenchyma categories

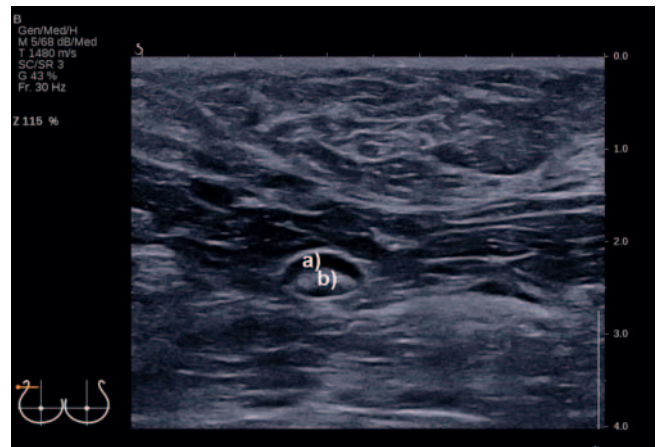
Breast density can still be determined on a percentage basis of fibroglandular tissue (I–IV) analogous to mammography assessment in the fourth edition of the ACR Breast Imaging Atlas from 2003 [4], the DEGUM recommendations from 2006 [3], and the WOB I recommendations from 2016 [24]. However, objective determination is significantly more difficult in this form on ultrasound than on mammography. Only volumetric measurement of the entire breast in the form of automatic three-dimensional breast ultrasound (ABUS) allows objective computer-based determination of the percentage of fibroglandular tissue.

A critical discussion regarding the ability to evaluate the parenchyma was also held in 2016 by 11 professional societies including the DEGUM [25].

Therefore, analogous to the current mammography and MRI assessment in the 5th edition of the ACR Atlas [26, 27], the DEGUM recommends using 4 categories to describe tissue composition (► Fig. 14–17):

a Almost entirely fatty tissue (► Fig. 14)

b Balanced admixture of fat and fibroglandular tissue (► Fig. 15)



► **Fig. 12** Benign oval lymph node with: **a** hypoechoic cortex and **b** hyperechoic medulla.

c Almost entirely fibroglandular tissue (► Fig. 16)

d Extreme fibroglandular tissue (► Fig. 17a, b)

with the addition of “easy to assess” or “difficult to assess”

It should be mentioned if the breast tissue is homogeneous and assessable in its entirety and than “easy to assess” or if the breast tissue is inhomogeneous and/or not assessable in its entirety and so “difficult to assess”.

Example 1

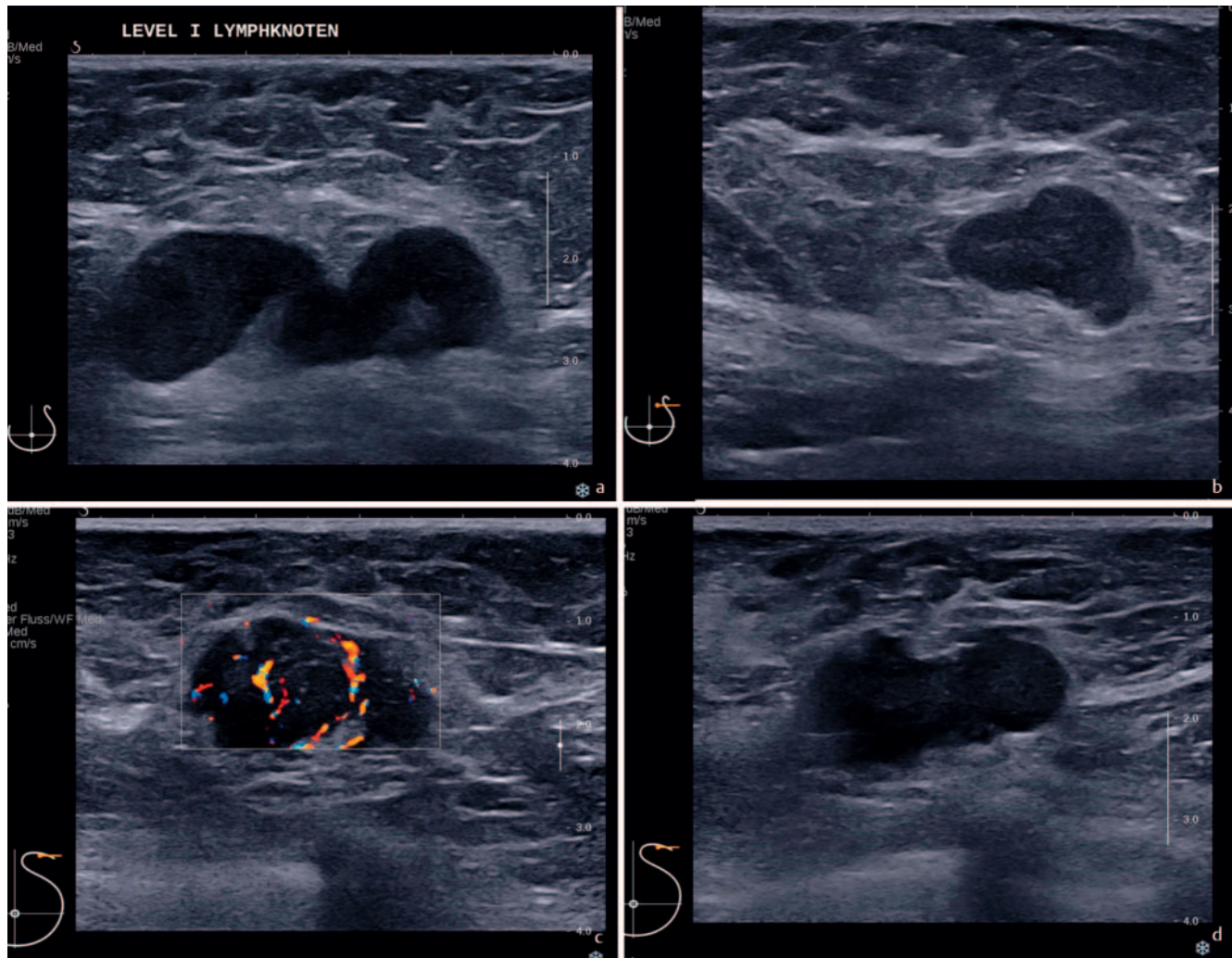
Involution in the case of gigantomastia can be evaluated as “almost entirely fatty tissue, difficult to assess” due to the size of the breast. If no lesion can be detected, the final assessment would be: “Parenchyma category a, difficult to assess, assessment category 1” or shortened form: **DEGUM category a/1, difficult to assess**.

In the case of fibroglandular tissue, the examination must be optimized by the selection of the ultrasound modes, the examination technique, the US system, and the transducer technology to ensure the ability to assess. The basic factors here are compression, frequency, focus setting, and time gain compensation to minimize artifacts and limitations and to optimize assessment.

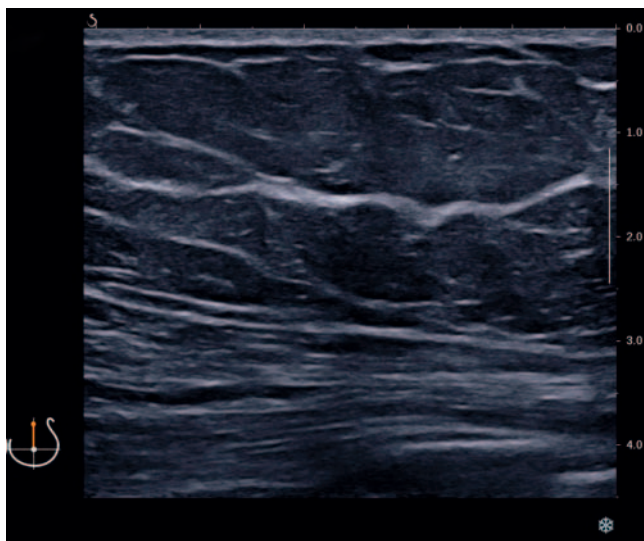
The percentage of fibroglandular tissue plays a subordinate role in assessment a–d. For the final categorization not only the ratio of fat tissue to glandular tissue but also primarily its structure is essential. Extreme fibroglandular tissue is present when there is alternation between pronounced hyperechoic and hypoechoic areas and acoustic shadowing artificially increases the heterogeneity of the tissue and the sensitivity of sonography can be affected, particularly in deeper layers. In spite of the mentioned optimization of the ultrasound system, assessment is only possible on a limited basis.

Example 2

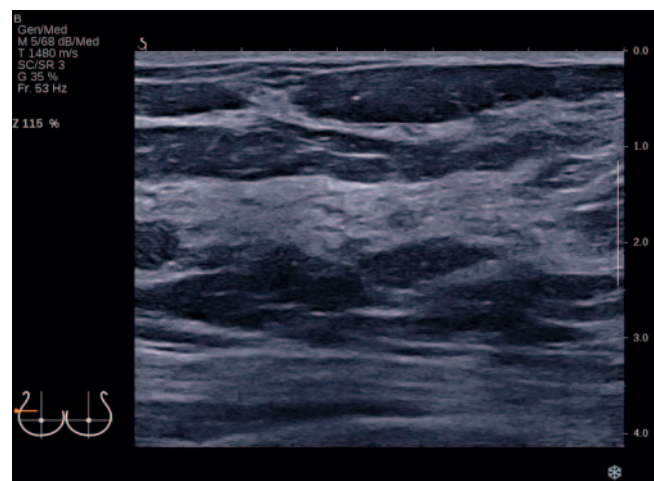
In the case of a small breast that can be evaluated in its entirety up to the muscle fascia, the ability to assess is to be categorized as “easy to assess” in spite of extreme fibroglandular tissue. If no lesion is detected, the final assessment would be: “Parenchyma category d, easy to assess, assessment category 1” or in shortened form: **DEGUM category d/1, easy to assess**.



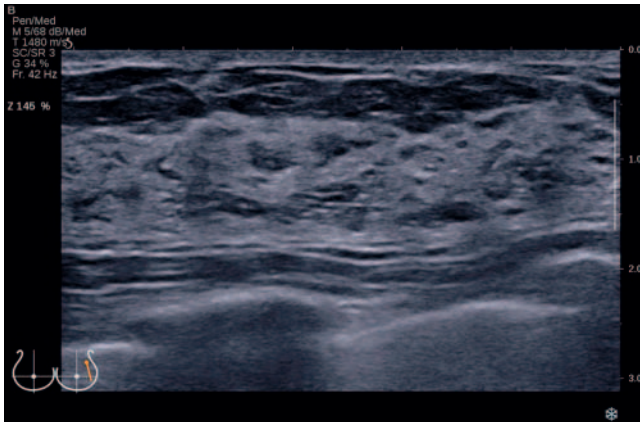
► **Fig. 13** **a** Malignant lymph nodes with asymmetrical enlargement of the hypoechoic cortex. **b** Malignant lymph node with loss of the corticomedullary structure. **c** Malignant lymph node with subcapsular vascularization. **d** Malignant lymph node with extracapsular invasion of the surrounding tissue.



► **Fig. 14** Parenchyma category a, almost entirely fatty tissue, easy to assess.



► **Fig. 15** Parenchyma category b, balanced admixture of fat and fibroglandular tissue, easy to assess.



► **Fig. 16** Parenchyma category c, almost entirely fibroglandular tissue, easy to assess.

5.2. Indications for breast ultrasound

- Clarification of unclear clinical findings (palpation findings, inflammatory changes, conspicuous cutaneous findings, nipple discharge) [9]
- Clarification of mammographic and MRI findings in categories 0, 3, 4, and 5 [9, 25].
- Differentiation between cystic and solid lesions
- In addition to mammography in the case of dense breast tissue
- First imaging choice in women <40 years
- First imaging choice in pregnancy and lactation
- Increased risk of breast cancer
- Follow-up in the case of neoadjuvant chemotherapy
- Ultrasound guidance for puncture procedures, biopsies, and marking [28, 29].
- Intraoperative tumor detection and target control [30, 31]
- Specimen ultrasound [32]
- Evaluation of lymph nodes
- In aftercare in addition to mammography including locoregional lymphatic drainage regions
- Evaluation of implants and their anatomical location [33]

5.3. Ultrasound DEGUM assessment criteria

Focal lesions (► Fig. 18)

- I. Shape:
 - Round
 - Oval
 - Irregular
- II. Axis (orientation):
 - Indifferent
 - Horizontal (parallel to the skin)
 - Vertical (not parallel to the skin)
- III. Margin (boundary):
 - Circumscribed (clear boundary)
 - Not circumscribed (no clear boundary)

Includes: poorly defined, spiculated, angulated, microlobulated, hyperechogenic rim (**caution:** This rim should be included in the measurement)

IV. Echogenicity: – Compared to subcutaneous fat tissue

- Anechoic
- Hypoechoic
- Isoechoic
- Hyperechoic
- Complex cystic and solid
- Heterogeneous (inhomogeneous)

V. Posterior acoustic features:

- Indifferent (no posterior acoustic features)
- Acoustic enhancement
- Acoustic attenuation or shadowing
- Combined pattern/complex behavior

Calcifications:

- Microcalcification in a focal lesion
- Intraductal microcalcification
- Macrocalcification

Suspicion of calcifications must always be correlated with a current mammography examination

Associated features:

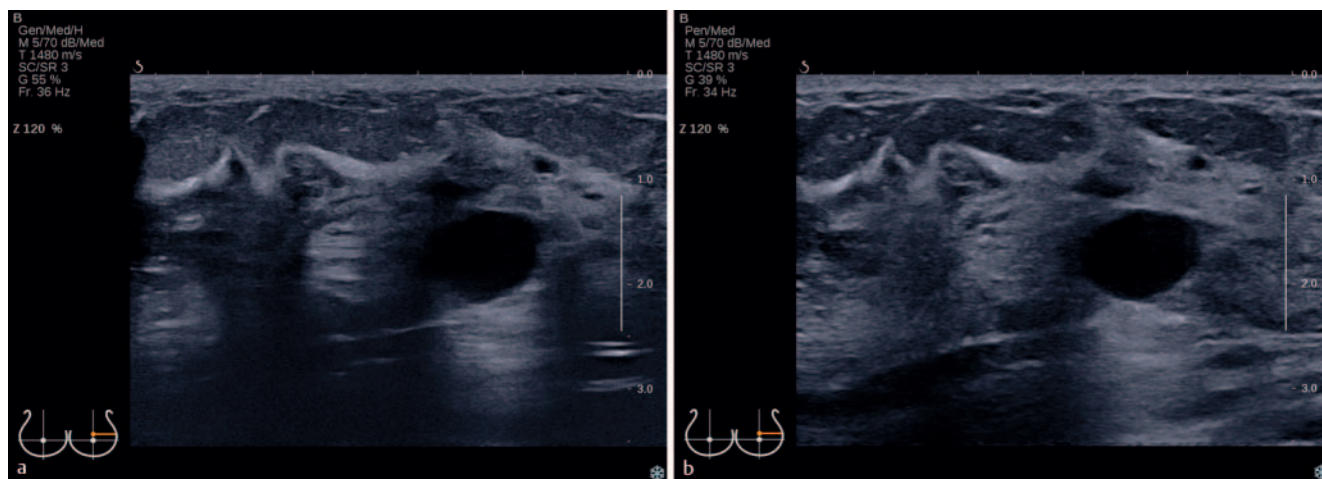
- Architectural distortion
- Ductal changes
- Skin changes
- Edema
- Vascularity – absent, internal vascularity, vascularity in rim
- Elasticity – soft, intermediate, hard

Special cases:

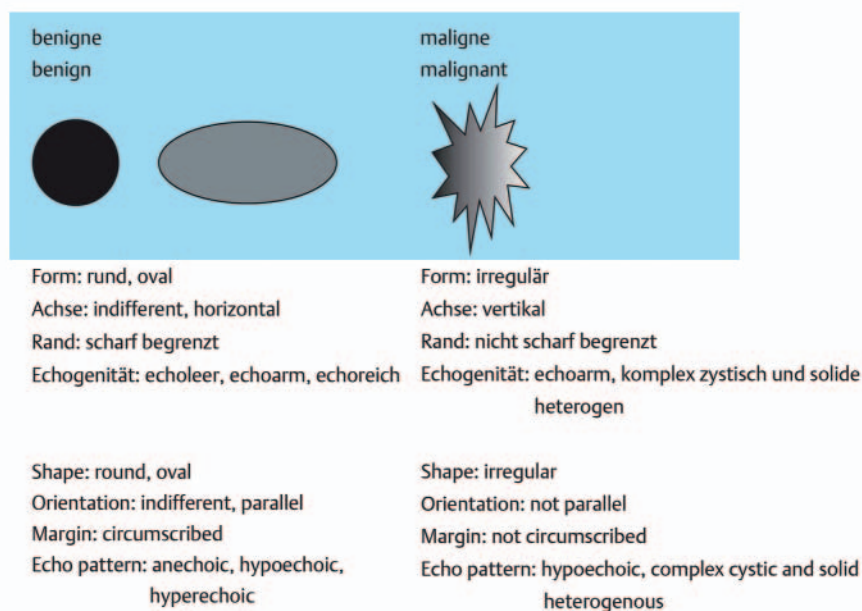
- Simple cysts
- Clustered microcysts
- Complicated cysts
- Lesions in/on the skin
- Foreign body, including implants
- Intramammary lymph nodes
- Locoregional lymph nodes
- Postsurgical fluid collection – seroma, hematoma
- Fat necrosis

5.4. Equipment/image settings

- Use the entire field of view, the thoracic wall is visible on the lower edge of the image (min. 2/3 of the image should contain mammary gland tissue) (► Fig. 19)
- Correct focus setting depending on the location of the lesion (caution: too many foci slow image reconstruction) (► Fig. 19)
- Larger lesions should also be fully visualized if possible – use panorama images or combined separate images
- Adapt the time gain compensation
- Select the highest possible acoustic frequency
 - This improves the detection rate of in-situ carcinomas and increases the sensitivity [34]
 - Recommendation regarding the average transmission frequency: 9–13 MHz; max. 18 MHz in the near field [35]
- Optimize the brightness of the image on the monitor and printer



► **Fig. 17** **a** Parenchyma category d, extreme fibroglandular tissue, without compression, difficult to assess. **b** Parenchyma category d, extreme fibroglandular tissue, same finding as in Fig. 18a but with compression.

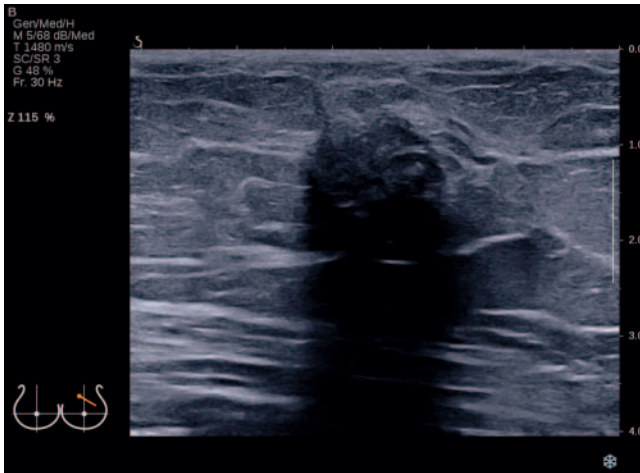

► **Fig. 18** Diagram of the most important assessment criteria for focal lesions with allocation to probably benign and probably malignant findings (based on Madjar et al. [3]).

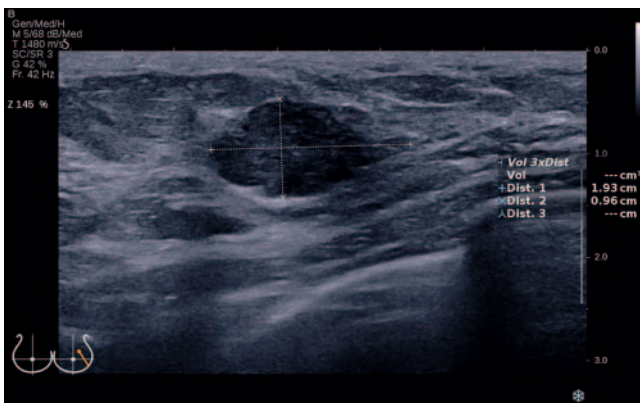
- Compare and use compound imaging, harmonic imaging, and non-contrast-enhanced B-mode imaging for better assessment of the margins of the lesion and the posterior acoustic features [36]

5.5. Image documentation

- Name of the facility
- Examination date
- Patient name/date of birth and/or ID
- Pictogram with correct display of the transducer orientation
- Objectively reproducible measurements of the lesion on two perpendicular planes with specification of three diameters
 - starting from the plane with the greatest diameter and determination of the tumor volume if applicable (► **Fig. 20, 21**).
 - Inclusion of the hyperechoic rim if present.
 - Standardized measurements with the transducer perpendicular to the skin, particularly important for follow-up during neoadjuvant chemotherapy.
 - Skin distance from the tumor: Upper edge of the tumor to the lower edge of the cutis as on-to-on measurement (independent measurement of postoperative, radiogenic, or inflammatory changes of the cutis)
- In the case of multiple lesions, separate documentation with schematic drawing of location



► **Fig. 19** Correct image setting with use of the entire field of view, correct focus setting at the level of the lesion with the lesion in the center of the image.

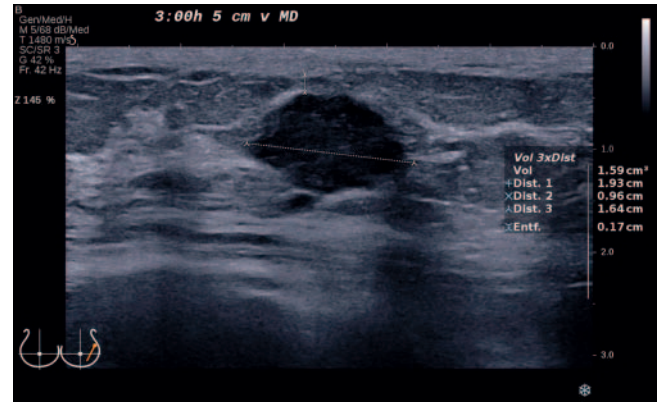


► **Fig. 20** Measurement of two perpendicular diameters in the plane with the greatest lesion diameter. Correct use of the entire field-of-view. Correct display of the transducer in the pictogram.

- If the ultrasound examination is inconspicuous, the minimum documentation (2 images) consists of one image of the upper-outer quadrant on the right and one image of the upper-outer quadrant on the left. Additional image documentation of a representative lymph node of both axillae is recommended.
- In the case of an abnormal ultrasound examination, all conspicuous findings regarding the mammary gland and the loco-regional lymphatic drainage regions should be documented in writing and images. The supraclavicular fossa should also be examined in the case of abnormalities on level II and/or III.

5.6. Documentation of ultrasound findings

- Name of the facility, name of the examiner, date of the examination
- Patient data: Name, date of birth, ID if applicable
- Issue/indication
- Medical history
- Inspection and palpation



► **Fig. 21** Measurement of the third diameter (same lesion as in ► **Fig. 20**) on the plane perpendicular to the first plane and calculation of the tumor volume. Measurement of the distance to the skin (on-to-on). Exact specification of the location. Correct display of the transducer in the pictogram.

■ Assignment of breast ultrasound findings to DEGUM categories

- Description of the lymph nodes
 - Description of the parenchyma and the ability to assess according to parenchyma categories a-d with the addition of “easy or difficult to assess” (see 5.1).
 - Description of suspicious lesions according to the DEGUM assessment criteria (see 5.3)
 - Lesion location data – clockwise orientation, distance from the skin, distance from the nipple (not the areola since it differs in size based on anatomy and can change after pregnancy or surgery)
 - US assessment categories 0–6 (see 5.1)
 - Correlation of findings to symptoms and any preceding ultrasound examinations or other examinations like mammography or MRI
- Recommended procedures

Conflict of Interest

The authors declare that they have no conflict of interest.

References

- [1] Stavros AT, Thickmann D, Rapp CL et al. Solid breast nodules: use of sonography to distinguish between benign and malignant nodules. *Radiology* 1995; 196: 123–134. doi:10.1148/radiology.196.1.7784555
- [2] Ohlinger R, Klein GM, Köhler G. Mamma-Sonographie – Wertigkeit sonographischer Dignitätskriterien für die Differenzialdiagnose solider Herdbefunde. *Ultraschall in Med* 2004; 25: 48–53. doi:10.1055/s-2003-45244
- [3] Madjar H, Ohlinger R, Mundinger A et al. BI-RADS analoge DEGUM Kriterien von Ultraschallbefunden der Brust – Konsensus des Arbeitskreises Mammasonographie der DEGUM. *Ultraschall in Med* 2006; 27: 374–379. doi:10.1055/s-2006-926943
- [4] American College of Radiology (ACR). ACR-BI-RADS® – Ultrasound. In: ACR Breast Imaging Reporting and Data System. Breast Imaging Atlas. In: Reston VA (Hrsg)2003; American College of Radiology.

- [5] Corsetti V, Houssami N, Ferrari A et al. Breast screening with ultrasound in women with mammographic-negative dense breasts: evidence on incremental cancer detection and false positives and associated cost. *Eur J cancer* 2008; 44: 539–544. doi:10.1016/j.ejca.2008.01.009
- [6] Kolb TM, Lichy J, Newhouse JH. Comparison of the performance of screening mammography, physical examination and breast US and evaluation of factors that influence them: an analysis of 27,825 patient evaluations. *Radiology* 2002; 225: 165–175. doi:10.1148/radiol.2251011667
- [7] Gießelman K. Über die Dichte spricht man nicht. *Deutsches Ärzteblatt* 2015; 1118–1119
- [8] Müller-Schimpfle MP, Brandenbusch VC, Degenhardt F. Zur Problematik der dichten Brust – AK Mamasonografie der DEGUM. *Senologie* 2016; 13: 76–81
- [9] Interdisziplinäre S3-Leitlinie Früherkennung, Diagnostik, Therapie und Nachsorge des Mammakarzinoms. Langversion 0.4.0 2017; AWM-F-Registernummer:032-045OL.
- [10] Munding A, Bader W. Rolle der Sonografie bei der Früherkennung des Mammakarzinoms. *TumorDiagn u Ther* 2019; 40: 417–424
- [11] Girardi V, Tonegutti M, Ciatto S et al. Breast ultrasound in 22,131 asymptomatic women with negative mammography. *Breast* 2013; 22: 806–809. doi:10.1016/j.breast.2013.02.101
- [12] Berg WA, Bandos AI, Mendelson EB et al. Ultrasound as the Primary Screening Test for Breast Cancer: Analysis From ACRIN 6666. *J Natl Cancer Inst* 2015; 108: djv367 doi:10.1093/jnci/djv367
- [13] Ohuchi N, Suzuki A, Sobue T et al. Sensitivity and specificity of mammography and adjunctive ultrasonography to screen for breast cancer in the Japan Strategic Anti-cancer Randomized Trial (J-START): a randomised controlled trial. *Lancet* 2016; 387: 341–348. doi:10.1016/S0140-6736(15)00774-6
- [14] Madjar H. Sonoanatomie der Brust. In *Kursbuch Mammasonographie Ein Lehratlas nach Richtlinien der DEGUM und der KBV. 3., komplett aktualisierte Auflage* Stuttgart. New York.: Georg Thieme Verlag; 2012: 47–54
- [15] Gabrielson M, Chiesa F, Behmer C et al. Association of reproductive history with breast tissue characteristics and receptor status in the normal breast. *Breast Cancer Res Treat* 2018; 170: 487–497. doi:10.1007/s10549-018-4768-0
- [16] Olsson H, Jernström H, Alm P et al. Proliferation of the breast epithelium in relation to menstrual cycle phase, hormonal use and reproductive factors. *Breast Cancer Res Treat* 1996; 40: 187–196. doi:10.1007/BF01806214
- [17] Soliman AT, De Sanctis V, Yassin M. Management of Adolescent Gynecomastia: An Update. *Acta Biomed* 2017; 88: 204–213. doi:10.23750/abm.v88i2.6665
- [18] Gruber I, Hahn M, Fehm T et al. Relevance and methods of interventional breast sonography in preoperative axillary lymph node staging. *Ultraschall Med* 2012; 33: 337–343. doi:10.1055/s-0031-1273317
- [19] Choi YJ, Ko EY, Han BK et al. High-resolution ultrasonographic features of axillary lymph node metastasis in patients with breast cancer. *Breast* 2009; 18: 119–122. doi:10.1016/j.breast.2009.2.004
- [20] Wang RY, Zhang YW, Gao ZM et al. Role of sonoelastography in assessment of axillary lymph nodes in breast cancer: a systemic review and metaanalysis. *Clin Radiol* 2020; 75: 320.e1–320.e7. doi:10.1016/j.crad.2019.11.016
- [21] Lin X, An X, Xiang H et al. Ultrasound Imaging for Detecting Metastasis to Level II and III Axillary Nodes after Axillary Lymph Node Dissection for Invasive Breast Cancer. *J Ultrasound Med* 2019; 38: 2925–2934. doi:10.1002/jum.14998
- [22] Qiu SQ, Aarnink M, van Maaren MC et al. Validation and update of a lymph node metastasis prediction model for breast cancer. *Eur J Surg Oncol* 2018; 44: 700–707. doi:10.1016/j.ejso.2017.12.008. Epub 2018 Jan 17.; PMID: 29449047
- [23] Steinkamp HJ, Beck A, Werk M et al. Kapseldurchbrüche zervikaler Lymphknotenmetastasen: Diagnostischer Stellenwert der Sonographie. *Ultraschall in Med* 2003; 24: 323–330. doi:10.1055/s-2003-42914
- [24] Mueller-Schimpfle MP, Brandenbusch VC, Degenhardt F et al. The Problem of Mammographic Breast Density – The Position of the DEGUM Working Group on Breast Ultrasound. *Ultraschall in Med* 2016; 37: 170–175. doi:10.1055/s-0041-108004
- [25] Müller-Schimpfle M et al. Diskussionspapier – BI-RADS die 5. – eine Kurzmiteilung aus deutsch-/österreichischer Sicht. *Geburtshilfe Frauenheilkd* 2016; 76: 490–496
- [26] Hrsg. American College of Radiology. ACR BI-RADS® Atlas der Mammadiagnostik. Richtlinien zur Befundung, Managementempfehlungen und Monitoring. Deutsche Übersetzung der 5. Englischen Auflage, 2013 Berlin. Heidelberg: Springer Verlag; 2016
- [27] Mendelson EB, Böhm-Velez M, Berg WA et al. ACR BI-RADS® – Ultrasound. In ACR BI-RADS® Atlas, Breast Imaging Reporting and Data System. Reston, VA, American College of Radiology; 2013.
- [28] Gruber I, Oberlechner E, Heck K et al. Percutaneous Ultrasound-Guided Core Needle Biopsy: Comparison of 16-Gauge versus 14-Gauge Needle and the Effect of Coaxial Guidance in 1065 Breast Biopsies – A Prospective Randomized Clinical Noninferiority Trial. *Ultraschall in Med* 2020; 41: 534–543. doi:10.1055/a-1014-2628
- [29] Hahn M, Krainick-Strobel U, Toellner T et al. Interdisciplinary consensus recommendations for the use of vacuum-assisted breast biopsy under sonographic guidance: first update 2012. *Ultraschall in Med* 2012; 33: 366–371. doi:10.1055/s-0032-1312831
- [30] Hoffmann J, Marx M, Hengstmann A et al. Ultrasound-Assisted Tumor Surgery in Breast Cancer – A Prospective, Randomized, Single-Center Study (MAC 001). *Ultraschall in Med* 2019; 40: 326–332. doi:10.1055/a-0637-1725
- [31] Krekel NM, Haloua MH, Lopes Cardozo AM et al. Intraoperative ultrasound guidance for palpable breast cancer excision (COBALT trial): a multicentre, randomised controlled trial. *Lancet Oncol* 2013; 14: 48–54. doi:10.1016/S1470-2045(12)70527-2
- [32] Olsha O, Shemesh D, Carmon M et al. Resection margins in ultrasound-guided breast-conserving surgery. *Ann Surg Oncol* 2011; 18: 447–452. doi:10.1245/s10434-010-1280-0
- [33] Hahn M, Kuner RP, Scheler P et al. Sonographic criteria for the confirmation of implant rotation and the development of an implant-capsule-interaction (“interface”) in anatomically formed textured breast implants with texturised Biocell-surface. *Ultraschall in Med* 2008; 29: 399–404. doi:10.1055/s-2007-963020
- [34] Schulz-Wendtland R, Bock K, Aichinger U et al. Mamma-Sonographie mit 7,5 MHz versus 13 MHz: Ist eine Verbesserung der diagnostischen Sicherheit im Rahmen der komplementären Mammadiagnostik möglich? *Ultraschall in Med* 2005; 26: 209–215. doi:10.1055/s-2005-857897
- [35] Eisenbrey JR, Dave JK, Forsberg F. Recent technological advancements in breast ultrasound. *Ultrasonics* 2016; 70: 183–190. doi:10.1016/j.ultras.2016.04.021. Epub 2016 Apr 25
- [36] Hahn M, Roessner L, Krainick-Strobel U et al. [Sonographic criteria for the differentiation of benign and malignant breast lesions using real-time spatial compound imaging in combination with XRES adaptive image processing]. *Ultraschall in Med* 2012; 33: 270–274. doi:10.1055/s-0029-1245497