




Quality Requirements for gynecological ultrasound examinations of DEGUM level II

Recommendations of the Sections/Working Groups Gynecology and Obstetrics of DEGUM, ÖGUM and SGUM

Qualitätsanforderungen an die gynäkologischen Ultraschalluntersuchungen der DEGUM Stufe II

Empfehlungen der Sektionen/Arbeitskreise Gynäkologie und Geburtshilfe der DEGUM, ÖGUM und SGUM

Authors

Markus Hoopmann¹, Boris Tutschek², Eberhard Merz³, Karl-Heinz Eichhorn⁴, Karl Oliver Kagan¹, Kai-Sven Heling⁵, Renaldo Faber⁶, Andreas Rempfen⁷, Christiane Kaehler⁸, Gwendolin Manegold-Brauer⁹, Samir Helmy¹⁰, Philipp Klaritsch¹¹, Dieter Grab¹²

Affiliations

- 1 Department of Obstetrics and Gynaecology, University of Tübingen, Tübingen, Germany
- 2 Prof. Tutschek, Prenatal Zürich, Zürich, Switzerland
- 3 Centre for Ultrasound and Prenatal Medicine, Frankfurt/Main, Germany
- 4 Gynäkologie und Geburtshilfe, Praxis für Pränatalmedizin, Weimar, Germany
- 5 Praxis, Prenatal Diagnosis and Human Genetics, Berlin, Germany
- 6 Leipzig, Center of Prenatal Medicine, Leipzig, Germany
- 7 Frauenklinik, Evangelisches Diakoniekrankenhaus, Schwäbisch-Hall, Germany
- 8 Obstetrics and Gynecology, Praxis für Pränatalmedizin, Erfurt, Germany
- 9 Department of Prenatal Medicine and Gynecologic Ultrasound, University Hospital Basel, Switzerland
- 10 Department of Obstetrics and Gynecology, Medical University of Vienna, Austria
- 11 Department of Obstetrics and Gynecology, Medical University Graz, Austria
- 12 Department of Obstetrics and Gynecology, University of Ulm, Germany

Key words

gynecology, level 2, education, training, quality assurance

received 07.06.2021

accepted 20.09.2021

published online 08.11.2021

Bibliography

Ultraschall in Med 2022; 43: 146–158

DOI 10.1055/a-1663-6322

ISSN 0172-4614

© 2021. Thieme. All rights reserved.

Georg Thieme Verlag KG, Rüdigerstraße 14, 70469 Stuttgart, Germany

Correspondence

Prof. Markus Hoopmann

Department of Obstetrics and Gynecology, University of Tübingen, Calwer Str. 7, 72076 Tübingen, Germany

Tel.: +49/70 71/29 85 57 66

Fax: +49/70 71/29 56 19

mhoopmann@gmx.de

ABSTRACT

Gynecological sonography is the central and most frequently used technical examination method used by gynecologists. Its focus is on the clarification of masses of the uterus and the adnexa, fertility diagnosis, clarification of bleeding disorders and chronic and acute pelvic problems, pelvic floor and incontinence diagnosis as well as the differential diagnosis of disturbed early pregnancy. The indication for diagnostic and therapeutic interventions, preoperative planning and postoperative controls are largely based on the findings of gynecological sonography. These examinations are particularly dependent on the experience of the examiner.

Based on the proven multi-stage concept of obstetric diagnostics, gynecological sonography should primarily be performed by an experienced and specialized examiner in patients for whom the initial gynecological examinations have not yet led to a sufficient assessment of the findings. So that the expert status required for this has an objective basis, the Gynecology and Obstetrics Section of DEGUM in coopera-

tion with ÖGUM and SGUM implemented the option of acquiring DEGUM Level II for gynecological sonography. The effectiveness of the care in the multi-level concept depends on the quality of the ultrasound examination at level I. Quality requirements for the basic examination and the differentiation between the basic and further examination have therefore already been defined by DEGUM/ÖGUM. The present work is intended to set out quality requirements for gynecological sonography of DEGUM level II and for the correspondingly certified gynecologists.

Common pathologies from gynecological sonography and requirements for imaging and documentation are described.

ZUSAMMENFASSUNG

Die gynäkologische Sonografie ist das zentrale und am häufigsten angewandte apparative Untersuchungsverfahren der Frauenärzt*innen. Ihre Schwerpunkte sind die Abklärung von Raumforderungen des Uterus und der Adnexen, die Fertilitätsdiagnostik, Abklärung von Blutungsstörungen und chronischen wie akuten Unterbauchbeschwerden, die Beckenboden- und Inkontinenzdiagnostik sowie die Differentialdiagnostik der gestörten Frühschwangerschaft. Die Indikation zu diagnostischen und therapeutischen Interventionen, die präoperative Planung und die postoperativen Kontrollen beruhen maßgeblich auf Befunden der gynäkologischen Sonografie. Diese Untersuchun-

gen sind im besonderen Maße von der Erfahrung des Untersuchers abhängig.

In Anlehnung an das bewährte Mehrstufenkonzept der geburtshilflichen Diagnostik sollte daher bei Patientinnen, in denen die frauenärztlichen Erstuntersuchungen noch nicht zu einer ausreichenden Einschätzung der Befunde führen, primär eine gynäkologische Sonografie durch einen erfahrenen und spezialisierten Untersucher erfolgen. Damit der hierfür erforderliche Expertenstatus eine objektivierbare Grundlage bekommt, wurde von der Sektion Gynäkologie und Geburtshilfe der DEGUM in Kooperation mit der ÖGUM und SGUM die Möglichkeit des Erwerbs der DEGUM-Stufe II für die gynäkologische Sonografie implementiert. Die Effektivität der Versorgung im Mehrstufenkonzept lebt aber von der Qualität der Ultraschalluntersuchung auf Stufe I. Qualitätsanforderungen für die Basisuntersuchung und die Differenzierung zwischen Basis- und weiterführender Untersuchung wurden daher bereits von der DEGUM/ÖGUM definiert. Die vorliegende Arbeit soll Qualitätsanforderungen an eine gynäkologische Sonografie der DEGUM-Stufe II und an die entsprechend zertifizierten Frauenärztinnen und Frauenärzte darlegen.

Häufige Pathologien aus der gynäkologischen Sonografie und Anforderungen an die Bildgebung und Dokumentation werden beschrieben.

Objective

Gynecological sonography is the primary and most frequently used examination method used by gynecologists. It focuses on the clarification of uterine and adnexal masses, fertility diagnostics, clarification of bleeding disorders and chronic as well as acute lower abdominal complaints, pelvic floor and incontinence diagnostics as well as differential diagnostics of early pregnancy disturbances. The indication for diagnostic and therapeutic interventions, preoperative planning, and postoperative controls are largely based on findings of gynecologic sonography. These examinations are particularly dependent on the experience of the examiner [1–5].

The potential of MRI, CT, and PET as second-line diagnostics is undisputed, but unfortunately, gynecological issues are currently still being addressed in an unfocused manner by cost-intensive, partly radiation-intensive, and non-specialized techniques. This lack of confidence in gynecologic diagnostics is not evidence- or guideline-based [6]. Other radiological methods are not superior with respect to most issues; radiological cross-sectional imaging techniques can provide relevant information in only a few selected specific issues [7–15]. Such unnecessary use can cause treatment delays, suboptimal treatment rates, and primary over- and under-treatment if the therapeutic and care pathways of gynecological patients do not remain under the direction of gynecologists [16–18].

Imaging diagnostics are of central importance and are the focus of this study. However, it should not be forgotten that patient

history as well as clinical and laboratory parameters are also of crucial importance for diagnosis.

Following the proven multistage concept of obstetric diagnostics, gynecologic sonography by an experienced specialized examiner should therefore be performed primarily on patients in whom the initial gynecologic examinations have not yet led to an adequate assessment of the findings. In order to provide an objective basis for the expert status required for this purpose, the Gynecology and Obstetrics section of the German Society for Ultrasound in Medicine (DEGUM), in cooperation with its Austrian and Swiss counterparts (ÖGUM/SGUM), has implemented the possibility of acquiring DEGUM Level II for gynecologic sonography. However, the effectiveness of care in the multilevel concept is based on the quality of the ultrasound examination at Level I. Quality requirements for the baseline examination and the differentiation between baseline and follow-up examinations have therefore already been defined by DEGUM/ÖGUM [19]. The purpose of this paper is to present quality requirements for DEGUM Level II gynecologic sonography and as well as appropriate certification of for gynecologists.

Common pathologies seen in gynecological sonography and imaging and documentation requirements are described. This compilation is based on frequency, clinical relevance, evidence, and anchoring in current guidelines and does not claim to be exhaustive.

Pathologies of the Uterus

Pathologies of the myometrium

The main requirement for advanced sonography of the myometrium is the description of masses, especially the differentiation between fibroids and adenomyosis (► Fig. 1d–f).

The reporting and documentation of a normal finding or pathological findings should include the items listed in ► Table 1 [20, 21] (► Fig. 2, 3).

Fibroids represent the most common benign tumors of the uterus. Depending on their location, a distinction is made among subserosal, intramural and submucosal fibroids. A round shape and hypoechogenic structure are typical. In regressively altered fibroids, calcifications are also found as anechoic foci within the resistance. Color Doppler typically reveals vessels predominantly in the marginal area of the fibroids.

3D sonography is a suitable additive method for the evaluation of the myometrium and the endo-myometrial junction.

Despite the rarity of the pathology (0.3–0.4/100 000), the distinction between myoma and sarcoma is a common issue faced by sonographic as well as radiological imaging. In most cases, a sufficiently preoperative diagnosis is not possible [22]. If a patient presents with a question of sarcoma risk, the risk stratification criteria summarized in ► Table 2 should be reviewed [23, 24].

Cervical cancer

In addition to gynecological palpation and speculum examination, transvaginal sonography is a component of the primary gynecologic diagnosis of cervical cancer. In adenocarcinoma, cervical carcinoma is usually a hyper- or isoechogenic mass, whereas squamous cell carcinoma is usually hypoechogenic (► Fig. 1m1). The task of advanced sonography is to supplement preoperative staging [26, 26]. The sonographic criteria have been summarized in ► Table 3.

Optional methods not proven by larger studies include 3D (power) Doppler sonography (► Fig. 1m2), tomographic 3D sonography and elastography [27, 28]. 3D ultrasonography can spatially visualize abnormal perfusion within the cervix.

Uterine malformations

An accurate description of findings and classification of congenital uterine anomalies is essential for prognostic assessment and treatment planning. The diagnostic tool of choice is 3D sonography performed by an experienced examiner. Unfortunately, clinical practice often shows incorrect nomenclature.

Correct description of findings according to classifications and guidelines is decisive, but none of these guidelines are universally accepted [29].

- Classification according to the American Fertility Society/ASRM [30]
- VCUAM classification [31]
- Classification according to ESHRE/ESGE [11, 32]

In principle, diagnostic procedures in childhood and adolescence should be limited to as few invasive measures as possible, and radiation exposure should be kept to a minimum.

The clinically rare Uterus didelphys can usually be diagnosed by two-dimensional imaging of 2 completely separated (hemi-) uteri. Particular attention should also be paid to the detection of 2 cervixes. The two (hemi-) uteri are usually displaced towards the pelvic walls.

Conspicuous width of the uterus is an initial sonographic criterion for most uterine malformations. In cross section, two lateralized endometrial sections are still visible close to the fundus (► Fig. 1g). The cavum shape is more recognizable by the endometrium, which is thicker and more echogenic during the secretory phase of the cycle.

After orientation by 2D ultrasonography, the use of 3D ultrasonography in specification is the method of choice, as it is the only one that allows accurate assessment of the cavum shape and the external fundal contour.

Most studies show a sensitivity of 3D ultrasound of more than 92% for the correct detection of uterine malformation and at least an equivalence to MRI [11, 33–35].

The most common issue is the differentiation between the common septate or subseptate uterus and the comparatively rare bicornate uterus, which due to different therapeutic approaches, is of significant relevance. The separate assessment of the external and internal fundus contours in relation to the uterine cavity in an exact coronary plane is crucial. Here, the connecting line between the two ostia is considered the reference plane. In the case of subseptate uterus, there is an intracavitary indentation greater than 50% of the myometrial fundus thickness or > 1 cm (► Fig. 1h) [11, 36].

In a bicornate uterus, the fundus is externally retracted more than 50% of the myometrial fundus thickness or > 1 cm [11, 36] 3D (transvaginal) sonography is essential for biometrically-anchored classification according to ESHRE/ESGE [37].

The cervix must also be evaluated in addition to assessment of the shape of the fundus. If there are two broad cervical parts which diverge in the lower section, a double cervix rather than a septated cervix must be assumed.

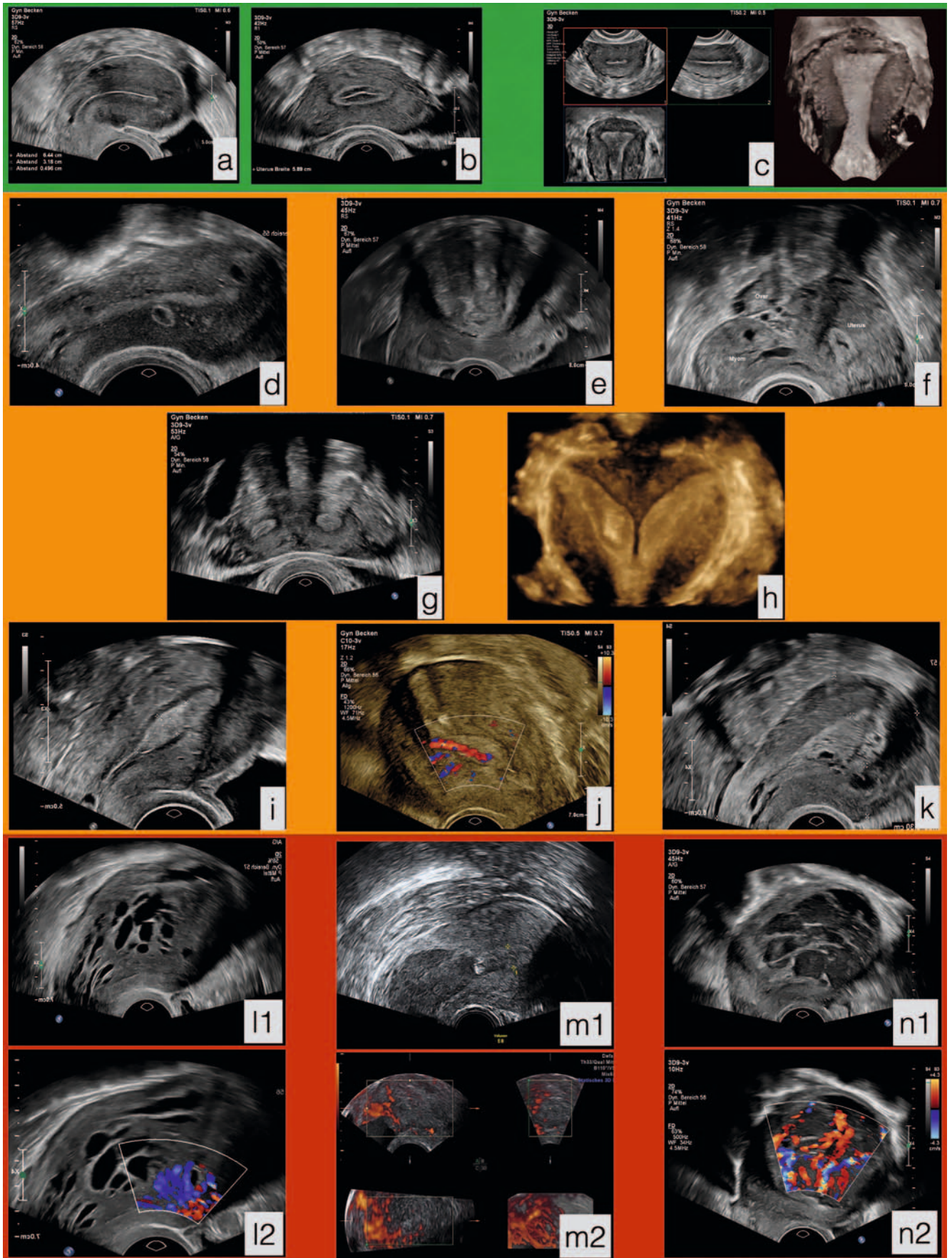
Intracavitary pathologies/endometrial assessment

Deviations from the normal endometrial structure can be caused by

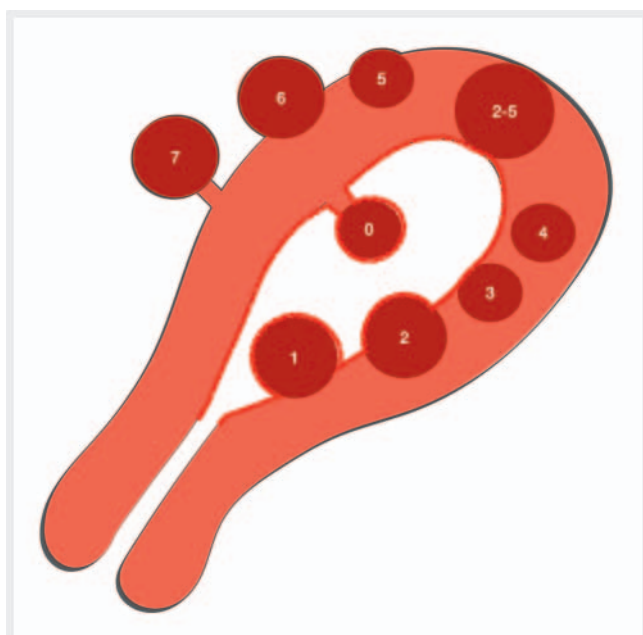
- endometrial hyperplasia (► Fig. 1k)
- endometrial carcinoma (► Fig. 1l1, l2)
- endometrial polyps (► Fig. 1i, j)
- intracavitary myomas
- synechiae

Findings and documentation of intracavitary pathologies in advanced sonography should be based on the criteria compiled in ► Table 4 [38–41].

3D sonography as well as sonohysterography can also provide additional information for the evaluation of the uterine cavity. In particular, coronary imaging of the uterine cavity makes it possible to obtain additional information using the 2D mode [42].



► **Fig. 1** Example findings of transvaginal ultrasonography of the uterus: physiological normal findings highlighted in green, benign changes highlighted in yellow, malignant changes highlighted in red. **a** Median longitudinal section of the uterus in the proliferation phase. **b** Mid-cycle cross-section of uterus. **c** 3D sonographic imaging of the uterus in multiplanar mode and coronary surface mode. **d** Median longitudinal section of uterus adenomyosis, numerous cystic lesions of the myometrium of varying caliber, some subendometrial, irregular EMJ. **e** Median longitudinal section of uterus with intramural myoma of posterior wall (FIGO 2–5), protrusion to serosa as well as to uterine cavity, largest diameter 4.9 cm, no measurable myometrial interstitial space, round shape, streaky acoustic shadows, smooth margin, isolated hyperechogenic central areas. **f** Cross-section of uterus showing a pedunculated round myoma (FIGO 7), 3.8 cm largest diameter, smooth margin, no acoustic shadows. **g** 2D sonographic image of a uterine septum in cross section with 2 endometrial reflexes separated by a myometrial bridge (“owl-eye” phenomenon). **h** 3D sonographic image of a subseptate uterus. **i** Median longitudinal uterine section showing a central endometrial polyp. **j** Color Doppler sonographic image of a single-feeder-vessel in an endometrial polyp. **k** Sagittal uterine longitudinal section with glandular cystic endometrial hyperplasia. **l** High-grade serous endometrial carcinoma, FIGO Stage II. **l1** Sagittal longitudinal uterine section with macrocystic-solid, highly built-up endometrium (4.6 cm wide), no midline, raised EMJ and deep myometrial infiltration > 50 % of wall thickness, cervical infiltration. **l2** Color Doppler image of tumor vascularization: Color score 4, sprouting of multiple, bundled tumor vessels with high vessel density and multiple branching. **m** Cervical cavity carcinoma. **m1** Sagittal longitudinal section of uterus with extensive hypoechoic mass in the cervical region. **m2** 3D Power Doppler-sonography: pronounced neovascularization. **n** High-grade endometrial stromal sarcoma pT1c. **n1** Sagittal longitudinal uterine section with oval predominantly hypoechoic mass extending 5.5 cm, no acoustic shadows. **n2** Color Doppler sonographic image: color score 4, prominent tumor vascularization with different calibers.



► **Fig. 2** Schematic representation of FIGO myoma classifications 1–7. 0 = pedunculated intracavitary; 1 = submucosal, < 50 % intramural; 2 = submucosal, ≥ 50 % intramural; 3 = 100 % intramural but in contact with endometrium; 4 = intramural; 5 = subserous, ≥ 50 % intramural; 6 = subserous, < 50 % intramural; 7 = pedunculated subserous; 8 = other (e. g., parasitic) [21].

It should be kept in mind that in approximately 10 % of examinations, the endometrium cannot be viewed and measured with sufficient certainty using transvaginal 2D ultrasonography. Therefore these additive methods should be used liberally in suspected cases.

Endometrial carcinoma

Postmenopausal bleeding is the leading clinical symptom of endometrial carcinoma.

The sonographic criteria of endometrial carcinoma are [41, 43]:

- increased endometrial thickness (at least > 4 mm, average between 11–26 mm)
- heterogeneous endometrium structure
- indistinct center line
- evidence of multiple, partially bundled vessels sprouting into the endometrium

Infiltration of the cervix as well as myometrial infiltration depth are easily assessable by transvaginal sonography; it supports preoperative staging and should be integrated into the description of findings [44].

Fallopian Tube Pathologies

Hydrosalpinx/saktosalpinx

Hydrosalpinx or saktosalpinx results from a functional obstruction of the tubes and accumulation of secretions in their lumen, often initially due to inflammation. Detection is particularly important when diagnosing infertility. The differentiation from ovarian cystic lesions is a challenge to differential diagnosis.

Typical manifestation in sonography includes:

- tubular, tortuous cystic mass
- evidence of pseudosepta (► **Fig. 4**)
- echogenic, roundish wall deposits (beads-on-a-string) and “cogwheel” sign in cross-section due to deposits (► **Fig. 5**).
- possibly a demarcation to a normal adjacent ovary can be shown

3D sonography can be helpful to demonstrate the tortuous cannular shape of the cystic distention of the tube [45].

Tubo-ovarian abscess

The sonographic evaluation of a tubo-ovarian abscess can be difficult in terms of differential diagnosis, since the picture can be heterogeneous and resembles malignant adnexal findings due to the formation of a conglomerate as well as strong vascularization (► **Fig. 6, 7**). Pain is the dominant clinical symptom which can usually be specifically provoked by careful use of a transvaginal probe, together with inflammation.

► **Table 1** Sonographic criteria for further evaluation of the myometrium.

NORMAL FINDING	
Criterion	Documentation
Size of uterus and cervix	<ul style="list-style-type: none"> Measurement of length and anterior-posterior diameter in median longitudinal section Measurement of transverse diameter in transverse or coronal section
External (serosal) contour of uterus	<ul style="list-style-type: none"> Smooth Irregular Bulging Retraction
Relationship of anterior and posterior uterine wall	<ul style="list-style-type: none"> Asymmetry? Ratio between anterior and posterior wall
Echogenicity of myometrium	<ul style="list-style-type: none"> Homogeneous Inhomogeneous
PATHOLOGY (including myomas, adenomyosis)	
Number	
Location	<ul style="list-style-type: none"> FIGO-classification 1–7 (► Fig. 2) [21]
Size	<ul style="list-style-type: none"> Measurement in 3 planes
Free margin	<ul style="list-style-type: none"> Direct distance of lesion to serosa and endometrium
Shape	<ul style="list-style-type: none"> Round Oval Irregular Easily distinguished Poorly distinguished
Border contour	<ul style="list-style-type: none"> Smooth Irregular
Acoustic shadows	<ul style="list-style-type: none"> None Streaky/fan-like Entire
Cystic portions	
Hyperechogenic portions	<ul style="list-style-type: none"> Hyperechogenic islands Calcifications
Subendometrial-myometrial junctional zone (EMJ)	<ul style="list-style-type: none"> Visualizable Regular Discontinuous
Doppler sonography (color Doppler, power Doppler)	<ul style="list-style-type: none"> Color score 1–4 (► Fig. 3) Vessel distribution, density, morphology

Sonographically, the cystic parts are never anechoic, but are usually hypoechoic with a ground glass-like part (pus), which can be sharply separated by sludge [46].

► **Table 2** Sonographic criteria in risk assessment of sarcoma (► **Fig. 1n1, n2**).

Sarcoma criteria
<ul style="list-style-type: none"> Irregular margins
<ul style="list-style-type: none"> Central necrosis, mixed echogenicity
<ul style="list-style-type: none"> Oval, single masses
<ul style="list-style-type: none"> Moderate to very pronounced vascularization (color score 3–4, see ► Fig. 3), irregular prominent vessels
<ul style="list-style-type: none"> Rapid growth (> 20 % volume within 3 months)
<ul style="list-style-type: none"> Atypical growth (e. g. under GNRH or in postmenopause)
<ul style="list-style-type: none"> Absence of calcifications
<ul style="list-style-type: none"> Absence of myoma-typical acoustic shadows

Ectopic pregnancy/tubal pregnancy

Preoperative diagnosis of ectopic pregnancy relies primarily on combined serologic assessment of HCG progression and transvaginal sonography [47, 48].

Since this should already be mastered in the daily basic diagnostics, the criteria are presented in the soon to be published requirements of DEGUM Level I and at this point are only referred to [49, 50].

Ectopic pregnancies outside the fallopian tube are much rarer and diagnostically and therapeutically challenging; in which case specialized management is required. In particular, interstitial pregnancies, cesarean scar pregnancies, and cervical pregnancies should be considered.

Tubal carcinoma

In recent years, the fallopian tube has been discussed as an underestimated starting point of ovarian cancer. As a rule, differentiation from ovarian carcinoma is only successful if the tumor is clearly distinct from the ovary. Typical tubular carcinoma presents as an elongated rigid structure with irregular internal echomorphic pattern and increased perfusion on color Doppler examination.

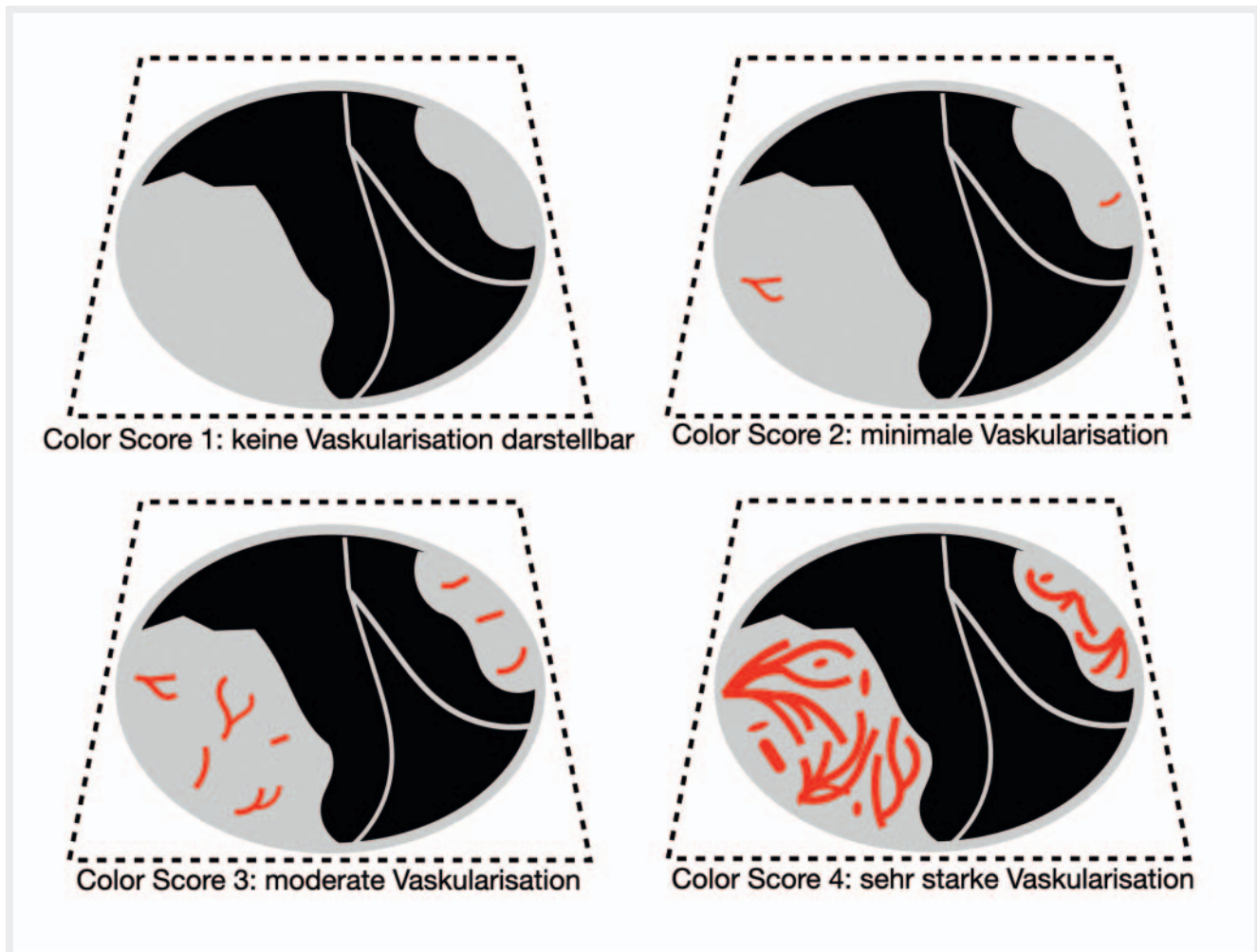
Pathologies of the Ovary

The most important aspects of further examination of the ovary are to differentiate functional from pathologic changes of the ovary, to assess the risk of malignancy, and to attempt histopathologic classification. ► **Table 5** summarizes the sonographic criteria which, according to current evidence, have proved particularly useful in the assessment of ovarian findings [49–51].

3D ultrasonography and 3D power Doppler imaging can make an additional diagnostic contribution in certain cases [52].

Common benign ovarian findings

Pathologies with common pathognomonic sonographic appearance include:



► **Fig. 3** Color score 1–4 scheme for subjective assessment of color Doppler in gynecologic sonography [52].

► **Table 3** Sonographic criteria for further evaluation of cervical cancer.

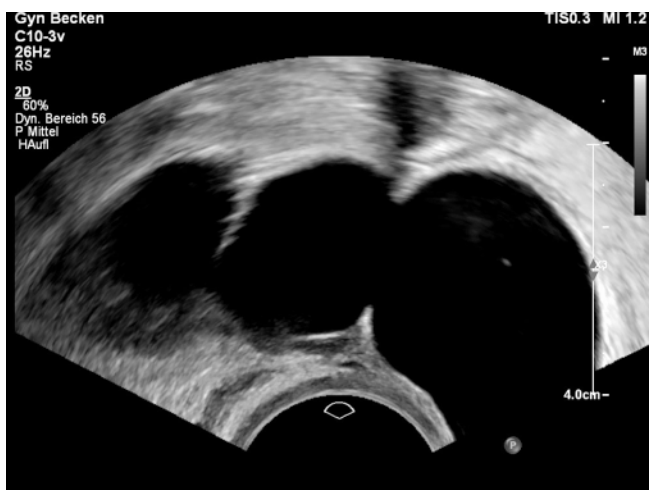Criterion	Sonographic manifestation
Tumor size > 4 cm	<ul style="list-style-type: none"> ▪ Sensitivity for detection of aforementioned criterion: 78 % ▪ Specificity 99 %
Stromal infiltration > 2/3 of wall thickness	<ul style="list-style-type: none"> ▪ Sensitivity for detection of aforementioned criterion: 88–91 % ▪ Specificity 93–97 %
Parametrial infiltration	<ul style="list-style-type: none"> ▪ Sensitivity for detection of aforementioned criterion: 60–83 % ▪ Specificity 89–100 %
Measurement of distance of tumor to internal orifice	<ul style="list-style-type: none"> ▪ TVS means of choice to assess possibility of fertility-saving surgery ▪ Estimation of the expected functional residual cervix length
Doppler sonography	<ul style="list-style-type: none"> ▪ Visualization of tumor vascularization ▪ 3D (power) Doppler sonography as needed

- simple (para-)ovarian cysts (► **Fig. 8e**),
- endometrioma (► **Fig. 8f**)
- mature teratomas/dermoid cysts (► **Fig. 8g**)
- serous or mucinous cystadenomas (► **Fig. 8h, i**) and
- fibromas (► **Fig. 8k**) [51, 53].

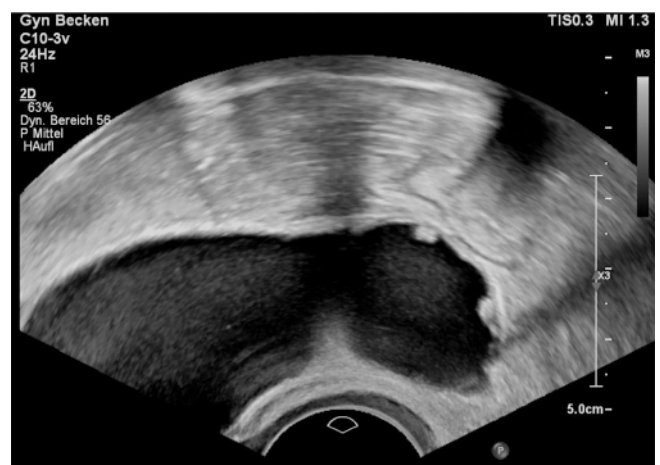Therefore, these benign diagnoses should be evaluated, detected and documented in a targeted manner within the framework of further sonographic diagnostics.

► **Table 4** Sonographic criteria for further evaluation of intracavitary pathologies.

Criterion	
Endometrial thickness	<ul style="list-style-type: none"> Maximum measured height in sagittal sectional plane Includes both halves of endometrium Sonic alignment 90° to uterine longitudinal axis
Echogenicity	<ul style="list-style-type: none"> Consistent Heterogeneous Hyperchogenic Isochogenic Hypoechochogenic (in relation to myometrium)
Endometrium midline	<ul style="list-style-type: none"> Linear Non-linear Irregular Not delimitable
Subendometrial-myometrial junctional zone (EMJ)	<ul style="list-style-type: none"> Regular Irregular Discontinuous Not delimitable
Bright edge	<ul style="list-style-type: none"> Echogenic border zone between intracavitary lesion und endometrium
Intracavitary fluid collection	<ul style="list-style-type: none"> Greatest diameter in sagittal plane
Synechia	<ul style="list-style-type: none"> Tissue strings crossing the cavity of bridging the endometrium
Color Doppler	<ul style="list-style-type: none"> Color score 1–4 (► Fig. 3)
Vascular pattern in power Doppler	<ul style="list-style-type: none"> Dominant vessel Multiple vessels Extending individually Bundled Branched Scattered Ring-shaped



► **Fig. 4** Hydrosalpinx with typical pseudosepta.

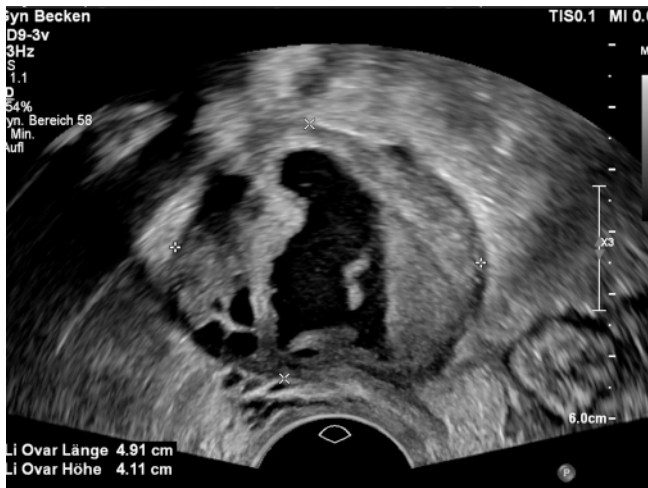

► **Fig. 5** Hydrosalpinx with small rounded echogenic wall deposits (“beads-on-a-string”).

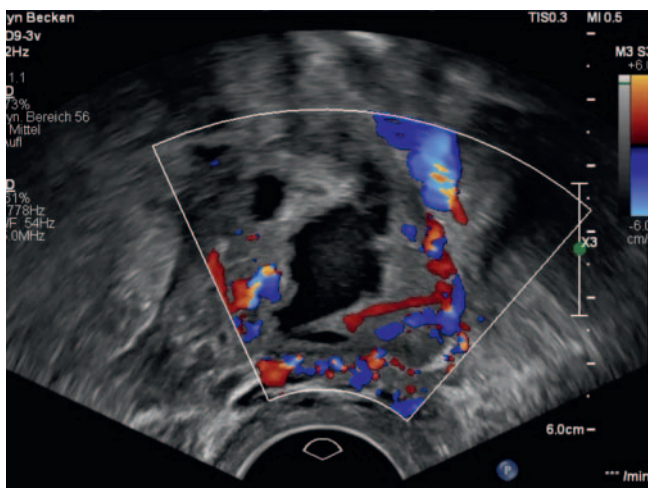
Ovarian torsion

The diagnosis of ovarian torsion is based on the combination of clinical symptoms and sonographic criteria, as summarized in ► **Table 6** [54].

Suspected torsion is an emergency diagnosis; consequently, there is no time for multi-level diagnostics in most cases. Therefore, it should be possible to make the diagnosis promptly even using basic diagnostics [10].



► **Fig. 6** Tubo-ovarian abscess: multilocular solid conglomerate tumor, echoic cyst contents with sludge.



► **Fig. 7** Color Doppler image of tubo-ovarian abscess: marked increased perfusion, color score 4.

Endometriosis

Manifestation of endometriosis is very heterogeneous. Preoperative diagnosis of propagation is important for surgical planning. According to the guidelines, a multistage diagnosis should be performed according to internationally established assessment criteria [55–57]:

Basic diagnostics should detect endometriomas and adenomyosis.

Then dynamic transvaginal sonography should be used to check the mobility of the adnexa, uterus, and surrounding structures. Markers of endometriosis and adhesions triggered by it may include fixation of the ovaries to each other so that they appear adjacent and on one image, or as an adherence to the uterus. Fixed retroflexion of the uterus is a sign of uterine adhesions (question mark sign).

The Douglas space is examined in the next examination step by gentle pressure of a vaginal probe against the cervix and simulta-

► **Table 5** Sonographic criteria for further evaluation of the ovary (according to IOTA).

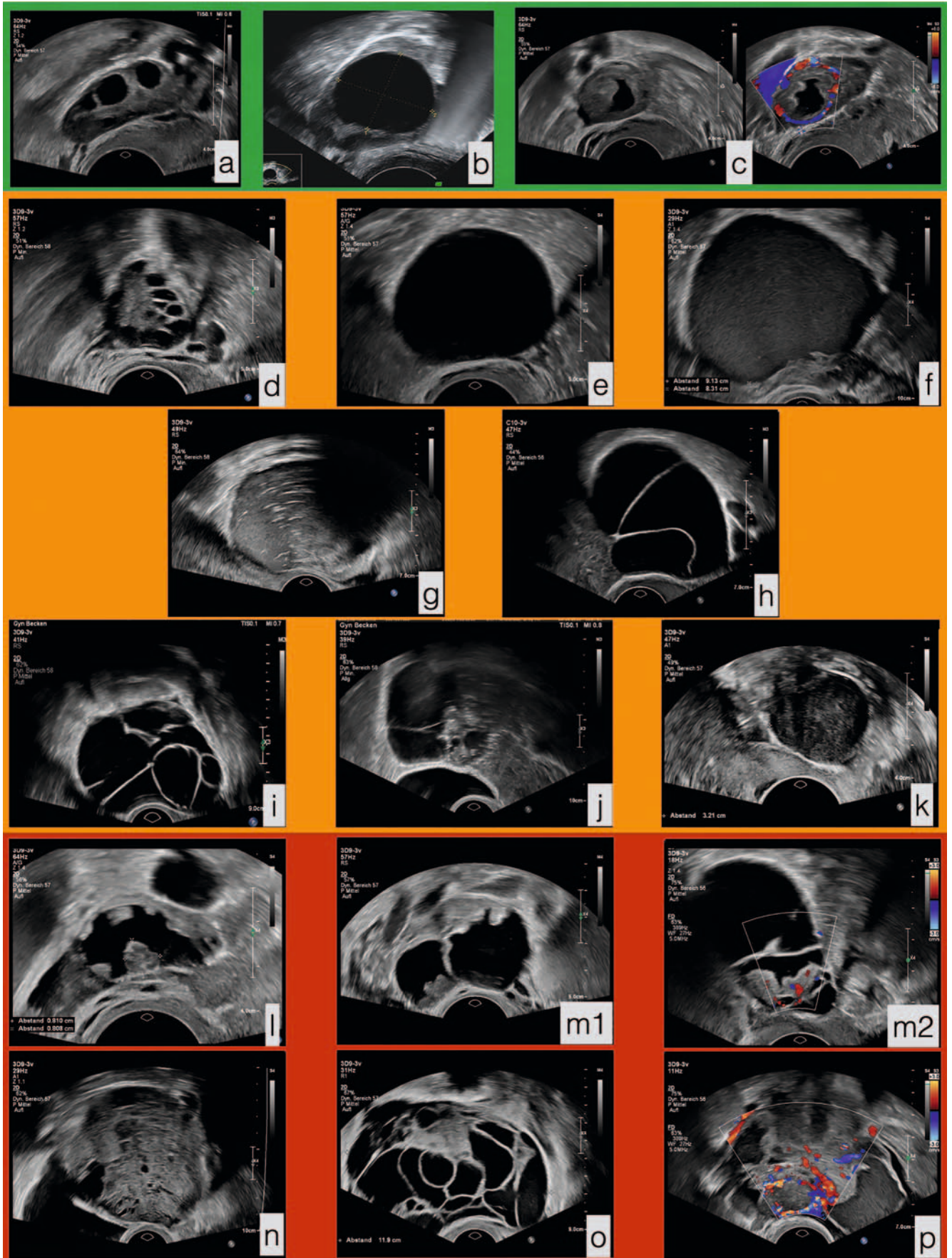
Criterion	Documentation
Total size	<ul style="list-style-type: none"> Measurement in 3 orthogonal planes
Solid portions/papillary stratification	<ul style="list-style-type: none"> Largest solid portion in 3 planes Number of papillary stratifications (0–3 or ≥ 4)
Tumor complexity	Specific classification as <ul style="list-style-type: none"> Unilocular-cystic Multilocular-cystic Unilocular-solid Multilocular-solid Solid
Cyst content	Distinction <ul style="list-style-type: none"> Anechoic Hypoechoic Ground glass Mixed Hemorrhagic
Number of cysts	<ul style="list-style-type: none"> n = ? > 10?
Wall structure	<ul style="list-style-type: none"> Smooth Irregular
Acoustic shadows	<ul style="list-style-type: none"> Present Absent
Ascites	<ul style="list-style-type: none"> Present Absent
Doppler sonography	<ul style="list-style-type: none"> Color score 1–4 (► Fig. 3)

► **Table 6** Sonographic criteria for ovary torsion.

Sonographic torsion criteria
<ul style="list-style-type: none"> Edema of ovary and fallopian tube
<ul style="list-style-type: none"> Increased echogenicity
<ul style="list-style-type: none"> Ovary enlargement > 4 cm
<ul style="list-style-type: none"> Reduced/absent perfusion (cavity: in early-stage hyperemia venous congestion)
<ul style="list-style-type: none"> “Whirl-pool” sign in Doppler
<ul style="list-style-type: none"> Presence of cysts
<ul style="list-style-type: none"> Free fluid

neous manual pressure on the lower abdomen. Normally, it should be possible to move the posterior wall of the cervix against the rectum (sliding sign). If this displaceability is missing, obliteration of the Douglas space must be assumed.

The final examination step involves the specific search for nodular foci of deep infiltrating endometriosis in the anterior or posterior segment of the lesser pelvis. This transvaginal examination has significant diagnostic value, but also requires a high degree of



► **Fig. 8** Example findings of transvaginal ultrasonography of the ovary. **a** Normal finding of a premenopausal ovary in early proliferation stage; **b** Normal finding of a premenopausal ovary, periovulatory, with 2.4 cm dominant follicle; **c** Normal findings of a premenopausal ovary in the 2nd half of the cycle with corpus luteum and annular perfusion shown in color Doppler sonography; **d** Polycystic ovary with condensed string of beads-like collection of small follicular cysts in the peripheral region of the ovary; **e** Simple anechoic unilocular cyst with smooth wall, largest diameter 4.3 cm; **f** Unilocular cyst with ground glass-like contents and slightly irregular wall, largest diameter 9.1 cm, pathognomic representation of an endometrioma; **g** unilocular cyst with mixed echogenic cyst contents and pronounced sonic shadow, largest diameter 5.5 cm, pathognomic representation of a dermoid cyst; **h** Multilocular cyst with anechoic cyst contents, smooth wall and septa, 3 chambers, largest diameter 6.1 cm, typical representation of a serous cystadenoma; **i** Multilocular cyst with hypoechoic cyst contents, septa of varying thickness, partly honeycomb-like cyst structure, < 10 chambers, largest diameter 5.5 cm, typical image of a mucinous cystadenoma; **j** Multilocular solid ovarian mass, septa of different thickness, echogenic solid parts with sound shadows, largest diameter 4.7 cm. Histology revealed a cystadenofibroma; **k** solid ovarian mass, smooth-walled, homogeneous hypoechoic echogenicity, streaky acoustic shadow, largest diameter 3.6 cm. Typical image of an ovarian fibroma; **l** Unilocular solid ovarian mass with 7 papillary stratifications, hypoechoic cyst contents, largest finding diameter 3.8 cm, largest solid component 8.1 mm. Histology revealed a serous borderline tumor; **m** Serous borderline tumor; 1. Multilocular solid ovarian mass with 3 papillary stratifications, hypoechoic cyst contents, 2 chambers, largest finding diameter 5.5 cm, largest solid component 13mm; 2. Vessel intrusion into the papillary overlays, color score 3; **n** Solid ovarian tumor, inhomogeneous internal structure with small cystic interspersion, largest diameter 9.1 cm, irregular wall structure, no acoustic shadows despite solid structure. Histology revealed a granulosa cell tumor; **o** Multilocular solid tumor of ovary, largest diameter 11.9 cm, hypoechoic cyst contents, more than 10 chambers, various broad septa, largest solid component 3.5 cm. Histology revealed high-grade serous ovarian carcinoma; **p** Multilocular solid tumor of the ovary, largest diameter 10.1 cm, largest solid component 6 cm, ascites. Doppler revealed significant vascularization: Color score 4. Histology revealed high-grade serous ovarian cancer.

specialization and special experience of the examiner. The targeted diagnosis of deep infiltrating endometriosis should therefore be performed by investigators who have extensive experience in (or in close) cooperation with an endometriosis center beyond the Level II qualification.

Other Areas of Gynecological Sonography

The areas of application listed above cover frequent occasions for more advanced gynecological sonography, but, as explained in the introduction, cannot reproduce the entire spectrum. Sonographic diagnostics can also cover the internal genitals, such as bowel and bladder assessment, as well as upper abdominal sonography, and provide important additional information. Furthermore, important gynecological special areas such as urogynecology or reproductive medicine with differentiated sonographic examination techniques have developed and established, the scope and requirements of which are not part of this overview.

Summary and Outlook

The present compilation of quality requirements for gynecological sonography shows current criteria in the sonographic diagnosis of the most common gynecological pathologies. The DEGUM concept for success is based on the recognized standards of quality assurance, further training and scientific examination of the method. The introduction of DEGUM Level II for gynecological sonography completes the spectrum of gynecological diagnostics with obstetric prenatal sonography and breast sonography. This is an important step for the optimization of diagnostic processes, but also for the conscious perception and recognition of these important diagnostics and their position in the profession.

Conflict of Interest

The authors declare that they have no conflict of interest.

References

- [1] Timmerman D, Schwärzler P, Collins WP et al. Subjective assessment of adnexal masses with the use of ultrasonography: an analysis of interobserver variability and experience. *Ultrasound Obst Gyn* 1999; 13: 11–16. doi:10.1046/j.1469-0705.1999.13010011.x
- [2] Wong M, Thanatsis N, Amin T et al. Ultrasound diagnosis of endometrial cancer by subjective pattern recognition in women with postmenopausal bleeding: prospective inter-rater agreement and reliability study. *Ultrasound Obst Gyn* 2021. doi:10.1002/uog.22141
- [3] Faschingbauer F, Benz M, Häberle L et al. Subjective assessment of ovarian masses using pattern recognition: the impact of experience on diagnostic performance and interobserver variability. *Arch Gynecol Obstet* 2012; 285: 1663–1669. doi:10.1007/s00404-012-2229-2
- [4] Holsbeke CV, Daemen A, Yazbek J et al. Ultrasound Experience Substantially Impacts on Diagnostic Performance and Confidence when Adnexal Masses Are Classified Using Pattern Recognition. *Gynecol Obstet Inves* 2010; 69: 160–168. doi:10.1159/000265012
- [5] Sayasneh A, Kaijser J, Preisler J et al. Accuracy of ultrasonography performed by examiners with varied training and experience in predicting specific pathology of adnexal masses. *Ultrasound Obst Gyn* 2015; 45: 605–612. doi:10.1002/uog.14675
- [6] Timmerman D, Planchamp F, Bourne T et al. ESGO/ISUOG/IOTA/ESGE Consensus statements on the pre-operative diagnosis of ovarian tumours*. *Ultrasound Obst Gyn* 2021. doi:10.1002/uog.23635
- [7] Gynecologists TAC of O and. Practice Bulletin No. 174: Evaluation and Management of Adnexal Masses. *Obstetrics Gynecol* 2016; 128: e210–e226. doi:10.1097/aog.0000000000001768
- [8] Thomassin-Naggara I, Daraï E, Lécuru F et al. Valeur diagnostique de l'imagerie (échographie, doppler, scanner, IRM et TEP-TDM) pour le diagnostic d'une masse ovarienne suspecte et le bilan d'extension d'un cancer de l'ovaire, des trompes ou péritonéal primitif. Article rédigé sur la base de la recommandation nationale de bonnes pratiques cliniques en cancérologie intitulée «Conduites à tenir initiales devant des patientes atteintes d'un cancer épithélial de l'ovaire» élaborée par FRANCOGYN, CNGOF, SFOG, GINECO-ARCAGY sous l'égide du CNGOF et labellisée par l'INCa. *Gynécologie Obstétrique Fertilité Sénologie* 2019; 47: 123–133. doi:10.1016/j.gofs.2018.12.012
- [9] Gynaecologists RC of O and. The Management of Ovarian Cysts in Postmenopausal Women. Green-top Guideline No34 2016. Im Internet: https://www.rcog.org.uk/globalassets/documents/guidelines/green-top-guidelines/gtg_34.pdf

- [10] Wattar B, Rimmer M, Rogozinska E et al. Accuracy of imaging modalities for adnexal torsion: a systematic review and meta-analysis. *Bjog Int J Obstetrics Gynaecol* 2021; 128: 37–44. doi:10.1111/1471-0528.16371
- [11] Grimbizis GF, Sardo ADS, Saravelos SH et al. The Thessaloniki ESHRE/ESGE consensus on diagnosis of female genital anomalies. *Human Reproduction* 2016; 31: 2–7. doi:10.1093/humrep/dev264
- [12] Shetty M. Imaging and differential diagnosis of ovarian cancer. *Seminars Ultrasound Ct Mri* 2019; 40: 302–318. doi:10.1053/j.sult.2019.04.002
- [13] Imaging: EP on W, Atri M, Alabousi A, et al. ACR Appropriateness Criteria® Clinically Suspected Adnexal Mass, No Acute Symptoms. *J Am Coll Radiol* 2019; 16: S77–S93. doi:10.1016/j.jacr.2019.02.011
- [14] Kaijser J, Vandecaveye V, Deroose CM et al. Imaging techniques for the pre-surgical diagnosis of adnexal tumours. *Best Pract Res Clin Ob* 2014; 28: 683–695. doi:10.1016/j.bpobgyn.2014.03.013
- [15] Dodge JE, Covens AL, Lacchetti C et al. Preoperative identification of a suspicious adnexal mass: A systematic review and meta-analysis. *Gynecol Oncol* 2012; 126: 157–166. doi:10.1016/j.ygyno.2012.03.048
- [16] Williams P, Murchie P, Bond C. Patient and primary care delays in the diagnostic pathway of gynaecological cancers: a systematic review of influencing factors. *Br J Gen Pract* 2019; 69: bjgp19X700781 doi:10.3399/bjgp19x700781
- [17] Baun ML, Falborg AZ, Hjertholm P et al. Ovarian cancer stage, variation in transvaginal ultrasound examination rates and the impact of an urgent referral pathway: A national ecological cohort study. *Acta Obstet Gyn Scan* 2019; 98: 1540–1548. doi:10.1111/aogs.13693
- [18] Verleye L, Vergote I, van der Zee AGJ. Patterns of care in surgery for ovarian cancer in Europe. *European J Surg Oncol Ejs* 2010; 36: S108–S114. doi:10.1016/j.ejs.2010.06.006
- [19] Grab D, Merz E, Prömpeler H et al. Standards zur gynaekologischen Sonografie. *Ultraschall in Med* 2011; 32: 415–417. doi:10.1055/s-0031-1281592
- [20] de Bosch TV, Dueholm M, Leone FPG et al. Terms, definitions and measurements to describe sonographic features of myometrium and uterine masses: a consensus opinion from the Morphological Uterus Sonographic Assessment (MUSA) group. *Ultrasound Obst Gyn* 2015; 46: 284–298. doi:10.1002/uog.14806
- [21] Munro MG, Critchley HOD, Fraser IS et al. The FIGO classification of causes of abnormal uterine bleeding in the reproductive years. *Fertil Steril* 2011; 95: 2204–2208.e3. doi:10.1016/j.fertnstert.2011.03.079
- [22] Multinu F, Casarin J, Tortorella L et al. Incidence of sarcoma in patients undergoing hysterectomy for benign indications: a population-based study. *Am J Obstet Gynecol* 2019; 220: 179.e1–e179.e10 doi:10.1016/j.ajog.2018.11.1086
- [23] Ludovisi M, Moro F, Pasciuto T et al. Imaging in gynecological disease (15): clinical and ultrasound characteristics of uterine sarcoma. *Ultrasound Obst Gyn* 2019; 54: 676–687. doi:10.1002/uog.20270
- [24] Amant F, van den Bosch T, Vergote I et al. Morcellation of uterine leiomyomas: a plea for patient triage. *The Lancet Oncology* 2015; 16: 1454–1456. doi:10.1016/s1470-2045(15)00375-7
- [25] Testa AC, Legge AD, Blasis ID et al. Imaging techniques for the evaluation of cervical cancer. *Best practice & research Clinical obstetrics & gynaecology* 2014; 28: 741–768. doi:10.1016/j.bpobgyn.2014.04.009
- [26] Epstein E, Testa A, Gaurilcik A et al. Early-stage cervical cancer: tumor delineation by magnetic resonance imaging and ultrasound – a European multicenter trial. *Gynecologic oncology* 2013; 128: 449–453. doi:10.1016/j.ygyno.2012.09.025
- [27] Byun JM, Kim YN, Jeong DH et al. Three-dimensional transvaginal ultrasonography for locally advanced cervical cancer. *International journal of gynecological cancer: official journal of the International Gynecological Cancer Society* 2013; 23: 1459–1464. doi:10.1097/igc.0b013e3182a16997
- [28] Bakay OA, Golovko TS. Use of elastography for cervical cancer diagnostics. *Experimental oncology* 2015; 37: 139–145. doi:10.1002/uog.11223
- [29] DGGG, OEGGG, SGGG. AWMF Leitlinie Registernr.015/052 Weibliche genitale Fehlbildungen. Im Internet: https://www.awmf.org/uploads/tx_szleitlinien/015-052l_S1_Weibliche_genitale_Fehlbildungen_2020-06.pdf
- [30] Society TAF. The American Fertility Society classifications of adnexal adhesions, distal tubal occlusion, tubal occlusion secondary to tubal ligation, tubal pregnancies, Müllerian anomalies and intrauterine adhesions. *Fertil Steril* 1988; 49: 944–955. doi:10.1016/s0015-0282(16)59942-7
- [31] Oppelt P, Renner SP, Brucker S et al. The VCUAM (Vagina Cervix Uterus Adnex-associated Malformation) Classification: a new classification for genital malformations. *Fertil Steril* 2005; 84: 1493–1497. doi:10.1016/j.fertnstert.2005.05.036
- [32] Grimbizis GF, Gordts S, Sardo ADS et al. The ESHRE/ESGE consensus on the classification of female genital tract congenital anomalies. *Human Reproduction* 2013; 28: 2032–2044. doi:10.1093/humrep/det098
- [33] Imboden S, Müller M, Raio L et al. Klinische Bedeutung des 3D-Ultraschalls neben MRI bei uterinen Fehlbildungen. *Ultraschall in Med* 2014; 35: 440–444. doi:10.1055/s-0033-1335664
- [34] Ghi T, Casadio P, Kuleva M et al. Accuracy of three-dimensional ultrasound in diagnosis and classification of congenital uterine anomalies. *Fertility and Sterility* 2009; 92: 808–813. doi:10.1016/j.fertnstert.2008.05.086
- [35] Bermejo C, Martinez-Ten P, Recio M et al. Three-dimensional ultrasound and magnetic resonance imaging assessment of cervix and vagina in women with uterine malformations. *Ultrasound Obst Gyn* 2014; 43: 336–345. doi:10.1002/uog.12536
- [36] Ludwin A, Martins WP, Nastri CO et al. Congenital Uterine Malformation by Experts (CUME): better criteria for distinguishing between normal/arcuate and septate uterus? *Ultrasound Obst Gyn* 2018; 51: 101–109. doi:10.1002/uog.18923
- [37] Bajka M, Badir S. Fundus Thickness Assessment by 3D Transvaginal Ultrasound Allows Metrics-Based Diagnosis and Treatment of Congenital Uterine Anomalies. *Ultraschall in Med* 2017; 38: 183–189. doi:10.1055/s-0034-1399701
- [38] Leone FPG, Timmerman D, Bourne T et al. Terms, definitions and measurements to describe the sonographic features of the endometrium and intrauterine lesions: a consensus opinion from the International Endometrial Tumor Analysis (IETA) group. *Ultrasound Obst Gyn* 2010; 35: 103–112. doi:10.1002/uog.7487
- [39] Valentin L. Ultrasound deserves to play a prominent role in the diagnosis and management of endometrial cancer. *Ultrasound Obst Gyn* 2014; 43: 483–487. doi:10.1002/uog.13371
- [40] Epstein E, Fischerova D, Valentin L et al. Ultrasound characteristics of endometrial cancer as defined by International Endometrial Tumor Analysis (IETA) consensus nomenclature: prospective multicenter study. *Ultrasound Obst Gyn* 2018; 51: 818–828. doi:10.1002/uog.18909
- [41] Bosch TVD, Verbakel JY, Valentin L et al. Typical ultrasound features of various endometrial pathologies described using International Endometrial Tumor Analysis (IETA) terminology in women with abnormal uterine bleeding. *Ultrasound Obst Gyn* 2021; 57: 164–172. doi:10.1002/uog.22109
- [42] Andreotti RF, Fleischer AC. Practical Applications of 3D Sonography in Gynecologic Imaging. *Radiol Clin N Am* 2014; 52: 1201–1213. doi:10.1016/j.rcl.2014.07.001
- [43] Epstein E, Fischerova D, Valentin L et al. Ultrasound characteristics of endometrial cancer as defined by International Endometrial Tumor Analysis (IETA) consensus nomenclature: prospective multicenter study. *Ultrasound Obst Gyn* 2018; 51: 818–828. doi:10.1002/uog.18909

- [44] Weber G, Merz E, Bahlmann F et al. Assessment of myometrial infiltration and preoperative staging by transvaginal ultrasound in patients with endometrial carcinoma. *Ultrasound Obst Gyn* 1995; 6: 362–367. doi:10.1046/j.1469-0705.1995.06050362.x
- [45] Timor-Tritsch IE, Monteagudo A, Tsybal T. Three-dimensional ultrasound inversion rendering technique facilitates the diagnosis of hydrosalpinx. *J Clin Ultrasound* 2010; 38: 372–376. doi:10.1002/jcu.20707
- [46] Chappell CA, Wiesenfeld HC. Pathogenesis, Diagnosis, and Management of Severe Pelvic Inflammatory Disease and Tuboovarian Abscess. *Clin Obstet Gynecol* 2012; 55: 893–903. doi:10.1097/grf.0b013e3182714681
- [47] Taran FA, Kagan KO, Hübner M et al. The Diagnosis and Treatment of Ectopic Pregnancy. *Deutsches Ärzteblatt international* 2015; 112: 693–703-quiz 704–705. doi:10.3238/arztebl.2015.0693
- [48] Kirk E, Bottomley C, Bourne T. Diagnosing ectopic pregnancy and current concepts in the management of pregnancy of unknown location. *Human reproduction update* 2014; 20: 250–261. doi:10.1093/humupd/dmt047
- [49] Merz E, Weber G, Bahlmann F et al. A New Sonomorphologic Scoring System (Mainz Score) for the Assessment of Ovarian Tumors Using Transvaginal Ultrasonography – Part I: A Comparison Between the Scoring-System and the Assessment by an Experienced Sonographer. *Ultraschall in Med* 1998; 19: 99–107. doi:10.1055/s-2007-1000471
- [50] Timmerman D, Valentin L, Bourne TH et al. Terms, definitions and measurements to describe the sonographic features of adnexal tumors: a consensus opinion from the International Ovarian Tumor Analysis (IOTA) Group. *Ultrasound Obst Gyn* 2000; 16: 500–505. doi:10.1046/j.1469-0705.2000.00287.x
- [51] Andreotti RF, Timmerman D, Strachowski LM et al. O-RADS US Risk Stratification and Management System: A Consensus Guideline from the ACR Ovarian-Adnexal Reporting and Data System Committee. *Radiology* 2019; 294: 191150 doi:10.1148/radiol.2019191150
- [52] Sladkevicius P, Jokubkiene L, Timmerman D et al. Vessel morphology depicted by three-dimensional power Doppler ultrasound as second-stage test in adnexal tumors that are difficult to classify: prospective diagnostic accuracy study. *Ultrasound Obst Gyn* 2021; 57: 324–334. doi:10.1002/uog.22191
- [53] Amey L, Timmerman D, Valentin L et al. Clinically oriented three-step strategy for assessment of adnexal pathology. *Ultrasound Obst Gyn* 2012; 40: 582–591. doi:10.1002/uog.11177
- [54] Bardin R, Perl N, Mashiach R et al. Prediction of Adnexal Torsion by Ultrasound in Women with Acute Abdominal Pain. *Ultraschall in Med* 2019; 41: 688–694. doi:10.1055/a-1014-2593
- [55] Guerriero S, Condous G, den Bosch TV et al. Systematic approach to sonographic evaluation of the pelvis in women with suspected endometriosis, including terms, definitions and measurements: a consensus opinion from the International Deep Endometriosis Analysis (IDEA) group. *Ultrasound Obst Gyn* 2016; 48: 318–332. doi:10.1002/uog.15955
- [56] Mattos LA, Goncalves MO, Andres MP et al. Structured US and MRI imaging report for patients with suspected endometriosis: Guide for Imagers and Clinicians. *J Minim Invas Gyn L* 2019; 26: 1016–1025. doi:10.1016/j.jmig.2019.02.017
- [57] Ulrich U, Buchweitz O, Greb R et al. National German Guideline (S2k): Guideline for the Diagnosis and Treatment of Endometriosis*. *Geburtsh Frauenheilk* 2014; 74: 1104–1118. doi:10.1055/s-0034-1383187