

From Research to Clinical Practice: Long-Term Impact of Randomized Clinical Trial Examining the Effect of Lumbar Drains on Cerebrospinal Fluid Leak Rates Following Endonasal Skull Base Surgery

Philippe Lavigne¹ Eric W. Wang² Paul A. Gardner³ Carl H. Snyderman⁴

¹ Department of Otolaryngology, Centre Hospitalier Universitaire de l'Université de Montreal, Montreal, Quebec, Canada

² Department of Neurosurgery, University of Pittsburgh, Pittsburgh, Pennsylvania, United States

³ Department of Otolaryngology, University of Pittsburgh Medical Center, Pittsburgh, Pennsylvania, United States

⁴ Department of Otolaryngology, University of Pittsburgh, Pittsburgh, Pennsylvania, United States

Address for correspondence Philippe Lavigne, MD, Department of Otolaryngology, Centre Hospitalier Universitaire de l'Université de Montreal, Montreal, Quebec, Canada (e-mail: philippe.lavigne4@gmail.com).

J Neurol Surg B Skull Base 2022;83:339–342.

Abstract

Intraoperative cerebrospinal fluid (CSF) leaks are associated with increased risk of postoperative CSF leaks despite multilayered reconstruction with vascularized tissue. A recent randomized controlled trial (RCT) examining the use of perioperative lumbar drains (LD) in high-risk skull base defects identified a significant reduction in postoperative CSF leak incidence (21.2 vs. 8.2%; $p = 0.017$). This study was conducted to assess the efficacy of the selective use of CSF diversion, for patients with intraoperative CSF leaks involving endoscopic endonasal approaches (EEA) to the skull base.

Method Consecutive endoscopic endonasal surgeries of the skull base from a pre-RCT cohort and post-RCT cohort were compared. The following case characteristics between the two cohorts were examined: patient age, body mass index (BMI), rate of revision surgery, tumor histology, use of CSF diversion, and vascularized reconstruction. The primary measured outcome was postoperative CSF leak.

Results The pre-RCT cohort included 76 patients and the post-RCT cohort included 77 patients, with dural defects in either the anterior or posterior cranial fossa (pituitary and parasellar/suprasellar surgeries excluded). There was a significant reduction in the incidence of postoperative CSF leak in the post-RCT cohort (27.6 vs. 12.9%; $p = 0.04$). On subgroup analysis, there was a trend toward improvement in CSF leak rate of the anterior cranial fossa (19.2 vs. 10.5%; $p = 0.27$), whereas CSF leak rates of the posterior cranial fossa were significantly reduced compared with the pre-RCT cohort (41.4 vs. 12.8%; $p = 0.02$).

Conclusion This study demonstrates that the integration of selective CSF diversion into the reconstructive algorithm improved postoperative CSF leak rates.

Keywords

- cerebrospinal fluid
- skull base reconstruction
- lumbar drain
- skull base surgery

received

May 20, 2021

accepted after revision

October 24, 2021

published online

December 14, 2021

© 2021. Thieme. All rights reserved.
Georg Thieme Verlag KG,
Rüdigerstraße 14,
70469 Stuttgart, Germany

DOI <https://doi.org/10.1055/a-1680-1870>.
ISSN 2193-6331.

Introduction

Multilayer reconstruction of skull base defects with vascularized tissue has been shown to significantly reduce rates of postoperative cerebrospinal fluid (CSF) leaks.^{1,2} Reduction of intracranial pressure with perioperative lumbar drainage may further reduce risk of postoperative CSF leak, but this is controversial.³ A recent randomized controlled trial (RCT) at the University of Pittsburgh Medical Center (UPMC) evaluated the use of perioperative lumbar drains (LD) in high-risk endoscopic endonasal skull base defects and found that they were associated with a significant reduction in postoperative CSF leak rates (21.2 vs. 8.2%; $p=0.017$).⁴ Secondary post hoc analysis from this study found that the use of perioperative LD was mostly beneficial for anterior and posterior cranial fossa defects, with no significant difference for suprasellar defects (sellar defects were not enrolled). This level Ib evidence led to the implementation of selective usage of LD as part of the reconstruction algorithm at our institution.

This study presents our institution's most recent data on postoperative CSF leak rates following endoscopic endonasal surgery of the skull base, which importantly capture outcomes before and after the integration of selective lumbar drainage as part of our skull base reconstruction algorithm.

Materials and Methods

A retrospective review of the patients who underwent an endoscopic endonasal approach (EEA) between January 2009 and July 2018 was performed. Included patients underwent EEA with reconstruction of intraoperative CSF leaks associated with anterior or posterior cranial fossa dural defects. Sellar and suprasellar approaches were excluded. Spontaneous CSF leaks of the anterior cranial fossa were also excluded as they represent a different pathophysiology and usually offer a good prognosis given their small size and lower flow. The LD trial was conducted from February 2011 to June 2015. Consecutively performed cases were dichotomized as either occurring pre-RCT (January 2009 to January 2011) or post-RCT (July 2016 to July 2018), with this inflection point indicative of the implementation of selective use of LD as

part of our reconstruction algorithm. These two cohorts were then compared (►Fig. 1) across the following characteristics: age, body mass index (BMI), revision surgery, tumor histology, use of CSF diversion, and vascularized reconstruction. An LD was indicated for high-flow leaks (dural defect $>1\text{ cm}^2$, extensive arachnoid dissection, and/or dissection into a ventricle or cistern). It was placed immediately at the end of the surgery in the operating room before emergence from anesthesia. It was set for a titration of 10 mL per hour and removed after 72 hours without a "clamping trial." The primary outcome evaluated was postoperative CSF leak. Chi-squared test and Student's *t*-test were performed for categorical and numerical data analysis, respectively.

Results

A total of 832 EEA patients were screened for possible study inclusion. Six hundred and seventy-nine patients were excluded due to either lack of intraoperative CSF leak or surgical site other than the anterior or posterior cranial fossa. ►Table 1 presents the pathologies encountered for each group. The pre-RCT cohort (2009–2011) included 76 patients and the post-RCT cohort (2016–2018) included 77 patients. Between the groups, there was no difference in age (51.6 vs. 56.1 years; $p=0.10$), BMI (27.6 vs. 29.7; $p=0.15$), rate of revision surgery (13.2 vs. 22.0%; $p=0.15$), rate of malignancy (63.2 vs. 58.4%; $p=0.19$), or rate of vascularized reconstruction (77.6 vs. 74.0%; $p=0.60$; ►Table 2). The use of CSF diversion at the time of surgery was significantly increased in the post-RCT cohort (13.2 vs. 76.6%; $p=0.0001$). When considered separately, the use of LD was increased in both the anterior cranial fossa (6.4 to 78.9%; $p=0.001$) and posterior cranial fossa (24.1 to 74.4%; $p=0.001$) approaches in the post-RCT cohort.

Compared with the pre-RCT cohort, postoperative CSF leak rates were significantly reduced in the post-RCT cohort (27.6 vs. 12.9%; $p=0.04$). ►Fig. 2 illustrates the evolution of postoperative CSF leak rates for anterior and posterior cranial fossa defects over the study period. On subgroup analysis, there was a trend toward improvement in CSF leak rate of the anterior cranial fossa (19.2 vs. 10.5%; $p=0.27$), whereas CSF leak rates of the posterior cranial fossa were significantly

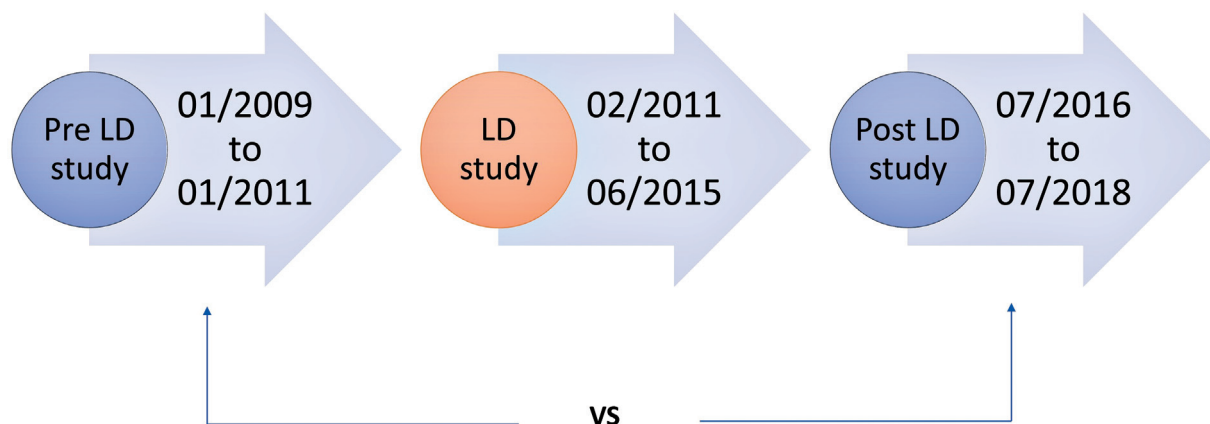


Fig. 1 Study design: prelumbar drain trial cohort versus postlumbar drain cohort outcomes.

Table 1 Pathology based on location and number of patients (pretrial, posttrial)

Anterior	Posterior fossa
Meningioma (13, 21)	Chordoma (17, 24)
Olfactory neuroblastoma (15, 7)	Chondrosarcoma (4, 7)
SCC (0, 3)	Meningioma (8, 6)
SNUC (5, 0)	Adenoma (0, 1)
Metastasis (1, 1)	Epidermoid (0, 1)
Trauma (4, 2)	
Neuroendocrine carcinoma (2, 1)	
Hemangiopericytoma (1, 0)	
Adenocarcinoma (1, 2)	
Infectious/ORN (1, 1)	
Adenoid cystic carcinoma (1, 0)	
Sarcoma (1, 0)	
Fibro-osseous (1, 0)	
Vascular lesion (1, 0)	

Abbreviations: ORN, osteoradionecrosis; SCC, squamous cell carcinoma; SNUC, sinonasal undifferentiated carcinoma.

reduced compared with the pre-RCT cohort (41.4 vs. 12.8%; $p = 0.02$).

Discussion

Multilayered reconstruction with vascularized tissue in skull base surgery has been validated by level IIa evidence.¹

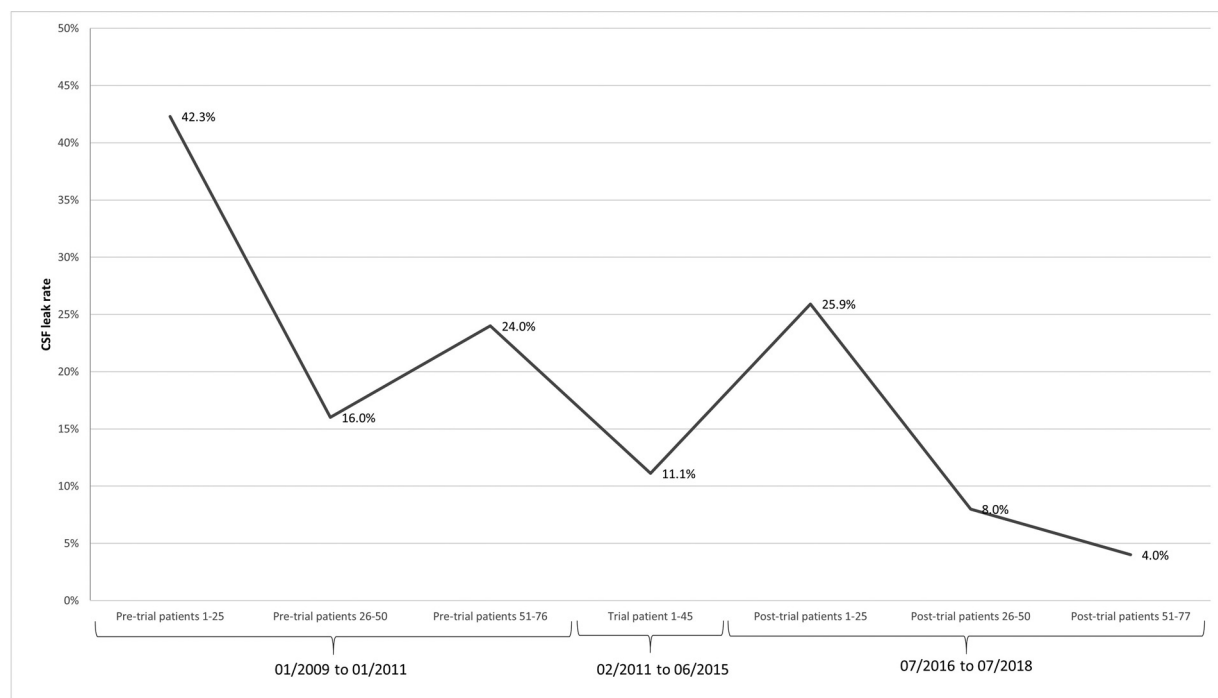
Table 2 Demographics and characteristics of cohorts

	Pretrial cohort	Posttrial cohort	p value
Number of patients	76	77	
Age (y)	51.6	56.1	0.10
BMI	27.6	29.7	0.15
Revision surgery rate (%)	13.2	22.0	0.15
Malignancy rate (%)	63.2	58.4	0.19
Vascularized reconstruction rate (%)	77.6	74.0	0.60
CSF diversion rate (%)	13.2	76.6	0.0001 ^a

Abbreviations: BMI, body mass index; CSF, cerebrospinal fluid.

^aStatistically significant.

Results from a recent RCT have also demonstrated the utility of perioperative LD as it was associated with marked reductions in postoperative CSF leak rates relating to anterior and posterior cranial fossa defects.⁴ However, clinical implementation of perioperative LD outside of the controlled, blinded setting of an RCT introduces subjective elements into the decision-making process of whether LD should be utilized, such as a patient's unique history, comorbidities, and disease process.^{5,6} In an effort to provide individualized care, the decision to employ LD is made in accordance to their specific risk factors for postoperative CSF leak, balancing the risks and benefits of the added procedure. This study provides evidence that integration of selective (individualized) use of postoperative LD has significantly reduced the occurrence of

**Fig. 2** Evolution of cerebrospinal fluid (CSF) leak rates (anterior and posterior cranial fossa only). Pre- and posttrial cohorts were divided into three consecutive groups of patients to assess the intracohort trend.

postoperative CSF leaks in patients with posterior fossa defects (41.4 vs. 12.8%; $p=0.02$). Also, the CSF leak rate was reduced for anterior cranial fossa defects but did not reach statistical significance (19.2 vs. 10.5%; $p=0.27$). In the current clinic practice, all patients who undergo surgery of the anterior fossa or posterior fossa receive an LD if the intraoperative CSF leak is considered high flow (dural defect larger than 1 cm², communication with cistern, significant arachnoid dissection). Additional clinical elements that are taken into consideration when deciding to use postoperative LD are the following: revision surgery, prior radiation therapy, patient BMI, obstructive sleep apnea syndrome, and ability to cover the entire defect with vascularized tissue.

Interestingly, the reduction in postoperative CSF leak rates of anterior cranial fossa defects showed a clear trend but did not reach significance (19.2 vs. 10.5%; $p=0.27$). This is likely caused by limited number of cases in each group, making the analysis underpowered. Therefore, although there does appear to be a role in this setting, high-quality prospective studies are required to fully assess the role of perioperative LD for reconstruction of anterior cranial fossa defects.

A limitation to this study is the retrospective review of factors thought to be associated with incidence of postoperative CSF leak (BMI, defect location, tumor histology, patient demographics). Additionally, over the period that the data were collected, several factors evolved and were thus not kept constant such as surgeon experience, overall reconstructive techniques, use of fascia lata (increased from 8.2 to 62.9%, $p=0.001$) and postoperative management other than lumbar drainage (i.e., nasal packing, postoperative patient restrictions). Nevertheless, the implementation of postoperative LD was an easily identifiable inflection point that could be used to reassess CSF leak rates.

Conclusion

Selective use of LD after reconstruction of skull base defects remains controversial. This study examined the efficacy of the implementation of perioperative LD into the reconstruction algorithm outside the controlled and blinded confines of an RCT. Our findings suggest that selective perioperative LD, together with the evolution of reconstructive techniques, greatly improved the incidence of postoperative CSF leak in endoscopic endonasal surgery, most significantly for posterior cranial fossa defects.

Conflict of Interest

None declared.

References

- 1 Harvey RJ, Parmar P, Sacks R, Zanation AM. Endoscopic skull base reconstruction of large dural defects: a systematic review of published evidence. *Laryngoscope* 2012;122(02):452–459
- 2 Thorp BD, Sreenath SB, Ebert CS, Zanation AM. Endoscopic skull base reconstruction: a review and clinical case series of 152 vascularized flaps used for surgical skull base defects in the setting of intraoperative cerebrospinal fluid leak. *Neurosurg Focus* 2014;37(04):E4
- 3 Ahmed OH, Marcus S, Tauber JR, Wang B, Fang Y, Lebowitz RA. Efficacy of perioperative lumbar drainage following endonasal endoscopic cerebrospinal fluid leak repair. *Otolaryngol Head Neck Surg* 2017;156(01):52–60
- 4 Zwagerman NT, Wang EW, Shin SS, et al. Does lumbar drainage reduce postoperative cerebrospinal fluid leak after endoscopic endonasal skull base surgery? A prospective, randomized controlled trial. *J Neurosurg* 2018;131(04):1172–1178
- 5 Suvarna VR. Real world evidence (RWE): are we (RWE) ready? *Perspect Clin Res* 2018;9(02):61–63
- 6 Webster J, Smith BD. The case for real-world evidence in the future of clinical research on chronic myeloid leukemia. *Clin Ther* 2019;41(02):336–349